



## Can texture indices derived from PET images differentiate tissue types?

Fanny Orhac, Michaël Soussan, Irène Buvat

### ► To cite this version:

Fanny Orhac, Michaël Soussan, Irène Buvat. Can texture indices derived from PET images differentiate tissue types?. Journées RITS 2015, Mar 2015, Dourdan, France. Actes des Journées RITS 2015, pp 96-97, 2015. <inserm-01154778>

**HAL Id: inserm-01154778**

**<http://www.hal.inserm.fr/inserm-01154778>**

Submitted on 23 May 2015

**HAL** is a multi-disciplinary open access archive for the deposit and dissemination of scientific research documents, whether they are published or not. The documents may come from teaching and research institutions in France or abroad, or from public or private research centers.

L'archive ouverte pluridisciplinaire **HAL**, est destinée au dépôt et à la diffusion de documents scientifiques de niveau recherche, publiés ou non, émanant des établissements d'enseignement et de recherche français ou étrangers, des laboratoires publics ou privés.



Distributed under a Creative Commons Attribution 4.0 International License

## Can texture indices derived from PET images differentiate tissue types?

Fanny Orlhac<sup>1\*</sup>, Michaël Soussan<sup>1,2</sup>, Irène Buvat<sup>1</sup>

<sup>1</sup> IMIV, U1023 Inserm / CEA-I2BM-SHFJ / Université Paris Sud - ERL 9218 CNRS, Orsay, France.

<sup>2</sup> Department of Nuclear Medicine, AP-HP, Avicenne Hospital, Bobigny, France.

\*Corresponding author, fanny.orphac@u-psud.fr

**Abstract – Aim:** Texture indices (TI) are of growing interest for tumor characterization. Yet, whether FDG-PET images can evidence tissue-specific pattern has received little attention so far. We studied the ability of enhanced TI to determine tissue types. **Materials and Methods:** Forty-eight patients with non-small cell lung cancer underwent FDG-PET before treatment. Seven enhanced TI were calculated using a new resampling method. Standardized Uptake Value (SUV) and metabolic volume (MV) were also systematically computed. The ability of each index to distinguish between tumor and liver tissue and between two subtypes of cancer was investigated using ROC analyses. **Results:** All enhanced TI could differentiate tumor from liver tissue with an Area Under the ROC Curve (AUC) higher than 0.692. Homogeneity and Low Gray-Level Emphasis could differentiate the adenocarcinomas (n=28) and squamous cell carcinomas (n=12) with AUC better than that of SUVmax and MV (Delong's test). Liver tissue had a more homogeneous texture than tumor tissue and adenocarcinomas exhibited a more homogeneous texture than squamous cell carcinomas. **Conclusion:** Enhanced TI vary as a function of the tissue type and cancer subtype, and might be used as a new tool for tumor characterization.

**Index terms - Image Processing, Medical Physics, Nuclear imaging.**

### I. INTRODUCTION

In oncology, the coexistence of different clones in a tumor as well as biological heterogeneity like necrosis, fibrosis or the presence of specific receptor affect the evolution of cancer and the choice of therapy. Therefore, several groups have explored the interest of texture indices (TI) based on PET images to characterize tumor heterogeneity for various types of cancer [1-3]. Two studies also demonstrated that some TI were strongly correlated with the tumor metabolic volume (MV) [4], especially for small tumors (less than 45 mL) [5]. Yet, the meaning and actual variation of textural metrics as a function of tissue type has not been carefully reported.

The purpose of this study was to investigate the value of enhanced TI in different tissue types.

### II. MATERIALS AND METHODS

#### II.1. Patients and PET/CT protocol

Forty-eight patients with non-small cell lung cancer were included in this study. Histological analysis was performed after surgery to determine the subtype of cancer: adenocarcinoma (n=28), squamous cell carcinoma (n=12) or other (n=8). All patients underwent an 18F-FDG PET/CT using a Gemini TF PET/CT scanner (Philips) before treatment. PET images were converted in Standardized Uptake Value (SUV) units normalized by the patient body weight.

#### II.2. Volume of interest (VOI) delineation

For each patient, the primary tumor was delineated using an adaptive threshold. The tumor VOI (VOI-T) was moved in the liver of the patient (VOI-L). For each VOI, MV and the maximum SUV (SUVmax) were computed.

#### II.3. Texture analysis

Before calculating TI, voxel intensities were resampled between 0 and 20 SUV units using 64 discrete values. This new resampling method differs from the conventional one consisting of resampling between the minimum and maximum SUV of each single tumor and has the advantage to cancel the correlation between TI and MV observed in [4-5]. After this step, we computed 3 texture matrices: co-occurrence matrix, gray-level run length matrix and gray-level zone length matrix. We extracted 7 so-called enhanced (due to the new resampling approach) TI: homogeneity, entropy, Short-Run Emphasis (SRE), Long-Run Emphasis (LRE), Run Length Non-Uniformity (RLNU), Low Gray-level Emphasis (LGZE) and High Gray-level Emphasis (HGZE).

#### II.4. Statistical analysis

The ability of each parameter to distinguish between tumor and liver tissue and between adenocarcinoma and squamous cell carcinoma was evaluated using ROC analysis. Differences in Area Under the ROC Curve (AUC) were tested using Delong's test. P-values less than 5% were considered statistically significant.

### III. RESULTS

The results of ROC analysis are summarized in Table 1. We show that for the new resampling method, the AUC varied between 0.870 and 0.982 as a function of TI for distinguishing between lung tumors and liver tissue. Four TI were more discriminant than SUVmax (AUC=0.930). Tumor tissue shows more heterogeneous texture than healthy tissue.

For the differentiation between the two subtypes of cancer, Homogeneity and LGZE yielded AUC equals to 0.778 and 0.756 respectively, that were statistically higher than AUC of SUVmax and MV. Adenocarcinoma exhibited more homogeneous texture than squamous cell carcinoma with higher homogeneity (Fig. 1), lower entropy and higher LGZE (data not shown).

### IV. DISCUSSION – CONCLUSION

We showed that enhanced TI computed with a new resampling method could differentiate tissue types with better performance than that of SUVmax and MV. These TI describe tissue-specific texture and might be used in addition to conventional indices. By distinguishing adenocarcinoma and squamous cell carcinoma, they might be useful to assess the tumor aggressiveness. These results are currently being confirmed in a larger cohort and other types of cancer.

In spite of modest spatial resolution in PET images, enhanced TI computed with an original resampling method might be useful as biomarkers and contribute to the tumor profiling in radiomic analyses towards personalized treatment.

Index	AUC (tumor vs. liver tissue)	AUC (cancer subtypes)
Homogeneity	0.982 *†	0.778*†
Entropy	0.978 *†	0.778 †
SRE	0.982 *†	0.731
LRE	0.978 *†	0.692 †
RLNU	0.692 †	0.692 †
LGZE	0.870 †	0.756*†
HGZE	0.884 †	0.758
SUVmax	0.930 †	0.747
MV	0.500	0.650

Table 1: Area under the ROC curve (AUC) for distinguishing tumor from liver tissue and adenocarcinoma from squamous cell carcinoma. \* or †: pvalue of Delong test lower than 5% with respect to SUVmax or MV respectively.

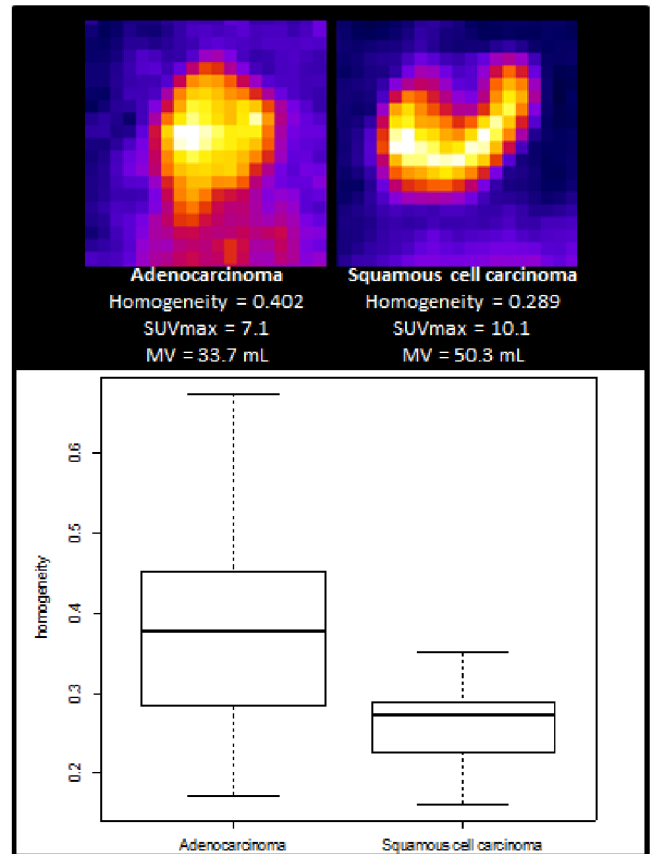


Figure 1: Illustration and boxplot of homogeneity for adenocarcinoma (left) and squamous cell carcinoma (right).

### REFERENCES

- [1] I. El Naqa, P. Grigsby, A. Apte et al., "Exploring feature-based approaches in PET images for predicting cancer treatment outcomes", *Pattern Recognit*, 2009, Vol. 42, pp. 1162-71.
- [2] F. Tixier, C.C. Le Rest, M. Hatt et al., "Intratumor heterogeneity characterized by textural features on baseline 18F-FDG PET images predicts response to concomitant radiochemotherapy in esophageal cancer", *J Nucl Med*, 2011, Vol. 52, pp. 369-78.
- [3] M. Soussan, F. Orhac, M. Boubaya et al., "Relationship between tumor heterogeneity measured on FDG-PET/CT and pathological prognostic factors in invasive breast cancer", *PlosOne*, 2014, Vol. 9, e94017.
- [4] F. Orhac, M. Soussan, J.A. Maisonobe et al., "Tumor texture analysis in 18F-FDG PET: relationships between texture parameters, histogram indices, standardized uptake values, metabolic volumes and total lesion glycolysis", *J Nucl Med*, 2014, Vol.55, pp. 414-22.
- [5] F.J. Brooks, P.W. Grigsby, "The effect of small tumor volumes on studies of intratumoral heterogeneity of tracer uptake", *J Nucl Med*, 2014, Vol.55, pp.37-42.