

The measurement of serum TNF- α levels in patients with lichen planus

Yesim Akpınar Kara¹✉

Abstract

Background: Lichen planus is a common mucocutaneous inflammatory skin disease with a multifactorial etiology. Cytokines play a key role in lichen planus pathogenesis. This study investigates the relationship between disease severity and levels of tumor necrosis factor- α (TNF- α), which is considered a primary cytokine that initiates cytotoxicity.

Material and methods: Serum TNF- α levels were compared between a patient group ($n = 34$) and a control group ($n = 20$). TNF- α serum levels were measured using human TNF- α Enzyme-Linked Immunosorbent Assay (ELISA) test kits, and the two groups were statistically compared to each other.

Results: Mean serum TNF- α levels were found to be significantly higher in the patient group than in the control group ($p < 0.005$). However, no significant association was observed between TNF- α levels and oral mucosal involvement ($p > 0.005$). No relationship was detected between TNF- α levels and patients' sex.

Conclusion: It is thought that TNF- α , a proinflammatory cytokine, may play an important role in the pathogenesis of lichen planus. TNF- α may be a simple and effective predictor to illustrate the inflammatory status in patients with lichen planus.

Keywords: lichen planus, cytokines, tumor necrosis factor- α (TNF- α)

Received: 16 June 2017 | Returned for modification: 13 October 2017 | Accepted: 10 November 2017

Introduction

Lichen planus is an itchy papulosquamous dermatosis characterized by typical papules located on the body, the oral and genital mucosa, and the flexor regions of the extremities, thus affecting the skin and mucous membranes. Although the etiology of the disease is not completely known, various theories have been put forward in this regard, focusing on endogenous-genetic, immunological, and exogenous-environmental factors (drugs, infection, and psychogenic) (1, 2). Recently, however, T cell-mediated immune response has been shown to play a role in this process. Studies in which monoclonal antibodies are used against T lymphocyte subtypes have also shown that there are often T helper lymphocytes in the dermal infiltrate in early lesions. In addition, it has been shown that there are often CD8(+) cytotoxic T cells infiltrating the epidermis in late lesions. A characteristic of lichen planus is epidermotropism of the lymphocytic infiltration, and so keratinocytes are the target cells (3, 4, 5).

An antigen can cross-react with epidermal cells and transform them into target cells with an effect of viral, oncogenic, or autoimmune reactions (3, 5, 6). Langerhans cells in the infiltrate process the antigen and provide them to T helper lymphocytes. Activated T lymphocytes stimulate other T lymphocytes through secretion of tumor necrosis factor- α (TNF- α), interleukin-2 (IL-2), and interferon- γ (IFN- γ), and they cause cytokine release from keratinocytes (7).

TNF- α is a molecule with 17Kd weight, a polypeptide structure, and anti-tumor immunity. TNF- α is a cytokine that plays an important role in host defense, including immunoregulatory responses implicated in the pathogenesis of many inflammatory and autoimmune diseases. Furthermore, it is a prototype molecule of a family related to the central mediator of acute inflammation (1). TNF- α is primarily released from stimulated monocytes and macrophage cells. Langerhans cells and active keratinocytes are other cellular sources of TNF- α . In the trauma area, it leads to

adhesion of both neutrophil and endothelial cells, and migration of leukocytes.

This study compares serum levels of TNF- α , which is thought to be one of the proinflammatory cytokines that initiate autoimmune cytotoxicity in ethiopathogenesis of lichen planus, between a healthy control group and patients with lichen planus.

Methods

The study included 34 patients that had received a clinical and histopathological diagnosis of lichen planus, were admitted to our dermatology clinic, had active lesions, and had not received topical or systemic corticosteroid and immunosuppressive treatment for at least 3 months prior to the study. The control group was composed of 20 randomly selected healthy subjects. All of the patients were informed about the study and their consent was obtained. Detailed patient histories were recorded. Physical examinations were performed. Whole blood count, sedimentation, and acute phase reactant measurements were carried out for both groups. Patients with autoimmune disease, malignancy, and familial lichen planus, and patients using drugs that may cause lichenoid eruption were excluded from the study. Attention was drawn to the fact that participants did not have upper respiratory tract or other infectious diseases up to 3 weeks prior to the selection of the patient and control groups. Among the 34 patients with lichen planus, 20 were female (58.8%) and 14 were male (41.2%). The ages of the patients ranged from 18 to 82 years. Among the 20 patients in the control group, 12 were female (60%) and eight were male (40%). The ages of the control group ranged from 21 to 52 years. The disease duration of the patient group was between 1 month and 8 years. Lesions were observed on the lower extremities of 23 patients, the upper limbs of 25 patients, the upper body of 24 patients, the oral mucosa of 16 patients, and the genital mucosa of three patients. The examination of the patients was conducted according to the Declaration of Helsinki principles.

¹Department of Dermatology, Ufuk University, Ankara, Turkey. ✉Corresponding author: yesim_akpinar@yahoo.com

Serum levels of TNF- α were assessed using the TNF- α Enzyme-Linked Immunosorbent Assay (ELISA) test (Biosource International, Human TNF- α , Belgium). Blood samples of patients were centrifuged at 3,000 rpm for 5 to 10 min in 10 cc sterile tubes, and then the serum was removed and stored at -20°C until the test day. The Biosource International hTNF- α kit is a solid phase sandwich ELISA method in which the antigen is conjugated with the specific antibody for hTNF- α in the first incubation and the biotin-coated antibody is added after washing. In the second incubation, this antibody was bound to the hTNF- α that was detected in the first incubation. After the removal of the excess secondary antibody, streptavidin-peroxidase was added. The four-layered sandwich was completed after the biotin-coated antibiotic was bound. Substrate solution was added after the third incubation and after removal of the unbound enzymes. The color was obtained after it was bound to the enzyme. The density of the colored product was directly proportional to the concentration of hTNF- α . Then absorbance levels were read at 450 nanometer wavelength and patient samples were evaluated. The results of the control group and the patient group were summarized in a table in terms of picograms/ml (Table 1).

Table 1 | Age, duration, and TNF- α distribution between groups.

	Group 1: lichen planus patients (n = 34)		Group 2: healthy controls (n = 20)		p-value
	M	SD	M	SD	
TNF- α (pg/ml)	64.03	19.78	35.32	13.12	< 0.005
Age (years)	42.85	14.27	35.85	8.41	< 0.005
Duration (months)	10.44	17.09			

Data were reported as mean (M) \pm standard deviation (SD). $p < 0.005$ was considered statistically significant.

Statistical analysis

The Mann-Whitney U analysis test was used to investigate the statistical comparison between groups. This test was used because the number of subjects in the study was small and the individuals in the two groups were different and randomly selected. The data were analyzed with descriptive statistical methods (percentage and mean \pm standard deviation), and statistical significance was defined at $p < 0.005$.

Results

When TNF- α levels were compared between the patients with lichen planus and the healthy control group, a statistically significant difference was observed ($p < 0.005$). TNF- α levels were not statistically different for those with oral mucosal involvement ($p > 0.005$). There was no statistical difference between sexes ($p > 0.005$). When the TNF- α levels of patient and control groups were compared in terms of age, the level of TNF- α was higher in the lichen planus group ($p < 0.005$; Tables 1 and 2).

Table 2 | TNF- α distribution of patients with lichen planus patients by oral mucosal involvement.

	Group 1: lichen planus patients with oral mucosal involvement (n = 16)		Group 2: lichen planus patients without oral mucosal involvement (n = 18)		p-value
	M	SD	M	SD	
TNF- α (pg/ml)	52.29	17.78	68.25	20.99	> 0.005

Data were reported as mean (M) \pm standard deviation (SD). $p < 0.005$ was considered statistically significant.

Discussion

A number of studies have been conducted on the etiopathogenesis of lichen planus and emphasis has been placed on the predominance of cell-mediated autoimmune response and epithelial cytotoxic cell injury. Lichen planus is a dermatosis that involves the local release of cytokines, the retention of lymphocytes, and the death of basal keratinocytes via lymphocyte-mediated immunological mechanisms (2). A late hypersensitive immune reaction in the etiology has been shown to result in a Th1 immune response (Fig. 1). It has been reported that there is an IL-2, IFN- γ , and TNF- α release around the dermal vessels, which allows adhesion molecules and T cells to accumulate (8). The cytokines released from activated T cells accumulate inflammatory cells in the region, and this leads to cell-mediated cytotoxicity and keratinocyte destruction. In this context, it has been shown that TNF- α and IFN- γ are the major cytokines in keratinocyte damage as well as in the action of lymphocytes and other inflammatory cells (8). These two cytokines, together with other cytokines that release locally and systemically, cause liquefaction degeneration in keratinocytes. In epithelial cells, TNF- α is cytotoxic at high concentration and antiproliferative at low concentrations. In prolonged release, it inhibits the proliferation of keratinocytes by the primer cytokine role. TNF- α has a key regulatory effect in the onset and progression of lichen planus (2). Langerhans cell activation is increased, especially in those with oral involvement (9).

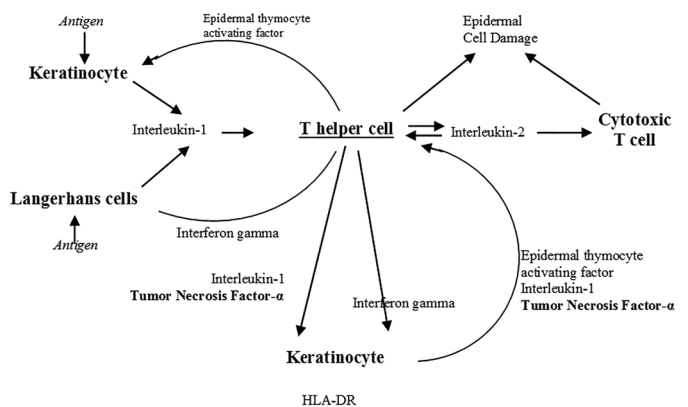


Figure 1 | Immunological theory in lichen planus.

In 1997, Simon et al. conducted a study with 15 patients that had acute eruptive lichen planus, and they examined the soluble form of the TNF- α receptor (STNF-R) in the serum and the expression of TNFRI and TNFRII in the lesion immunohistochemically. According to their results, serum TNFRI is significantly different from the control, and both receptor levels are found to be high in infiltrating lymphocytes. They have indicated that epidermal cells or T lymphocytes correlate with apoptosis in skin lesions of lichen planus (1). Nickoloff et al. demonstrated an *in vitro* synergistic interaction of TNF receptors with IFN- γ in the basal layer. They supported the idea that it leads to apoptosis in lichen planus (9). They also reported that serum TNF-R levels may be markers of activity in lichen planus patients (9). Recent studies have shown that TNF- α production is high in mononuclear cells and keratinocytes when patients with non-lesional or normal oral mucosa and oral lichen planus were compared to each other (10). In a study by Kaur et al. in Korea in 2016, serum and saliva TNF- α concentrations in 54 patients with oral lichen planus were higher than those of the control group. This suggests that saliva and serum

TNF- α levels may be a diagnostic marker for oral involvement that is considered a precancerous lesion, and saliva TNF- α was proposed as a diagnostic marker for oral involvement (11). Karagouni et al. examined TNF- α , IL-2, IFN- γ , IL-6, IL-1 β , and lymphotoxin levels in the serum of 31 patients with oral lichen planus, and they found only TNF- α and IL-6 levels higher in patients compared to the control group (12).

In recent years, studies have focused on the importance of T cell-mediated autoimmune reaction in the pathogenesis of lichen planus. It is also important that TNF- α is a major mediator of inflammation in conjunction with IL-1, thereby inducing T cell activation, apoptosis, and an increase in the expression of adhesion molecules (ICAM-1, UCAM-1, ELAM-1) (12). For this reason, serum TNF- α levels were investigated in this study. The level of TNF- α in the serum of lichen planus patients was measured at 11.7–144 pg/ml (mean 64.03 pg/ml), higher than that of healthy subjects (TNF- α : 13–59 pg/ml, mean = 35.32 pg/ml). In our study, the serum TNF- α levels of the lichen planus patients were significantly higher than the control group. The patient group with oral involvement was not statistically different when compared to the group without oral involvement. Rhodus et al. observed that a significantly higher level of salivary TNF- α was detected in oral lichen planus patients than in normal controls (13). Moreover, Pezelj-Ribaric et al. demonstrated significantly higher amounts of salivary TNF- α in oral lichen planus patients compared to healthy controls (14). However, Pekiner et al. observed no statistically significant difference in serum TNF- α in oral lichen planus between healthy and control groups (15). For this reason, we believe that in those with oral mucosal involvement the release of TNF- α may be more likely to occur when the activity of the disease is increased and thus may be dependent on the phase (9). Moreover, the epithelia from oral lichen planus lesions have been previously shown to produce TNF- α 10- to 20-fold greater than that in keratinocytes from normal gingiva (16). In these studies, the higher levels of TNF- α in saliva compared with those in serum suggest that saliva offers some advantages over serum because it can be collected noninvasively by individuals with modest training, and its analysis has demonstrated values of various biochemical and immunologic parameters comparable to those that are routinely assessed in serum. Therefore, we believed that measuring TNF- α levels in saliva in the active phase and in a larger group of patients with lichen planus with oral mucosal involvement might be meaningful.

When the TNF- α levels of patients and control groups were compared in terms of age, the level of TNF- α was higher in the

lichen planus group. In addition, TNF levels increased with age in both groups. As age increases, the release of other proinflammatory cytokines such as TNF also increases because aging is a biological process characterized by progressive physiological decline. The inflammation theory of aging, also called “inflammaging” (inflammation + aging), proposes a link between immune changes and the increased incidence of age-related diseases. This theory is supported by the observation that serum concentrations of inflammatory mediators are elevated in old age and that these elevations are associated with the pathogenesis of many age-related diseases (17). Serum TNF- α levels can be affected by age, stress, alcohol consumption, smoking, and genetics. These factors cannot be easily matched in both patients with lichen planus and healthy controls. We believe that the study will be more meaningful when the patient and control groups are in the same age range.

A response is obtained in patients with multiple oral lichen planus resistant to systemic steroids and immunosuppressant treatments after using anti-TNF- α antagonist agents (18). Successful treatment with infliximab and adalimumab has been reported in two patients with oral lichen planus (19, 20). Furthermore, cytokine and anticytokine therapies have shown some potential in the treatment of autoimmune diseases. For example, agents directed against TNF- α , infliximab (murine/human chimeric monoclonal antibody against TNF- α), and etanercept (a soluble TNF- α receptor fused to the Fc portion of a human immunoglobulin G1 molecule) are effective in the treatment of chronic disorders such as lichen planus (20). The efficacy of these drugs in treatment has shown the importance of TNF- α in lichen planus.

This was a small prospective study and the number of subjects was low in both groups. We could not assess the levels of TNF- α in saliva because we had no valid standardized laboratory tools that might be able to measure this. Limitations of this study include a lack of uniform matching of age between patients with lichen planus and healthy controls.

Conclusion

We found high serum TNF- α levels in patients with lichen planus, and our results are consistent with the findings of previous studies. Based on these findings, we believe that TNF- α is not solely an intermediate mediator in the pathogenesis of the disease. When oral lichen planus lesions are thought to be precancerous, TNF- α may be an important marker in disease activity and follow-up.

References

1. Freedberg I, Eisen A, Wolff K, Austen KF, Goldsmith LA, Fitzpatrick TB. *Dermatology in general medicine*. 5th ed. New York: McGraw-Hill; 1999.
2. Dominiques R, de Carhalyo GC, Aoki V, Silva Duarte AJ, Sato MN. Activation of myeloid dendritic cells, effector cells and regulatory T cells in lichen planus. *J Transl Med*. 2016;14:171.
3. Boyd AS, Neldner KH. Lichen planus. *J Am Acad Dermatol*. 1991;25:593–619.
4. Black MM. Lichen planus and lichenoid disorders. In: Champion RH, Burtan JL, Burns DA, Breathnach SM, editors. *Textbook of dermatology*. 6th ed. Oxford: Blackwell; 1998. p. 1899–1918.
5. Jin X, Wang J, Zhu L, Wang L, Dan H, Zeng X, Chen Q. Association between-308 G/A polymorphism in TNF- α gene and lichen planus: a meta-analysis. *J Dermatol Sci*. 2012;68:127–34.
6. Chen X, Liu Z, Yue Q. The expression of TNF-alpha and ICAM-1 in lesions of lichen planus and its implication. *J Huazhong Univ Sci Technolog Med Sci*. 2007;27:739–41.
7. Erdem MT, Gulec AI, Kiziltunc A, Yildirim A, Atasoy M. Increased serum level of tumor necrosis factor alpha in lichen planus. *Dermatology*. 2003;207:367–70.
8. Simon M Jr, Gruschwitz MS. In situ expression and serum levels of TNF-alpha receptors in patients with lichen planus. *Acta Derm Venereol*. 1997;77:191–3.
9. Nickoloff BJ, Reusch MK, Bensch K, Karasek MA. Preferential binding of monocytes and Leu+ 2 T lymphocytes to interferon-gamma treated cultured skin endothelial cells and keratinocytes. *Arch Dermatol Res*. 1988;280:235–45.
10. Lu R, Zhang J, Sun W, Du G, Zhou G. Inflammation-related cytokines in oral lichen planus: an overview. *J Oral Pathol Med*. 2015;44:1–14.
11. Kaur J, Jacobs R. Proinflammatory cytokine levels in oral lichen planus, oral leukoplakia and oral submucous fibrosis. *J Korean Assoc Oral Maxillofac Surg*. 2015;41:171.
12. Karagouni EE, Dotsika EN. Alteration in peripheral blood mononuclear cell function and serum cytokines in oral lichen planus. *J Oral Pathol Med*. 1994;23:28–35.

13. Rhodus NL, Cheng B, Myers S, Bowles W, Ho V, Ondrey F. A comparison of the pro-inflammatory, NF-kappaB-dependent cytokines: TNF-alpha, IL-1-alpha, IL-6, and IL-8 in different oral fluids from oral lichen planus patients. *Clin Immunol.* 2005;114:278-83.
14. Pezelj-Ribaric S, Prso IB, Abram M, Glazar I, Brumini G, Simunovic-Soskic M. Salivary levels of tumor necrosis factor-alpha in oral lichen planus. *Mediators Inflamm.* 2004;13:131-3.
15. Pekiner FN, Demirel GY, Borahan MO, Ozbayrak S. Cytokine profiles in serum of patients with oral lichen planus. *Cytokine.* 2012;60:701-6.
16. Yamamoto T, Osaki T, Yoneda K, Ueta E. Cytokine production by keratinocytes and mononuclear infiltrates in oral lichen planus. *J Oral Pathol Med.* 1994;23:309-15.
17. Cruz-Almeida Y, Aguirre M, Sorenson HL, Tighe P, Wallet SM, Riley JL. Age differences in cytokine expression under conditions of health using experimental pain models. *Exp Gerontol.* 2015;72:150-6.
18. O'Neill ID. Off-label use of biologics in the management of inflammatory oral mucosal disease. *J Oral Pathol Med.* 2008;37:575-81.
19. Zhang J, Zhou G, Du GF, Xu XY, Zhou HM. Biologics, an alternative therapeutic approach for lichen planus. *J Oral Pathol Med.* 2011;40:521-4.
20. O'Neill ID, Scully C. Biologics in oral medicine: ulcerative disorders. *Oral Dis.* 2013;19:37-45.