

# We are IntechOpen, the world's leading publisher of Open Access books Built by scientists, for scientists

6,300

Open access books available

170,000

International authors and editors

185M

Downloads

Our authors are among the

154

Countries delivered to

TOP 1%

most cited scientists

12.2%

Contributors from top 500 universities



WEB OF SCIENCE™

Selection of our books indexed in the Book Citation Index  
in Web of Science™ Core Collection (BKCI)

Interested in publishing with us?  
Contact [book.department@intechopen.com](mailto:book.department@intechopen.com)

Numbers displayed above are based on latest data collected.  
For more information visit [www.intechopen.com](http://www.intechopen.com)



# Minimally Invasive Transforaminal Lumbar Interbody Fusion: A Novel Technique and Technology with Case Series

*Mick Perez-Cruet, Ramiro Pérez de la Torre  
and Siddharth Ramanathan*

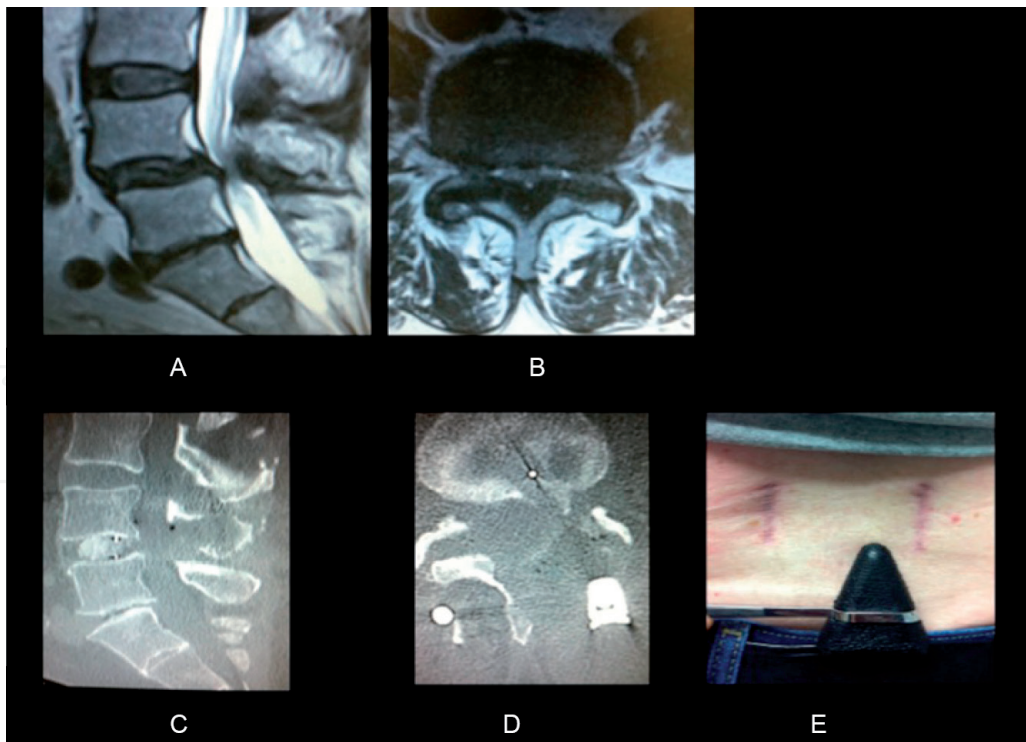
## Abstract

Minimally invasive spine surgery (MIS) transforaminal lumbar interbody fusion (MI-TLIF) has been utilized to treat a variety of spinal disorders. Like other minimally invasive spine surgery techniques and technology, the MI-TLIF approach has the potential to limit the morbidity associated with larger exposures required for open surgery. The MI-TLIF approach has a number of advantages over many other minimally invasive spine surgery approaches including direct decompression of neural elements, collection of morselized autograph from the surgical site to achieve high fusion rates, restoration of spinal canal diameter, foraminal diameter, disk height, and reduction of spondylolisthesis. In this chapter, we discuss a novel technique for performing MI-TLIF developed by the senior author who is a leading minimally invasive spine surgeon. The technique and technology illustrated in this chapter were developed out of a recognition of a need to reduce the learning curve for performing MI-TLIF, as well as need for a cost-effective method that provides a high fusion rate, excellent clinical outcomes, and low complication rate. The indications, surgical planning, postoperative care, complications, and patient outcomes in a large series will be reviewed using this novel MI-TLIF technique.

**Keywords:** minimally invasive spine surgery (MIS), minimally invasive transforaminal lumbar interbody fusion (MI-TLIF), degenerative disk disease, spondylolisthesis, lumbar stenosis, recurrent disk herniation

## 1. Introduction

Over the last two decade, the use of spine instrumentation options has become the standard of care for the treatment of a variety of spinal disorders [1–6]. Lumbar spine surgery indications continue to evolve as more clinical outcomes studies become available [7–10]. Indications include lumbar stenosis, lumbar spondylolisthesis with and without stenosis, degenerative disk disease (DDD), lumbar scoliosis, and recurrent disk herniations. There are a variety of surgical options including open fusion and instrumentation, posterior lumbar interbody fusion (PLIF), minimally invasive transforaminal lumbar interbody fusion (MI-TLIF), oblique lateral interbody fusion (OLIF), abdominal lumbar interbody fusion (ALIF),



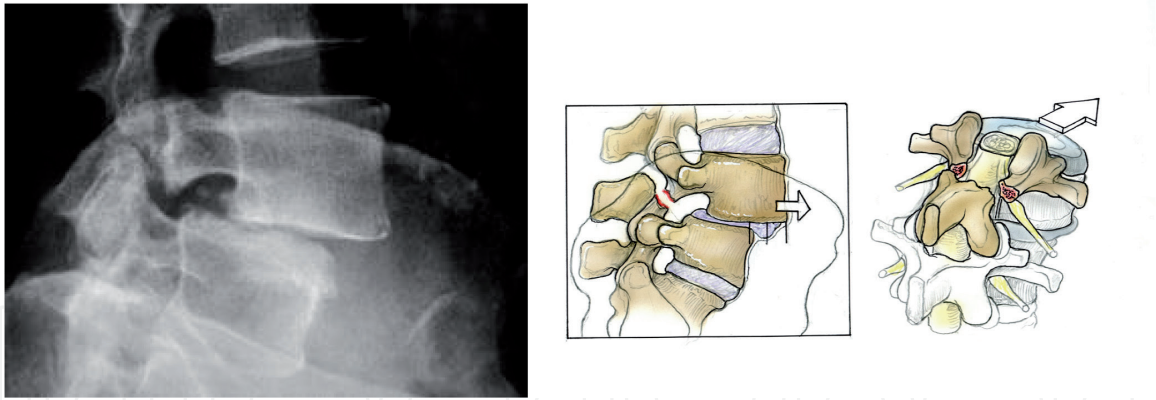
**Figure 1.** Preoperative A. sagittal and B. axial T2-weighted MRI images showing L4–5 grade 1 spondylolisthesis with associated stenosis. Postoperative C. sagittal, D. axial CT, and E. postoperative incision following MI-TLIF approach showing adequate central canal decompression, restoration of disk height, and normal sagittal alignment.

extreme lateral interbody fusion (XLIF), and others. In this chapter, we will review a novel MI-TLIF technique, discuss surgical nuances related to the procedure, and review a large clinical series using this technique and technology.

MI-TLIF is a minimally invasive spine technique that has gained tremendous acceptance in the surgical community. The number of publications utilizing the MI-TLIF technique testifies to its popularity compared with other minimally invasive spine surgery (MIS) fusion techniques [11–13]. The rationale behind the MI-TLIF procedure is the advantage of direct neural decompression, reduced neural retraction during the procedure, and compression of interbody graft material to promote arthrodesis [14–16]. Additionally, the posterior approach permits collection of drilled morselized autograph bone for fusion material, which when placed into the intervertebral disk space promotes arthrodesis (**Figure 1**). Further, the technique and instrumentation that have been developed preserve the disk annulus and contain the injected bone graft material. By placing this bone graft material under load, arthrodesis is promoted according to Wolff’s law. On comparative studies, MI-TLIF was shown to be superior to other techniques in terms of bone fusion rates, complications rates, and biomechanical properties [17–23]. Most of the proponents of this approach support the concept of preserved anatomical structures avoiding instability, while restoring sagittal alignment [24]. Using the same posterior approach, percutaneous pedicle screws can be applied bilaterally which further promotes fusion rates.

## 2. Indications for MI-TLIF

Indications for fusion and instrumentation include degenerative disk disease (DDD), spondylolisthesis with or without stenosis, lumbar stenosis, scoliosis, and instability due to trauma/tumor resection (**Figure 2**) [25].



**Figure 2.**  
*Lateral plain X-ray radiograph and illustration of spondylolysis with pars interarticularis defect.*

There are a number of relative contraindications for selecting this approach including severe osteoporosis, active infection, and uncontrolled bleeding disorders. However, we have found that patients with osteoporosis can be effectively treated using this technique. Obesity was initially a relative contraindication; however, as more clinical outcomes studies, including our series, have become available, this can now be considered as an accepted indication when other techniques are not appropriate [26].

### 3. Surgical procedure

#### 3.1 Preoperative planning

A thorough preoperative patient history and examination is performed. Preoperative radiographic workup includes plain X-rays with AP, lateral, flexion, and extension views. Magnetic resonance imaging (MRI) of the lumbar spine is performed. In reoperation cases or in patients with scoliosis, a computed tomography (CT) myelogram can be helpful in defining bony anatomy, foraminal, and central canal stenosis better. In patients without significant neural compression and relatively preserved disk height, lumbar diskography with post-diskography CT confirming annular tears can be a method to identify the origin of discogenic back pain that can respond favorably to interbody fusion [27].

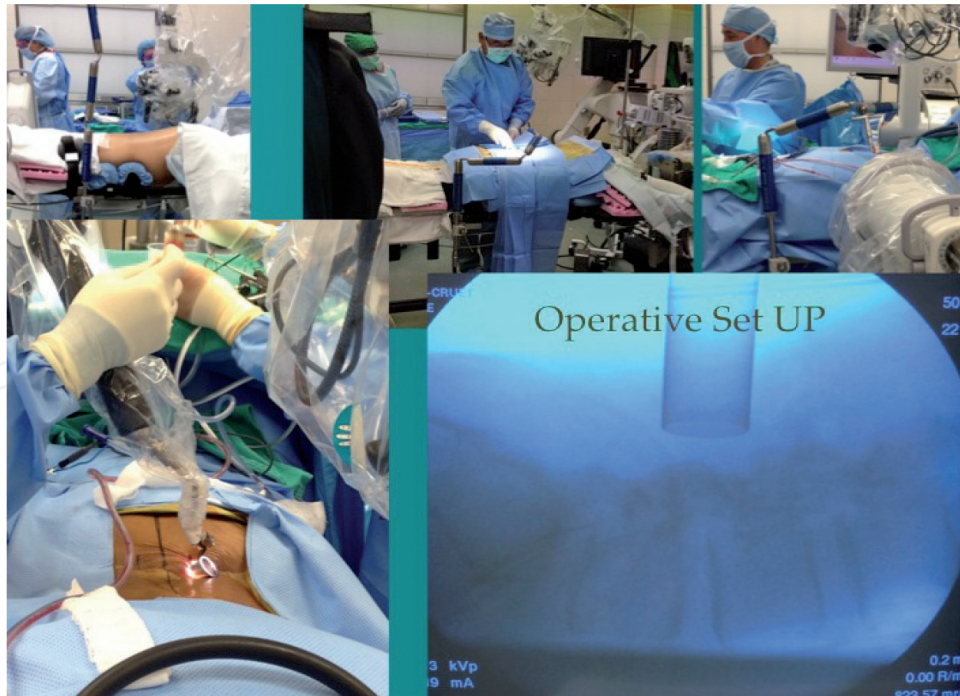#### 3.2 Patient positioning

We prefer general anesthesia with endotracheal intubation for most patients as these cases average 3 hours. Once the patient is intubated, a Foley catheter is placed and the patient is log-rolled onto a Jackson table in the prone position (**Figure 3**). The Jackson table is helpful, because it allows unencumbered fluoroscopic visualization of the spine along with easy removal of the fluoroscopic unit from the surgical field. All pressure points are adequately padded. A time-out is called to confirm surgical level and procedure, proper padding of patient, etc.

#### 3.3 Spinal approach

##### 3.3.1 Incision

The patient is prone-positioned with appropriate padding, prepping, and draping in sterile surgical fashion. The midline is marked to help orient the surgeon. An

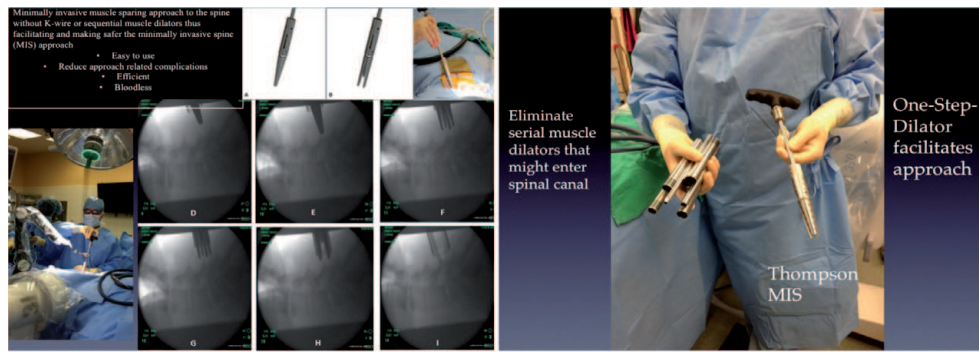


**Figure 3.** Intraoperative images showing patient positioned prone on a Jackson table, fluoroscopic unit in place, and pneumatic arm used to hold the tubular retractor for easy repositioning at the press of a button.

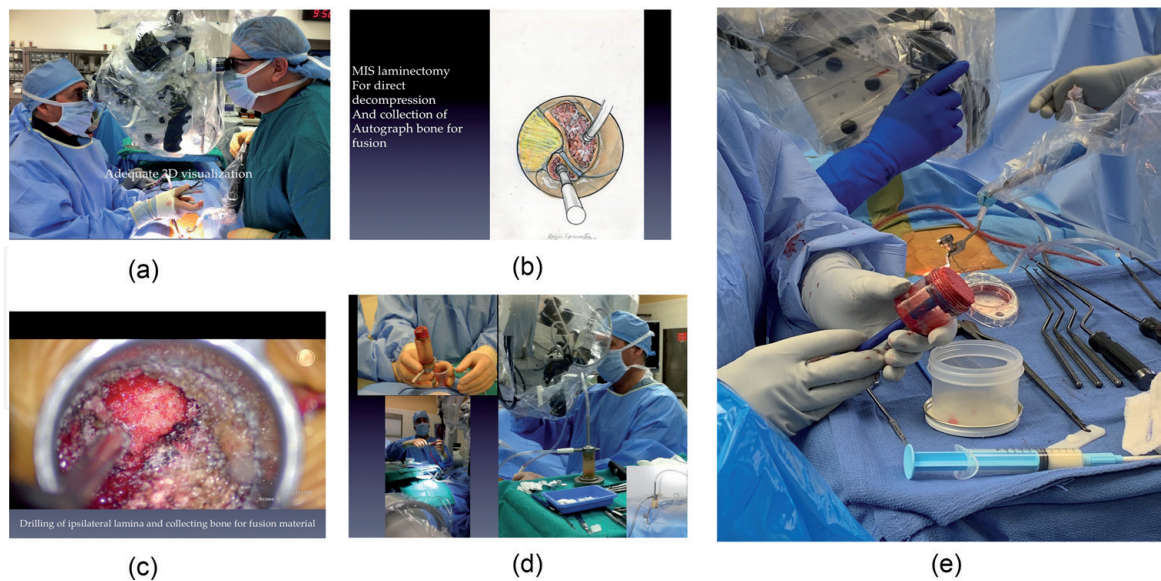
18-gauge spinal needle is used with lateral fluoroscopy to identify the proper level. A 3–3.5 cm incision is made lateral to the midline directly over the disk space in which the MI-TLIF is to be performed. This distance from the midline allows access to the base of the spinous process for adequate minimally invasive laminectomy for direct decompression of the spinal canal. If no decompression is required, the incision is made 3.5 cm distance from the midline. This distance facilitates interbody implant placement within the disk space. After the fascial incision is made parallel to the spinous processes, the one-step-dilator is brought into the operating field (**Figure 4**). With the support of a holder and using fluoroscopic guidance, the dilator is advanced toward the facet in a clockwise fashion. After docking the dilator on the facet, counterclockwise rotation of the handle opens the flanges of the dilator, separating the muscle tissue. A tubular retractor of the appropriate depth is then placed. The procedure is performed under direct microscope visualization through the tubular retractor. The approach is bloodless and obviates the need for K-wires or serial dilation, avoiding the potential complications that can be seen when using these instruments (**Figure 4**).

### 3.3.2 Lumbar exposure and decompression

After positioning the tubular retractor, the microscope is brought into the surgical field. AP and lateral fluoroscopy can be used to ensure proper retractor placement. Soft tissue is excised to the extent of the facet laterally and the ipsilateral lamina medially, and a high-speed drill and M8 cutting burr are used to drill the lamina. All drilled bone is collected using the BoneBac™ Press (Thompson MIS, Salem, NH). This bone is used for fusion material, avoids graft site morbidity, and if needed, can be combined with other biologic material (**Figure 5**). If significant spinal stenosis coexists, a minimally invasive laminectomy is performed allowing circumferential decompression of the spinal canal. We are strong believers that decompression needs to be addressed before percutaneous screws are placed, as most of the surgical steps are done in a logical stepwise fashion.



**Figure 4.**  
 a. Intraoperative images showing the use of one-step-dilator to approach the spine and b. eliminate K-wire and multiple muscle dilators. c. Illustration of the one-step-dilator retractor used to approach the spine in a muscle sparing fashion.



**Figure 5.**  
 a. Intraoperative view showing the use of microscope. b. Illustration, and c. intraoperative photos showing decompression of lamina with high-speed cutting burr and d. collection of drilled morselized bone graft material e. using the BoneBac™ press.

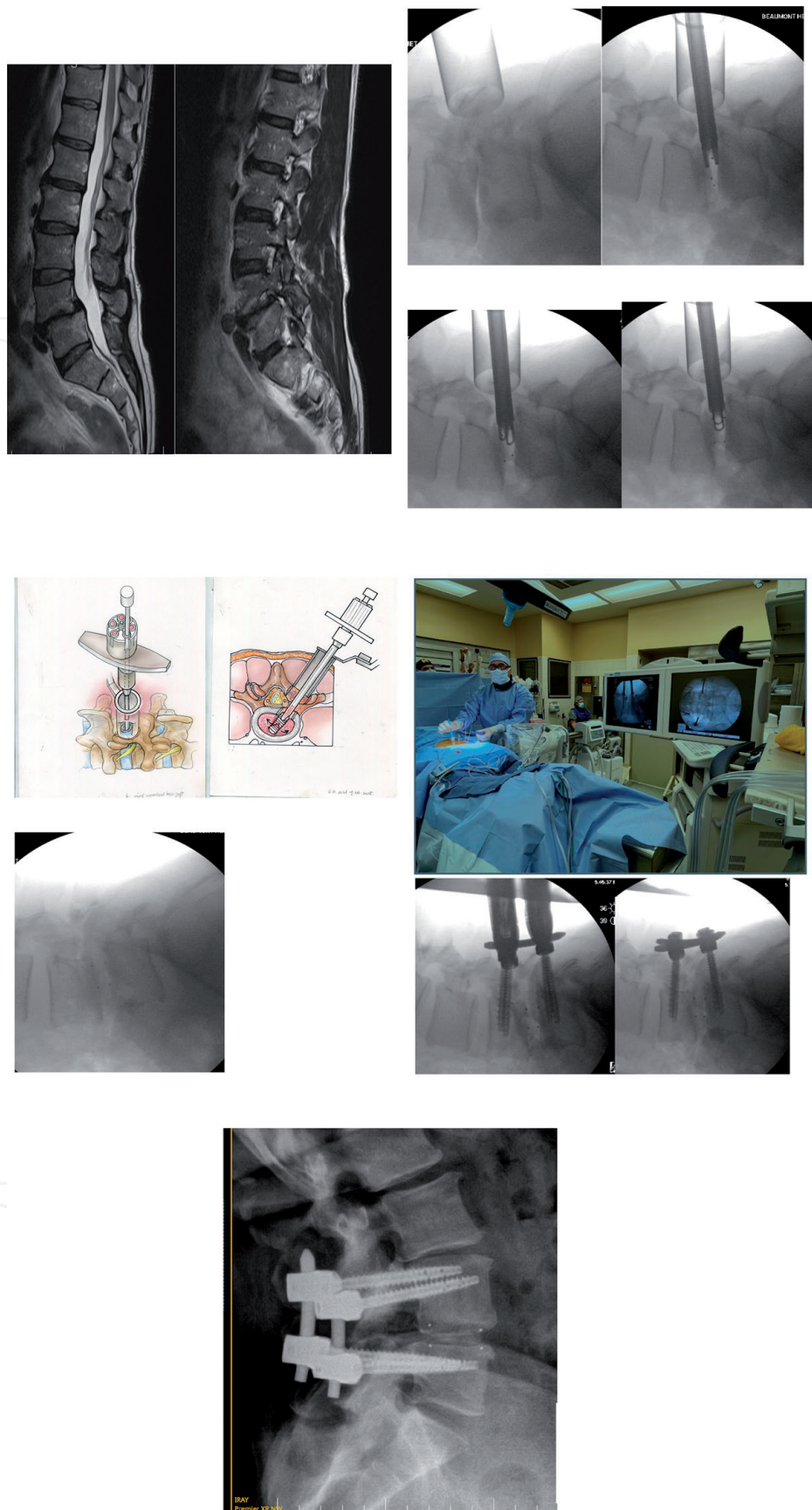
### 3.3.3 Interbody fusion

Upon decompressing the spinal canal, the tubular retractor is repositioned to expose the facet complex. In every case, lateral fluoroscopy is used to confirm the appropriate level. An ipsilateral facetectomy is then completed using a high-speed

cutting burr, and an annulotomy is performed to enter the disk space. A series of disk space reamers, curettes, and rongeurs are used to prepare the disk space and vertebral endplates for interbody arthrodesis. Care must be taken to adequately remove the cartilage endplates to improve interbody arthrodesis. Once preparation of the disk space is completed, the implant is selected based on trials. The most commonly used implant size is 7 mm wide by 11 mm or 12 mm tall and 26 mm in length. This size appears to be appropriate in the majority of cases and provides for adequate disk and foraminal height restoration. In many cases, partial reduction of spondylolisthesis occurs with restoration of the disk height. Lateral fluoroscopic images identify the proper location of the implant within the disk space. Once the implant is within the disk space, the tubular retractor is positioned medially to help seat the implant within the center of the disk space. The relatively small width of the implant design and bulleted nose allows for ease of placement within the interbody disk space. The implant is then rotated 90 degrees thus restoring disk space and foraminal height to 11 or 12 mm, respectively. With the implant properly positioned, BoneBac™ TLIF bullets are filled with morselized autograph bone collected during the procedure using the BoneBac™ Press. The bone is then pushed down the handle of the implant to allow filling of the disk space as the bone is pushed out around the implant and contained by the intact annulus fibrosus of the disk. Typically, 10–12 bullets of drilled morselized autograph are used to completely fill the disk space. This process allows for off-loading of the interbody implant while allowing the compression of the morselized autograph to improve fusion rates via Wolff's law. If more bone graft material is needed, the morselized autograph is mixed with additional bone graft material (i.e. allograft, demineralized bone matrix, etc.). Once the disk space is packed with bone graft, the implant is released and deployed into the disk space. The disk space is inspected with a ball-ended probe under microscope visualization to assure that all bone graft material is within the disk space and that adequate direct neural decompression has been achieved. Additionally, bone graft material can be used to reconstruct the resected facet complex allowing for circumferential bone fusion (**Figure 6**). With complete and adequate hemostasis, the tubular retractor is removed allowing the paraspinal muscles to return to their normal anatomical position. Postoperative CT confirms adequate filling of disk space with morselized autograph.

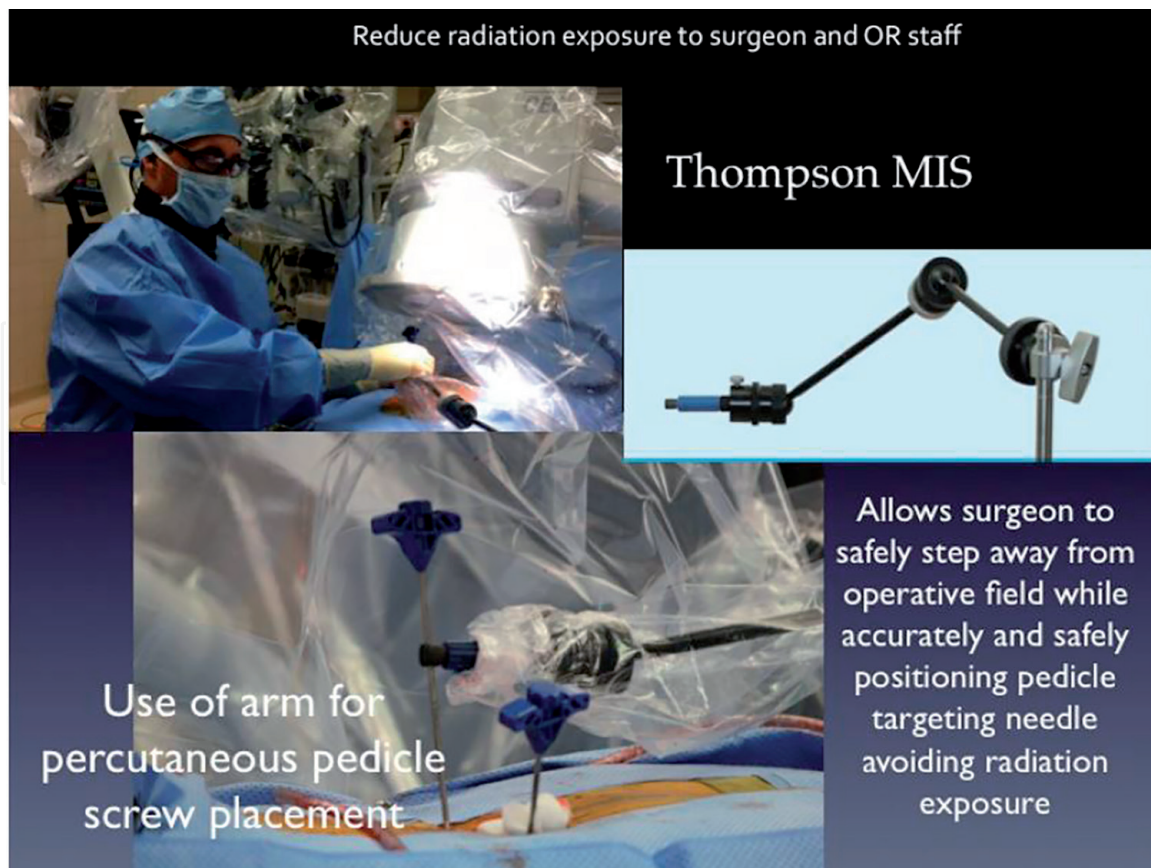
#### *3.3.4 Percutaneous pedicle screw instrumentation*

Upon completion of decompression and interbody fusion, the tubular retractor is removed, and the paraspinal muscles are allowed to return to their normal anatomical position. A contralateral incision is made equidistant from the midline, and AP and lateral fluoroscopy are used to target the pedicles for percutaneous pedicle screw fixation. Alternatively, image-guided robotic navigation can be used for this purpose [28, 29]. To avoid parallax distortion on fluoroscopic imaging, the target vertebrae is centered on the image, the endplate is made as one single line, and the spinous process is oriented between the pedicles. Intraoperative electrophysiologic monitoring with EMG is performed (**Figure 6**). To ensure proper positioning after K-wire and pedicle screw placement, these constructs are stimulated with a probe. Stimulation thresholds less than 8 mAmps necessitate repositioning of K-wire and/or pedicle screw. Typically, percutaneous screws are placed bilaterally and segmentally at each MI-TLIF section to ensure adequate fixation and promote arthrodesis. To reduce radiation exposure, we use the MinRad™ arm (Thompson MIS, Salem, NH) to hold the Jamshidi needle in place. This device also facilitates percutaneous pedicle screw placement by allowing for small adjustments of the pedicle targeting needle, thereby improving pedicle screw placement accuracy (**Figure 7**).



**Figure 6.** Preoperative MRI showing A. midline and B. lateral sagittal images of grade 1 spondylolisthesis with severe foraminal stenosis causing patient's symptoms of debilitating back pain. Intraoperative fluoroscopic images showing C. tubular retractor in place, D. placement of 7 wide PEEK implant into the interbody space, E-F. rotation of the implant to restore disk height to 11 mm, G-H. injection of drilled morselized autograft into the disk space, I. deploying implant into the disk space, J. photo showing intraoperative stimulation of K-wires and percutaneous pedicle screws to assure adequate placement, K-L. reduction of the spondylolisthesis using percutaneous pedicle screw reduction methods, and M. final lateral fluoroscopic image using Thompson MIS BoneBac™ TLIF system. Note restoration of disk height, sagittal alignment, and foraminal and canal diameter.





**Figure 7.**  
*Intraoperative photo and images of MinRad used to hold pedicle access needle for.*

If concomitant vertebral subluxation is present, reduction of the spondylolisthesis is attempted to restore sagittal alignment (**Figure 6**). This technique significantly increases the neural foraminal size and central canal diameter while also ensuring sufficient surface area between adjacent vertebrae for arthrodesis (**Figure 8**).

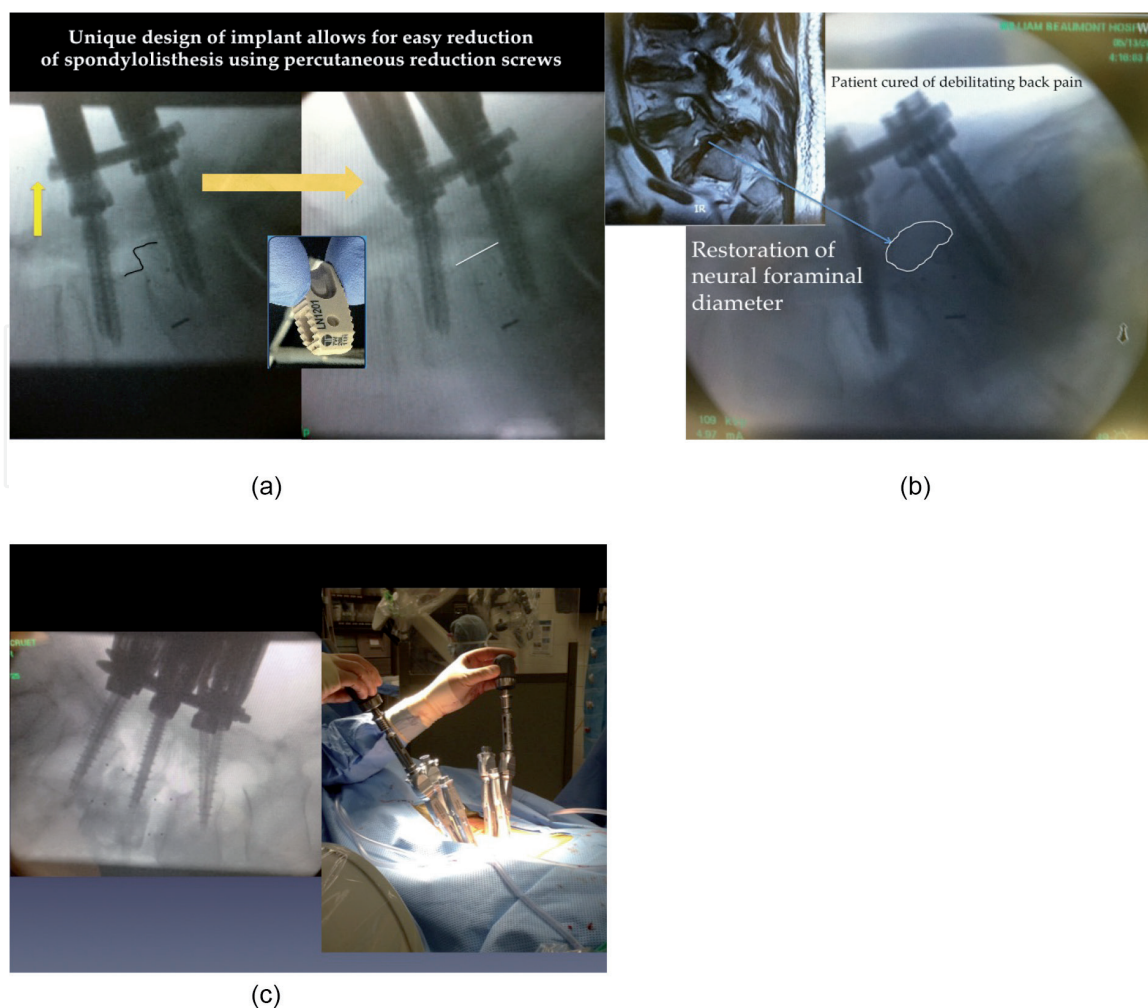
After wound irrigation, a 2–0 vicryl suture is used to close the fascial layer in an interrupted fashion. A subcuticular stitch and skin glue adhesive are used to close the skin. Drainage and wound dressing are generally not required, and the infection rate is negligible. Excellent long-term clinical outcomes using this MI-TLIF technique have been achieved (**Table 1**) [26].

Excellent long-term patient-generated outcome results have been achieved using the MI-TLIF technique described. Source: Quality-of-Life Outcomes With Minimally Invasive Transforaminal Lumbar Interbody Fusion Based on Long-Term Analysis of 304 Consecutive Patients. Mick J. Perez-Cruet, MD, MS, Namath S. Hussain, MD, G. Zachary White, BS, Evan M. Begun, BS, Robert A. Collins, DO, Daniel K. Fahim, MD, Girish K. Hiremath, MD, Fadumo M. Adbi, BS, and Sammy A. Yacob, *SPINE* Volume 39, Number 3, p E191 - E198, 2014.

Adjacent segment disease over a 5-year postoperative period has been approximately 2% compared to 13.6% in traditional open lumbar arthrodesis series [8, 30].

### 3.3.5 Postoperative care

Patients typically stay in the hospital for 2–3 days after surgery and ambulate the day after surgery. Postoperative pain is managed initially with IV and oral pain medications and muscle relaxers as needed. Consultation with physical therapist or occupational therapist is arranged before discharge. Patients are discharged with postoperative care guidelines and follow-up plans. The follow-up is performed at



**Figure 8.**

a. Intraoperative lateral fluoroscopic images using unique design of the BoneBac™ TLIF device to reduce grade 1 spondylolisthesis to grade 0 and thus b. restore foraminal height allowing adequate decompression of the exiting nerve root. c. Reduction of multi-segmental spondylolisthesis with percutaneous reduction screws.

	Baseline	Follow-up time		
		12 mo*	24 mo*	47 mo*
Back pain visual analog scale	7.0 ± 2.4	4.2 ± 3.0 (2.8, 40%)	4.5 ± 3.0 (2.5, 35.7%)	3.5 ± 2.8 (3.5, 50%)
Oswestry Disability Index	43.1 ± 15.7	29.7 ± 18.8 (13.4, 31.1%)	30.2 ± 20.4 (12.9, 29.9%)	28.2 ± 21.7 (14.9, 34.6%)
SF-36 physical component score	30.6 ± 7.8	38.3 ± 11.3 (7.7, 25.2%)	38.1 ± 11.7 (7.5, 24.5%)	39.6 ± 11.7 (9, 29.4%)
SF-36 mental component score	43.8 ± 11.0	48.3 ± 13.0 (4.5, 10.3)	49.7 ± 12.9 (5.9, 13.5%)	49.7 ± 11.2 (5.9, 13.5%)
P		<0.001	<0.001	<0.05

The values are given as the mean and the standard deviation.

SF-36 indicates Short-Form 36. \*Net change and percent improvement from baseline, respectively, are in parenthesis.

**Table 1.**

Long-term results.

2 weeks, 3 month, 6 month, and 1 year from the day of surgery. Patients are advised to wear a LSO brace when ambulating for the first 3 months postoperatively. Outpatient physical therapy is typically started 2 weeks after surgery, and the patient is taught exercise programs to improve core muscle strength and function.

### 3.3.6 Management of complications

Our patients tolerate this MI-TLIF procedure exceptionally well. Potential peri-operative complications include infection, hematoma, hardware malposition or failure, neurological injury, and cerebrospinal fluid leakage. Perioperative antibiotics, meticulous wound closure, and appropriate dressing changes can prevent wound infections. Proper utilization of fluoroscopic imaging and stimulation of K-wires and pedicle screws minimize the risk of instrumentation malposition and nerve root impingement. A small durotomy can be successfully treated with Gelfoam to cover the defect, followed by fibrin glue, followed by meticulous wound closure using a running locking nylon stitch. Complications can be limited by adequate surgical training and critical patient selection. Most postoperative wound infections are superficial and above the fascial plane and can be treated with a week's course of oral antibiotics.

## 4. Clinical series

Using this technique, the following represents our MI-TLIF clinical series comprised 405 consecutive cases. The clinical characteristics are seen in **Table 2**. The average age of patients in the series was 64 years with most being female (60%). Forty-five percent of patients were classified as obese. The primary condition was treated with spondylolisthesis and spinal stenosis most commonly at the L4–5 level with back pain as the primary complaint. High blood pressure, diabetes, and high cholesterol were the most commonly seen co-morbidities.

Parameter	Patient data			
Age (years)	64.1 ± 12.5			
Sex (males:females%)	39.9%: 60.1%			
Symptoms duration	92.3 ± 16.5 months			
<b>BMI categorization</b>				
BMI less than or equal to 30 kg/m <sup>2</sup>	55.8%			
BMI 30.1–34.9 kg/m <sup>2</sup> (Class I Obesity)	22.6%			
BMI 35.0–39.9 kg/m <sup>2</sup> (Class II Obesity)	14.4%			
BMI ≥40.0 kg/m <sup>2</sup> (Class III Obesity)	7.2%			
Diagnosis	Total	L4/L5	L5/S1	L3/L4
Spondylolisthesis	262 (65.1%)	28.03%	20.1%	16.9%
Spinal stenosis	261 (64.7%)	44.7%	11.2%	19.3%
Foraminal stenosis	226 (56.1%)	48.1%	20.3%	16.9%
Degenerative disk disease	95 (23.8%)	11.7%	11.4%	4.9%
Herniated disk	135 (33.5%)	6.9%	5.7%	1.2%
Synovial cyst	18 (4.4%)			
Degenerative scoliosis	149 (36.9%)			
<b>Presenting symptoms</b>				
Back pain	367 (91.1%)			
Neurogenic claudications	165 (40.9%)			
Leg pain	145 (35.9%)			

Parameter	Patient data
Others	80 (19.9%)
Comorbidity	Patient data
Hypertension	95 (23.6%)
Diabetes	62 (15.4%)
High cholesterol	33 (8.9%)
Cardiovascular disease	29 (7.2%)
Smoking	33 (8.9%)
Urinary incontinence	11 (2.7%)
Stroke history	12 (2.9%)
Osteoporosis	8 (1.9%)
Hypothyroidism	41 (10.2%)
Fibromyalgia	10 (2.5%)
Cancer	50 (12.4%)
Rheumatoid arthritis	11 (2.7%)

**Table 2.**  
 Patient characteristics ( $n = 405$ ).

## 5. Minimally invasive TLIF series

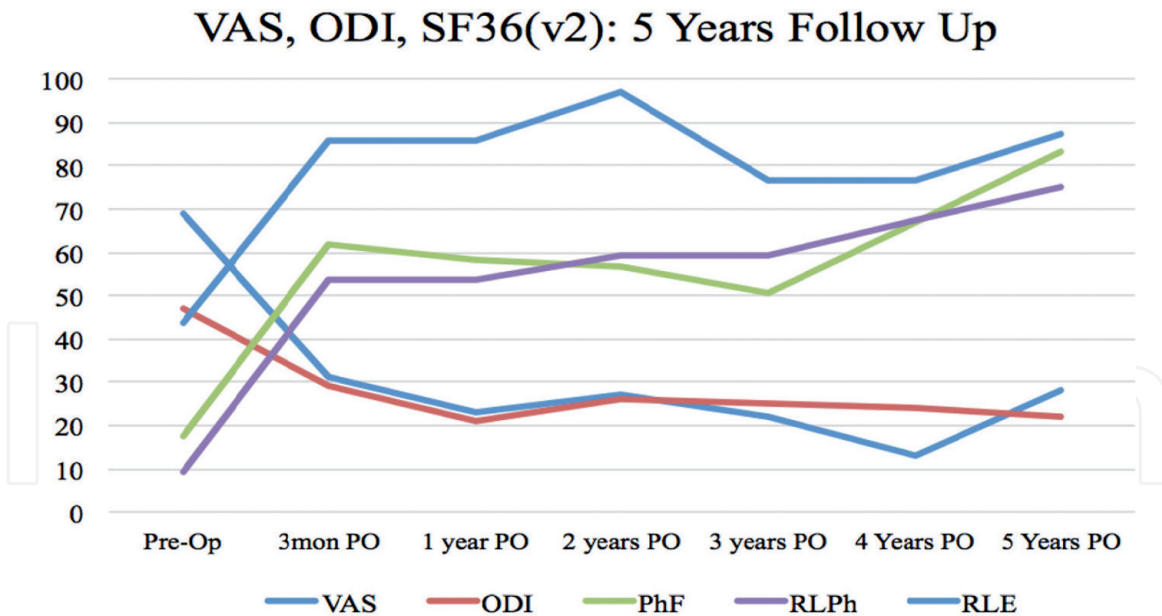
Patients had a significant improvement in visual analog scores (VASs), Oswestry Disability Index (ODI), and Short Form-36 (SF36) over the 5-year follow-up period (**Table 3, Figure 9**).

ODI: Oswestry Disability Index, VAS: visual analog scale, SF: Short Form, PhF: physical function, RLPh: role limitation due to physical health problem, RLE: role limitation due to emotional health problem.

Complication rates in these series were low with cerebrospinal fluid (CSF) leak/dural tear experienced in only 0.5% of patients. Fusion rates based on the Bridwell

Parameter.	Preop	Postop 3 mon	Postop 1 year	Postop 2 years	Postop 3 years	Postop 4 years	Postop 5 years
ODI	45.9 ± 16.4	29.3 ± 19.3	21.9 ± 17.8	25.9 ± 15.6	24.6 ± 18.9	24.7 ± 13.7	22.3 ± 17.6
<i>P</i>		0.0002	0.0001	0.047	0.015	0.008	0.012
VAS	6.9 ± 2.2	3.1 ± 2.2	2.3 ± 1.9	2.7 ± 1.8	2.2 ± 1.4	1.3 ± 1.5	2.8 ± 1.6
<i>P</i>		0.0001	0.0001	0.0082	0.0001	0.0001	0.0026
PhF	17.5 ± 11.9	62 ± 20.3	58.4 ± 26.5	56.8 ± 27.2	50.5 ± 26.7	66.9 ± 18.5	83.3 ± 10.3
<i>P</i>		0.13	0.17	0.03	0.21	0.003	0.003
RLPh	9 ± 10.3	53.7 ± 26.6	53.9 ± 31.7	59.4 ± 30.7	59.4 ± 24.7	67.3 ± 23.4	75 ± 22
<i>P</i>		0.046	0.007	0.002	0.025	0.025	0.026
RLE	43.7 ± 4.1	85.8 ± 19.5	85.9 ± 15.4	96.9 ± 4.2	65.8 ± 31.04	76.65 ± 25.2	87.5 ± 19.5
<i>P</i>		0.019	0.08	0.0002	0.36	0.03	0.03

**Table 3.**  
 VAS, ODI, and SF36 ( $v_2$ ) scores (5-year follow-up).



**Figure 9.** Line graph demonstrating mean VAS of back pain, ODI and SF36 (v2) scores over 5 years follow up time. PhF: Physical function, RLPh: Role limitation due to physical health problem, RLE: Role limitation due to emotional health problem. PO: Post-operative. Op: Operative.

fusion criteria was extremely high with 97% achieving Grade I (**Table 4**). This was felt to be in large part because of the novel method of injecting the patient’s own drilled morselized autograph into the properly prepared disk interspace. With loading of the filled disk space autograph bone material, according to Wolff’s law, very high fusion rates can be achieved.

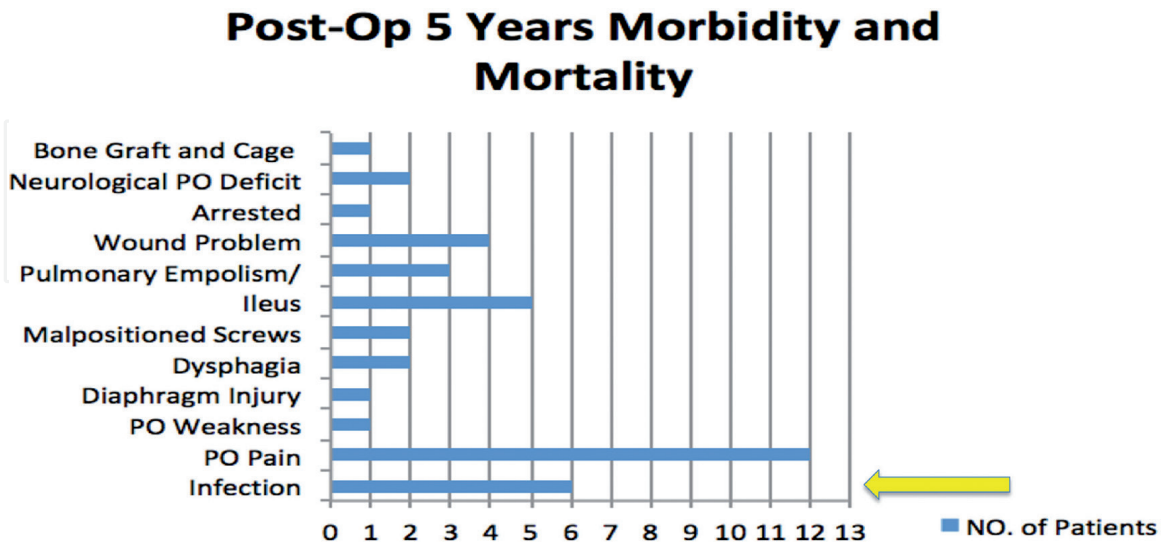
Postoperative complications	Neurological (<3 Months)	Non-neurological (%)
PO pain	2.9%	—
PO weakness	0.3%	—
Neurological PO deficit	0.5	—
Diaphragm injury	—	0.3%
Dysphagia	—	0.5%
Malpositioned screws	—	0.5%
Pulmonary embolism/thrombosis	—	0.7%
Ileus	—	1.2%
Wound problem (infection/hematoma)	0.9%	—
Arrested	—	0.3%
Bone graft and cage	—	0.3%
CSF leak/dural tear	—	0.5%
<b>Postoperative fusion rates<sup>11</sup></b>		
Description	Grades	Percentage
Fusion with remodeling and trabeculae	I	97.3%
Graft intact, not fully remodeled, no radiolucencies	II	1.7%
Graft intact, but a definite lucency	III	1%
Definitely not fused, collapsed	IV	—

PO: postoperative, CSF: cerebrospinal fluid.

**Table 4.** Postoperative complications and fusion rates %, (n = 405).

## 6. Complication rates in minimally invasive TLIF series

Based on monthly recorded morbidity and mortality data, complications rates in this series were extremely low (**Figure 10**).



**Figure 10.**  
*Morbidity and mortality: 5-year follow-up.*

## 7. Conclusion

The novel MI-TLIF approach and technology reviewed in this chapter afford significant short- and long-term improvements for patients suffering from debilitating low back pain. Long-term benefits include a reduced rate of adjacent segment disease requiring reoperation, high rates of fusion, and low complication rates. Clinically, our patients have been extremely satisfied in the treatment of their chronic back pain disorders. The majority of our patients are completely pain-free and have returned to work full time and are able to resume activities of daily living.

### Conflict of interest

Thompson MIS/BoneBac: Stock Ownership, Orthofix: Speaker Bureau, Thieme Publishing Inc.: Royalties.

IntechOpen

## **Author details**

Mick Perez-Cruet<sup>1,2\*</sup>, Ramiro Pérez de la Torre<sup>2</sup> and Siddharth Ramanathan<sup>1</sup>

1 Department of Neurosurgery, Oakland University William Beaumont, School of Medicine, Rochester, MI, United States

2 Department of Neurosurgery, Michigan Head and Spine Institute, Royal Oak, MI, United States

\*Address all correspondence to: perezcruet@yahoo.com

## **IntechOpen**

---

© 2022 The Author(s). Licensee IntechOpen. This chapter is distributed under the terms of the Creative Commons Attribution License (<http://creativecommons.org/licenses/by/3.0>), which permits unrestricted use, distribution, and reproduction in any medium, provided the original work is properly cited. 

## References

- [1] Allain J, Dufour T. Anterior lumbar fusion techniques: ALIF, OLIF, DLIF, LLIF, IXLIF. *Orthopaedics & Traumatology, Surgery & Research*. 2020;**106**(1S):S149-S157
- [2] Patel D, Yoo J, Karmakar S, Lamoutte E, Singh K. Interbody options in lumbar fusion. *Spine Surgery*. 2019;**5**(Suppl. 1):S19-S24
- [3] Choudri T, Mummaneni P, Dhall S, Eck J, Groff M, Ghogawala Z, et al. Guideline update for the performance of fusion procedures for degenerative disease of the lumbar spine. Part 4: Radiographic assessment of fusion status. *Journal of Neurosurgery. Spine*. 2014;**21**(1):23-30
- [4] Babu MA, Coumans JV, Carter BS, Taylor WR, Kasper EM, Roitberg BZ, et al. A review of lumbar spinal instrumentation: Evidence and controversy. *Journal of Neurology, Neurosurgery, and Psychiatry*. 2011;**82**(9):948-951
- [5] Yoshihara H. Surgical options for lumbosacral fusion: Biomechanical stability, advantage, disadvantage and affecting factors in selecting options. *European Journal of Orthopaedic Surgery and Traumatology*. 2014;**24**(Suppl. 1):S73-S82
- [6] Kerolus M, Turel MK, Tan L, Deutsch H. Stand-alone anterior lumbar interbody fusion: Indications, techniques, surgical outcomes and complications. *Expert Review of Medical Devices*. 2016;**13**(12):1127-1136
- [7] de la Torre RA P, Kelkar PS, Beier A, et al. Decompression, transforaminal lumbar interbody fusion, reduction, and percutaneous pedicle screw fixation. In: Perez-Cruet MJ, Beisse RW, Pimenta L, Kim DH, editors. *Minimally Invasive Spine Fusion: Techniques and Operative Nuances*. St. Louis: Quality Medical Publishing; 2011. pp. 345-367
- [8] Perez-Cruet MJ, Hussain NS, White GZ, Begun EM, Collins RA, Fahim DK, et al. Quality-of-life outcomes with minimally invasive Transforaminal lumbar interbody fusion based on long-term analysis of 304 consecutive patients. *Spine*. 2014;**39**(3):E191-E198
- [9] Khechen B, Haws BE, Patel DV, Narain AS, Hijji FY, Guntin JA, et al. Comparison of postoperative outcomes between primary MIS TLIF and MIS TLIF with revision decompression. *Spine (Phila Pa 1976)*. 2019;**44**(2):150-156
- [10] Teng I, Han J, Phan K, Mobbs R. A meta-analysis comparing ALIF, PLIF, TLIF and LLIF. *Journal of Clinical Neuroscience*. 2017;**44**:11-17
- [11] Hammad A, Wirries A, Ardeshiri A, Nikiforov O, Geiger F. Open versus minimally invasive TLIF: Literature review and meta-analysis. *Journal of Orthopaedic Surgery and Research*. 2019;**14**(1):229
- [12] Garg B, Mehta N. Minimally invasive transforaminal lumbar interbody fusion (MI-TLIF): A review of indications, technique, results and complications. *Journal of Clinical Orthopaedics & Trauma*. 2019;**10**(Suppl. 1):S156-S162
- [13] Momin A, Steinmetz M. Evolution of minimally invasive lumbar spine surgery. *World Neurosurgery*. 2020;**140**:622-626
- [14] Mummaneni P, Bisson E, Kerezoudis P, Glassman S, Foley K, Slotkin J, et al. Minimally invasive versus open fusion for grade I degenerative lumbar spondylolisthesis: Analysis of the quality. *Neurosurgical Focus*. 2017;**43**(2):E11 Outcomes Database
- [15] Ghogawala Z, Dziura J, Butler WE, Dai F, Terrin N, Magge SN, et al.



Laminectomy plus fusion versus laminectomy alone for lumbar spondylolisthesis. *The New England Journal of Medicine*. April 14, 2016;**374**(15):1424-1434

[16] Wang B, Hua W, Ke W, Lu S, Li X, Zeng X, et al. Biomechanical evaluation of Transforaminal lumbar interbody fusion and oblique lumbar interbody fusion on the adjacent segment: A finite element analysis. *World Neurosurgery*. 2019;**126**:e819-e824

[17] Villavicencio A, Nurneikiene S, Roeca C, Nelson L, Mason A. Minimally invasive versus open transforaminal lumbar interbody fusion. *Surgical Neurology International*. 2010;**1**:12

[18] Habib A, Smith ZA, Lawton CD, Fessler RG. Minimally invasive transforaminal lumbar interbody fusion: A perspective on current evidence and clinical knowledge. *Minimally Invasive Surgery*. 2012;**2012**:657342

[19] Scheufler KM, Dohmen H, Vougioukas VI. Percutaneous transforaminal lumbar interbody fusion for the treatment of degenerative lumbar instability. *Neurosurgery*. 2007;**60**(4, suppl. 2):203-212

[20] Dhall SS, Wang MY, Mummaneni PV. Clinical and radiographic comparison of mini-open transforaminal lumbar interbody fusion with open transforaminal lumbar interbody fusion in 42 patients with long-term follow-up: Clinical article. *Journal of Neurosurgery: Spine*. 2008;**9**(6):560-565

[21] Peng CWB, Yue WM, Poh SY, Yeo W, Tan SB. Clinical and radiological outcomes of minimally invasive versus open transforaminal lumbar interbody fusion. *Spine*. 2009;**34**(13):1385-1389

[22] Schizas C, Tzinieris N, Tziridis E, Kosmopoulos V. Minimally invasive versus open transforaminal lumbar

interbody fusion: Evaluating initial experience. *International Orthopaedics*. 2009;**33**(6):1683-1688

[23] Wang J, Zhou Y, Zhang ZF, Li CQ, Zheng WJ, Liu J. Comparison of one-level minimally invasive and open transforaminal lumbar interbody fusion in degenerative and isthmic spondylolisthesis grades 1 and 2. *European Spine Journal*. 2010;**19**(10):1780-1784

[24] Champagne P, Walsh C, Diabira J, Plante M, Wang Z, Boubez G, et al. Sagittal balance correction following lumbar interbody fusion: A comparison of the three approaches. *Asian Spine Journal*. 2019;**13**(3):450-458

[25] Mobbs R, Phan K, Malham G, Seex K, Rao P. Lumbar interbody fusion: Techniques, indications and comparison of interbody fusion options including PLIF, TLIF, MI-TLIF, OLIF/ATP, LLIF and ALIF. *Journal of Spine Surgery*. 2015;**1**(1):2-18

[26] Terman SW, Yee TJ, Lau D, Khan AA, La Marca F, Park P. Minimally invasive versus open transforaminal lumbar interbody fusion: Comparison of clinical outcomes among obese patients. *Journal of Neurosurgery Spine*. June 2014;**20**(6):644-652. DOI: 10.3171/2014.2.SPINE13794. [Epub Apr 18, 2014]

[27] Xi MA, Tong HC, Fahim DK, Perez-Cruet M. Using provocative discography and computed tomography to select patients with refractory discogenic low back pain for lumbar fusion surgery. *Cureus*. Feb 27, 2016;**8**(2):e514

[28] Staub BN, Sadrameli SS. The use of robotics in minimally invasive spine surgery. *Journal of Spine Surgery*. 2019;**5**(Suppl. 1):S31-S40

[29] Vo CD, Jiang B, Azad TD, Crawford NR, Bydon A. Theodore N robotic spine surgery: Current state in

minimally invasive surgery. *Global Spine Journal*. 2020;**10**(Suppl. 2): 34S-40S

[30] Sears WR, Sergides IG, Kazemi N, Smith M, White GJ, Osburg B. Incidence and prevalence of surgery at segments adjacent to a previous posterior lumbar arthrodesis. *The Spine Journal*. 2011;**11**:11-20

IntechOpen

IntechOpen