

ASPECTS OF INTRA-OPERATIVE INACTIVATION AND METHODS OF SURGICAL RESOLUTION OF RESIDUAL CAVITIES IN PULMONARY HYDATID CYST IN CHILDREN

Babuci S.,^{1,2} Petrovici V.,^{1,2} Dogotari N.,² Malanco S.,² Pasicovschi T.^{1,2}

¹ Public Institution State University of Medicine and Pharmacy "Nicolae Testemițanu",

² PMSI Mother and Child Institute, Chisinau, Republic of Moldova

ABSTRACT

The study includes a complex analysis of clinical, imaging, morpho-pathological and laboratory observations, as well as the results of the medical and surgical treatment of 150 patients, aged 3-17 years, with pulmonary hydatidosis, of which 135 with primary hydatidosis and 15 with recurrent hydatidosis.

Thus, the results of this study allow us to conclude that intraoperative use of 2% silver nitrate solution allows effective antiparasitic inactivation of hydatid larval cyst elements and adequate disinfection of residual cavities, which contributes to a significant reduction in the incidence of recurrent cases and postoperative septic complications. The residual cavity capitonnage with intraoperative filling using "LitAr" preparation represents an optimal way of resolving residual cavities in major hydatid cyst with the presence of bronchial fistulas and in hydatid cyst complicated with rupture, ensuring fast postoperative re-expansion of the restant parenchyma, it being superior to pneumonostomy.

Key words: *hydatid cyst, lung, children, treatment*

INTRODUCTION

Hydatid disease is a cyclozoonotic parasitic disease caused by the larval form of *Echinococcus granulosus*, quite rarely encountered in Western countries and considered endemic, with major public health problems in several regions of the globe [1, 4, 53], including the Republic of Moldova [30, 48]. Although parasitic cystic lesions are most commonly found in the liver (54.2-70%) and lungs (20-33.3%), the hydatid metacestode may involve any tissue and organ including: muscles (5%), bones (%), kidneys (2%), heart (1%), pancreas (1%), central nervous system (1%), spleen (1%) etc. [20, 27]. Some authors consider that in children, compared to adults, the lungs are most affected; the incidence of lung forms being about 68%, giant or multiple hydatid cysts are not a rarity [7, 17, 33].

At present, chemotherapeutic preparations for the conservative treatment of hydatidosis are available, such as benzimidazole derivatives (albendazole, mebendazole) or their combination with pyrazinoisoquinoline derivatives, but no conclusive evidence of their curative efficacy exists [6, 37]. Moreover, a harmful action of these preparations on vital organs [26] has been recorded. In this context, surgical intervention is the treatment of choice of the hydatid cyst of various localization. It requires to unconditionally comply with some important principles that significantly influence the evolution and the disease treatment [23], among which: cyst evacuation with complete removal of parasitic larval cyst elements, deworming and avoiding the intra-operative contamination and the residual cavity resolution [8, 43, 46]. Despite the multitude of technical precau-

tions and the diversity of protoscolicide substances, the intraoperative contamination with hydatid larval cyst content is quite common, causing 10% of postoperative recurrences [43]. The optimal way of the residual cavity resolution in both the lung and liver hydatid cyst, the attitude towards pericystic parenchyma, especially in complicated and recurrent forms of the disease, are contradictory. Although various surgical, conservative and radical techniques are proposed [16, 45, 52], the rate of postoperative morbidity in hydatid disease is still high, ranging between 12.5% and 25%, with one or more associated complications [35, 52].

The objective of the study was to carry out a comparative evaluation of the *in vitro* and *in vivo* protoscolicidal effect of some chemical compounds, such as 0.5%, 1% and 2% silver nitrate, as an attempt to intra-operatively inactivate the hydatid larval cyst, and to elucidate some surgical technique peculiarities in the postechinococcectomic residual cavities resolution.

MATERIAL AND METHODS

The study includes a complex analysis of clinical, imaging, morpho-pathological and laboratory observations, as well as the results of the medical and surgical treatment of 150 patients, aged 3-17 years, with pulmonary hydatidosis, of which 135 with primary hydatidosis and 15 with recurrent hydatidosis.

The elements of hydatid cyst and daughter-vesicles served as material for the experimental study, obtained through the puncture of hydatid metacestode (without any parasiticide treatment), as well as parasitic larval cyst totally removed (laminar cuticle

together with the proligerous membrane, obtained after pericystectomy). The native material, collected intra-operatively, was subjected to the histopathological study, recording on the video camera without any additional coloring methods. In addition to silver nitrate, we also used other scolicide agents: 10% and 20% hypertonic saline solution, 95% alcohol, 2% mebendazole suspension, 3% hydrogen peroxide, 10% iodopovidone.

The following morphopathological changes were taken into consideration when analyzing the effectiveness of the scolicide agent: the degree of the chemical agent penetration into the tissues of the germ elements; the disappearance of their active movements; the intensity of their coloring (from brown to black); the presence of objective signs of damage to the structure of the wall and organs of the germ elements; chaotic distribution of hooks. The duration of exposure of the parasiticide solutions used in hydatidosis was 1, 2, 5, 10, 15, 20 and 30 min, respectively (table 1). In order to document the results obtained, a microscope video camera was used.

The topographic study of pulmonary hydatidosis showed that in 77 (51.3%) cases the right lung was affected, in 54 (36%) cases – the left lung was affected, and in 19 (12.7%) both. Concomitant lung and liver involvement was found in 26 children (17.3%), of which: right lung + liver involvement - 11, left lung + liver involvement - 8, bilateral lung hydatid cyst + liver – 5 cases. In 2 children, some poly-organic forms were found with concomitant damage to the lungs, liver, spleen, brain, and kidneys. In 64% of cases, large and giant cystic formations (the volume of the parasitic larval cyst exceeded 500 ml) were diagnosed, affecting mainly the right lung - 31 cases, the left lung - 18 cases; the lungs and the liver being simultaneously involved in 15 children. Of the total number of patients, in 19 (12.7%) some clinical-evolutionary forms were found which were complicated with: infected lung hydatid cyst - 4 cases; hydatid cyst rupture in bronchus - 11; simultaneous rupture of hydatid cyst in bronchus and pleural cavity - 4. The distribution of patients by age showed the predominance of children aged 7-14 years both in the group of boys (51, 69%) and girls (60.66%). The analysis of the distribution of patients by sex showed that 59.3% were male and 40.7% female.

Diagnostic imaging methods included chest X-ray, computed tomography with and without reconstruction, pulmonary perfusion scintigraphy, hepatic scintigraphy, ultrasound of the lungs and abdominal organs.

The anesthesiology of patients in the study group was performed with the Drager Fabius plus anesthesia workstation, the Infiniti Vista XL multi-function monitor, the Scio Four Oxi plus gas analyzer. Rapid induction was performed with Sevoflurane through the facial mask. Catheterization of two and more peripheral veins was performed, the central

vein catheterization being abandoned. For premedication, the intravenous administration of Atropine sulphate solution with Diazepam solution was used. Opiates (Fentanyl), myoplegia with Atracurium or Pipecuronium bromide were used for basic anaesthesia.

After 100% oxygen preventive hyperventilation, tracheal intubation was carried out, assisted breathing being performed with the apparatus in pressure-controlled ventilation mode, peak inspiratory pressure - 20 mm col. (max. 30-40 mm col. of water), positive end expiratory pressure - 5-10 mm col. of water. Subsequently, Isoflurane (minimum alveolar concentration <1) was infused, which had a lower influence on pulmonary hypoxic vasoconstriction. In the unipulmonary intubation, a bronchial tube with lumen with or without a cuff was used, depending on the child's age and airway dimensions.

In the unipulmonary intubation, assisted mechanical and manual ventilations proved to be useful, depending on the surgery stage, with the temporary arrest of short-term breathing in the inspiration or expiration phase. Under the control of the monitoring indices (FIO₂, SaO₂, ETCO₂) the optimal ventilation regime was established by changing the respiratory volume and respiratory rate.

RESULTS

The results of the experimental study show that the sensitivity of the germ elements to the scolicide solutions used (table 1) depends, to a large extent, on the clinical-evolutionary stages of the parasitic disease and the degree of maturation of the germ elements: the "younger" they are, the more sensitive to the scolicide agents they are, therefore the metascolex (a degenerative form of protoscolex) was significantly more sensitive compared to orthoscolex.

The germ elements in the daughter vesicles of the maternal membrane are well protected and, therefore, resistant to the action of scolicide solutions as compared to free protoscolex.

According to the final results of the "in vitro" study, 10% and 20% hypertonic saline solutions, 2% mebendazole, 3% oxygen peroxide have shown to be less effective in inactivating hydatid germ elements even at an exposure of 15-20 minutes. Higher inactivation possibilities included 96% alcohol and 10% povidone iodine. Some higher comparative results were recorded when using silver nitrate. Thus, signs of the germ elements inactivation were observed within the first 5-7 minutes after using this preparation in 1% concentration, while 2% concentration was effective even within the first 2 minutes after administration.

The results of the action of 1-2% silver nitrate on the structural elements of the parasitic larval cyst and the fibrous capsule in the lung hydatid cyst in children presented a major interest. Chitin and fibrous capsule fragments, treated with this substance, were

subjected to the morphopathological study (63 cases). After treating the fibrous capsule with 1% and 2% silver nitrate, some variable structural degenerative changes were observed, strictly depending on the solution concentration and the exposure period. Under the action of 1% silver nitrate for 1.5-2 minutes, there was a moderate decomplexation of the syncytium structure of the proligerous membrane with marked syncytium imbibition and pronounced argentophilia, as well as the syncytium cell adhesion to the ratatinated pseudoglobulins.

Table 1. Efficacy of parasitocidal solutions depending on the duration of the exposure

| No. | Preparation used | No. of test | Duration of exposure | Scolicide effect |
|-----|-----------------------------------|-------------|----------------------|------------------|
| 1. | NaCl 10 % | 30 | 15-20 min | Absent |
| 2. | NaCl 20 % | 30 | 15-20 min | + |
| 3. | Ethanol 96 % | 30 | 15-20 min | ++ |
| 4. | Mebendazole Susp. 2 % | 30 | 15-20 min | Absent |
| 5. | H ₂ O ₂ 3 % | 30 | 15-20 min | + |
| 6. | Povidone iodine 10 % | 30 | 10-15 min | + |
| 7. | Povidone iodine 10 % | 30 | 25-30 min | ++ |
| 8. | Silver nitrate 0,25 % | 30 | 15-20 min | + |
| 9. | Silver nitrate 0,5 % | 30 | 15-20 min | + |
| 10. | Silver nitrate 1 % | 30 | 5-7 min | ++ |
| 11. | Silver nitrate 2 % | 30 | 1-1,5 min | ++ |
| 12. | Silver nitrate 2 % | 30 | 2-2,5 min | +++ |

At an exposure for 4-5 min. of the preparation, there was recorded the complete decomplexation of the proligerous membrane, with the necrotic degeneration of the proligerous syncytium and the reticular net, its ejection, with denaturation and coagulation processes, the lamellar tunica having a marbled appearance.

At 2 % silver nitrate exposure for 2 minutes there was determined a more active degeneration in the proligerous membrane, manifested by total or sub-total necrosis, with mild argentophilia, rendering it a granular appearance. The action of 1% and 2% silver nitrate for 2-3 minutes causes major denaturation and coagulation with total disintegration of the parasitic elements (fig. 1). At the fibrous capsule level, the preparation soaks in its superficial layers, forming a strict demarcation area between the layer of eosinophilic necrosis and granulation. Within these

limits there is a dystrophy of the connective fibers, in some places their disjunction being observed, followed by aseptic necrosis. After 3-5 minutes, the swelling of cytoplasmic fibroblasts is observed, sometimes seconded by a micro-vacuolation, the nuclei being ratatinated. The fibroblasts on the area adjacent to silver nitrate action became more succulent. A more advanced and deeper aseptic necrosis was determined at an exposure for 5-7 minutes, in some cases reaching the fibrovascular layer. In some sectors the penetration of the preparation into the adjacent lung parenchyma was observed. As a rule, the pericyclic bronchial net remains intact, except the bronchi that open up into the residual cavity.

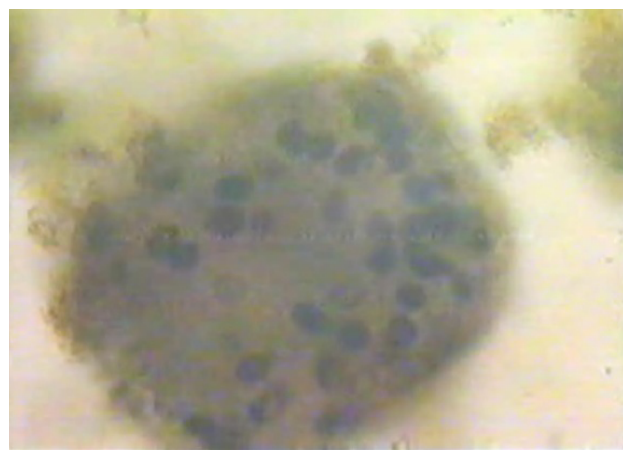
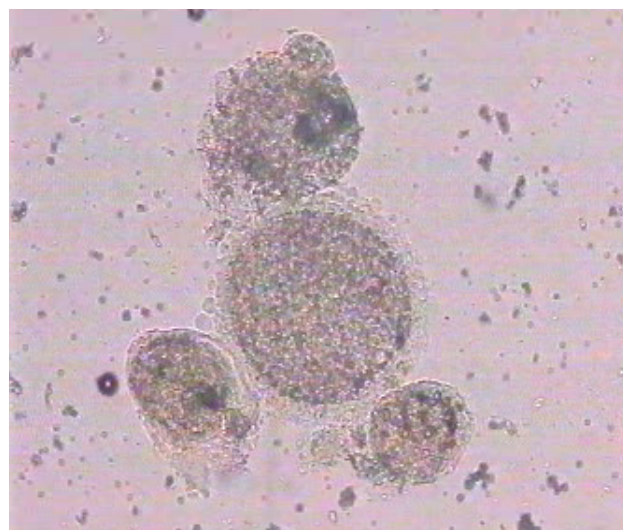

Fig. 1. Microscopic aspect of protoscolex treated with 2% silver nitrate

The results obtained show that 2% silver nitrate has marked necrotic action and it can be used in pulmonary hydatidosis as an elective substance in the intraoperative inactivation of the hydatid larval cyst. The scolicide and bactericidal action of 2% silver nitrate, along with its necrolytic action, provides favorable conditions for both the obliteration of the postechinococcoectomy residual cavity and for the prophylaxis of relapses and postoperative complica-

tions. Administration of this preparation reduces the risk of parasite germ elements dissemination, as well as intra- and post-operative complications, relapses. The choice of appropriate anesthesiological assistance in surgical interventions in lung hydatid cyst in children has been made according to factors that influence the pulmonary ventilation/perfusion ratio and increase the risk of developing hypoxaemia, including: lateral position of the patient, pneumothorax, in some cases the need for one-lung intubation, etc. To prevent the development of atelectasis and obturation of the intubation tube with blood clots and biological fluids, assisted pulmonary ventilation was performed under permanent positive pressure conditions at expiration. Only patients with adequate self-respiration were extubated, as well as cough reflex being restored and satisfactory muscular tonus being present due to restored consciousness.

Surgical techniques were applied and managed according to the topography and dimensions of the hydatid cyst. They included:

- pulmonary echinococectomy+Delbet capitonnage of the residual cavity - 33 cases;
- echinococectomy + residual cavity capitonnage with suture application in overleveled bursae with absorbable wire "to-and-fro" - 56 cases;
- echinococectomy + residual cavity capitonnage with suture application in overleveled bursae with absorbable wire "to-and-fro" with application of "LitAr" material - 44 cases;
- echinococectomy + pneumonostomy - 18 cases;
- economical marginal cyst-pericystectomy resections (12 cases);

The predominant use of echinococectomy with the residual cavity resolution by application of sutures in overleveled bursae with absorbable wire "to-and-fro" was imposed by some negative moments that develop after the Delbet capitonnage of the residual cavity. All the dehiscences of the capitonnage sutures observed in the study group in children with uncomplicated lung hydatid cyst (3 patients) occurred when using this method, the persistence of residual spaces being found in 11 cases.

Difficulties in resolving residual cavities also occur in the case of overleveled "to and fro" capitonnage, especially in large cystic formations and deep intrapulmonary formations. In these cases, there is a real risk of developing pulmonary collapse caused by persistent air leakage from secondary bronchial fistulas (2 cases), residual cavity infection (1 case), long persistence of residual spaces in major cysts (4 cases) (fig. 2). In view of these inconveniences, the method was completed using "LitAr" plastic material, the process being particularly useful in these cases.

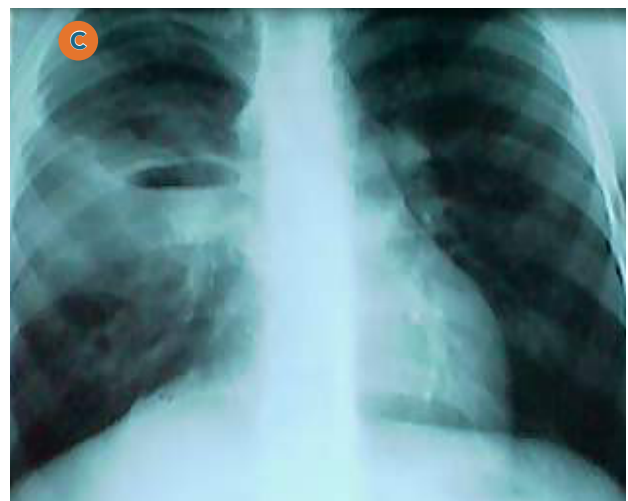
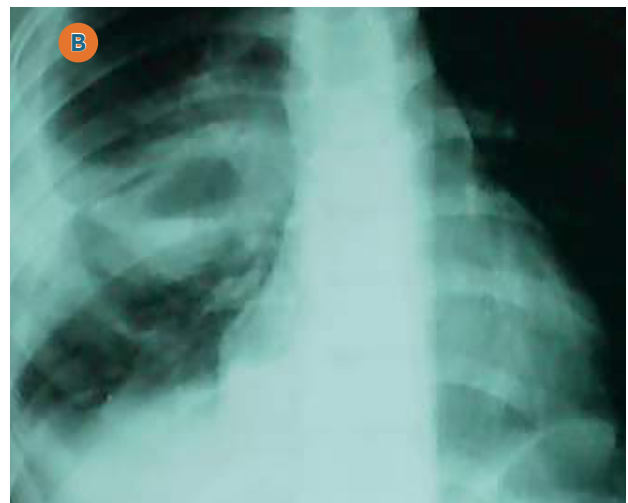
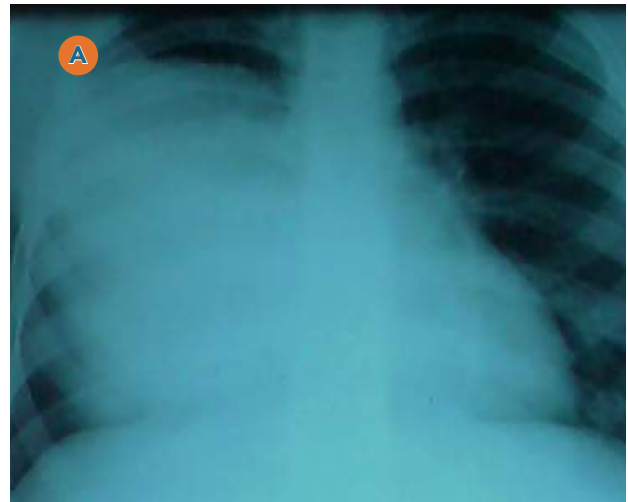


Fig. 2. Patient V, 13 years old. Preoperative chest X-ray (A) - giant pulmonary hydatid cyst of the right lung; the presence of residual spaces after capitonnage at discharge (B) and 30 days post-operatively (C)

Some serious problems in resolving residual cavities occur in complicated hydatid cyst, these patients being hospitalized late. Morphopathological investigations have confirmed that the capitonnage of the residual cavities in these cases may be a fail-

ure due to the presence of marked inflammatory-destructive phenomena of the fibrous capsule layers and pericystic pulmonary tissue. In major cysts and in forms complicated with rupture, resolved by suturing fistulas with external drainage of the residual cavity (cystostomy) and the pleural cavity, significant postoperative morbidity was determined due to long persistence of the residual cavity (30 - 112 days) (fig. 3, 4), aerostatic disorders (12 cases), and the development of serious complications manifested by the destructive pleuro-pulmonary process (3 cases), postoperative suppurative pleurisy (2 cases), compressive pneumothorax (6 cases) (fig. 5).

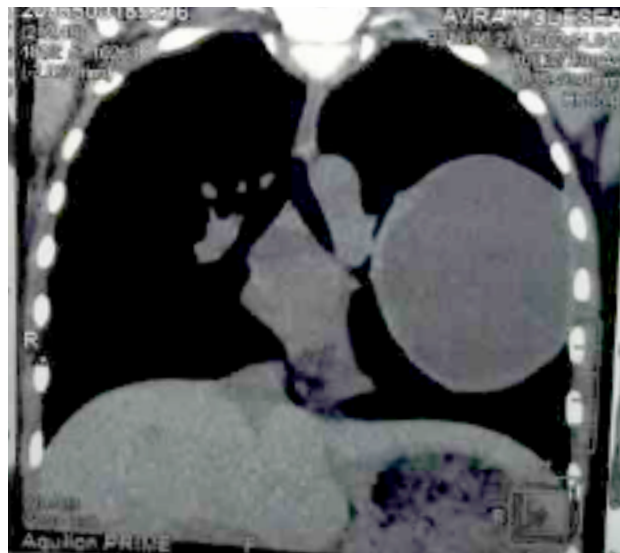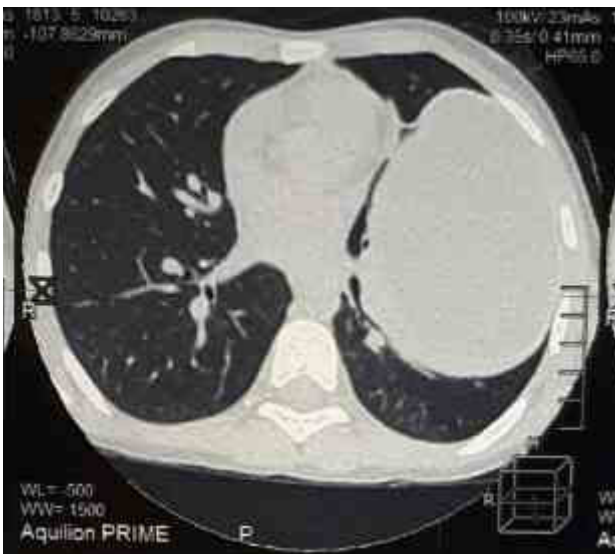


Fig. 3. Patient A., 10 years. Preoperative computed tomography. Hydatid cyst in the lower lobe of the left lung

To fill the residual cavity subjected to capitonnage, we used plastic material "LitAr" (42 cases) which is a collagen preparation with hydroxyapatite. The preparation was applied concurrently with the capitonnage of residual cavities, filling 2/3 of the volume of these spaces. The use of this plastic material allowed to obtain stable aerostasis and haemo-

stasis in the postechinococcectomic residual cavity in most cases (fig. 7), except 2 patients with infected hydatid larval cyst complicated with rupture in which only the observed fistula was sutured and filled, the residual cavities being drained. According to the results obtained, this method is not sufficient for a stable aerostasis, so it was subsequently abandoned.

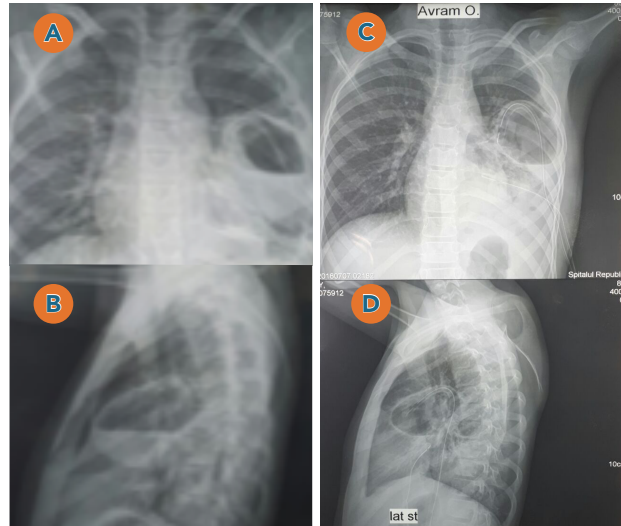


Fig. 4. Patient A., 10 years. A – chest X-ray performed on the 3rd postoperative day: the presence of the residual cavity with fluid drained out (A, B), which is maintained on the 38th day after surgery (C, D)

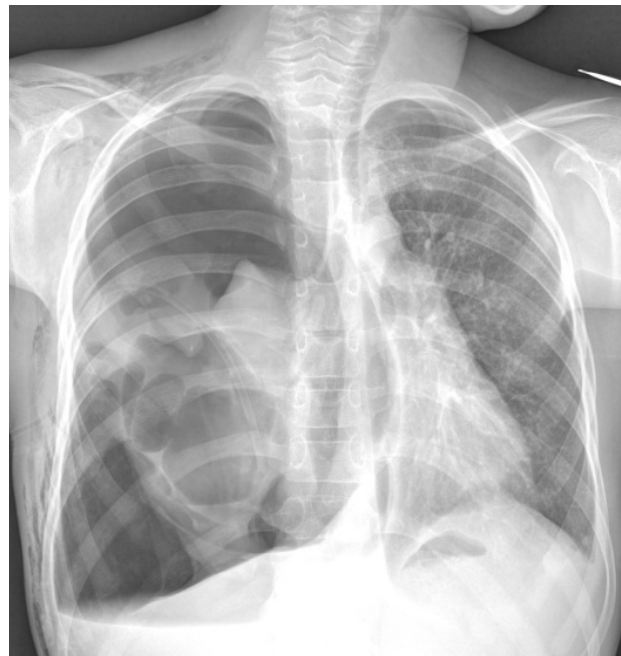

Fig. 5. Patient L., 10 years. Postoperative chest X-ray performed 6 days after surgery. Compressive pneumothorax on the right with the residual cavity visualization

Cystostomy (pneumostomy) proved to be an effective method in uncomplicated hydatid cysts without inflammatory changes of the pericystic parenchyma, localized predominantly in the peripheral lung areas and without the presence of major bronchial fistulas (fig. 6).

To perform an efficient filling, it was necessary, along with the capitonnage of the residual cavities, to fill at least 2/3 of the volume of the residual spaces. This procedure also represents an effective method of prophylaxis of postoperative complications. The period of time that ensures a satisfactory filling of the residual cavity is 20-25 days, during which acceleration of the local repairing phenomena takes place. The adverse reaction was recorded in one case by the development of pleurasy resolved without major therapeutic problems. This method was particularly useful in major or complicated lung hydatid cyst, usually accompanied by marked pleuropulmonary inflammatory phenomena and bronchial fistulas, thereby avoiding pulmonary resection operations.

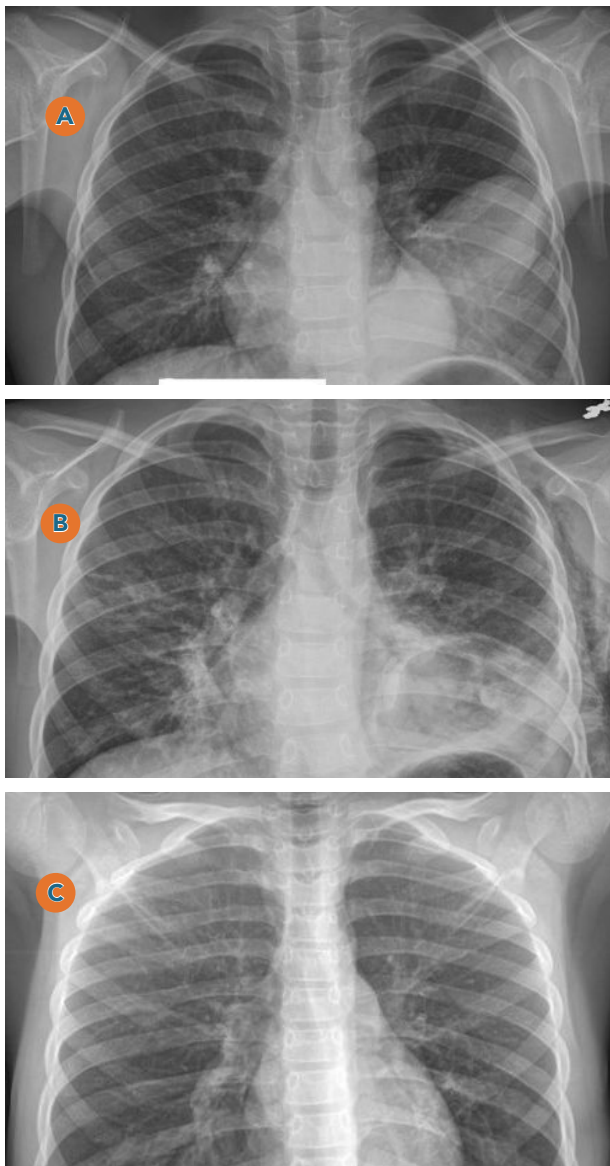


Fig. 6. Patient P, 9 years old. A - preoperative chest X-ray: the presence of a large formation in the lower lobe of the left lung; B - chest X-ray 10 days postoperatively: the presence of a residual cavity; C - chest X-ray 60 days postoperatively

Cases of the lung hydatid cyst recurrence were recorded in 6 (4%) patients, of which 1 patient was reoperated 3 times and one female patient twice, the number of surgical reinterventions reaching 11 (7.33%). Cases of death in the study group were not recorded.

DISCUSSIONS

Surgical intervention is the optimal treatment in lung hydatid cyst [18]. Surgical removal of the intact hydatid larval cyst remains the preferred option in the surgical treatment of this disease with any location, intraoperative contamination being the main cause of multiple secondary hydatidosis. In this context, several substances with a protoscolicidal action have been proposed for the intra-operative inactivation of parasitic elements, including: formalin, thymol, ethanol 95%, hypertonic saline solution 20%, hypertonic glucose solution, povidone iodine, cetrimide, octenidine hydrochloride, chlorhexidine gluconate, hot water, etc. [13, 14, 22, 36]. The increased toxicity and the development of adverse reactions and serious complications induced by these preparations necessitated to search for new scolicide agents with less harmful action on the macro-organism and with increased efficiency in inactivating this parasitic agent [12,34,41]. For this purpose, there were tested several compounds obtained from plants and microorganisms [3, 32, 42], chenodeoxycholic acid, an effective bile stones dissolving agent [44], sodium arsenite [49], silver nanoparticles [40], and biogenic selenium [31]. The results of these experimental studies are at the discussion stage, opinions being often contradictory [29]. It is important that during the process of intra-operative inactivation, the active migration phenomenon of protoscolex is also taken into account [5].

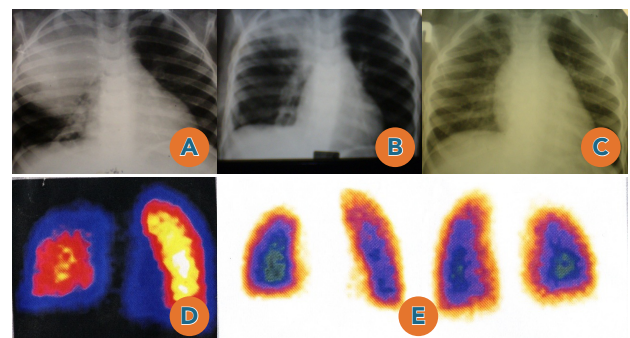


Fig. 7. Patient C. 3 years. A - Preoperative X-ray: Major hydatid cyst in the upper lobe of the right lung. B - postoperative X-ray at discharge (12th day). C - chest X-ray 1 year after surgery. D - pulmonary scintigraphy (perfusion) performed 1 year after surgery. E - postoperative pulmonary scintigraphy of patient C. performed 2 years after surgery

Several techniques have been proposed to remove the hydatid larval cyst dependent on intra-op-

erative conditions, including enucleation (Ugon procedure) plus capitonnage, cystotomy with bronchial fistulas closure plus capitonnage (Possadas procedure), cyst-pericystectomy (Perez-Fontana method), pneumostomy, lung resections, etc. [10, 24, 38].

In the literature there is also controversy regarding the attitude towards the residual cavities after the removal of the hydatid larval cyst [45]. Although parasitic cyst enucleation is only possible in 21.4% of adults and 16% of children [10], some authors believe that using this procedure along with bronchial fistulas closure should be a standard surgical technique, because the residual cavity capitonnage, does not have significant beneficial effects in post-operative evolution [19]. At the same time, several authors opt for cystotomy with the capitonnage of the residual cavity and the preservation of the pericystic parenchyma, the avoidance of the bronchial-pleural fistulas and the prevention of the abscess formation within the residual cavities are important advantages of this technique [2, 11, 28, 51].

There is a risk that capitonnage of the residual cavities will cause the disfigurement of lung parenchyma, which may influence the postoperative re-expansion of the lung [38], and in complicated forms of the disease it can lead to infection, the laceration of the pulmonary tissue and the insufficiency of the capitonnage sutures [45]. The non-capitonnage procedure with pneumonostomy is considered a safe and effective alternative technique by several authors, who concluded that the capitonnage procedure does not have any advantages in terms of hospitalization length, duration of air removal through the chest tube or prevention of some complications such as empyema, persistence of fistulas and air leaks, recurrence [15, 16, 24, 47]. This technical procedure of creating a direct communication between the residual cavity and pleural space, with the removal of bronchial fistulas and external drainage in pulmonary echinococectomy was proposed by Yacoubian H.D. and Dajani T. (1963).

Pulmonary resections, justified under certain conditions [52], should be performed with caution even in the case of infected hydatid cysts, giant or multiple cysts involving the same lobe [21, 25], some technical procedures being preferred with the preservation of the pulmonary parenchyma [39], especially in children and endemic areas, where the risk of recurrence is a real concern [9].

Thus, the results of this study allow us to conclude that:

1. Intraoperative use of 2% silver nitrate solution allows effective antiparasitic inactivation of hydatid larval cyst elements and adequate disinfection of residual cavities, which contributes to a significant reduction in the incidence of recurrent cases and postoperative septic complications.
2. The use of contemporaneous inhalers of Sevoflurane, Isoflurane in the general anesthesia regimens in lung surgery in children allows adequate management and safe control of the level of anesthesia and analgesia with minimal implications for hypoxic pulmonary vasoconstriction.
3. The residual cavity capitonnage with intraoperative filling using "LitAr" preparation represents an optimal way of resolving residual cavities in major hydatid cyst with the presence of bronchial fistulas and in hydatid cyst complicated with rupture, ensuring fast postoperative re-expansion of the restant parenchyma, it being superior to pneumonostomy.

REFERENCES

1. Agudelo Higueta N.I., Brunetti E., McCloskey C. Cystic echinococcosis. *J. Clin. Microbiol.* 54:518-23. doi:10.1128/JCM.02420-15.
2. Aldahmashi M., Alassal M., Kasb I., Elrakhawy H. Conservative surgical management for pulmonary hydatid cyst: analysis and outcome of 148 cases. *HPC. Canadian Resp. J.* 2016. Art. ID 8473070. 6 pag. <http://dx.doi.org/10.1155/2016/8473070>.
3. Almalki E., Al-Shaebi E.M., Al-Quarishy S. et al. In vitro effectiveness of Curcuma longa and Zingiber officinale extracts on Echinococcus protoscoleces. *Saudi J. Biol. Sci.* 2017. 24:90-4.
4. Arinc S., Kosif A., Ertugrul M. et al. Evaluation of pulmonary hydatid cyst cases. *Int. J. Surg.* 2009. 7:192-5.
5. Babuci S. Argumentarea patogenetică și clinic-morfologică a tratamentului medico-chirurgical în hidatidoza pulmonară la copil. Autoref. dis. dr. hab. șt.med. Chișinău. 2005. 30 p.
6. Bygott J.M., Chiodini P.L. Praziquantel: Neglected drug? Ineffective treatment? Or therapeutic choice in cystic hydatid disease? *Acta Tropica.* 2009. 111:95-101.
7. Cangir A.K., Seahin E., Enoen S. et al. Surgical treatment of pulmonary hydatid cysts in children. *J. Pediatr. Surg.* 2001. 36:917-20.
8. Ciobotaru M.D., Luca M., Cobzaru R.G. Surgical management of pulmonary hydatidosis in children. *Rev. Med. Chir. Med. Nat. Iasi.* 2014. 118(3):753-8.
9. Dakak M., Caylak H., Kavakli K. et al. Parenchyma-saving surgical treatment of giant pulmonary hydatid cysts. *Thorac. Cardiovasc. Surg.* 2009. 57(3):165-8.
10. Dincer S.I., Demir A., Sayar A. et al. Surgical treatment of pulmonary hydatid disease: a comparison of children and adults. *J. Pediatr. Surg.* 2006. 41:1230-6.
11. Eisa K.M., Muba., Abdel-Aal K.M. Cystotomy and capitonnage for pulmonary hydatid cyst in upper Egypt, multicenter experience. *J. Egypt. Soc. Cardio-Thor. Surg.* 2013. 21(2):145-8. *Anaesth.* 2016. 19:557-60.
12. Ekci B. Scolicidal agent use in hydatid cysts and complications. *Yeditepe Med. J.* 2011. 5(17):379-84.
13. Elissondo M.C., Albani C.M., Gende L. et al. Efficacy of thymol against Echinococcus granulosus protoscoleces. *Parasitol. Int.* 2008. 57:185-90.
14. Elissondo M.C., Pense P.E., Denegri G.M. Could thymol have effectiveness on scolices and germinal layer of hydatid cysts? *Acta Tropica.* 2013. 125:251-7.
15. Erdogan A., Ayten A., Demircan A. Methods of surgical therapy in pulmonary hydatid disease: is capitonnage advantageous? *Aust. NZ J Surg.* 2005. 75:992-6.
16. Eren M.N., Balci A.E., Eren S. Non-capitonnage method for surgical treatment of lung hydatid cysts. *Asian Cardiovasc. Thorac. Ann.* 2005. 13:20-3.
17. Ghedira Besbes L., Haddad S., Ben Meriem Ch. et al. Giant hydatid lung cysts: About two paediatric cases. *Resp. Med. CME.* 2010. 3:174-8.
18. Ghotbi F., Aghajanzadeh M., Mohtasham B. et al. Complicated hydatid cysts of the lung: is capitonnage better than uncapitonnage method? Comparison between capitonnage and uncapitonnage technique in the complicated hdatid cysts of the lung. *Res. J. Med. Sci.* 2016. 10(3):84-90.
19. Goni M.O., Karim M.F., Alam M.K. et al. Capitonnage versus non-capitonnage surgery for pulmonary hydatid cyst: a head to head study. *J. Dhaka Med. Coll.* 2014. 21(1):94-101.
20. Gupta R., Sharma S.B., Prabhakar G., Mathur P. Hydatid disease in children: Our experience. *Formisan J. Surg.* 2014. 47:211-20.
21. Hasdiraz L., Oguzkaya F., Bilgin M. Is lobectomy necessary in the treatment of pulmonary hydatid cysts? *ANZ J. Surg.* 2006. 76:488-90.
22. Hosseini S.V., Ghanbarzadeh K., Barzin Z. et al. In vitro protoscolicidal effects of hypertonic glucose on protoscolices of hydatid cyst. *Korean J. Parasitol.* 2006. 44(3):239-42.
23. Ionescu S., Andrei B., Mocanu M. et al. 25 years experience in pulmonary hydatid cysts treatment. *J. Pediatr.* 2014. XVII (65-66):55-7.
24. Jehangir S., Kurian J.J., Jacob T.J. et al. Pneumonostomy in the surgical management of hydatid cyst of the lung. *Eur. J. Pediatr. Surg.* 2017. 27(2):171-6.
25. Kilic D., Findikcioglu A., Bilen A., Koc Z. Management of complicated hydatid cyst of the thorax. 2007. 77(9):752-7.
26. Koca T., Akcam M. Albendazole-induced autoimmune hepatitis. *Indian Pediatr.* 2015. 52(1):78-9.
27. Koca T., Dereci S., Gencer A. et al. Cystic echinococcosis in childhood: five-years of experience from a single-center. *Turk. Parazitol. Derg.* 2016. 40(1):26-31.
28. Kosar A., Orki A., Hacıbrahimoglu G. et al. Effect of capitonnage and cystotomy on outcome of childhood pulmonary hydatid cysts. *J. Thorac. Cardiovasc. Surg.* 2006. 132:560-4.
29. Lashkarizadeh M.R., Asgaripour K., Saedi E. et al. Comparison of scolicidal effects of amphotericin B, silver nanoparticles, and Foeniculum vulgare mill on hydatid cysts protoscolices. *Iran J. Parasitol.* 2015. 10(2):206-12.
30. Lungu V. Epidemiology of human echinococcosis in the Republic of Moldova. *Sci Parasitol.* 2012. 13(2):87-91.
31. Mahmoudvand H., Harandi M.F., Shakibaie M. et al. Scolicidal effects of biogenic selenium nanoparticles against protoscolices of hydatid cysts. *Int. J. Surg.* 2014. 12:399-403.
32. Mahmoudvand H., Kheirandish F., Dezaki E.S. et al. Chemical composition, efficacy and safety of Pistacia vera (var. Fandoghi) to inactivate protoscoleces during hydatid cyst surgery. *Biomed. Pharmacother.* 2016. 82:393-8.
33. Marghli S., Zairi J., Ammar A. et al. Hydatidose pulmonaire : étude monocentrique comparant grand et petit enfant. *J. de Pédiatrie et de Puériculture.* 2012. 25(2):81-90.

34. Michalodimitrakis M., Nathena D., Mavroforou A. et al. Fatal hypernatraemia after laparoscopic treatment of hydatid liver cyst: medical and legal concerns of a rare complication. *Forensic Sci. Int.* 2012. 219:e16-e18.
35. Mirshemirani A.R., Razavi S., Sadeghian S. Surgical Treatment of Pulmonary Hydatid Cyst in 72 Children. *Tanafos.* 2009. 8(1):56-61.
36. Moazeni M., Alipour-Chaharmahali M.R. Echinococcus granulosus: in vitro effectiveness of warm water on protoscolices. *Exp. Parasitol.* 2011. 127:14-7.
37. Moroni S., Moscatelli G., Bournissen F.G. et al. Abdominal cystic echinococcosis treated with albendazole. A pediatric cohort study. *PLoS One.* 2016. 11(9):e0160472.
38. Nabi M.S., Waseem T. Pulmonary hydatid disease: what is the optimal surgical strategy? *Int. J. Surg.* 2010. 8:612-6.
39. Oncel M., Sadi S.G., Tezcan B. et al. Parenchyma-preserving and minimally invasive thoracotomy technique in giant pulmonary hydatid cysts. *Turk. Gogus Kalp Dama.* 2015. 23(1):88-91.
40. Rahimi M.T., Ahmadpour E., Esboei B.R. et al. Scolicidal activity of biosynthesized silver nanoparticles against Echinococcus granulosus protoscolices. *Int. J. Surg.* 2015. 15:128-33.
41. Rajabi M.A. Fatal reactions and methaemoglobinaemia after eilver nitrate irrigation of hydatid cyst. *Surg. Practice.* 2009. 13:2-7.
42. Shahnazi M., Azadmehr A., Andalibian A. et al. Protoscolicidal and immunomodulatory activity of Ziziphora tenuior extract and fractions. *Asian Pacific J. Trop. Med.* 2016. 9(11):1062-8.
43. Shahnazi M., Bodakhsh F., Azadmehr A. et al. Study of protoscolicidal effects of hypertonic glucose on protoscolices of hydatid cyst at different concentrations and exposure times. *HPC. Int. Schol. Res. Not.* 2014. Article ID 314502, 5 pag. <http://dx.doi.org/10.1155/2014/314502>.
44. Shi H., Lei Y., Wang B. et al. Protoscolicidal effects of chenodeoxyxholic acid on protoscoleces of Echinococcus granulosus. *Exp. Parasitol.* 2016. 167:76-82.
45. Sokouti M., Golzari S., Aghdam B.A. Surgery of uncomplicated pulmonary hydatid cysts: capitonnage or uncapitonnage? *Int. J. Surg.*, 2011; 9: 221-4.
46. Topcu S., Kurul I.C., Altinok T. et al. Giant hydatid cysts of lung and liver. *Ann. Thorac. Surg.* 2003. 75:292-4.
47. Turna A., Yilmaz M.A., Hacıbrahimoglu G. et al. Surgical treatment of pulmonary hydatid cysts: is capitonnage necessary? *Ann. Thorac. Surg.* 2002. 74:191-5.
48. Umhang G., Chihai O., Boue F. Molecular characterization of Echinococcus granulosus in a hyperendemic European focus, the Republic of Moldova. *Parasitol. Res.* 2014. 113(12):4371-6.
49. Xing G., Wang B., Lei Y. et al. In vitro effect of sodium arsenite on Echinococcus granulosus protoscoleces. *Mol. Biochem. Parasitol.* 2016. 207:49-55.
50. Yacoubian H.D., Dajani T. Preliminary report on a new method of surgical management of hydatid cysts of the lung. *Ann. Surg.* 1963. 157(4):618-24.
51. Yaldiz S., GURSOY S., UCVEY A. et al. Capitonnage results in low postoperative morbidity in the surgical treatment of pulmonary echinococcosis. *Ann. Thorac. Surg.* 2012. 93:962-7.
52. Yekeler E., Karaarslan K., Yazicioglu A. et al. Lobectomy for pulmonary hydatid cyst. *Turk. J. Med. Sci.* 2013. 43:1024-9.
53. Yiallourou A.I., Nastos C., Theodoraki K. et al. Surgical management of major complications of hydatid cysts of the liver - A review of the literature. *Ann. Clin. Cytol. Pathol.* 2017. 3(1):1049.