

A case of giant retroperitoneal lymphangioma and IgG4-positive fibrosis: Causality or coincidence?

SAGE Open Medical Case Reports
Volume 9: 1–6
© The Author(s) 2021
Article reuse guidelines:
sagepub.com/journals-permissions
DOI: 10.1177/2050313X211016993
journals.sagepub.com/home/sco



Kim Rouven Liedtke^{1,2} , Christoph Käding^{1,3}, Paula Döring⁴, Sander Bekechus⁵ and Anne Susann Glitsch¹

Abstract

Several chronic inflammatory diseases have been found to be a subtype of IgG4-related disease, all of which have a typical clinical and histological change, which is based in particular on an overexpression of IgG4 and subsequent fibrosis. At least a part of the retroperitoneal fibrosis, which was originally classified as idiopathic, seems to be assigned to IgG4-related disease. Lymphangiomas are benign, cystic tumors that rarely occur in adults. However, there is no firm association with IgG4-related disease described in the literature to date. This report is about a patient suffering from acute renal failure due to a giant retroperitoneal cyst. Surgical resection remains incomplete in the iliac vessel area due to severe fibrosis and histology revealed features of both lymphangioma and IgG4⁺ fibrosis. The case description is followed by a brief overview of IgG4-related disease and a consideration of whether lymphangiomas might be assigned to this topic.

Keywords

Abdominal cyst, acute kidney failure, IgG4-related disease, lymphangioma, Ormond's disease, retroperitoneal fibrosis

Date received: 22 November 2020; accepted: 21 April 2021

Introduction

Lymphangiomas are rare, benign, cystic tumors that particularly affect children and are mainly located in the head and neck area or the axilla.¹ While the pathogenesis remains unclear in detail, a congenital anomaly of the lymphatic system is assumed.² Trauma and intraoperative injuries to the lymphatic vessels are discussed as possible trigger mechanisms, especially for even less frequent occurrence in adulthood.^{3,4} In terms of diagnosis, ultrasound, computed tomography (CT) and magnetic resonance imaging (MRI) are approximately equivalent in the detection of a cystic mass,⁵ although the final diagnosis of lymphangioma can very often only be made after surgical resection and subsequent histological analysis.⁶ Due to the low incidence of lymphangiomas, especially in adulthood, the level of evidence is poor, but complete surgical resection is recommended as an effective therapy with a low risk of recurrence.⁷ This has already been done laparoscopically, even with a large cyst.⁸

Retroperitoneal fibrosis is a rare disease which, in addition to unspecific pain, is often revealed by medialization and obstruction of the ureters with subsequent renal failure.⁹

The first-line treatment for retroperitoneal fibrosis includes immunosuppressive therapy (e.g. steroids). However, if the obstruction is significant, surgery should be considered.¹⁰ At least some of the patients show features of an IgG4-related autoimmune disease (IgG4-RD).^{11,12} The term IgG4-RD subsumes a multitude of various diseases that can affect almost any organ (e.g. autoimmune pancreatitis type 1, Mikulicz's disease).¹³ These are characterized by elevated serum IgG

¹Department of General, Visceral, Thoracic and Vascular Surgery, Greifswald University Medical Centre, Greifswald, Germany

²Department of Trauma and Orthopedic Surgery, Experimental Trauma Surgery, University Medical Center Schleswig-Holstein

³Department of Urology, Greifswald University Medical Centre, Greifswald, Germany

⁴Institute of Pathology, Greifswald University Medical Centre, Greifswald, Germany

⁵Centre for Innovation Competence (ZIK) *plasmatis*, Leibniz Institute for Plasma Science and Technology (INP Greifswald), Greifswald, Germany

Corresponding Author:

Kim Rouven Liedtke, Department of Trauma and Orthopedic Surgery, Experimental Trauma Surgery, University Medical Center Schleswig-Holstein, Arnold-Heller-Straße 3, 24105 Kiel, Germany.
Email: kimrouven.liedtke@uksh.de



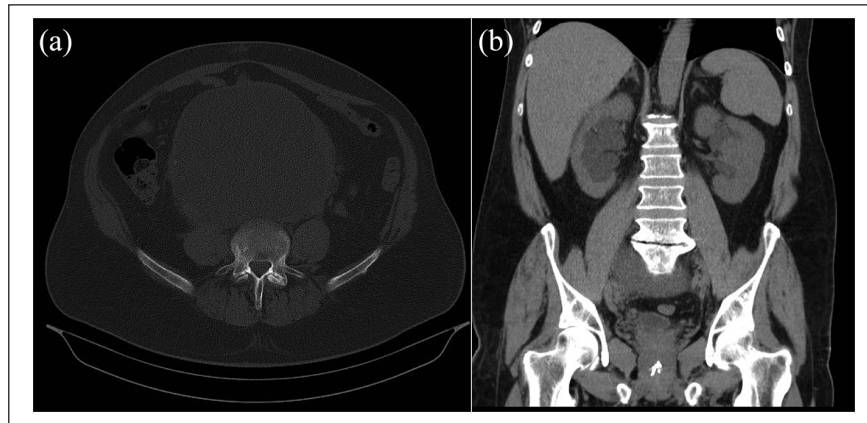


Figure 1. Unenhanced CT scan revealed a large retroperitoneal cystic mass. Both ureters were compressed by the homogeneous tumor with consecutive obstructive uropathy. Images in axial (a) and coronary (b) axis.

and a typical histopathological triad: that is, (a) a lymphoplasmacytic infiltrate enriched with IgG4⁺ plasma cells (>50 per high-power field in most tissues, but with an IgG4/IgG ratio >40% in all tissues), (b) storiform fibrosis and (c) obliterative phlebitis.¹⁴ The pathogenesis and especially the role of IgG4 are still unclear.¹⁵ The American College of Rheumatology (ACR) and the European League Against Rheumatism (EULAR), and the Japanese IgG4 team developed scoring systems (i.e. ACR/EULAR classification criteria for IgG4-RD,¹⁶ revised comprehensive diagnostic (RCD) criteria for IgG4-RD)¹⁷ to increase diagnostic reliability in this emerging field of IgG4-RD.

Here, we report about a complicated case of a symptomatic giant retroperitoneal cyst showing characteristics of both lymphangioma and IgG4⁺ fibrosis.

Case presentation

This report is about a 61-year-old Caucasian patient with a mostly unremarkable medical history. More than 30 years ago, the patient underwent an open appendectomy and an inguinal hernia repair (i.e. Lichtenstein). Anamnestically, there were no other operations or allergies. At the time of hospitalization, the patient is not taking any medication. He presented unspecific abdominal pain for 2 weeks, moderate anemia (hemoglobin: 7.4 mmol/L, reference: 8.6–11.2) and acute kidney failure (creatinine: 179 μ mol/L (49–97)). Furthermore, the blood investigation revealed no seminal findings (leucocytes: 7.87 Gpt/L (4.3–10.0), thrombocytes: 314 Gpt/L (140–440), alanine aminotransferase (ALAT): 0.78 μ katal/L (0.22–0.77), aspartate aminotransferase (ASAT): 0.39 μ katal/L (<0.59), alkaline phosphatase: 1.7 μ katal/L (0.83–2.26), gamma-GT: 0.59 μ katal/L (0–0.96), lipase: 2.94 μ katal/L (1.59–6.36)). Physical examination was unremarkable, with the exception of a distant but soft abdomen that was not tender on pressure. An unenhanced CT scan demonstrated a large, cystic homogeneous tumor with compression of both ureters and consecutive obstructive uropathy

(Figure 1). Upon request, the patient stated a significant increase in abdominal circumference over the past 4 years, but had not consulted a doctor due to the lack of pain. For further diagnosis and treatment, he was transferred to the university medicine and retrograde pyelography was performed. Communication between the ureters and the tumor was excluded and ureter stents were placed on both sides (Figure 2). An enhanced CT showed the consistently sized (19 cm \times 17 cm \times 14 cm), non-septated, homogeneous (10–15 HU), suspiciously thick-walled retroperitoneal cyst with a close relationship to both ureters, the sacral vertebra S1 and the duodenum (Figure 3). The retroperitoneal lymph nodes were only moderately enlarged (13 mm shortest axial diameter); otherwise, there was no evidence of lymph node or organ metastases in the examined area. Therefore, differential diagnoses included a tailgut cyst, an epidermoid cyst, a lymphangioma or a duodenal duplication cyst, less likely a meningocele or malignant origin (myxoid retroperitoneal sarcoma, primary retroperitoneal mesothelioma).

Considering both the size and the suspect wall enlargement, we planned an approach via open resection. After performing median laparotomy, the large cyst was found. Due to the enormous size, no further preparation was possible, so we initially decided to puncture the cyst. Consecutively, plenty of chylous fluid was emptied. The cyst could be resected subsequently, whereby only an incomplete resection (R2) could be achieved in the area of the iliac bifurcation. Here, the cyst was firmly attached to the vessels via severe fibrosis and an unavailing resection attempt resulted in severe bleeding of the right iliac vein requiring suture.

The histologic analysis revealed a large and slit-like cystic lumen lined by a flat layer of endothelial cells with inconspicuous nuclei. These cells expressed podoplanin (positive reaction with antibody clone D2-40, Figure 4) and consequently led to the diagnosis of a lymphangioma. In proximity, there existed a pronounced, partly storiform fibrosis involving the adjacent adipose tissue. Here, spotted lymphoplasmacellular inflammatory infiltrates with numerous

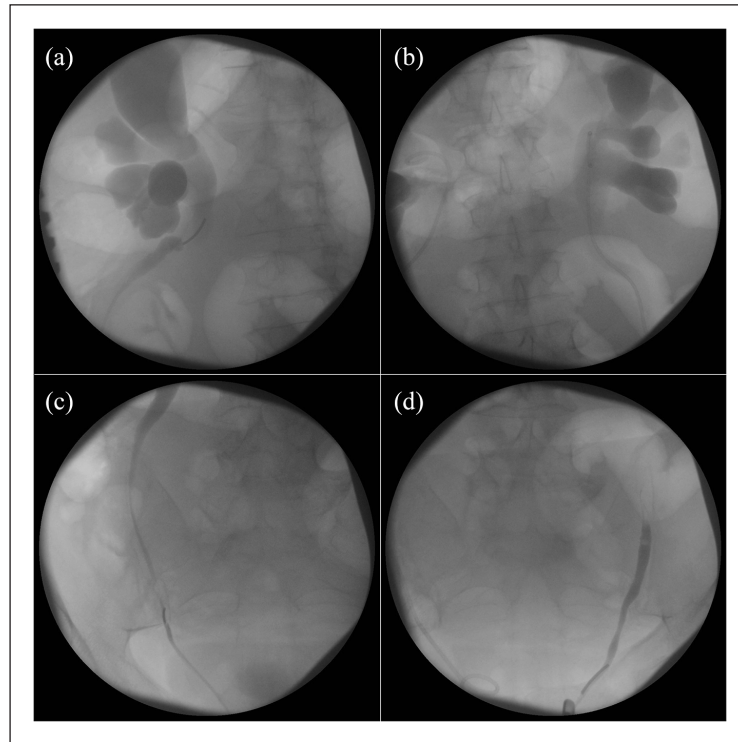


Figure 2. Preoperative retrograde ureteropyelography revealing lateralization and compression of both ureters as reason of acute renal failure. The examination showed the space-consuming character of the cyst and clarified its impact with consecutive obstructive hydronephrosis grade 3 on both sides. There was no connection between the upper urinary tract and the giant cyst. Ureteral stents were placed on both sides due to acute renal failure during the intervention. Shown is the upper urinary tract on the right (a, c) and left (b, d) side.

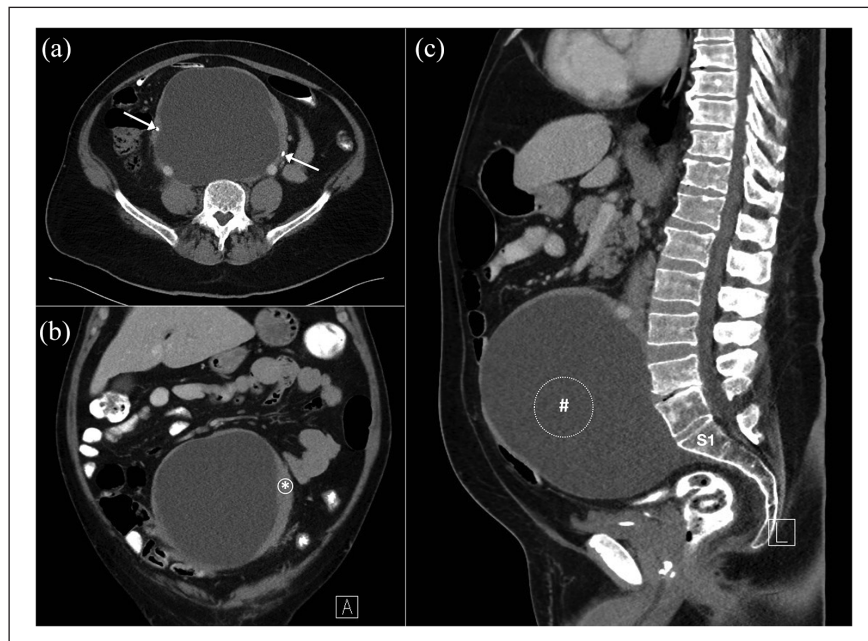


Figure 3. Contrast agent enhanced abdominal CT scan. The retroperitoneal cyst is large (19 cm × 17 cm × 14 cm), non-septated and walled irregularly. While the liquid content is homogeneous (10–15 HU, number sign), the wall appears suspiciously enhanced (60–70 HU, asterisk). The cyst is in close contact with the spinal column (sacral vertebra, S1). Arrows indicate the ureteral stents. CT scan is enhanced by oral, rectal and intravenous applied contrast agent (iodine based). Images in coronary (a), axial (b) and sagittal (c) axis.

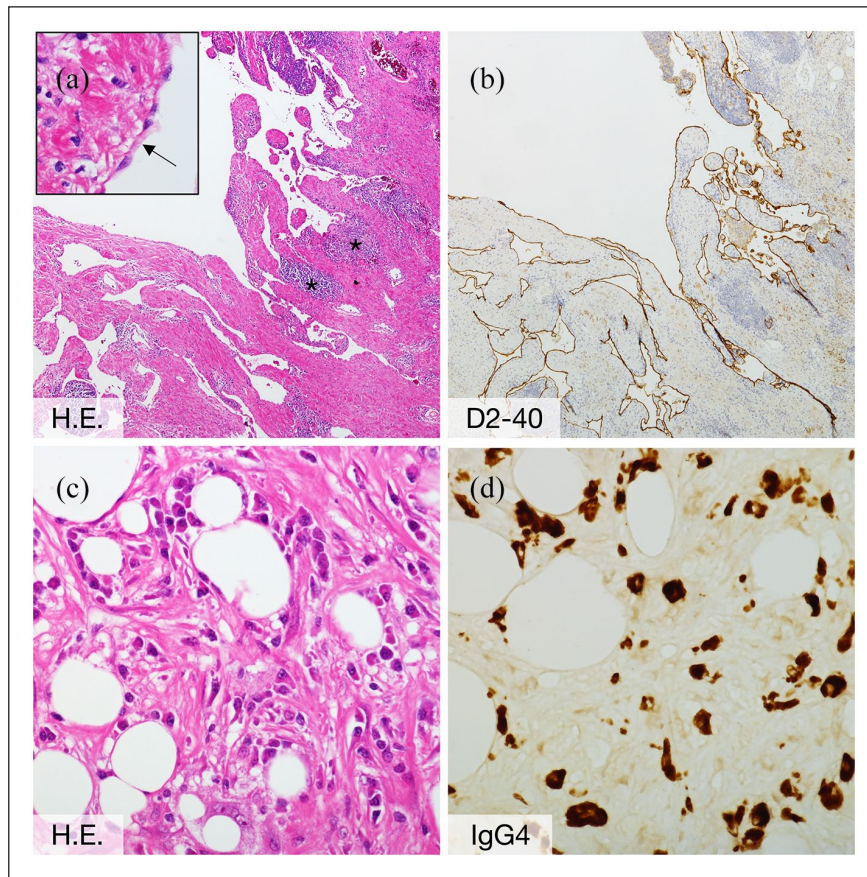


Figure 4. Pathological examination demonstrating characteristics of lymphangioma and IgG4⁺ fibrosis. The wide and slit-like cystic lumen is lined by flat endothelial cells (a, see inset, arrow). In immunohistochemistry, these cells were D2-40 positive (b). Note the spotted lymphoplasmacellular infiltrates in proximity to the cystic lumina (a, asterisk). Retroperitoneal fibrosis involves the adipose tissue with numerous plasma cells (c). The proportion of IgG4⁺ plasma cells was extremely high (>50 IgG4⁺ plasma cells/high power field) in hotspot regions (d).

Length of lower image border: 2.33 mm (a, b) or 0.23 mm c, d).

plasma cells could be found. The proportion of IgG4⁺ plasma cells was high with up to >50 cells per high-power field in hotspot regions with an IgG4/IgG ratio of approximately 60%. These findings fit the histological definition of IgG4-RD (e.g. IgG4⁺ retroperitoneal fibrosis) determined by an international expert group.¹⁴

The postoperative course was unremarkable, and the abdominal drainage could be removed on the first postoperative day (<300 mL serous fluid). On the sixth day, the patient was discharged from hospital and the ureter stents were removed on an outpatient basis. Nearly 1 month after the operation, the patient presented to the emergency department with an ascending urinary tract infection. After inpatient intravenous antibiotic therapy, the patient was discharged symptom-free on day 5. One month later, the patient presented again with the same diagnosis. This time outpatient antibiotic therapy was carried out successfully.

In a 3-month follow-up, the patient presented in a good condition. Blood examination was unremarkable, particularly serum level of immunoglobulin G was not elevated (10.7 g/L (7–16), Ig-G4: 0.079 g/L (0.04–0.78)) and urinary

examination revealed no pathologic finding either. An abdominal MRI showed a small Gadolinium-enhancing lesion with residual fluid in the area of the previous R2 resection (Figure 5). In addition, both ureters were prominently enhanced, as in the case of chronic inflammation, but no signs of spacious retroperitoneal fibrosis could be detected. In consent with the patient and due to the absence of symptoms, a decision was made against immunosuppressive therapy and in favor of close follow-up care.

Discussion

The coincidence of lymphangioma and retroperitoneal fibrosis has yet not been described. An extensive literature search revealed just one case of IgG4⁺, steroid responsive lymphangioma in a young woman. However, the pathological examination did not reveal any fibrosis or obliterative phlebitis, and the authors concluded that their patient did not have IgG4-RD.¹⁸ Both retroperitoneal fibrosis and lymphadenopathy have been observed in IgG4-RD,¹⁹ but cystic forms of retroperitoneal fibrosis are an absolute rarity; only three of

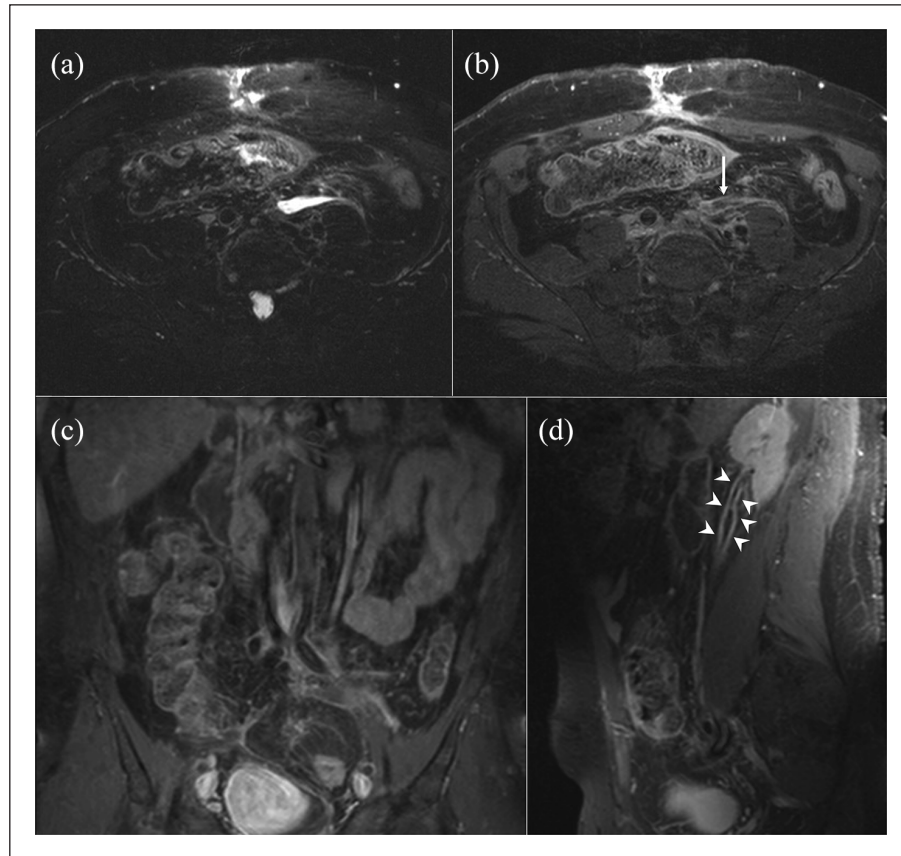


Figure 5. Follow-up MRI revealed a small cystic residuum and no signs of spacious retroperitoneal fibrosis. Close to the left A. iliaca communis a small fluid structure was detected (a). The wall was enhanced by contrast agent (b, arrow). The presumed residual lymphangioma extended up to the left M. psoas. The ureter wall was enhanced by contrast agent (right > left; arrow head, c, d); however, no relevant uropathy was observed. In addition, no spacious fibrosis was detected in the retroperitoneum. Sequence protocol: T2 weighted, turbo spin echo, fat saturated (a); T1 weighted, turbo spin echo, fat saturated, gadolinium enhanced (b–d).

these cases are described in the literature,^{20,21} and only one of them was punctured with evidence of chylous fluid. Fibrosis is more likely to cause a hydrocele or varicocele testis as a consequence of gonadal vessel involvement.²²

In the case presented herein, the histopathological examination revealed both lymphangioma and IgG4-associated retroperitoneal fibrosis. Given the approved scoring systems, IgG4-RD is meant to be present (28 points in ACR/EULAR classification criteria for IgG4-RD; threshold ≥ 20) or at least probable (RCD criteria for IgG4-RD) in this patient. However, it is important to note that the diagnosis of IgG4-RD was not suspected prior surgery. Therefore, the preoperative diagnosis is very artificial concerning inclusion and exclusion criteria.

Additionally, one should take into consideration that prior imaging from the patient is not available. Perhaps, the cyst grew over decades without causing specific symptoms, like it is quite common for abdominal lymphangiomas.²³ However, the patient negates any trauma or previous surgery that may have resulted in disruption of the retroperitoneal lymphatic vessels. A causal relationship therefore seems at least likely. The large lymphangioma could then either have developed completely new as a result of fibrosis

with subsequent disruption of the lymphatic vessels or could have rapidly progressed on the basis of an already existing, but smaller lymphangioma. On the contrary, fibrosis could also have been the result of the lymphangioma. Although it is a seldomly observed finding, lymphangiomas can present with chronic inflammation and subsequent fibrosis.²⁴ The lymphangioma then induced a local inflammation that met the histopathological criteria of IgG4-RD, but without systemic effects. Based on the follow-up results (normal serum IgG level, no evidence of fibrosis on MRI), this possibility appears to be the more likely. However, an elevated serum IgG4 is neither exclusive to IgG4-RD nor does a normal concentration rule out the diagnosis.²⁵

Regardless of the exact pathogenesis, this is the first case report of simultaneous giant lymphangioma and IgG4⁺ retroperitoneal fibrosis. The giant cyst impeded the possible diagnosis of retroperitoneal fibrosis preoperatively and consequently a surgical approach has been chosen without considering steroid therapy. Relevant fibrosis in close contact to the iliac vessels, however, impeded the complete resection of the cyst wall. This demonstrates the surgical value of this finding, as the intended goal (R0 resection of the cyst) could not be achieved. It is speculative whether medical therapy

would have achieved remission, and it is also speculative whether the lymphangioma induced the local fibrosis, or vice versa. Although the cyst was resected incompletely (R2) and no immunosuppressive therapy was performed, there is no evidence for relevant recrudescence at the 3-month follow-up. The clinical significance of the R2 resection is therefore also unclear. Further research and case reports could help to answer these questions and offer new treatment options.

Conclusion

This case is about an adult patient suffering from giant retroperitoneal lymphangioma that avoided complete resection (R0) due to concomitant, severe IgG4⁺ fibrosis. Therefore, physicians and patients should be aware of the possibility of surgical failure in per se benign lymphangiomas and might consider further diagnostics. Additionally, this report reveals how patchy the understanding of the pathogenesis of IgG4-RD is so far and is intended to sensitize physicians to examine the proportion of IgG4⁺ plasma cells in lymphangioma tissue—especially for those characterized by pronounced fibrosis. In this group of patients, systemic therapy in the event of a relapse might be a promising treatment option.

Declaration of conflicting interests

The author(s) declared no potential conflicts of interest with respect to the research, authorship, and/or publication of this article.

Ethical approval

Our institution does not require ethical approval for reporting individual cases or case series.

Funding

The author(s) received no financial support for the research, authorship, and/or publication of this article.

Informed consent

Written informed consent was obtained from the patient for their anonymized information to be published in this article.

ORCID iD

Kim Rouven Liedtke  <https://orcid.org/0000-0002-0273-509X>

References

- Alqahtani A, Nguyen LT, Flageole H, et al. 25 Years' experience with lymphangiomas in children. *J Pediatr Surg* 1999; 34(7): 1164–1168.
- Aprea G, Guida F, Canfora A, et al. Mesenteric cystic lymphangioma in adult: a case series and review of the literature. *BMC Surg* 2013; 13(1): A4.
- Aneeshkumar MK, Kale S, Kabbani M, et al. Cystic lymphangioma in adults: can trauma be the trigger. *Eur Arch Otorhinolaryngol* 2005; 262(4): 335–337.
- Kim JH, Ryu WS, Min BW, et al. Acquired omental cystic lymphangioma after subtotal gastrectomy: a case report. *J Korean Med Sci* 2009; 24(6): 1212–1215.
- Romeo V, Maurea S, Mainenti PP, et al. Correlative imaging of cystic lymphangiomas: ultrasound, CT and MRI comparison. *Acta Radiol Open* 2015; 4(5): 2047981614564911.
- Takiff H, Calabria R, Yin L, et al. Mesenteric cysts and intra-abdominal cystic lymphangiomas. *Arch Surg* 1985; 120(11): 1266–1269.
- Makni A, Chebbi F, Fetirich F, et al. Surgical management of intra-abdominal cystic lymphangioma. *World J Surg* 2012; 36(5): 1037–1043.
- Kasza J, Brody FJ, Khambaty F, et al. Laparoscopic resection of a retroperitoneal cystic lymphangioma in an adult. *Surg Laparosc Endosc Percutan Tech* 2010; 20(3): e114–116.
- Ormond JK. Idiopathic retroperitoneal fibrosis: an established clinical entity. *JAMA* 1960; 174(12): 1561–1568.
- Pipitone N, Vaglio A and Salvarani C. Retroperitoneal fibrosis. *Best Pract Res Clin Rheumatol* 2012; 26(4): 439–448.
- Khosroshahi A, Carruthers MN, Stone JH, et al. Rethinking Ormond's disease: "idiopathic" retroperitoneal fibrosis in the era of IgG4-related disease. *Medicine* 2013; 92(2): 82–91.
- Zen Y, Onodera M, Inoue D, et al. Retroperitoneal fibrosis: a clinicopathologic study with respect to immunoglobulin G4. *Am J Surg Pathol* 2009; 33(12): 1833–1839.
- Kleger A, Seufferlein T, Wagner M, et al. IgG4-related autoimmune diseases: polymorphous presentation complicates diagnosis and treatment. *Dtsch Arztebl Int* 2015; 112(8): 128–135.
- Deshpande V, Zen Y, Chan JK, et al. Consensus statement on the pathology of IgG4-related disease. *Mod Pathol* 2012; 25(9): 1181–1192.
- Okazaki K, Uchida K, Koyabu M, et al. Recent advances in the concept and diagnosis of autoimmune pancreatitis and IgG4-related disease. *J Gastroenterol* 2011; 46(3): 277–288.
- Wallace ZS, Naden RP, Chari S, et al. The 2019 American College of Rheumatology/European League against rheumatism classification criteria for IgG4-related disease. *Arthritis Rheumatol* 2020; 72(1): 7–19.
- Umehara H, Okazaki K, Kawa S, et al. The 2020 revised comprehensive diagnostic (RCD) criteria for IgG4-RD. *Mod Rheumatol* 2021; 31(3): 529–533.
- Al Zaki AA, Mann SL, Carruthers MN, et al. A young woman with steroid-responsive, IgG4-positive plasma cell-enriched cystic lymphangioma and chylous ascites. *Clin Case Rep* 2018; 6(6): 1098–1100.
- Umehara H, Okazaki K, Masaki Y, et al. A novel clinical entity, IgG4-related disease (Igg4rd): general concept and details. *Mod Rheumatol* 2012; 22(1): 1–14.
- Jansen I, Hendriksz TR and Van Bommel EF. Pseudocyst formation in retroperitoneal fibrosis relapse. *Br J Radiol* 2010; 83(990): e111–e113.
- Feldberg MA and van Waes PF. Computed tomography of pseudocysts in retroperitoneal fibrosis. *J Comput Assist Tomogr* 1987; 11(3): 485–487.
- Vaglio A, Salvarani C and Buzio C. Retroperitoneal fibrosis. *Lancet* 2006; 367(9506): 241–251.
- Roisman I, Manny J, Fields S, et al. Intra-abdominal lymphangioma. *Br J Surg* 1989; 76(5): 485–489.
- Hornick JL and Fletcher CD. Intraabdominal cystic lymphangiomas obscured by marked superimposed reactive changes: clinicopathological analysis of a series. *Hum Pathol* 2005; 36(4): 426–432.
- Carruthers MN, Khosroshahi A, Augustin T, et al. The diagnostic utility of serum IgG4 concentrations in IgG4-related disease. *Ann Rheum Dis* 2015; 74(1): 14–18.