

6-8-2016

Full mouth rehabilitation of a combined fixed and removable prosthesis: A Case report

Colette EL BOUEIZ

Elie ZEBOUNI

Follow this and additional works at: <https://digitalcommons.aaru.edu.jo/iajd>

Recommended Citation

EL BOUEIZ, Colette and ZEBOUNI, Elie (2016) "Full mouth rehabilitation of a combined fixed and removable prosthesis: A Case report," *International Arab Journal of Dentistry*. Vol. 7: Iss. 1, Article 4. Available at: <https://digitalcommons.aaru.edu.jo/iajd/vol7/iss1/4>

This Scientific Article (Research Note) is brought to you for free and open access by Arab Journals Platform. It has been accepted for inclusion in International Arab Journal of Dentistry by an authorized editor. The journal is hosted on [Digital Commons](#), an Elsevier platform. For more information, please contact rakan@aarj.edu.jo, marah@aarj.edu.jo, u.murad@aarj.edu.jo.

FULL MOUTH REHABILITATION OF A COMBINED FIXED AND REMOVABLE PROSTHESIS: A CASE REPORT

Colette El Boueiz* | Elie Zebouni**

Abstract

The full mouth rehabilitation seeks to restore the occlusal function, in order to allow to the masticatory system to operate physiologically with an occlusal stability in centric relation and a well-defined anterior guidance.

The esthetics in all its parameters will have to be restored, this being the patient's chief complaint.

A sequential treatment plan, where several disciplines inter-act, will be exposed in a specific order of interventions to meet the concerns expressed by the patient, especially in intermediary phases of treatment.

The treatment plan will include a periodontal initial preparation, extraction of unfavorable teeth with a period of fixed temporization at the lower jaw and a temporary removable appliance at the upper jaw.

The final prosthesis will be as follow: fixed prosthesis on all teeth at the mandible and a removable prosthesis (overdenture type) at the maxilla.

Keywords: Full mouth rehabilitation - occlusal stability - overdenture - centric relation - anterior guidance.

IAJD 2016;7(1):23-31.

RÉHABILITATION TOTALE PAR DES PROTHÈSES FIXÈES ET AMOVIBLES: UN RAPPORT DE CAS CLINIQUE

Résumé

La réhabilitation prothétique totale cherche à rétablir l'ensemble des fonctions occlusales, et ceci pour permettre à l'appareil manducateur de fonctionner physiologiquement avec une stabilité occlusale en relation centrée et un guidage antérieur bien défini.

Etant le motif principal de la consultation, l'esthétique sera prioritairement rétablie dans le respect des différents critères.

Un plan de traitement séquentiel pluridisciplinaire sera présenté selon la chronologie des étapes de réalisation des soins et qui prend en considération les appréhensions d'abord esthétiques de la patiente, particulièrement dans les phases intermédiaires du traitement.

Le plan de traitement comprendra un assainissement parodontal, l'extraction des dents à pronostic défavorable en passant par une temporisation fixe à la mandibule et amovible au maxillaire supérieur.

Les prothèses définitives ont consisté en des réhabilitations fixées à la mandibule et la confection d'une prothèse amovible supra dentaire (type overdenture) au niveau du maxillaire supérieur.

Mots-clés: réhabilitation prothétique totale - stabilité occlusale – prothèse amovible supra dentaire - relation centrée - guidance antérieure.

IAJD 2016;7(1):23-31.

* Clinical Assistant,
Master en Sciences Biologiques,
Dpt of Prosthodontics, Faculty of Dental
Medecine,
Saint-Joseph University, Lebanon
colette.boueiz@usj.edu.lb

** Prof. ,
Head of Dpt of Prosthodontics and
Occlusodontics,
Faculty of Dental Medecine,
Saint-Joseph University, Lebanon

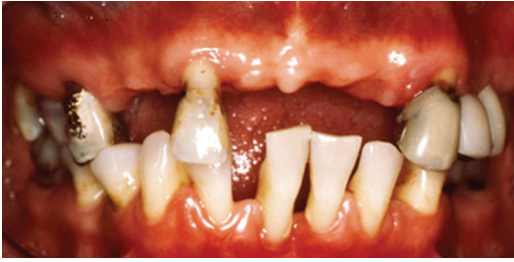

Fig. 1a: Clinical view of the upper and lower jaw relationship.

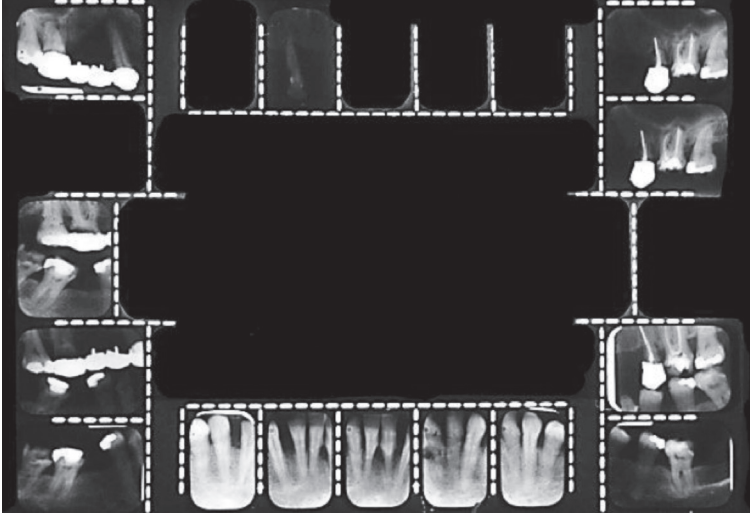


Fig. 1b: Initial x-rays.

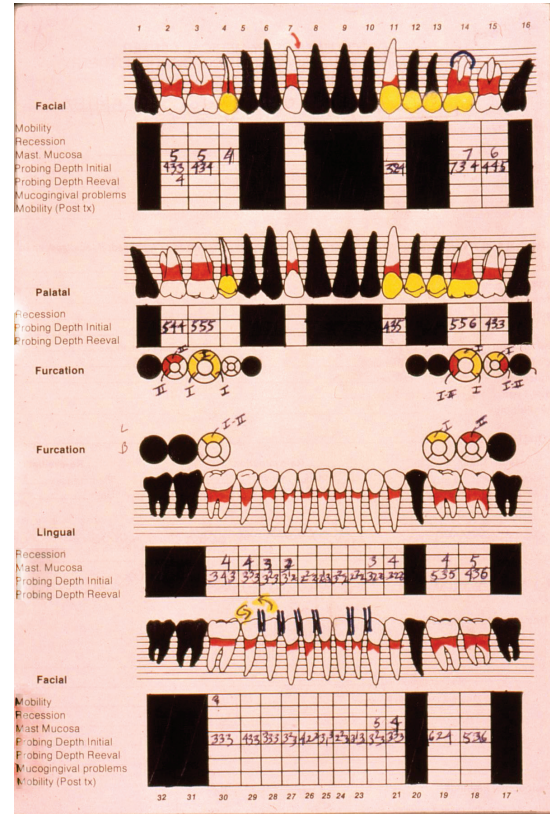


Fig. 1c: Periodontal chart.

Introduction

In cases of completely broken-down dentitions involving upper and lower jaw, associated with loss of vertical dimension, loss of functional and esthetic parameters, it is essential to have a well thought sequenced treatment plan [1, 2].

The goal of this case report is to show the management of the multiple steps involved in the execution of such a treatment plan which most of the time could take months to complete. Those patients will be under the care of many specialists [3-5]. What will be essential is the proper sequencing and coordination of each one's intervention [6].

Case presentation

A 54- years old woman presented to the school of dentistry at Saint Joseph University, Beirut, suffering

from a complete breakdown in her dentition. Her chief complaint was: "I want to fix my teeth, I don't like the way they look."

The clinical examination revealed:

In the upper jaw the loss of several teeth: 14-13-11-21-22. The presence of resin to gold prosthesis, as well as old amalgams (Figs. 1a & 1b). An ill-fitting flipper was used to provide a minimum of decent esthetics.

In the lower jaw, we noted the presence of diastemas and rotations of the existing teeth, with the presence of extensive decay. The four lower incisors showed signs of a severe periodontitis associated with the presence of heavy calculus and subsequent teeth migration and pocketing (Fig. 1c).

After multispecialties consultations [7], we came up with the following treatment plan:

On the upper jaw:

- Amalgam on the teeth # 16 and # 27;
- Coping on the tooth # 23;
- Overdenture.

On the lower jaw:

- Onlay on the tooth # 46;
- Porcelain – fused to metal bridge from the tooth # 45 to the tooth # 36 knowing that the teeth # 42,41,31,32 and 35 are pontics, with the addition of an extra incisor between the teeth # 31 and # 41 due to the large space and to avoid the confection of oversized first incisors.

Orthodontics was proposed to correct misalignments and rotations. The patient refused due to time considerations.

Initial preparation

An initial preparation was performed consisting of a full mouth scaling

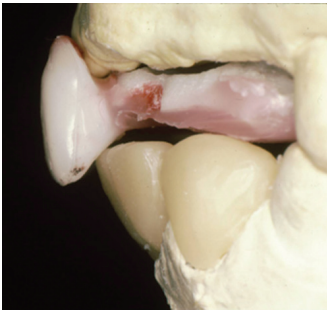


Fig. 2a: Profile view.

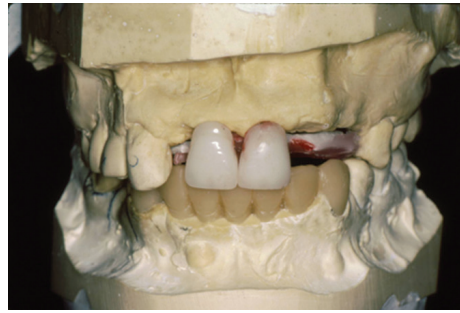


Fig. 2b: Buccal view.

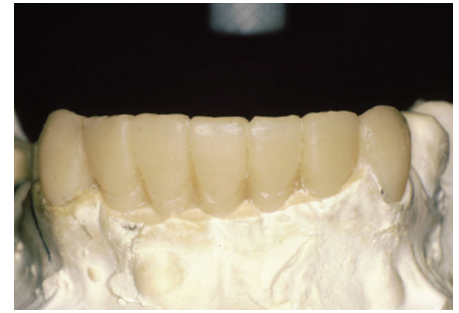

Fig. 2c: Diagnostic lower wax up.

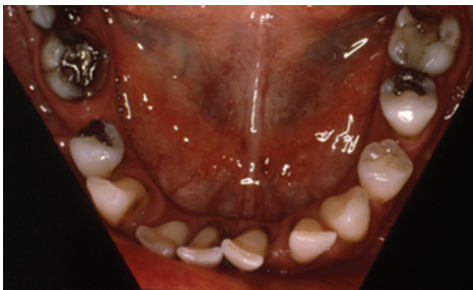

Fig. 3a: Lower arch before temporisation.

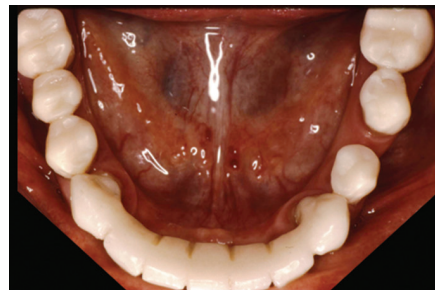

Fig. 3b: Lower arch view after temporisation.

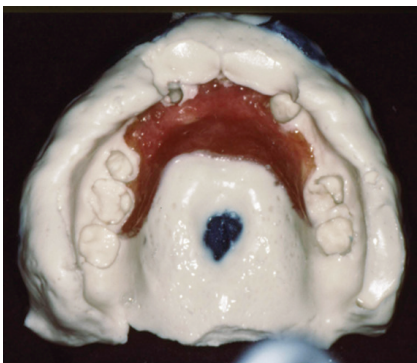


Fig. 4: Alginate pick-up impression.

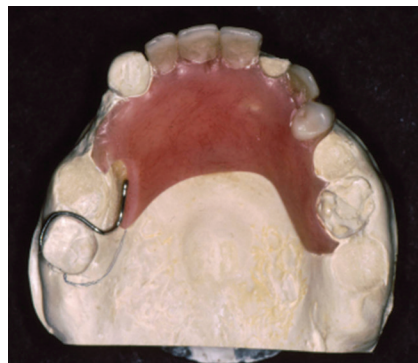

Fig. 5a: Modification at the anterior

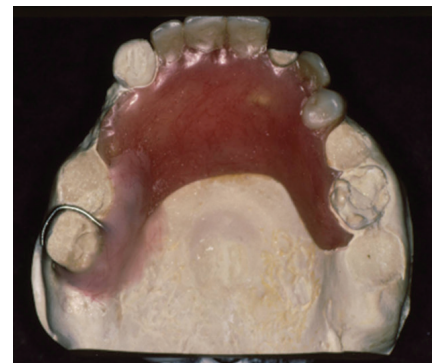
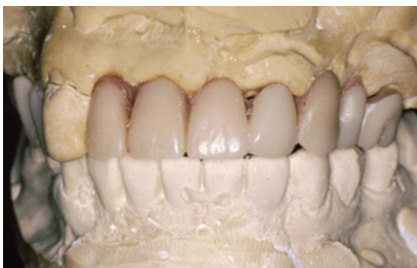
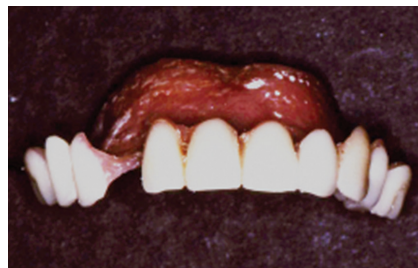Fig. 5b: Modification at the posterior region to the existing flipper.



Figs. 5c,d: Final adjustment of the flipper.



and root planning followed by an oral hygiene instruction.

Diagnostic wax up

In the absence of exact references regarding the positions of the upper incisors (ill-fitting acrylic partial denture), and the anterior migration of the lower incisors due to the periodontal condition, the first and foremost requirement is to position the upper two incisors based on esthetics and phonetics (Figs. 2a & 2b), then transfer it to the articulator where it becomes much easier to develop the lower wax up and establish the plane of occlusion (Fig. 2c).

Clinical temporization

The four lower incisors deemed hopeless were extracted and a heated-processed temporary bridge 13-x-x-x-x-x-43 (adding an extra incisor to fill the edentulous space) was immediately placed. The posterior quadrants were temporized with cold – cure blocks temporaries thus, restoring the lower occlusal plane of occlusion (Figs. 3a & 3b).

Stabilization of the upper jaw using the existing flipper: an alginate pick – up impression for the upper existing flipper was made (Fig. 4). The impression was immediately poured with a fast setting stone. The two casts were mounted on an articulator and the modifications were made to the existing flipper (Figs. 5a, 5b, 5c & 5d).

While the laboratory procedures were being made, the patient was anesthetized and the hopeless teeth were extracted (Fig. 6).

A few hours later the patient left the office with the upper jaw completely stabilized. Total functions as well as esthetics were delivered in a total of two appointments (Fig. 7).

The treatment of the candidiasis was done according to the following protocol [8-10]:

*Application of daktarin oral gel for five minutes twice a day for two weeks period.

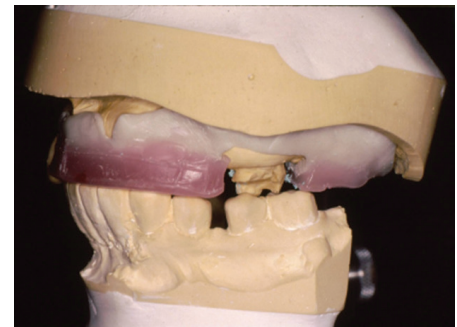
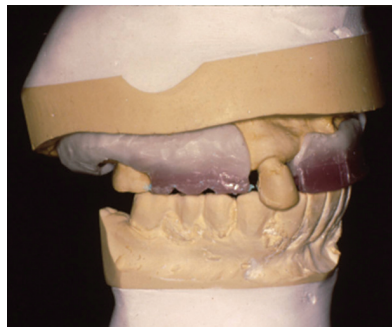
*Mouth rinse of chlorhexidine solution 0.12 %.

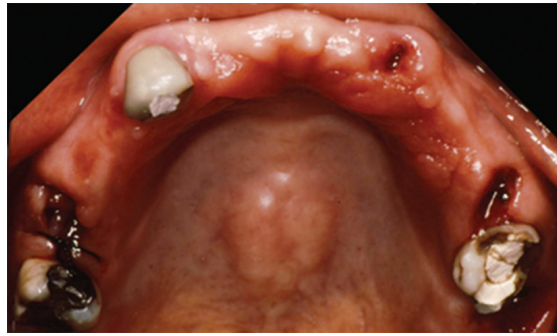

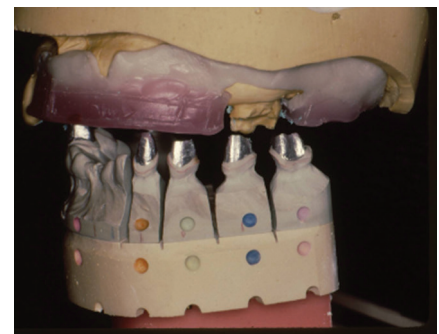
Fig. 6: Extraction of the hopeless teeth.

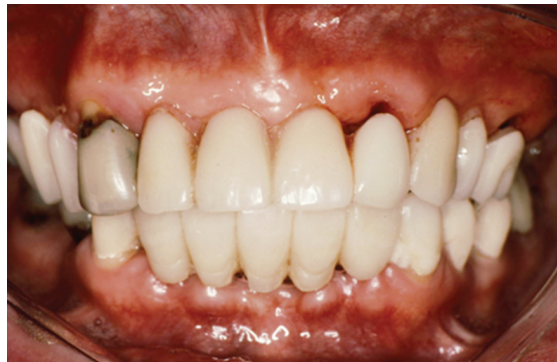

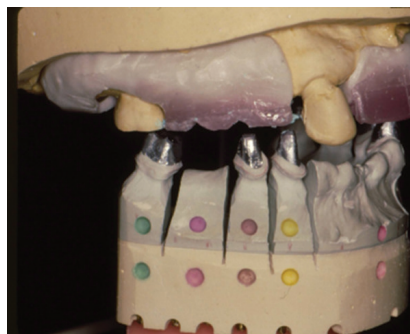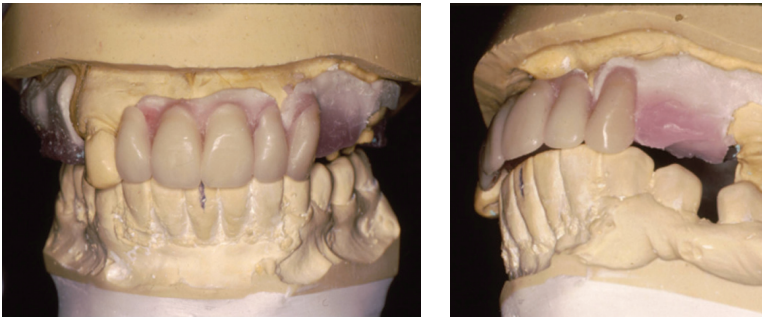
Fig. 7: Upper and lower arch temporization.



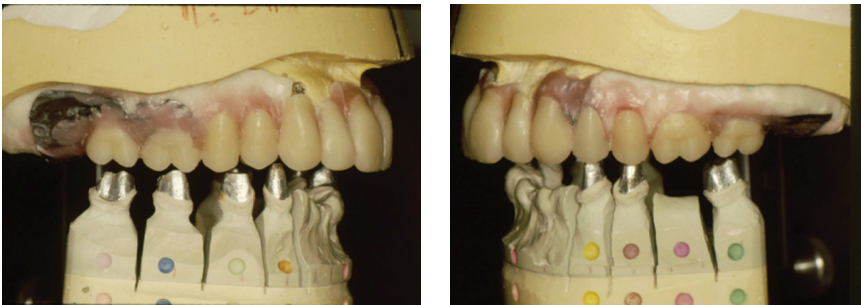
Figs. 8a,b: Mounting of the upper master – cast opposing the lower temporaries.




Figs. 9a,b: Mounting of the upper master – cast opposing the lower master pindexed cast.



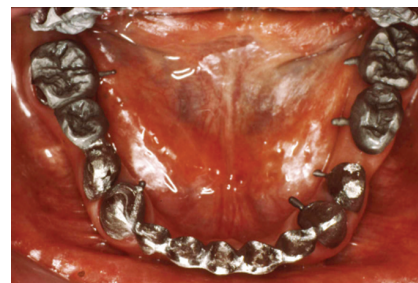
Figs. 10a,b: Set-up of the upper 6 anterior teeth.



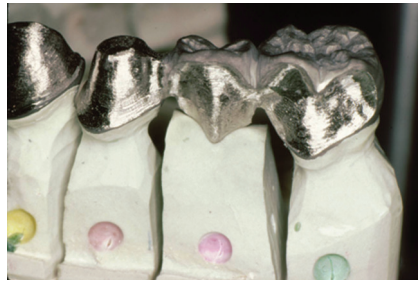Figs. 11a,b: Setting of the full upper using (Pilkington-Turner) anatomical teeth.



Figs. 12a, b: Adjustment of the anterior table.



Figs. 13a, b: Metal try-in of the lower frameworks.



Figs. 14a, b: Posterior metal frameworks.

Laboratory phase

A two months period was given for complete tissue healing. The upper final impression for the overdenture was made and mounted in relation to the lower temporaries (Figs. 8a & 8b).

The final impression for the lower fixed reconstruction was made and cross mounted in relation to the upper master cast (Figs. 9a & 9b).

Using the references of the lower temporaries, the upper six denture teeth were set up establishing the overbite and overjet relationship (Figs. 10a & 10b). The set-up was checked in the mouth for esthetics and phonetics. Finally the complete upper set-up was done using the Pilkington-Turner anatomical teeth (Figs. 11a & 11b).

At this point, it was obvious that the laboratory technician will have an easier job developing the metal infrastructure as well as the ceramic build up to the denture teeth being used in the final overdenture, thus keeping all adjustments to a minimum [11].

Following the adjustment of the anterior table (Figs. 12a & 12b) in concordance with the posterior cuspal inclination, the lower metal infrastructure was completed (Fig. 13a & 13b).

Metal framework try-in

The posterior teeth were designed with metal occlusals in order to diminish wear of the opposing teeth. The metal used is a 52% gold palladium alloy (Figs. 14a, 14b, 14c & 14d).

The ceramic build-up was completed in respect to the anatomical requirements of the denture set-up as well

as the color of the chosen teeth. The final occlusal scheme developed was a bilateral balanced occlusion with no anterior guidance (Figs. 15a, 15b, 15c & 15d).

Final insertion

The lower crowns were cemented. All margins were left supra-gingival. There was no concern of esthetics since the smile-line didn't uncover the lower margins thus facilitating oral hygiene (Figs. 16a, 16b, 16c & 16d).

All prosthesis (upper and lower) were delivered at once (Figs. 17a, 17b & 17c), followed by a patient remount for occlusal refinement.

The patient was instructed on how to maintain the fixed and removable prosthesis and was put on a six months recall.

Discussion

When setting-up a treatment plan for a periodontally compromised case, it is often very difficult to come up with one ideal treatment that would provide a long-term longevity in terms of function and esthetics [12].

Minimal information is available for the long-term survival rates of fixed dental prosthesis (FDPs) and single crowns (SC) supported by implants in periodontally compromised patients [13].

Patients (especially the elderly) prefer conventional removable dental prosthesis (RDPs) for low cost, less complexity and time of treatment despite their unsatisfactory retention;

conventional FDPs provide a high level of satisfaction to patients. Although implant-supported restorations provide higher esthetic satisfaction, the high cost, complexity, time of treatment, and surgical risks limit their wide acceptance among patients [14].

The decision to use either implant- or tooth-supported restorations needs to be based on the available scientific evidence and oral and systemic conditions, including patient preference [15]. For these reasons, many parameters must be taken in consideration in this specific case: dental phobia, cost of the treatment, duration of the treatment as well as the age of the patient.

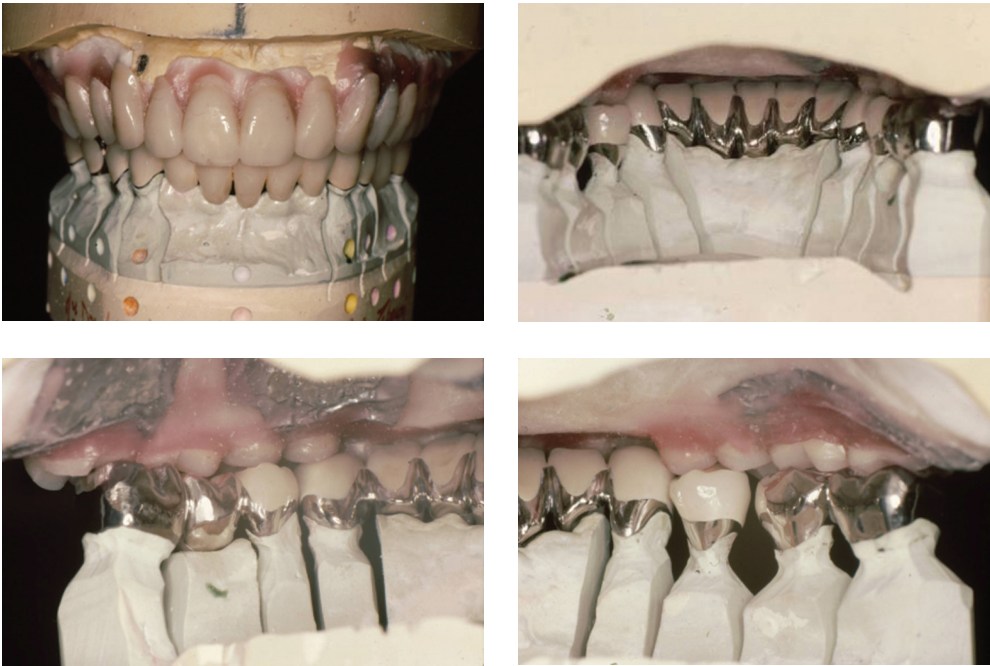
Orthodontics was ruled out, even though it would have facilitated the treatment, due to time constraints [16].

Implants were not considered due to financial limitations.

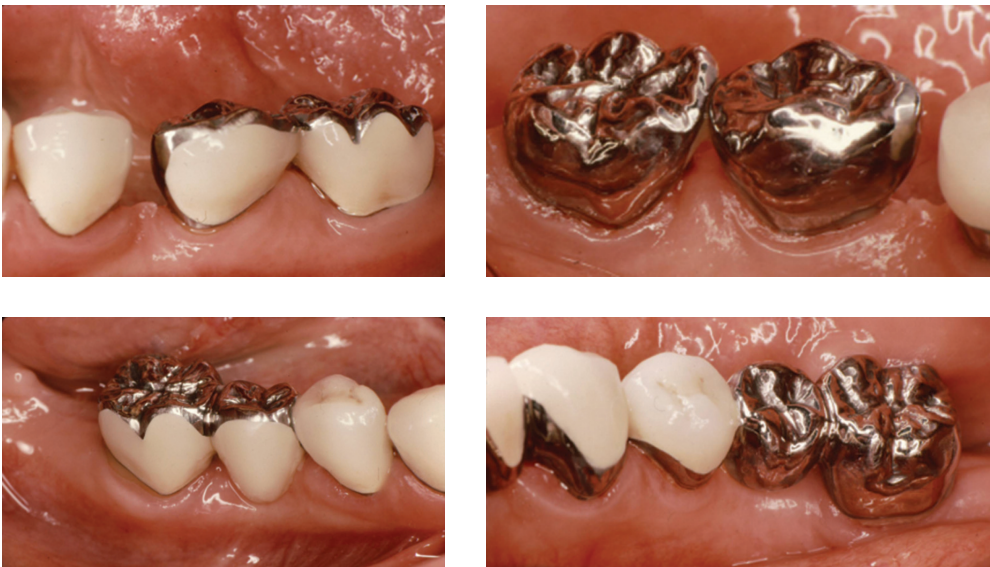Dental phobia was, at first, a serious problem but the patient became more cooperative as the treatment progressed.

The overdenture indication was best-suited for this patient. It is now well established that keeping the roots under an overdenture substantially reduces bone loss [17].

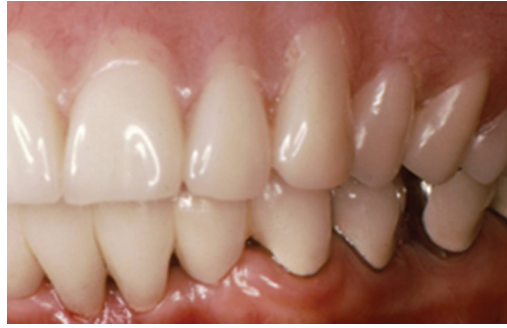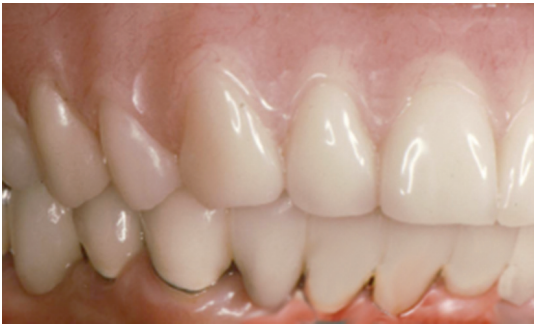The existing literature reviews provide limited evidence suggesting the use of RDPs with design modifications along with strict periodontal care in periodontal patients. Numerous systematic reviews on conventional FDPs and implant-supported restorations provide a moderate level of evidence favoring their survival in periodontal



Figs. 15a, b, c & d: Ceramic build-up versus the denture-teeth with respect to the occlusal parameters of a denture versus a fixed prosthesis.



Figs. 16a, b, c & d: Clinical view of the lower fixed prosthesis.



Figs. 17b, c: Bilateral balanced occlusion.

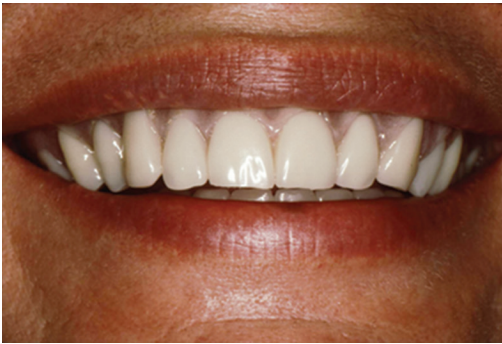

Fig.17a: The patient's smile.

patients; however, for long-term success of these restorations, the patient's periodontal condition needs to be stabilized. In terms of patient preference, no restoration is superior, as they are all governed by their cost, advantages, and disadvantages [15].

Conclusion

In view of large and complex cases, the key for success is a well-thought sequenced treatment plan. In totally broken-down dentitions, where all key parameters have been lost, it is essential to find the building stone where the reconstruction of the case should begin.

Following the first step, clinical and laboratory procedures will sequence one another in a methodical and logical way, the goal being to reach a functional and esthetical predictable outcome.

Long-term success of such prosthesis depends essentially on a good oral

hygiene and a strict recall and maintenance program [14].

Longitudinal studies with standardized treatment protocol and methodology are needed to evaluate and compare tooth-supported and implant-supported restorations in periodontal patients with regard to survival rates, cost, maintenance and patient-centered outcomes.

References

1. Interdisciplinary Treatment Planning. Principles, Design, Implementation. Michael Cohen, DDS, MSD. Quintessence books. Edition 2008. Fundamental treatment planning: Application of three basic Principles. Henry i. Nichols, DDS. pp.283.
2. Atlas de Médecine Dentaire. Prothèse adjointe totale et composite. Alfred H. Geering et Martin Kundert. Flammarion. V. Méthodologie particulière de traitement, pp.170-175.
3. Valaiti F, Belsler UC. Full-mouth adhesive rehabilitation of a severely eroded dentition: the three step technique. Part 2. Eur J Esteh Dent 2008;3:30-44.
4. Lussi A, Laeggi T. Erosion: diagnosis and risk factors. Clin Oral Investig 2008;12:S5-S13.
5. Milosevic A, O'Sullivan E. Diagnosis, prevention and management of dental erosion: summary of an updated national guideline. Prim Dent Care 2008;15:11-12.
6. Brezavšček M, Lamott U, Att W. Treatment planning and dental rehabilitation of a periodontally compromised partially edentulous patient: a case report - Part I. Int J Esthet Dent 2014;9(3):402-11.
7. Interdisciplinary Treatment Planning. Principles, Design, Implementation. Michael Cohen, DDS, MSD. Quintessence books. Edition 2008. Comprehensive interdisciplinary management of patients with missing and/ or abnormally proportioned teeth. Ward M. Smalley. DDS, MSD.
8. Fajri L, Bendfil F. Diagnostic et gestion des lésions d'origine prothétique de l'édenté total. Actualités odonto-stomatologiques 2008;243:225-238.
9. Pindborg JJ. Atlas des maladies de la muqueuse buccale. Ed Masson 1994.
10. Rossie K, Guggenheimer J. Oral candidiasis: clinical manifestations, diagnosis and treatment. Practical Periodontic and aesthetic dentistry 1997;9(6):635-641.
11. Atlas de Médecine Dentaire. Prothèse adjointe totale et composite. Alfred H. Geering et Martin Kundert. Flammarion. Edition 1988. Prothèse composite, p.153-156.
12. Brezavšček M, Lamott U, Att W. Treatment planning and dental rehabilitation of a periodontally compromised partially edentulous patient: a case report - Part I. Int J Esthet Dent 2014;9(3):402-11.
13. Dhingra K. Oral rehabilitation considerations for partially edentulous periodontal patients. J Prosthodont 2012;21(6):494-513.
14. Zitzmann NU, Krastl G, Walter C, et al. Strategic considerations in treatment planning: deciding when to treat, extract, or replace a questionable tooth. J Prosthet Dent 2010;104:80-91.
15. Brezavšček M, Lamott U, Att W. Treatment planning and dental rehabilitation of periodontally compromised partially edentulous patient: a case report - Part II. Int J Esthet Dent 2014;9(4):506-15.
16. Agarwal S, Gupta S, Chugh VK, Jain E, Valiathan A, Nanda R. Interdisciplinary treatment of a periodontally compromised adult patient with multiple missing posterior teeth. Am J Orthod Dentofacial Orthop 2014;145(2):238-48.
17. Carlsson G. Implant and root- supported overdentures - a literature review and some data on bone loss in edentulous jaws. J Adv Prosthodont 2014; 6:245-52.
18. Wolfart S, Weyer N, Kern M. Patient attendance in a recall program after prosthodontic rehabilitation: a 5-year follow-up. Int J Prosthodont 2012Sep-Oct; 25(5):491-6.