

# SENSORINEURAL HEARING LOSS IN THE OPPOSITE EAR FOLLOWING HEAD TRAUMA

Otology

Submitted : 24.11.2015

Accepted : 29.02.2016

Published : 29.02.2016

Ahmet Mahmut Tekin<sup>1</sup>, Erkan Soylu<sup>1</sup>, Gökhan Altın<sup>2</sup>, Fahrettin Yılmaz<sup>1</sup>, İlknur Haberal Can<sup>2</sup>

<sup>1</sup> Medipol Üniversitesi

<sup>2</sup> İstanbul Medipol Mega Üniversite Hastanesi

## Özet

### KAFA TRAVMASI SONRASI KARŞI KULAKTA SENSÖRİNÖRAL İŞİTME KAYBI

Kafa travması sonrası işitme kaybı sık karşılaşılan komplikasyonlardan biridir. Travma sonrasında bu şikayetlerle gelen bazı hastalarda sensörinöral işitme kaybı için labirent hasarını gösteren radyolojik bir bulgu saptanamamakla beraber altta yatan mekanizmanın kafa travmalarında sıklıkla rastlanan labirentin konküzyonu olduğu varsayılmaktadır. Bu yazıda kafa travması sonrası temporal kemik fraktürü olmadan karşı kulakta labirentin konküzyon nedeniyle işitme kaybı ve çift taraflı tinnitus gelişmiş bir olguyu sunduk.

**Anahtar kelimeler:** *Labirent konküzyonu, İşitme kaybı, Kafa travması*

## Abstract

### SENSORINEURAL HEARING LOSS IN THE OPPOSITE EAR FOLLOWING HEAD TRAUMA

Sensorineural hearing loss following the head trauma is one of the most common complications that might occur. Although radiological evidence that presents the labyrinth damage as sensorineural hearing loss in some patients complaining of these symptoms after the trauma; cannot be determined. The underlying mechanism is commonly assumed to be the concussion of the labyrinth that is frequently seen in head traumas. In this paper, we would like to present double-sided tinnitus and hearing loss that developed after the head trauma due to the concussion of the labyrinth in the opposite ear without temporal bone fractures.

**Keywords:** *Labyrinth concussion, Hearing loss, Head trauma*

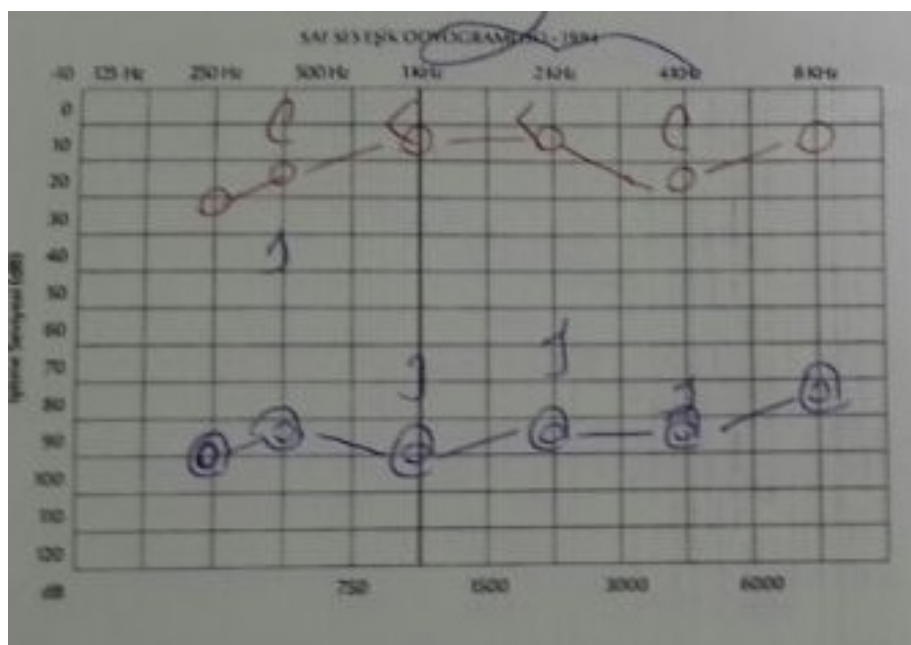
## Introduction

Sensorineural hearing loss that might occur after the head trauma is one of the most common complications in this process. [1]. The clinical view as a result of the head trauma requires a multidisciplinary approach concerning areas of expertise including neurosurgery, neurology, radiology, and otolaryngology. It is well-known that both conductive and sensorineural-type hearing losses might occur afterwards the head trauma. Complications that directly affect the inner ear such as vestibular and cochlear fractures, bleeding in the inner ear and direct damage of the nerve VIII manifest themselves through the vestibular and audiological symptoms [2]. Moreover, a radiological finding that presents labyrinth damage as the sensorineural hearing loss in some patients complaining of these symptoms after head traumas cannot be determined. The underlying mechanism is commonly assumed to be the concussion of the labyrinth that is frequently seen in head traumas in these patients [3]. The concussion of the labyrinth is defined as sensorineural hearing loss that may accompany vestibular symptoms as a result of the reflection of the intense pressure of the opposite ear without an open labyrinth fracture after the trauma [4]. Sensorineural hearing loss is characterized by high-frequency hearing loss that notches in the 4-6 kHz range like acoustic trauma [5]. A review of the literature revealed that the number of case reports of contralateral sensorineural hearing loss without temporal bone fracture is very rare. In this paper, we present double-sided tinnitus and hearing loss that developed after head trauma due to concussion of the labyrinth in the opposite ear

without temporal bone fractures.

## Case Report

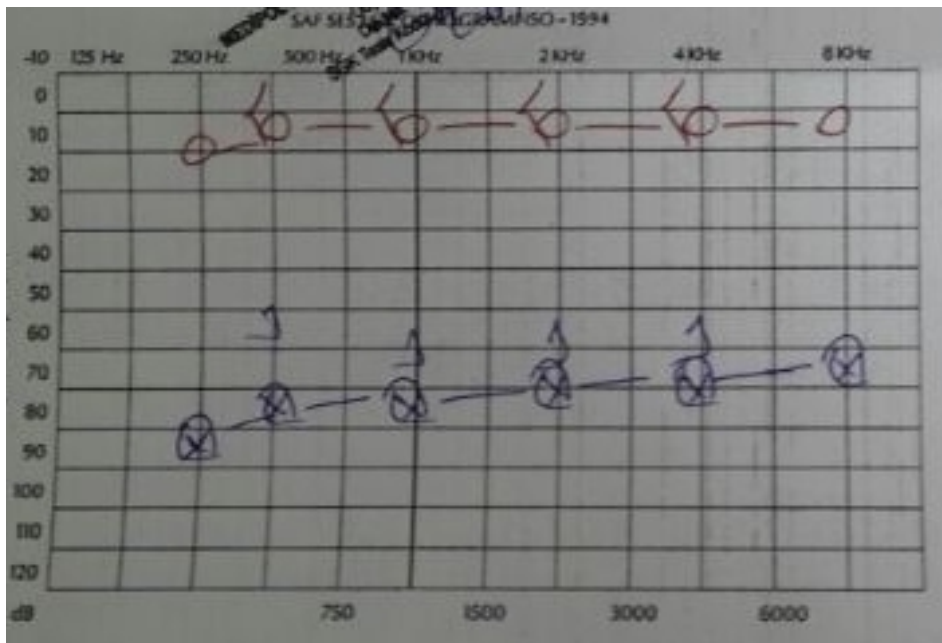
A 17-year-old male patient who we assumed did not have hearing loss in the left ear as he could use both ears while talking to the phone previously, was admitted to our clinical with complaints of hearing loss of the left ear and tinnitus in both ears as a consequence of a slap on the right ear. The external ear canal and tympanic membranes were normal according to the results of the otoscopy examination. No features were determined in the other ear, nose, throat, head and neck examination. The Weber test was lateralized to the right ear of the patient. According to the results of the pure tone audiometry examination, sensorineural hearing loss of 88db was revealed in the left ear (Figure 1).



**Figure 1**

Pre-treatment hearing test

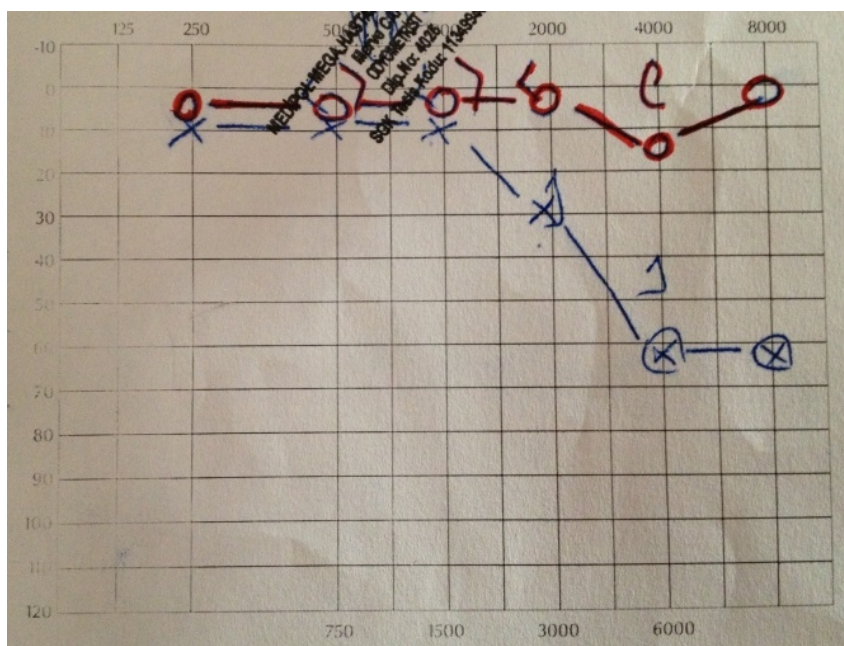
Neither temporal bone fractures nor hemorrhage in the middle ear were detected in the temporal bone CT scan of the patient. Neurological injury was not also detected in the inner ear or cranial region according to the MR images. The methylprednisolone (1 mg/kg/day, reduced gradually), plasma extender (low molecular weight dextran 500 ml/day), vitamin B1, vitamin B6, vitamin B12 complex (500 mg/day), and aspirin (100 mg/day) were administered, and hyperbaric oxygen therapy was provided to the patient. Pure tone audiometry was performed after three days of treatment of the patient. Seventy-three dB sensorineural hearing loss was observed in the left ear (Figure 2).



**Figure 2**

Hearing test after the 3 daily treatment with hyperbaric oxygen therapy and steroids application.

After the patient received 20 sessions of hyperbaric oxygen therapy, pure tone audiometry has repeated. In conclusion, improvement was observed in the low frequencies in the left ear, and 65dB sensorineural hearing loss at high frequencies was found (specify the pure tone average). A hearing aid was not implemented because there were no problems with hearing while interacting with people (Figure 3).



**Figure 3**

Post-treatment hearing test.

## Discussion

As we can see in the clinical view, partial or total hearing loss occurs in the vast majority of patients with head

injuries. Hearing loss has been reported between the rates 15-66 % following the head trauma in adult case studies in literature [6]. As a study that was performed in the pediatric population, Williams et al. reported that 22 of 25 patients with head trauma; have experienced hearing loss [7]. Temporal bone trauma as a result of the head traumas can cause hearing loss more frequent than expected. In temporal bone trauma, hearing loss can occur in both ears in which trauma occurred, as well as the opposite ear [8]. Although hearing loss as a result of temporal bone trauma is frequently accompanied by temporal bone fractures, also some cases have been reported with the absence of a temporal bone fracture [9]. Given the basic classification of temporal bone fractures, longitudinal temporal bone fractures are the most common causes of hearing loss after head trauma. The external auditory canal, tympanic membrane, and ossicular damage can be frequently seen in longitudinal temporal bone fractures; therefore, conductive hearing loss is often detected in these cases. The type of hearing loss is sensorineural in transverse bone fractures, as trauma mostly affects the labyrinth [10]. In a published case series by Griffith et al., sensorineural hearing loss was seen in 66 of 84 head injury patients without temporal bone fractures. Conductive hearing loss was observed in only seven patients, and they were included in the aforementioned study [11]. The finding of head trauma was not detected in the current patients and sensorineural hearing loss developed on the opposite side of trauma. Opposite side post-traumatic hearing loss was reported in both traumas with or without temporal bone fractures. Sensorineural hearing loss on the opposite side was observed in three patients with unilateral temporal bone fractures in a series reported by Uluğ et al. [8]. Similar to our case, Toh et al. published a case with sensorineural hearing loss on the opposite side that did not have temporal bone fractures [9]. Although, the causes of hearing loss that developed in these patients - who were observed to have opposite side hearing loss- was more than the same side hearing loss which is not specifically known, thereupon labyrinth concussion may be the underlying basic mechanism. The authors consider the concussion of the labyrinth as a cause of hearing loss in this case.

In conclusion, if there are any symptoms such as tinnitus, hearing loss, and dizziness in patients admitted to the clinic after assault, hearing tests should be requested and a possible hearing loss should be diagnosed even if the otoscopic examination is normal.

## References

1. Segal S, Eviatar E, Berenholz L, Kessler A, Shlamkovitch N. Dynamics of sensorineural hearing loss after head trauma. *Otology & Neurotology* 2002 May;23(3):312-5.
2. Fitzgerald DC. Head trauma: hearing loss and dizziness. *The Journal of Trauma*. 1996 Mar;40(3):488-96.
3. Mohd Khairi MD, Irfan M, Rosdan S. Traumatic head injury with contralateral sensorineural hearing loss. *Ann Acad Med Singapore*. 2009 Nov;38(11):1017-8.
4. Canalis Rf, Lambert Pr *The Ear : Comprehensive Otolaryngology*. Philadelphia : Lippincott Williams & Wilkins ;1999 p.795-6.
5. Sakallıoğlu, Ö., Polat, C., Soylu, E., Orhan, İ., Altınsoy, H. B. Contralateral profound hearing loss after head trauma: *Türk Otolarengoloji Arşivi* 2011; 49(3); 58-60
6. Kochhar, L.K.,Deka, R:C.,Kacker ,S.K., et al.:Hearing Loss After Head Injury.*Ear Nose Throat Journal* 1990,69:537-540
7. Williams, W. T., Ghorayeb, B. Y., & Yeakley, J. W. (1992). Pediatric temporal bone fractures. *The Laryngoscope*, 102(6), 600-603.
8. Uluğ, T., & Ulubil, S. A. . Contralateral labyrinthine concussion in temporal bone fractures. *The Journal of otolaryngology*, 2006 35(6), 380-383.
9. Toh A, Ho EC, Turner N Contralateral deafness post head injury without temporal bone fractures *Am J Otolaryngol*. 2010 Jan-Feb;31(1):54-6.
10. Schuknecht, H. F., & Davison, R. C. Deafness and vertigo from head injury. *AMA archives of otolaryngology*, 195663(5), 513-528.
11. Griffiths MV. The incidence of auditory and vestibular concussion following minor head injury. *Journal of*

Laryngology and Otology 1979; 93: 253-26.