

## A PROSPECTIVE STUDY COMPARING CONCURRENT CHEMORADIATION WITH OR WITHOUT GEFITINIB IN TREATMENT OF LOCALLY ADVANCED HEAD AND NECK CARCINOMA

BISWARUP BANERJEE, SUMITAVA DE\*, LINKON BISWAS, SRIKRISHNA MANDAL

Department of Radiotherapy, Nil Ratan Sircar Medical College and Hospital, Kolkata, West Bengal, India. Email: drsumitava@gmail.com

Received: 21 January 2022, Revised and Accepted: 30 February 2022

### ABSTRACT

**Objective:** Concurrent chemoradiotherapy (CTRT) is now an acceptable definitive therapy for locally advanced head and neck carcinomas. However, multiple studies revealed that addition of anti-Epidermal growth factor receptors agent with CTRT improves the loco-regional response at a cost of higher but acceptable toxicity. Our study aimed at assessing CTRT with or without Gefitinib in terms of treatment response and acute toxicity profile.

**Methods:** Patients with locally advanced, non-metastatic, squamous cell carcinoma of Head-neck were randomized in two groups-the control group received external beam radiotherapy (RT) 66 Gy/33 fractions/6.5 weeks along with concurrent injection Cisplatin at the dose of 100 mg/m<sup>2</sup> on days 1, 22, and 43 during radiation and the study group received CTRT along with Tab Gefitinib-250 mg during the duration of RT. Response assessment was done after completion of treatment and all patients were followed up for treatment related acute toxicity during the course of treatment and then at every month for at least 6 months.

**Results:** About 46.66% of study arm (CTRT+Gefitinib) patients showed complete response (CR) and overall response was 79%. In control arm (CTRT alone), there was 51.6% CR and overall response was 77%, though difference was statistically not significant (p=0.84). Although statistically not significant, Gefitinib containing arm had numerically higher hematological, gastro-intestinal toxicity, and weight loss.

**Conclusion:** Gefitinib along with chemoradiation showed numerically higher overall response (CR+partial response) and comparable acute toxicity profile in comparison to chemoradiation alone.

**Keywords:** Concurrent chemoradiation, Gefitinib, Head and Neck Carcinoma.

© 2022 The Authors. Published by Innovare Academic Sciences Pvt Ltd. This is an open access article under the CC BY license (<http://creativecommons.org/licenses/by/4.0/>) DOI: <http://dx.doi.org/10.22159/ajpcr.2022v15i4.44177>. Journal homepage: <https://innovareacademics.in/journals/index.php/ajpcr>

### INTRODUCTION

World-wide nearly 650,000 people develop Head and Neck Cancer (HNC) each year and there are 350,000 deaths from this disease. In India, cancers of lip and oral cavity constitute the second most common cancer (10.3%) according to GLOBOCAN 2020 data [1]. Concurrent chemo-radiation (CTRT) has emerged as an acceptable definitive treatment for locally advanced carcinoma of head and neck region [2]. Robust and mature data from various randomized studies and meta-analysis of chemotherapy in head and neck cancer have favored platinum based chemo-radiation [3]. Recently updated meta-analysis by Blanchard *et al.* demonstrated the benefit of the addition of chemotherapy in terms of overall survival (OS) in head and neck squamous cell carcinoma. The 5-year absolute benefits associated with concomitant chemotherapy are 8.9%, 8.1%, 5.4%, and 4%, respectively, for oral cavity, oropharynx, larynx, and hypopharynx, respectively.

Epidermal growth factor receptors (EGFR) which are abundantly expressed by squamous cell carcinoma of head and neck region promotes a multitude of important signaling pathways associated with cancer development and progression and importantly, resistance to radiation [4,5]. Since radiotherapy (RT) plays an integral role in managing HNC, inhibiting the EGFR pathway along with it might improve the cancer cure.

A study done by Bonner *et al.* demonstrated that concomitant RT plus Cetuximab, an EGFR specific antibody, improved the loco-regional control (LRC), disease free survival (DFS), and OS in locally advanced head-neck cancer patients [6]. Another drug Gefitinib works as potent and specific EGFR tyrosine kinase inhibitor (TKI). Addition of Gefitinib to first line combined modality therapy for patients with locally advanced head and neck carcinoma, increased the incidences of Grades 3 and 4 mucositis and diarrhea during the therapy but did improve the progression free survival and OS.

However, there is paucity of studies specifically in Indian population where squamous cell carcinoma of head and neck region is a very common cancer. In this background, the objective of our study was to compare the effect of Gefitinib plus cisplatin based chemoradiation with that of CTRT alone on the therapeutic response and acute toxicity profile in the treatment of locally advanced head and neck carcinoma.

### METHODS

It was a double arm, single institutional prospective, comparative study in patients with locally advanced (T3-4, N0, M0 and any T, N1-3, M0) squamous cell carcinoma of oropharynx, hypopharynx, and larynx aged between 18 and 70 years having adequate hepatic, renal, hematological parameters, and an Eastern Cooperative Oncology Group ECOG score of 0-2. Patients with recurrent carcinoma, the previous history of any other malignancy or chemotherapy or RT, were excluded. The study was conducted between January 2019 and January 2020.

#### Study technique

Patients were selected using above mentioned inclusion and exclusion criteria and randomized into two groups

#### Control ARM (CTRT)

Participants in this arm received external beam RT (EBRT) with conventional 2 Gy/fraction, 5 days a week, for about 6.5 weeks up to total dose of 66 Gy along with concomitant injection Cisplatin at the dose of 100 mg/m<sup>2</sup> of body surface area (BSA) on days 1, 22, and 43 (3 weekly) during radiation.

#### Study ARM (CTRT with Gefitinib)

Patients in this arm received a total dose of 66 Gy in conventional fractionation like control arm with concurrent injection cisplatin (100 mg/m<sup>2</sup>) 3 weekly along with Tab Gefitinib-250 mg during the entire duration of RT.

**RT technique**

Dental checkup and procedures were completed at least 2–3 weeks before the date of commencement of RT as pre-RT dental prophylaxis.

RT delivered by means of conventional 2D planning using “Theratron 780E” telecobalt machine with Conventional Two-phase planning –

**Phase I**

Total 44 Gy in 22 fractions over 4.5 weeks in conventional fractionation given.

Two lateral parallel opposed facio-cervical fields including the primary and draining lymph node groups were used to deliver EBRT in Phase I.

**Phase II**

Dose of 22 Gy in 11 fractions over 2 weeks in conventional fractionation is given.

Two parallel opposed facio-cervical fields were used here also. However, here the posterior border of the lateral facio-cervical fields was shifted from tip of mastoid process to tragus to spare the spinal cord (OFF CORD).

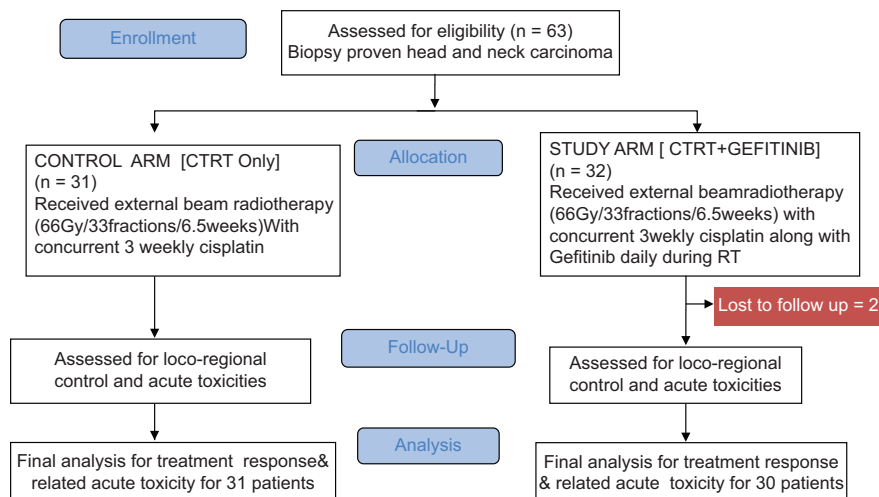
Response assessment was done using RECIST1.1 after completion of treatment. All patients were followed up weekly for treatment related acute toxicity during the entire course of treatment and then at every months for 6 months for each patient after completion of treatment. Follow-up included proper history of complaints, clinical examination, CBC, LFT, KFT parameters, and other necessary investigations as indicated including imaging. Treatment related toxicities were assessed as per toxicity assessment tools-CTCAE (Common terminology criteria for adverse events scale v5.0) and with radiation therapy oncology group (RTOG) scoring. Patients developing Grade III or above toxicity were given treatment interruption and were managed as required. Patients with progressive disease were managed with chemotherapy or surgery as per requirement.

Approval for study was taken from institutional ethics committee.

There is no source of financial grant or other funding.

**Statistical analysis**

Data were analyzed and compared according to appropriate statistical tests using SPSS v.20 software and Microsoft word-excel. Data were summarized as mean and standard deviation for numerical variables and count and percentages for categorical variables. Unpaired proportions were compared by Chi-square test or Fisher’s exact test, as appropriate. Any  $p < 0.05$  will be considered statistically significant.

**RESULTS****Consort diagram**

Patients were comparable in terms of age, gender, performance status, site of primary disease, stage of disease at presentation between the two arms of the study.

At the end of EBRT, study arm showed overall response (complete response [CR]+partial response [PR]) in 80% (26.66% showed CR and 53.33% showed PR) of the participants. In control arm 13 (41.9%) showed CR and 14 (45.16%) showed PR making the overall response around 87%.

However, at the end of 6 month follow-up, in the study arm 14 patients (46.66%) showed CR and 10 pt (33%) showed PR, overall response was 79%. In control arm, there was 51.6% CR (16 patients) and 25.8% PR. Overall response was 77%. Although numerically more patients showed overall response in study arm (CIRT+Gefitinib), the difference is statistically insignificant ( $p=0.84$ ) (Table 2).

**Toxicity comparison**

About 50% of patients in the study arm showed Grade 2 skin toxicity in comparison to 45% in control arm (Table 3).

Grade 3 toxicity was numerically higher in control arm, but these differences are not statistically significant ( $p=0.66$ ).

Grade 1 mucosal toxicity was higher (29% vs. 16%) in control arm whereas Grade 2 and Grade 3 mucosal toxicity was numerically higher in study arm. However, these differences were not statistically significant (Fig 1).

Grade 2 xerostomia was numerically higher in control arm. However, the difference was not statistically significant ( $p=0.967$ ) (Table 4).

Acute pharyngeal and acute laryngeal toxicity profiles were comparable between the chemoradiation and chemoradiation with Gefitinib.

During treatment, around 23.33% of study arm patients suffered from Grade 3 diarrhea in comparison to 12.9% of control arm. About 74.19% of only CIRT patients had no incidence of diarrhea compared to 66.6% in Gefitinib containing arm. But, this higher incidence of diarrhea in patients treated with Gefitinib along with CIRT is not statistically significant ( $p=0.902$ ) (Fig 2).

During treatment 58% of patients in the study arm lose 5–10% of their body weight compared to 6% in control arm. Most of the control arm patients (93%) loose <5% of body weight. This difference was not statistically significant ( $p=0.973$ ).

Incidence of both Grade 2 and Grade 3 anemia are higher in study arm patients receiving CIRT with Gefitinib. However, this difference was not statistically significant ( $p=0.959$ ) (Table 5).

Grade II leukopenia (6% vs. 0%) and neutropenia (10% vs. 3%) were numerically higher in Gefitinib containing arm, but this finding was not statistically significant (p=0.97) (Table 6).

**DISCUSSION**

In attempt to improve the therapeutic outcome, CRTT was introduced where chemotherapy acts as a radio sensitizer. The combination of chemotherapy and radiation may improve the local control and survival rate because of synergistic effect of chemoradiation [7]. Targeted therapy against EGFR receptors commonly expressed by squamous cell carcinoma of head and neck was used in this study along with CRTT. Standard CRTT with or without Gefitinib was compared here in terms of local control and acute toxicity profile.

The mean age of the patients in study arm was 54.83 years and in control arm 56.02 years (Table 1). According to available literature, the most common age for development of HNC is 5<sup>th</sup>-6<sup>th</sup> decade in India[8]. The mean age of our study population thus corresponds to the existing data for Indian Population. The lowest age of presentation was

**Table 1: Distribution of baseline characteristics**

Characteristics	Arm of the study		Total	p-value
	Control arm (n=31)	Study arm (n=30)		
Mean age	56.02 years	54.83 years	61	0.73
Gender				
Male	26	25	61	0.975
Female	5	5		
Total	31	30		
Primary site of disease				
Larynx	17	14	61	0.805
Oropharynx	11	12		
Hypopharynx	3	4		
Total	31	30		
Stage of disease at presentation				
Stage III	18	16	61	0.601
Stage IV (non-metastatic)	13	14		
Total	31	30		
Performance status (eastern cooperative oncology group score)				
0	02	01	61	0.934
1	18	17		
2	11	12		
Total	31	30		

34 years and the maximum age at presentation was at 70 years in our study. Around 83% of patients were male in both the arms of this study, echoing the fact that the incidence of head neck carcinoma is more in men than women.

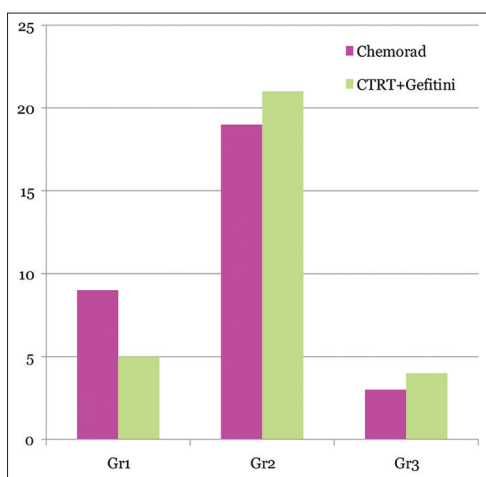
Local response rates were assessed using the RECIST1.1 at 1 month after completion of the External Beam Radiation treatment and then monthly for 6 months. At the end of 6 month follow-up, in the study arm 46.66% patients showed CR and 33% showed PR, overall response was 79%. In control arm, there was 51.6% CR and 25.8% PR. Overall response was 77%. Although numerically more patients showed overall response in study arm (CRTT+Gefitinib), the difference is statistically not significant (p=0.84).

Preclinical studies strongly suggested that the combination of Gefitinib and RT completely inhibited the downstream signaling of EGFR and had a strong inhibitory effect on DNA-PK pathways [9]. A study by Saini *et al.* compared Cisplatin based CRT with Cisplatin and Gefitinib based CRT in locally advanced squamous cell carcinoma of head neck carcinoma. Out of 67 patients randomized, 32 patient was in CRT arm (Arm I) and 35 in CRT+Gefitinib (ArmII). Overall response rate (CR+PR) was 62% and 71.42% in arm I and arm II, respectively. However, the difference was statistically not significant (p=0.605). The median PFS was 24 months in ArmI while 35 months in Arm II (p=0.287). The median survival was 31 months for arm I and 37 months for Arm II (p=0.4344). Proliferative disease showed trend toward significance in terms of response but could not reach the level of significance (p=0.086) [10].

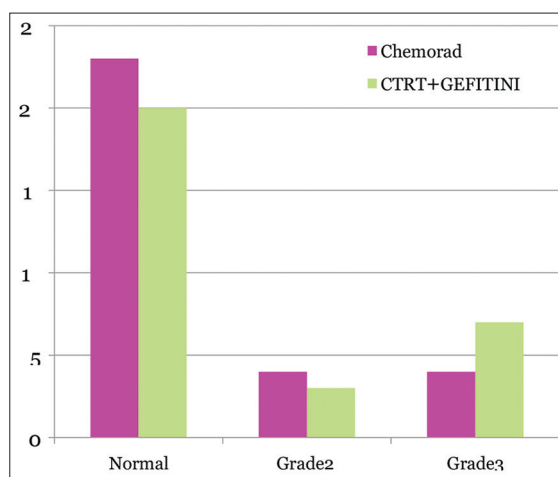
Another study by Pal *et al.* who was a prospective controlled trial of concurrent CRT versus concurrent CRT plus Gefitinib in locally advanced squamous cell carcinoma of head and neck. The study was done in 2011-12 enrolling 64 patients in study and control arm. About 29.03% patients achieved CR in control arm while 36.67% achieved CR in study arm. The difference was not statistically significant (p=0.5255). Total number of patients achieved overall response (CR+PR) in control arm was 61.29% and it is 76.23% in study arm. However, it was not statistically significant (p=0.1947) [11].

The skin toxicity and acute xerostomia of higher grade (Grade 2 and Grade 3) were numerically higher in control arm though statistically insignificant. Acute pharyngeal, laryngeal, and mucosal toxicities were comparable in both the arms of study.

On the other hand, although statistically insignificant the Grade 2 and Grade 3 hematological toxicity like anemia, neutropenia was higher in Gefitinib containing study arm than chemo-radiation only control arm (p=0.95). Occurrence of Grade 3 diarrhea and weight loss of >5% was also numerically higher in Gefitinib containing study arm. However, all these differences were statistically insignificant.



**Fig. 1: Comparison of acute mucositis between the two arms**



**Fig. 2: Comparison of diarrhea between two arms**

Table 2: Comparison of treatment response between the two arms

Response (during RT and monthly follow-up)	Study arm (number of patients)							Control arm (number of patients)							p-value
	During RT	F/u 1	F/u 2	F/u 3	F/u 4	F/u 5	F/u 6	During RT	F/U 1	F/U 2	F/U 3	F/U 4	F/U 5	F/U 6	
Complete response	8	7	11	9	16	13	14	13	18	17	17	16	16	16	0.87 during RT 0.86 F/U1
Partial response	16	14	12	11	5	10	10	14	8	7	7	8	8	8	
Stable disease	3	3	3	3	2	3	2	2	2	2	3	4	3	2	0.88 F/U3
Progressive disease	3	6	4	7	7	4	4	2	3	4	4	3	4	5	0.88 F/U4
															0.80 F/U5
															0.84 F/U6

Table 3: Comparison of acute skin toxicity between two arms

Arm of study	Skin toxicity			Total	p-value
	Grade 1	Grade 2	Grade 3		
Study	11	15	4	30	0.666
Control	12	14	5	31	
Total (n)	23	29	9	61	

Table 4: Comparison of xerostomia between the two arms

Arm of study	Xerostomia			Total	p-value
	Grade 1	Grade 2	Grade 3		
Study	10	20	0	30	0.967
Control	10	21	0	31	
Total (n)	20	41	0	61	

Table 5: Comparison of anemia during treatment

Arm of study	Anemia during treatment				Total	p-value
	Grade 0	Grade 1	Grade 2	Grade 3		
Study	3	16	08	03	30	0.959
Control	5	18	06	02	31	
Total (n)	8	34	14	5	61	

Table 6: Comparison of other hematological toxicities

Parameter	Arm	Toxicity grade			p-value
		Grade 0	Grade I	GradeII	
Total leukocyte count	Control	26	04	0	0.975
	Study	23	06	02	
Absolute neutrophil count	Control	27	02	01	0.977
	Study	24	04	03	
Platelet count	Control	27	03	0	0.978
	Study	26	04	01	

The reason behind this increased high grade hematological toxicity, weight loss, and diarrhea among Gefitinib containing arm is the systemic toxicity of Gefitinib. Myelosuppressive effect of Gefitinib caused the hematological toxicity whereas it is effect on gastro-intestinal mucosa resulted in higher incidence of diarrhea.

Overall the addition of Gefitinib to concurrent cisplatin based chemoradiation was found to be well tolerated in our study. Chen *et al.* revealed that Gefitinib was well tolerated with concomitant boost RT or CTRT with weekly cisplatin [12]. The addition of Gefitinib associated with moderate increase in toxicity. Although the regimen

was efficacious, the survival results overlap with results reported with chemoradiation alone.

However, there are certain limitations in this study. At first, the sample size was small. Second, it was a single institutional study; hence, results derived cannot be extrapolated on entire population. Entire study duration was almost 12 months including patient accrual, intervention, and assessment. Hence, the late toxicity profile, DSF/progression-free survival, OS, late toxicities, and quality of life after treatment cannot be assessed appropriately.

## CONCLUSION

The aim of the study was to compare the outcome of chemoradiation with or without Gefitinib in terms of loco-regional response and acute toxicity profile among the patients with squamous cell carcinoma of head-neck region. Although statistically insignificant, the study arm containing Gefitinib along with chemoradiation showed numerically higher overall response (CR+PR) and comparable acute toxicity profile in comparison to chemoradiation alone. Further studies with large sample size and longer follow-up are necessary to ascertain whether or not Gefitinib along with CTRT is a better alternative of conventional CTRT now used.

## ACKNOWLEDGMENT

We acknowledge the assistance of Department of RT, NRS Medical College and Hospital in undertaking this study. We are also grateful to the patients who participated in our study.

## CONFLICTS OF INTEREST

None of the authors had any conflict of interest to declare.

## AUTHORS' CONTRIBUTION

Dr. Biswarup Banerjee, Dr. Sumitava De designed and conducted the research and finalize the manuscript; Dr. Linkon Biswas and Dr. Srikrishna Mandal did the literature review, statistical analysis, interpretation of data, reviewing and editing of the manuscript.

## AUTHORS' FUNDING

None.

## REFERENCES

- Sung H, Ferlay J, Siegel RL, Laversanne M, Soerjomataram I, Jemal A, *et al.* Global cancer statistics 2020: GLOBOCAN estimates of incidence and mortality worldwide for 36 cancers in 185 countries. *CA Cancer J Clin* 2021;71:209-49. doi: 10.3322/caac.21660, PMID 33538338
- Fu KK. Combined-modality therapy for head and neck cancer. *Oncology (Williston Park)* 1997;11:1781-90. PMID 9436185
- Pignon JP, le Maitre A, Maillard E, Bourhis J, MACH-NC Collaborative Group. Meta-analysis of chemotherapy in head and neck cancer (MACH-NC): An update on 93 randomised trials and 17,346 patients. *Radiother Oncol* 2009;92:4-14. doi: 10.1016/j.radonc.2009.04.014, PMID 19446902

4. Perisanidis C. Prevalence of EGFR tyrosine kinase domain mutations in head and neck squamous cell carcinoma: Cohort study and systematic review. *In Vivo* 2017;31:23-34. doi: 10.21873/invivo.11020, PMID 28064216
5. Smilek P, Neuwirthova J, Jarkovsky J, Dusek L, Rottenberg J, Kostrica R, et al. Epidermal growth factor receptor (EGFR) expression and mutations in the EGFR signaling pathway in correlation with anti-EGFR therapy in head and neck squamous cell carcinomas. *Neoplasma* 2012;59:508-15. doi: 10.4149/neo\_2012\_065, PMID 22668015
6. Bonner JA, Harari PM, Giralt J, Azarnia N, Shin DM, Cohen RB, et al. Radiotherapy plus cetuximab for squamous-cell carcinoma of the head and neck. *N Engl J Med* 2006;354:567-78. doi: 10.4149/neo\_2012\_065, PMID 22668015
7. Lawrence TS, Blackstock AW, McGinn C. The mechanism of action of radiosensitization of conventional chemotherapeutic agents. *Semin Radiat Oncol* 2003;13:13-21. doi: 10.1053/srao.2003.50002, PMID 12520460
8. Siddiqui MS, Chandra R, Aziz A, Suman S. Epidemiology and histopathological spectrum of head and neck cancers in Bihar, a state of Eastern India. *Asian Pac J Cancer Prev* 2012;13:3949-53. doi: 10.7314/apjcp.2012.13.8.3949, PMID 2309849
9. Shintani S, Li C, Mihara M, Terakado N, Yano J, Nakashiro K, et al. Enhancement of tumour radioresponse by combined treatment with gefitinib (Iressa, ZD 1839) an epidermal growth factor receptor tyrosine kinase inhibitor, is accompanied by inhibition of DNA damage repair and cell growth in oral cancer. *Int J Cancer* 2003;107:1030-7. doi: 10.7314/apjcp.2012.13.8.3949, PMID 2309849
10. Saini SK, Srivastava S, Dixit AK. Gefitinib with concurrent chemoradiation in locally advanced head neck cancer. *Gac Mex Oncol* 2016;15:138-44. doi: 10.1016/j.gamo.2016.04.002
11. Bhattacharya B, Adhikary S, Basu J, Pal S, Chattopadhyay B, Ghosh T. A prospective randomised controlled trial of concurrent chemoradiation versus concurrent chemoradiation along with gefitinib in locally advanced squamous cell carcinoma of head and neck. *Clin Cancer Investig J* 2014;3:146-52. doi: 10.4103/2278-0513.130160
12. Chen C, Kane M, Song J, Campana J, Raben A, Hu K, et al. Phase I trial of gefitinib in combination with radiation or chemoradiation for patients with locally advanced squamous cell head and neck cancer. *J Clin Oncol* 2007;25:4880-6.