

TO EVALUATE THE MORPHOLOGICAL AND MORPHOMETRIC FEATURES OF ADULT HUMAN CADAVERIC RIGHT LUNG IN NORTH INDIAN POPULATION

KULBIR KAUR¹, RAJAN KUMAR SINGLA², VANDANA SIDHU^{1*}, RAVI KANT SHARMA¹

¹Department of Anatomy, Government Medical College, Amritsar, Punjab, India. ²Department of Anatomy, Government Medical College, Patiala, Punjab, India. Email: vandanasidhu71@gmail.com

Received: 29 December 2021, Revised and Accepted: 10 February 2022

ABSTRACT

Objectives: In the present study, different morphological and morphometric features of adult human cadaveric right lungs were observed and noted on the predesigned pro forma. Not much of such measurements have been done in the past. The mean values and standard deviations are calculated. The data thus obtained were tabulated scrutinized, analyzed, and compared with the earlier studies wherever possible. If any variant from the normal is observed, an attempt has been made to explain the same on ontogenic or phylogenetic basis.

Methods: The present study has been conducted on 50 adult human cadaveric right lungs obtained from embalmed cadavers, used for dissection in the department of Anatomy, Govt. Medical College, Amritsar, formed the material for the current study.

Results: Majority of the lungs (49 [98%]) were spongy in texture while 1 (2%) lung was firm to touch. It is evident that majority of lungs depicted mottling in the form of black, brown or grey in color in 38%, 28%, and 26% of the specimens, respectively. A complete grey, brown, or brownish black color was seen in 2% lungs each. In one lung yellow mottling was seen which could be because of fat deposition. Length of posterior border (19.9cm) was more as compared to anterior border (17.8 cm). Lungs were measured both along lateral and medial surfaces. Along the lateral surface its mean value was 18.52±3.178 cm (Range 12–25 cm) while along medial surface its mean value was 15.11±2.241 cm (Range 9–23 cm). The mean AP width of right lung at center was 11.05±2.864 cm (Range 7–23 cm) and along inferior border was 13.26±2.743 cm (Range 9–20 cm). The mean mediolateral width was found to be 7.536±2.318 cm with range being 4–15.2 cm.

Conclusion: Knowledge of normal measurements of lungs and their variations may help cardiothoracic surgeons to avoid undue complications during surgery. Furthermore, it may help radiologist to resolve perplexed radiographic findings.

Keywords: Lungs, Morphology, Morphometry.

© 2022 The Authors. Published by Innovare Academic Sciences Pvt Ltd. This is an open access article under the CC BY license (<http://creativecommons.org/licenses/by/4.0/>) DOI: <http://dx.doi.org/10.22159/ajpcr.2022v15i3.44007>. Journal homepage: <https://innovareacademics.in/journals/index.php/ajpcr>

INTRODUCTION

The lungs are the essential organs of respiration. They are situated on either side of the heart and other mediastinal contents. Each lung is free in its pleural cavity, except for its attachment to the heart and trachea at the hilum. When removed from the thorax; a fresh lung is spongy, can float in water, and crepitates when handled, because of the air within its alveoli. Exchange of gases is accomplished in the mosaic of specialized cells that form millions of tiny, exceptionally thin-walled air sacs called alveoli [1]. It is also highly elastic and so it retracts on removal from the thorax. Its surface is smooth and shiny and is separated by fine, dark lines into numerous small polyhedral domains, each crossed by numerous finer lines, indicating the areas of contact between its most peripheral lobules and the pleural surface [2-4].

At birth the lungs are pink, but in adults they are dark grey and patchy mottled. As age advances this maculation becomes black, as granules of inhaled carbonaceous material are deposited in the loose connective tissue near the lung surface. The effects of this inhalation of soot and dust containing carbonaceous material have become a serious problem of industrial hygiene in mines and factories and of public health in large cities [2,6]. This darkening is often more marked in men than women, in those who have dwelt in industrial areas and in smokers. The posterior pulmonary border is usually darker than the anterior. In the upper, less movable parts of the lung, this surface pigmentation tends to be concentrated opposite the intercostal spaces.

Similarly costal surface is much darker than mediastinal surface or base, while the surface within the fissures is the lightest of all. These facts led

Huber [5]. To assume that pigmentation seems to be more in the places most accessible to light. Lungs from fetuses or stillborn infants who have not respired differ from those of infants who have taken a breath in that they are firm like liver, non-crepitant and sink in water. It is only when air and an increased supply of blood are introduced into the lung with first inspiration that it assumes the characteristic soft, spongy and, and buoyant qualities [2,6].

The adult right lung usually weighs 625 g and the left 565 g, but the range of wet weights is considerable, not least because it reflects the amount of blood or serous fluid contained within the lungs when weighed. In proportion to body stature, the lungs are heavier in men than in women [2,6].

METHODS

Material for the present study comprised right lungs obtained from 50 well embalmed adult human cadavers of both the sexes dissected in the Department of Anatomy, Govt. Medical College, and Amritsar. The lungs were removed from the cadavers as per the guidelines in Cunningham's Manual of Practical Anatomy [7] taking special precautions so as to preserve all the vessels, bronchi, and ligaments at the hilum. Different morphological features were noted, and measurements were taken as per the attached pro forma. Following instruments were used for this purpose,

1. Graduated metric scale.
2. Unbranded silk thread-for measuring various curved distances.
3. Vernier caliper-to measure diameter, lengths, and depths.
4. Indian ink.
5. A pair of fine forceps.

All the observations were recorded on the pro forma and were scrutinized and analyzed.

Observation

General features

These were observed as follows:

1. Shape of the lung was noted whether it was conical or any other shape.
2. Texture of the lung was noted by pressing the lung between the two hands whether the texture was spongy or hard.
3. Color of the lung was noted by gross examination whether it was pink, brown, grey, black, mottled grey, mottled black, or any other color.
4. Length (Apex to Base) was measured on the lateral as well as on the medial surface.
 - a. Length along Lateral surface: On the lateral surface, it was measured with the help of wet silk thread. The thread was kept approximately in the middle of the lateral surface extending from apex to middle of the lateral part of the inferior border. (AB in Fig. 1) It was marked at the designated points with Indian ink. Then it was lifted off the lung and spread along the graduated metric scale to measure its length.
 - b. Length along Medial surface: On the medial surface, it was measured with the help of wet silk thread which was kept along the medial surface extending from apex till middle of medial part of inferior border. (AB in Fig. 2) It was then lifted off the lung and spread along the graduated metric scale to measure it.
5. Anteroposterior Width
 - a. At the center:

For measuring this parameter, two metric scales were kept touching the anterior and posterior borders and then the distance between these metric scales was noted with the help of a graduated metric scale in the middle of the lung. (CD in Fig. 2)
 - b. At the Inferior Border:

For measuring this parameter, two metric scales were kept along the anterior and posterior borders at the level of inferior border. The distance between these metric scales was noted with the help of a graduated metric scale (EF in Fig. 2).
6. Medirolateral width was measured with the help of Vernier caliper as the widest distance between the medial and the lateral surfaces.

Different parts of right lung were studied:

1. Apex

It was noted whether it was blunt, sharp, or rounded.
2. Base
 - a. Shape: It was noted whether it was semilunar or of any other shape.
 - b. Contour was noted whether it was concave, convex, or flat.
 - c. Impressions were noted if present.
3. Costal Surface
 - a. Contour was noted whether convex or concave.
 - b. Smoothness of the surface was noted whether rough or smooth.
 - c. Impressions for the ribs were noted whether present or not.
4. Medial surface of the lung is divided into two parts:
 - I Vertebral part
 - a. Contour was noted whether convex, concave or elevated.
 - b. Anteroposterior width of vertebral part
 - i. In the center was measured with the Vernier caliper as a distance between midpoints of anterior edge of vertebral part and posterior border of lung (GD in Fig. 2).
 - ii. At lower border was measured with Vernier caliper as a distance between anterior edge of vertebral surface and posterior border of lung (HF in Fig. 2).
 - II Mediastinal part
 - a. Contour was noted whether convex or concave.
 - b. Anteroposterior width of mediastinal part
 - i. In center was measured with the Vernier caliper as a distance between anterior border of lung and posterior extremity of mediastinal surface in the middle of the lungs (CG in Fig. 2).
 - ii. At lower border was measured with the Vernier caliper as a distance between anterior border of lung and posterior extremity of mediastinal surface at the level of inferior border of the lung (EH in Fig. 2).
 - c. Percentages of A.P. width of mediastinal part with regard to total A.P. width at center and at the lower border were calculated.
5. Anterior Border
 - a. Thickness of anterior border was noted down whether thin, sharp, or thick.
 - b. Length was measured with wet silk thread spread from apex to base along the anterior border. It was marked with Indian ink then lifted off the lung and measured along the graduated metric scale (AD in Fig. 1).

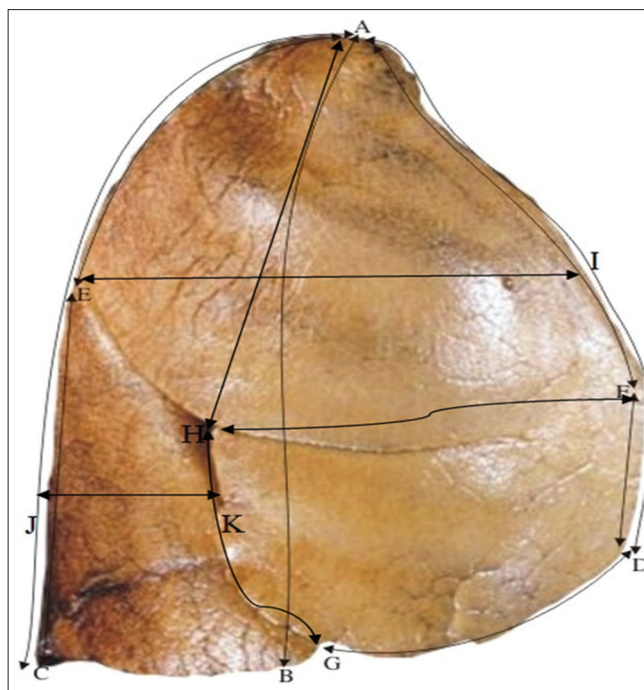


Fig. 1: Showing different parameters on costal surface. AB=Length from apex to base on Lateral surface. AC=Length of lung along Posterior Border, AD=Length of lung along Anterior Border. AE=Distance between Apex and point of intersection of Oblique Fissure on Posterior Border. AF=Distance between Apex and point of intersection of Horizontal fissure on Anterior Border. AH=Height of upper lobe between apex and point of origin of Horizontal Fissure on costal surface. CE=Distance between lower end of posterior border and point of intersection of Oblique Fissure on posterior border, DF=Distance between base and point of intersection of Horizontal Fissure on Anterior Border, DG=Distance between point of intersection of Oblique Fissure on Inferior border and latter's anterior end. EI=A.P width of upper lobe (at the end of lower end of 1st height). FH=Length of Antero-superior border of Middle lobe, GH=Length of Posterior border of Middle Lobe of lung. JK=A.P Width of Lower Lobe of lung (at the level of middle of height of Lower Lobe

- c. Any other variant of anterior border was noted.
6. Posterior Border
- Thickness of the posterior border was noted whether thick or thin.
 - Length was measured with wet silk thread spread from apex to base along the posterior border. Then the thread was lifted off the lung and measured along a graduated metric scale (AC in Fig. 1).
 - Any special features were noted if any.
7. Inferior border
- Thickness of the inferior border was noted whether it was thin, sharp or thick.
 - Length of inferior border was taken with wet silk thread kept along inferior border.
- i. Sharp part
- It was kept along inferior border starting from anterior border, going along the inferior border between lateral and inferior surface to posterior border and then to the point of demarcation between vertebral and mediastinal parts of medial surface (this part of inferior border is usually sharp) (EF in Fig. 3). It was then marked at the designated points and lifted off the lung and measured along graduated metric scale.
- ii. Blunt part
- The length of inferior border separating mediastinal surface from the base was also measured separately (this part of inferior border is usually blunt) (EF dotted in Fig.3).

It was then marked at the designated points and lifted off the lung and measured along graduated metric scale.

Any special features were noted if present

DISCUSSION

The present study has been conducted on 50 adult human cadaveric right lungs obtained from the department of Anatomy, Govt. Medical

College, Amritsar. Different morphological features were observed and measurements were taken and noted on the predesigned pro forma. The mean values and standard deviations are calculated. The data thus obtained were tabulated scrutinized, analyzed, and compared with the earlier studies wherever possible. If any variant from the normal is observed, an attempt has been made to explain the same on ontogenic or phylogenic basis. Different observations of the study are discussed below.

General features

Shape

Toing in line with different textbooks of anatomy [2-4,6,8-10]. All the 50 lungs of the present study were conical in shape. However, these differed from the true cones in two aspects, that is, the base was concave, and apex was not over middle of base but much to the medial and posterior side of it. It is evident also from the fact that length of lung from apex to base was more on lateral aspect (18.52 cm) as compared on medial aspect (15.11 cm). However, length of posterior border (19.9 cm) was more as compared to anterior border (17.8 cm) but it was due to the fact that the lung extends more downwards along the posterior border.

Texture

Hanging together with the standard textbooks of anatomy [2-4,6,8-10] majority of the lungs [49 (98%)] were spongy in texture while 1 (2%) lung (sp. No.10) was firm to touch.

Color

Table 1 shows the different colors of the lungs as observed in the present study. It is evident that majority of lungs depicted mottling in the form of black, brown or grey in color in 38%, 28%, and 26% of the specimens, respectively. A complete grey, brown, or brownish black color was seen in 2% lungs each. In one lung yellow mottling was seen which could be because of fat deposition.

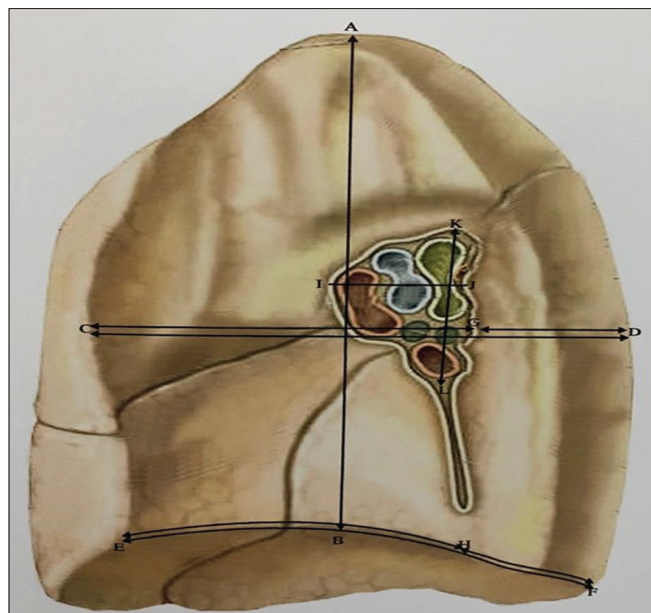

Fig. 2: Showing different parameters on medial surface.

AB=Length of lung from apex to base on medial surface.

CD=Anteroposterior width of lung at the centre.

CG=Anteroposterior width of mediastinal part of lung at the center.

EF=Anteroposterior width of lung at the lower border.

EH=Anteroposterior width of mediastinal part of lung at the lower border, GD=Anteroposterior width of vertebral surface of lung at the centre.

HF=Anteroposterior width of vertebral surface of lung at the lower border. IJ=Anteroposterior diameter of hilum

of lung. KL=Vertical diameter of Hilum of lung

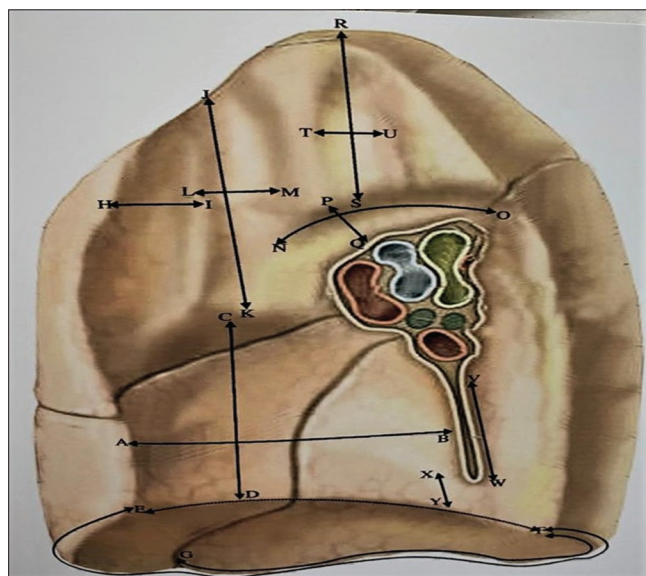

Fig. 3: Showing different parameters on medial surface.

AB=Anteroposterior diameter of impression for right atrium.

CD=Vertical diameter of impression for right atrium. EF=Length

of sharp part of Inferior border of lung. (Full), EF=Length of blunt

part of Inferior border of lung. (Dotted), GF=Distance between

point of intersection of Oblique fissure on Inferior border and

posterior end of sharp part of Inferior border. HI=Distance of

groove for SVC from Anterior border, JK=Length of groove for SVC.

LM=Diameter of groove for SVC. NO=Length of groove for Azygous

vein, PQ=Diameter of groove for Azygous vein. RS=Length of

groove for esophagus, TU=Diameter of groove for esophagus

In general, it was seen that posterior border was darker as compared to anterior one and the costal surface was darker than mediastinal surface. On the contrary the surface within the fissures was lightest of all. This was in consonance with Huber [5] who assumed that this pigmentation is more at places which are more accessible to light.

It is a known fact that at birth lungs are pink in color because of high vascularity and absence of exposure to carbonaceous particles. As the age advances, the granules of inhaled carbon particles are deposited in loose connective tissue near the lung surface giving a mottled brown, black or grey color. Such mottling was seen in 92% of the lungs of the present study with another 6% being completely brown, black or grey. The source of such carbon particles is usually the carbonaceous pollutants emitted from vehicular traffic or smoking. Such a high incidence of carbonaceous particles in lungs of inhabitants of this region is very alarming demanding an urgent need to take preventive steps to control air pollution.

1. Length from apex to base

It was measured both along lateral and medial surfaces. Along the lateral surface its mean value was 18.52 ± 3.178 cm (Range 12–25 cm) while along medial surface its mean value was 15.11 ± 2.241 cm (Range 9–23 cm). Thus, it was more along the lateral surface as compared to medial surface which is because of the convexity of the former and concavity of the later. No data could be found in the accessible literature for comparison.

2. Anteroposterior width

The mean AP width of right lung at center was 11.05 ± 2.864 cm (Range 7–23 cm) and along inferior border was 13.26 ± 2.743 cm (Range 9–20 cm). Thus, it was more along inferior border which was owing to the conical shape of the lung. For comparison, no data could be found in the accessible literature.

3. Medirolateral width

The mean medirolateral width was found to be 7.536 ± 2.318 cm with range being 4–15.2 cm. Thus, it was much less as compared to AP width for obvious reasons, that is, the lung is more compressed from side to side because of presence of heart.

Parts

Apex

In the present study, the apex was found to be blunt in all the lungs.

Base

Hanging together with the standard textbooks of anatomy [2-4,6,8-10], the base was semilunar in shape with concave contour in all the lungs of the present study. While 42 (84%) lungs showed no impression on base, 6 (12%) lungs (Sp. No: 1, 2, 7, 11, 29, and 34) depicted accessory fissures in one or the other form.

Costal surface

(a and b) Contour and Smoothness: The costal surface was smooth and convex in contour in 49 (98%) lungs each. However, in one lung (Sp. No: 8) it was rough due to impression of ribs and in another (Sp. No: 40) the contour was concave. (To be discussed vide infra).

Table 1: Showing different types of colors of the lungs

S. No	Color	No of lungs	Percentage
1.	Mottled black	19	38
2.	Mottled Brown	14	28
3.	Mottled Grey	13	26
4.	Mottled Yellow	1	2
5.	Completely Brown	1	2
6.	Completely Grey	1	2
7.	Brownish black	1	2
8.	Total	50	100

(c) Impression of Ribs: Table 2 depicts the variations seen in impressions of ribs on the costal surface.

Thus, in majority of lungs (45 [95%]), there were only slight markings of ribs and in 2 (4%) specimens the markings were completely absent. Only 3 (6%) lungs showed well marked impressions of ribs. However, 1st rib gave a well-marked impression in 6 (12%) lungs. In these 6 (12%) lungs, the other ribs gave slight impressions.

Medial Surface

1. Vertebral part

a. Contour

It was convex in 48(96%), concavo-convex in 1(2%) (Sp. No 6), and partially concave and partially convex in 1(2%) (Sp. No: 40) lung.

b. Anteroposterior Width

Its mean value was 4.149 ± 1.459 cm (Range 2–7 cm) in the center and 5.512 ± 1.501 cm (Range 3–10 cm) at inferior border. Thus, it was more at inferior border as compared to the center. For comparison no data could be traced in the accessible literature.

c. Percentage of Total AP Width

On an average, it was $37.2\% \pm 7.5\%$ (Range-20–57.14%) of total anteroposterior width of right lung in the center and $41.243 \pm 5.9\%$ (Range 27.3–53.3%) of total anteroposterior width at the inferior border.

d. Impression Of Vertebrae

Table 3 depicts the number of lungs showing different types of vertebral impressions.

Thus, vertebral impressions were well marked only in 10(20%) lungs with slight markings in 33(66%) lungs. These were altogether absent in 6(12%) lungs.

2. Mediastinal part

a. Contour

In the present study, the contour of the mediastinal part was concave in 47 (94%) lungs, convex in 1(2%) lung (Sp. No 12), and concavo-convex in 2(4%) lungs. (Sp. No 14 and 15) Since all these three lungs were apparently normal, no possible reason could be assigned to the contour being convex/concavo-convex.

b. Anteroposterior width

Its mean value at center was 6.922 ± 1.83 cm (Range 3–10 cm) and at lower border was $7.8 \text{ cm} \pm 1.66$ cm (Range 5–10.8 cm). Thus, as in vertebral part it was more at inferior border. No data could be traced in the accessible literature for its comparison.

c. Percentage of total AP width

On an average at the center, it was $62.79\% \pm 7.51\%$ (Range 42.9–80%) of the total AP width while at the lower border it was $58.9 \pm 5.8\%$ of

Table 2: Showing impressions of ribs on the lungs

S. No	Type of impression ribs	No. of lungs showing it (n%)
1.	Well-marked	3 (6)
2.	Slightly marked	45 (90)
3.	Absent	2 (4)
4.	Total	50 (100)

Table 3: Showing different types of vertebral impressions

S. No	Type of vertebral impression	No of lungs showing it (n%)
1	Well-marked	10 (20)
2	Slightly marked	33 (66)
3	Felt only on touch	1 (2)
4	Absent	6 (12)
5	Total	50 (100)

the total AP width. Thus, the mediastinal surface was wider in center (62.79% of total anteroposterior width) than at inferior border (58.9% of total anteroposterior width). On the contrary vertebral surface was wider at inferior border (41.2% of total anteroposterior width) than in the center of lung (37.2% of total anteroposterior width). It could be because in the central part mediastinal surface is in contact with right atrium whose main bulk lies there and as we trace it down it is continuous with IVC and decreases in width. So near lower border anteroposterior width of mediastinal part is less. Moreover, the vertebral surface near the center of the lung is in contact with vertebrae no. T₄-T₆ (which are small in size) as compared to vertebral surface near inferior border which is in contact with vertebrae no. T₉-T₁₀ (which are larger in size). So vertebral surface is larger in anteroposterior width near inferior border as compared to central part of lung.

Anterior border

a. Thickness

In the present study, anterior border was sharp in 45(90%) lungs, thin in 4(8%) lungs (Sp. No: 14, 16, 17 and 39), and thick in 1(2%) lung. (Sp. No: 19).

b. Length

The anterior border was 17.8 ± 2.74 cm long with range being 12 cm to 24 cm. In 2 (4%) lungs (Sp. No 9 and 10), the anterior border depicted a well-marked impression of 1st rib, while 48(96%) lungs showed no special features.

Posterior border

In consonance with the standard textbooks of anatomy [2-4,6,8-10] it was thick in all the 50 lungs with a mean length of 19.9 ± 3.21 cm (Range 15–28 cm). Thus, posterior border was longer (19.9 cm) as compared to anterior border [17.8 cm (vide supra)]. It was found so in 48 (96%) lungs. However, in 2 (4%) lungs, the anterior border was longer than posterior border (Sp.No.3 and 43)

Variation: In one specimen (Sr. No.40) a large concave impression with height 11 cm, breadth 2.1 cm, and depth 2.5 cm was seen on posterior border extending onto posterior 2.5 cm of vertebral surface and posterior 3.2 cm of costal surface. Its upper limit was 5 cm below apex and lower limit was 4 cm above the lower end of posterior border. No space occupying lesion was seen in the thoracic cavity adjoining to this concavity which could be held responsible for it.

Inferior border

a. Thickness

In the present study, the inferior border was sharp laterally and blunt medially in 49(98%) lungs while in one (2%) lung (Sp No. 41) it was sharp throughout.

b. Length

i. Sharp part

The sharp part of inferior border was 26.21±3.99 cm (Range 20–36 cm) long.

ii. Blunt part

The blunt part was 4.31±1.46 cm (Range 2.5–9.0 cm) long.

No data could be found in accessible literature for comparison of length of inferior border.

c. Any special features

Out of the 50 lungs of the present study inferior border of 47(94%) lungs showed no special features while in 3(6%) lungs it showed the impression of accessory fissure.

CONCLUSION

The present study was conducted on 50 adult human cadaveric right lungs of north Indian population. Different morphological features were looked for and morphometrical parameters were measured. The results obtained were tabulated, scrutinized, and statistically analyzed. These

were compared with the accessible literature. The various parameters studied, and the results concluded are as follows:

All the 50 lungs were conical in shape and spongy in texture. Majority of the lungs showed black, brown, or grey mottling. The length of lung along the lateral surface was more as compared to medial surface. The anteroposterior width was more along inferior border as compared with the width along the center. Mediolateral width was less as compared to anteroposterior width due to the presence of heart. While the apex of all the lungs was blunt, the base was semilunar in shape with concave contour. Majority of the lungs showed no impression on the base while 16% of the lungs depicted accessory fissures in one or the other form. The costal surface of majority of the lungs was found to be smooth and convex with slight impressions of ribs.

The vertebral part of the medial surface was found to be convex in majority of lungs while mediastinal part was concave. The anteroposterior width of both vertebral and mediastinal parts was more at the inferior border as compared with the anteroposterior width in the center. Impressions of vertebrae were slightly marked in majority of the lungs. The posterior border was thick and more in length as compared with the anterior border which was sharp and less in length in majority of the lungs. The inferior border was sharp laterally and blunt medially in majority of the lungs and the length of sharp part was more than the length of blunt part.

Knowledge of normal measurements of lungs and their variations helps cardiothoracic surgeons to avoid undue complications during surgery. Furthermore, it may help radiologist to resolve perplexed radiographic findings and make accurate diagnosis in case of lung pathologies.

ACKNOWLEDGMENT

The authors acknowledge the immense help received from the scholars whose articles are cited and included in references of this manuscript. The authors are also grateful to Authors/Editors/publishers of all those articles, journals, and books from where the literature for this article has been reviewed and discussed.

AUTHORS CONTRIBUTIONS

All the authors have equally contributed to the article.

CONFLICTS OF INTEREST

No conflicts of interest.

AUTHORS FUNDING

Nil.

REFERENCES

1. Wikipedia. Human Lung. Wikipedia; 2013.
2. Gatzoulis MA. Thorax, lungs and diaphragm Standring. In: Gray's Anatomy, the Anatomical Basis of Clinical Practice. 40th ed. Philadelphia, PA: Churchill Livingstone; 2008. p. 992-93.
3. Datta AK. Essentials of Human Anatomy. 9th ed. Mumbai: Current Books International; 2013. p. 35-46.
4. Lockhart RD, Hamilton GF, Fyfe FW. Anatomy of the Human Body. 1st ed. London: Faber Ltd.; 1959. p. 542-6.
5. Huber GC. Piersol's Human Anatomy Including Structure and Development and Practical Considerations. 9th ed., Vol. 2. Philadelphia, PA: JB Lippincott Co.; 1930. p. 1843-55.
6. Romanes GJ. Cunningham's Textbook of Anatomy. 10th ed. New York: Oxford University Press; 1964. p. 462-4.
7. Romanes GJ. Cunningham's Manual of Practical Anatomy. Vol. 2. New York: Oxford Medical; 2003. p. 29-38.
8. Boyd JD, Clark WE, Hamilton WJ, Yoffey JM, Zuckerman S, Appleton AB. Textbook of Human Anatomy. London: Macmillan and Co. Ltd.; 1956. p. 422-30.
9. Hollinshed WH. Anatomy for surgeons. In: The Thorax, Abdomen and Pelvis. 2nd ed., Vol. 42. New York: Harper and Row; 1971. p. 50-75.
10. Kulkarni NV. Clinical Anatomy for Students: Problem Solving Approach. New Delhi: Jaypee Brothers; 2007. p. 151-60.