

Original Article (BRAIN)

Short-Term Complications of Microscopic Trans Nasal Transsphenoidal Pituitary Adenectomy

Samra Majeed¹, Sana Majeed¹, Muhammad Umair¹, Shahzaib Tasdique³, Waqas Mehdi², Anjum Habib Vohra³

¹Department of Neurosurgery, Services Hospital, ²Mayo Hospital, ³Surgimed Hospital, Lahore, Pakistan

ABSTRACT

Background/Objective: The commonest of pituitary gland tumors is pituitary adenoma which may be excised transcranially or trans nasal trans sphenoidal using either microscope or endoscope, in this study, the microscope was used. The objective was to see the short-term outcome of patients after microscopic transnasal trans-sphenoidal pituitary adenectomy.

Material & Methods: This was a descriptive prospective study carried out from July 2019 to July 2021. 80 cases were included. All patients were investigated by contrast brain MRI, hormonal assay for pituitary gland & visual perimetry. Patients were evaluated for complications at 48 hours and 7 days.

Results: Mean age of the study population was 41.78 ± 11.75 years. There were 61 (76%) men & 19 (24%) women. 55 (68.8%) patients had functioning and 25 (3.3%) patients had nonfunctioning adenoma. Among 33 (41.3%) patients size of the adenoma was < 0.9 cm and 47 (58.8%) patients had adenoma > 1.0 cm. 12 patients had CSF leaks within 48 hours of surgery and 5 had a persistent leak on the 7th day. No statistically significant association was seen between age, gender, and size of adenoma and persistent CSF leak ($P > 0.05$). Diabetes insipidus was found in 9 patients. 3 had post-operative hematoma, 01 patient had meningitis and 2 patients died.

Conclusion: microscopic transnasal trans-sphenoidal surgery is a safe procedure yet associated with significant complications.

Keywords: Pituitary, Adenectomy, Microscope, Trans-Sphenoidal.

Corresponding Author: Samra Majeed
Department of Neurosurgery, Services Hospital, Lahore
Email: semi_hemi3@yahoo.com

DOI: 10.36552/pjns.v26i2.694

Date of Submission: 10-03-2022
Date of Revision: 18-05-2022
Date of Acceptance: 25-06-2022
Date of Online Publishing: 30-06-2022
Date of Print: 30-06-2022

INTRODUCTION

The pituitary gland is termed the "master gland" of the human body as, despite its tiny size, it influences practically every major organ.¹ The anterior lobe of the pituitary gland, also termed adenohypophysis, is made up of five separate

types of cells that release six different types of hormones. Lactotrophs generate prolactin (PRL), somatotrophs create growth hormone (GH), corticotrophic cells release adrenocorticotrophic hormone (ACTH), thyrotrophs produce thyroid-stimulating hormone (TSH) & gonadotrophs secrete follicle-stimulating hormone (FSH) & luteinizing hormone (LH). The hypothalamus is known to influence the synthesis of these hormones. Hormonal production is also influenced by negative feedback regulation from the target organ's hormone products.

The neurohypophysis secretes two hormones: antidiuretic hormone (ADH) and oxytocin. A pituitary adenoma is the most common pituitary gland tumor. 1 Some pituitary tumors produce too many hormones, which otherwise govern critical bodily systems. On the contrary, certain pituitary tumors may impair normal pituitary gland activities, resulting in reduced hormone production.²⁻³

The prevalence of pituitary tumors or adenomas is frequently reported based on autopsy or MRI data.⁴ An epidemiological research found that pituitary adenomas can affect up to 16.5 percent of people. 5 With an estimated frequency of 16.7 percent, the bulk of them are larger than 10 mm in size (14.4 percent in autopsies & 22.5 percent in radiological findings).⁵⁻⁶

Pituitary adenomas are characterized according to their size, secretion, and histology. Tumors with a diameter of 9 mm are called microadenomas, whereas those with a diameter of more than 9 mm are called macroadenomas. Giant adenomas are tumors that are ≥ 4 cm. The hormones secreted by functioning adenomas are categorized, for example, growth hormone-secreting and prolactinomas. A pituitary tumor can be formed by any of the pituitary gland's many cell types. Nonfunctioning tumors do not create clinically significant increases in hormone levels. However, even among nonfunctioning

tumors, a variety of tumor forms are observed, including null cell and oncocytoma.⁷

Management of pituitary tumors is defined by their types and size.⁵ Operative treatment is usually considered for debulking the tumor mass to achieve the betterment of visual disturbance and other presenting complaints⁸. It is observed that diagnoses and excision have increased remarkably over the past 2 decades and trans-sphenoidal resection has been on increasing trends while transcranial resections have notably decreased.⁹

Transnasal trans-sphenoidal pituitary surgery is a frequent operative treatment that is now recognized as the standard surgical approach to sellar lesions due to the benefits of enhanced visibility and low invasiveness. This has been described as a safe and successful way of removing pituitary tumors. This is a common treatment these days, although there are some possible problems, such as cerebrospinal fluid (CSF) leak, infections, electrolyte imbalance, vascular, endocrinologic, and rhinological abnormalities.^{4,10} The purpose of this study was to look at patients' short-term outcomes following microscopic transnasal transsphenoidal pituitary adenectomy. Complications prolong hospital stay, putting additional strain on limited resources, and complications such as meningitis can be deadly.

MATERIAL & METHODS

Study Design & Setting

A descriptive prospective study (Quasi observational study) was carried out at Services Hospital Lahore & Surgimed Hospital from July 2019 to July 2021. This study included 80 cases and a nonprobability consecutive sampling technique was used.

Inclusion Criteria

Patients diagnosed with pituitary adenoma on

MRI brain plain & contrast, both genders, between the age group of 18 – 60 years were part of this study.

Exclusion Criteria

Those patients younger than 20 years or older than 60 years, with recurrent tumors & tumors other than adenomas, were excluded from the study. We also excluded those who did not agree to be part of the study.

Data Collection

Eighty patients with pituitary tumors were studied. All patients fulfilling the criteria were admitted through our patient department of Services Hospital Lahore or Surgimed hospital Lahore. Informed consent was obtained either from the patients or attendants. The patient's name, age, sex, and address were obtained initially along with detailed history. All patients were investigated by an MRI brain plain & contrast, pituitary hormonal assay (cortisol, prolactin, growth hormone, Insulin-like growth factor-I, follicle-stimulating hormone, luteinizing hormone, thyroid function tests) visual perimetry & baseline investigations to ensure the patient is optimized for surgery. Follow-up of the patients was done at 48 hours and 7 days to record short-term post-operative complications of trans nasal transsphenoidal pituitary adenectomy. SPSS 23 was used to enter and analyze all of the data.

Surgical Technique

After informed consent & induction of general anesthesia, nasal preparation and positioning of the patient (placed supine with neck 10 – 15 degree extended and nasal tip in line with right anterior superior iliac supine) nasal speculum was placed in the right nostril. Middle turbinate was identified, about 1cm distal to it, the root of the septum until an anterior wall of sphenoid sinus was identified. With the help of the speculum, the

septum was subluxed and deviated. Then microscope was brought into the field and the sphenoid sinus was opened by an osteotome. Then the floor of the sella was opened, dura revealed which was diathermized and a midline incision was made with No. 11 blade. The tumor was debulked intracapsularly.

The tumor was resected piecemeal by use of ring curettes, pituitary rongeurs, suction, and irrigation. After tumor removal floor of the sella was reconstructed with fat from the right lateral thigh, surgical and bone chips saved during submucosal resection. Sphenoid sinus was packed with fat, the speculum was removed, septum returned to midline and mucosa was placed back and both the nostrils were packed with BIPP (Bismuth iodine paraffin paste) soaked gauze and a sterile dressing was done for 48 hours. The patient was nursed in a supine position with a head-end elevation of 30 degrees. The patient was evaluated for complications at 48 hours & 7 to record in the Proforma.

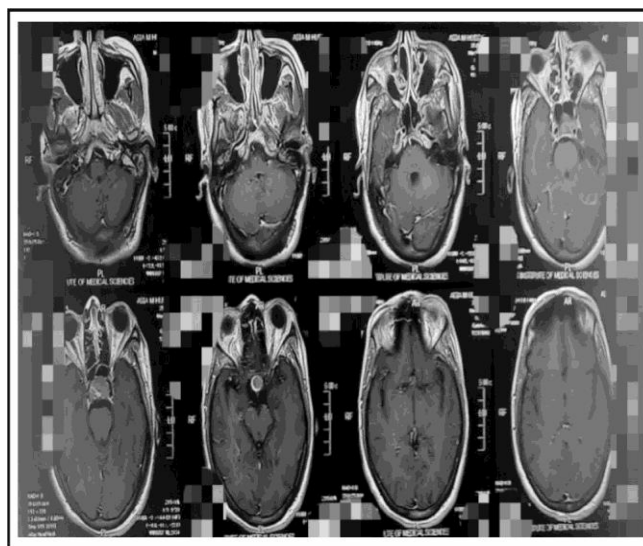


Figure 1a: Axial view. (Images used with permission)

Figure 1: MRI Brain T1 weighted image with contrast showing sellar lesion (1a, axial view, 1b sagittal view) patient had elevated growth hormone.

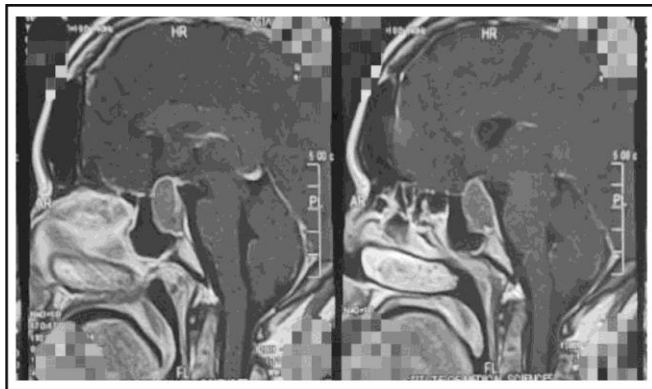


Figure 1b: Sagittal view. (Images used with permission)

Table 1: Type of Adenoma.

	Frequency	Percentage
Functioning	55	68.8%
Non Functioning	25	31.3%
Total	80	100%

Table 2: Size of Adenoma.

	Frequency	Percentage
Microadenoma ≤ 0.9 cm	13	16.25%
Macroadenoma ≥ 1.0 cm	67	83.75%
Total	80	100%

RESULTS

Age Distribution

The average age of the patients was 41.7811.75 years. The patient’s minimum and maximum ages were 20 and 60 years, respectively.

Gender Distribution

Gender distribution of patients showed 61 (76%) men and 19 (24%) women.

Type of Adenoma

There were 55 (68.8%) patients who had a functioning and 25 (3.3%) patients who had non-functioning adenoma (Table-1).

Size of Adenoma

Among 13 (41.3%) patients’ size of the adenoma was ≤ 0.9 cm and 67 (58.8%) patients had adenoma ≥ 1.0 cm (Table-2).

Post-Operative Complications

CSF leak was found to be the most common complication followed by diabetes insipidus which was transient in most cases. In patients who had CSF leak at 48 hours, nasal packing was prolonged for another 5 days and lumbar drainage was done. It settled in 9 cases with this technique however 3 patients needed another surgery. Nine patients developed postoperative diabetes insipidus, but it was mostly transient, only one patient had prolonged DI & was discharged on tablet Minirin (Desmopressin acetate). One patient developed tumor bed hematoma within the first 24 hours & was diagnosed with CT brain plain on deteriorating GCS. The patient improved postoperatively. One of the patients with CSF leak developed meningitis. Two patients died postoperatively, one of those was a case of pituitary apoplexy.

Table 3: Short-term complications of surgery.

Complication	48 Hours		7 Days	
	Frequency	%age	Frequency	%age
CSF leak	12	15	3	3.75
Diabetes insipidus	9	11.25	1	1.25
Hematoma	3	3.75	-	-
Meningitis	-	-	1	1.25
Mortality	1	1.25	1	1.25

Table 4: Comparison of CSF leak in different age groups.

		CSF Leakage		
		Yes	No	Total
Age Groups	20-30	0 (0%)	18(24%)	18 (22.5%)
	31-40	1 (20%)	14 (18.7%)	15 (18.75%)
	41-50	1 (20%)	24 (32%)	25 (31.25%)
	51-60	3 (60%)	19 (25.3%)	22 (27.5%)
Total		5 (100%)	75 (100%)	80 (%)

Chi-Square Test= 3.469; p-value= 0.325 (Insignificant)

Table 5: Comparison Of CSF Leak In Both Genders.

		CSF Leakage		
		Yes	No	Total
Gender	Male	5 (100%)	56 (74.7%)	61 (76.25%)
	Female	0 (0%)	19 (25.3%)	19 (23.75%)
Total		5 (100%)	75 (100%)	80 (100%)

Chi-Square Test= 1.661, p-value= 0.197 (Insignificant)

Table 6: Comparison of CSF Leak Concerning Size of Adenoma.

		CSF Leakage		
		Yes	No	Total
Size	≤ 0.9 Cm	2 (40%)	31 (41.3%)	33 (41.25%)
	≥ 1.0 Cm	3 (60%)	44 (58.7%)	47 (58.75%)
Total		5 (100%)	75 (100%)	80 (%)

Chi-Square Test=0.003, p-value= 0.953 (Insignificant)

Relation of Persistent CSF Leak with Age, Sex, and Size of Adenoma

CSF leak present on the 7th day was labeled as the persistent CSF leak & its relation with the age, sex & size of the tumor was determined (Tables 4-6).

DISCUSSION

Trans-sphenoidal pituitary surgery is a frequent operation that has become the primary treatment for sellar lesions.¹¹ Although trans-sphenoidal surgery has been consistently described as a safe & successful treatment for pituitary tumor removal, it is not risk and complication-free^{12,13}.

Persistent cerebrospinal fluid (CSF) rhinorrhea post-operatively is one of the most pertinent causes of morbidity following trans-sphenoidal

surgery for pituitary adenomas¹⁴.

With regards to surgical complications of transsphenoidal surgery, CSF leak remains to be the most common and disturbing postoperative morbidity. It is described that the success of intraoperative reconstruction of sella following dissection is a major determinant of postoperative CSF leak. Postoperative CSF leak is a common complication of transnasal trans-sphenoidal pituitary adenectomy & encountered in reported series of 0.5 – 15%.^{15,16}

A local study, describing the complications of transsphenoidal surgery, cited the prevalence of postoperative CSF leak as 3.9%.¹⁷ The major risk factor for the post-operative CSF leak is the intraoperative leak, non-meticulous repair of the sella is another important factor.^{16,18}

In this study, it was observed that 12 (15%) of the patients had CSF leak which was managed conservatively however persistent CSF leak was only in 5 (6.25%), after microscopic transnasal transsphenoidal pituitary adenectomy. Patients' age, gender, and size of the tumor were stratified to see the impact of these variables on CSF leak after transnasal transsphenoidal pituitary adenectomy. But results showed no significant association between CSF leaks.

Henry Jung from the USA reported postoperative CSF rhinorrhea was 1.7%.¹⁹ However this rate of 1.7% is very low as compared to the frequency of CSF in this study which is 6.25%.

Gao et al. published a meta-analysis of the results & consequences of endoscopic and microscopic transsphenoidal surgery for pituitary adenomas. According to his results, the post-operative CSF leak was rather severe (12.8 percent vs. 12.2 percent for the endoscopic and microscopic groups, respectively).²⁰

A study reported that CSF leakage was observed in ten patients (40%) who were treated with a transsphenoidal microscopic approach¹⁰. Adam A Razak in his study presented his early experience and compared endoscopic surgery with microscopic experience. As per his findings, CSF leak rates were the same in both study groups. Six patients (15%) in the MTSS (microscopic transnasal trans sphenoidal) group and four (10%) in the ETSS (endoscopic transnasal transsphenoidal) group had postoperative CSF leakage (p-value = 0.74).²¹ In this study, CSF leak was comparable to our study for microscopic transnasal transsphenoidal pituitary adenectomy.

Diabetes insipidus was observed to be the second most common complication after CSF rhinorrhea i.e. 11.25% (9 patients). However, it was transient in most cases (8 patients). A study by Chowdhury and others showed post-operative DI at 14.8% slightly higher than our study however it was transient in this study as well²².

Randeva et al. observed a 16% incidence of transitory diabetes insipidus in pituitary apoplexy patients throughout their hospital stay. DI following trans-sphenoidal surgery was considered to be caused by compression or damage of the neurohypophysis and interrupted blood supply of the gland or an edematous pituitary stalk. Pituitary apoplexy is usually restricted to the adenohypophysis; however, it can occur in the posterior lobe as well.²³

Pesky et al. found that 9.0 percent of individuals had transitory DI and 1.4 percent had persistent DI. They also discovered a much greater rate of transient DI in functional adenomas than in nonfunctional adenomas (16.6 percent vs. 3.4 percent).^{22,24}

Post-operative hematoma at the operative site following any intracranial surgery is the most cumbersome complication usually arising within the first 24 hours, resulting in serious morbidity or even mortality, if not coped timely.²² In a study, 15 patients (10%) patients²² developed this complication however, in our study it was very low i.e., 3.75%.

CONCLUSION

Trans nasal trans-sphenoidal microscopic surgery is considered a safe procedure but like any other surgery, it also carries the notable risk of postoperative complications. In our study, CSF leak was found most common complication followed by diabetes insipidus. In this study, no relation of CSF rhinorrhea could be established to age, gender, or size of the tumor. A more meticulous approach and use of new gadgets & materials (like the use of fibrin glue while reconstructing sella) may help in further decreasing the complication rate.

Limitations

Surgeons with different expertise and experience performed the surgery. No long-term complications were included in this study.

REFERENCES

1. Shamim MS, Khursheed F, Bari ME. Operating on master gland: 100 consecutive hypophysectomies at Aga Khan University Hospital, Karachi. *Pak J Neurological Sci.* 2006; 1: 66-9.
2. Wade AN, Baccon J, Grady MS, Judy KD, O'Rourke DM, Snyder PJ. Clinically silent somatotroph adenomas are common. *European Journal of Endocrinology.* 2011; 165 (1): 39-44.
3. Zada G, Woodmansee WW, Ramkissoon S, Amadio J, Nose V, Laws Jr ER. Atypical pituitary adenomas: incidence, clinical characteristics, and implications: Clinical article. *Journal of Neurosurgery.* 2011; 114 (2): 336-44.
4. Fernandez A, Karavitaki N, Wass JA. Prevalence of pituitary adenomas: a community-based, cross-sectional study in Banbury (Oxfordshire, UK). *Clinical Endocrinology.* 2010; 72 (3): 377-82.
5. Mezosi E, Nemes O. [Treatment of pituitary adenomas]. *Orvosi Hetilap.* 2009; 150 (39): 1803-10.
6. Asa SL. Practical pituitary pathology: what does the pathologist need to know? *Archives of Pathology & Laboratory Medicine.* 2008; 132 (8): 1231-40.
7. Richard GE ASaSL. Pituitary tumors: diagnosis and management In: Carrie RM NM, editor. *Principles of Neurological surgery 3rd Ed: Elsevier; 2012: p. 627.*
8. Vance ML. Treatment Of Pituitary Adenomas. [Online available from]: <http://content.lib.utah.edu/utis/getfile/collection/ehsl-nam/id/1084/filename/1085.pdf>. Accessed Nov 2013.
9. Villwock JA, Villwock M, Deshaies E, Goyal P, editors. Significant increases of pituitary tumors and resections from 1993 to 2011. *International Forum of Allergy & Rhinology, 2014: Wiley Online Library.*
10. Kahilogullari G, Beton S, Al-Beyati ES, Kantarcioglu O, Bozkurt M, Kantarcioglu E, et al. Olfactory functions after transsphenoidal pituitary surgery: endoscopic versus microscopic approach. *The Laryngoscope.* 2013; 123 (9): 2112-9.
11. Fatemi N, Dusick JR, de Paiva Neto MA, Kelly DF. The endonasal microscopic approach for pituitary adenomas and other parasellar tumors: a 10-year experience. *Neurosurgery.* 2008; 63 (4): 244-56.
12. Benveniste RJ, King WA, Walsh J, Lee JS, Delman BN, Post KD. Repeated transsphenoidal surgery to treat recurrent or residual pituitary adenoma. *Journal of Neurosurgery.* 2005; 102 (6): 1004-12.
13. Mortini P, Losa M, Barzaghi R, Boari N, Giovanelli M. Results of transsphenoidal surgery in a large series of patients with pituitary adenoma. *Neurosurgery.* 2005; 56 (6): 1222-33.
14. Hobbs C, Darr A, Carlin W. Management of intra-operative cerebrospinal fluid leak following endoscopic trans-sphenoidal pituitary surgery. *The Journal of Laryngology & Otology.* 2011; 125 (03): 311-3.
15. Jane Jr JA, Thapar K, Kaptain GJ, Maartens N, Laws Jr ER. Pituitary surgery: transsphenoidal approach. *Neurosurgery.* 2002; 51 (2): 435-44.
16. Laws Jr ER, Fode NC, Redmond MJ. Transsphenoidal surgery following unsuccessful prior therapy: An assessment of benefits and risks in 158 patients. *Journal of Neurosurgery.* 1985; 63 (6): 823-9.
17. Ciric I, Ragin A, Baumgartner C, Pierce D. Complications of transsphenoidal surgery: results of a national survey, review of the literature, and personal experience. *Neurosurgery.* 1997; 40 (2): 225-37.
18. Seiler RW, Mariani L. Sellar reconstruction with resorbable vicryl patches, gelatin foam, and fibrin glue in transsphenoidal surgery: a 10-year experience with 376 patients. *Journal of Neurosurgery.* 2000; 93 (5): 762-5.
19. Jung H, Shah A, Ajlan A. Perioperative Cerebrospinal Fluid Diversion Utilizing Lumbar Drains in Transsphenoidal Surgery. *Journal of Neurological Disorders.* 2014.
20. Gao Y, Zhong C, Wang Y, Xu S, Guo Y, Dai C, et al. Endoscopic versus microscopic transsphenoidal pituitary adenoma surgery: a meta-analysis. *World Journal of Surgical Oncology.* 2014; 12 (1): 1-12.
21. Razak AA, Horridge M, Connolly DJ, Warren DJ, Mirza S, Muraleedharan V, et al. Comparison of endoscopic and microscopic trans-sphenoidal pituitary surgery: early results in a single centre. *British Journal of Neurosurgery.* 2013; 27 (1): 40-3.
22. Chowdhury T, Prabhakar H, Bithal PK, Schaller B, Dash HH. Immediate postoperative complications in transsphenoidal pituitary surgery: A prospective

- study. Saudi Journal of Anaesthesia. 2014; 8 (3): 335–341.
23. Randeve HS, Schoebel J, Byrne J, Esiri M, Adams CB, Wass JA. Classical pituitary apoplexy: Clinical features, management and outcome. Clin Endocrinol (Oxf). 1999; 51: 181–8.
24. Persky MS, Brunner E, Copper PR, Cohen NL. Perioperative complication of transsphenoidal excision for pituitary adenomas. Skull Base Surgery. 1996; 6: 231–5.

Additional Information

Disclosures: Authors report no conflict of interest.

Ethical Review Board Approval: The study was conformed to the ethical review board requirements.

Human Subjects: Consent was obtained by all patients/participants in this study.

Conflicts of Interest:

In compliance with the ICMJE uniform disclosure form, all authors declare the following:

Financial Relationships: All authors have declared that they have no financial relationships at present or within the previous three years with any organizations that might have an interest in the submitted work.

Other Relationships: All authors have declared that there are no other relationships or activities that could appear to have influenced the submitted work.

AUTHORS CONTRIBUTIONS

Sr.#	Author's Full Name	Intellectual Contribution to Paper in Terms of:
1.	Samra Majeed	1. Study design and methodology.
2.	Samra Majeed, Sana Majeed	2. Paper writing and data calculations.
3.	Samra Majeed, Anjum Habib Vohra	3. Data collection and calculations.
4.	Muhammad Umair, Waqas Mehdi	4. Analysis of data and interpretation of results.
5.	Sana Majeed, Samra Majeed	5. Literature review and referencing.
6.	Prof Anjum Habib Vohra, Shahzaib Tasdique	6. Analysis of data and quality insurer.