

Original Article (SPINE)

## Neurological Improvement after Decompression for Dorsal Spine Tuberculosis (TB)

Arif Hussain,<sup>1</sup> Musawer Khan,<sup>2</sup> Sajid Khan,<sup>2</sup> Mumtaz Ali,<sup>1</sup> Akramullah,<sup>1</sup> Muhammad Zubair<sup>1</sup>  
Maria Mumtaz<sup>1</sup>

<sup>1</sup>Department of Neurosurgery, Prime Teaching Hospital, Peshawar, Pakistan

<sup>2</sup>Department of Neurosurgery, Mardan Medical Complex, MTI, Mardan, Pakistan

### ABSTRACT

**Objectives:** To assess the neurological improvement after decompression for dorsal spine tuberculosis in terms of Frankel grading.

**Materials and Method:** Prospective study was done in the Neurosurgery department, Prime Teaching Hospital Peshawar from 2018 to 2021. Patients of both genders aged between 18 to 60 years were selected while those unfit for surgery or requiring conservative management were excluded from the study. After clinical examination and radiological findings, the patients were diagnosed with dorsal spine tuberculosis requiring surgery. All patients were followed for 3 months post-operatively. Neurological improvement was measured by comparing pre and post-op Frankel grading. Complications were also documented.

**Results:** Out of 38 patients included in the study, 16 (42%) were male and 22 (58%) were female. The mean age of presentation was  $34 \pm 5$ . The distribution for age groups was 18 – 30 (08), 31 – 40 (13), 41 – 50 (11), and 51 – 60 (06). Level of disease D4 – D8 were 17 (44.8%) and D9 – D12 was 21 (55.2%). Pre-operative neurological status of the patients was (5.2%) Frankel A, (10.5%) Frankel B, (47.3) Frankel C, (22%) Frankel D, and (7.8%) Frankel E while Post-operative grading was (2.6%) Frankel A, (5.2%) Frankel B, (23.6%) Frankel C, (47.3%) Frankel D and (18.4) Frankel E. 3 patients experienced worsening of neurology, 2 patients bleeding and CSF leak and 1 patient died as a complication of the surgery.

**Conclusion:** Surgical option involving decompression of spine TB followed by stabilization is utilized in a majority of patients with neurological deficits. It is very effective and the results are good. The main advantage is thorough debridement and achievement of spinal stabilization.

**Keywords:** Dorsal Spine Tuberculosis, Frankel Grading, Spinal Stabilization.

**Corresponding Author:** Musawer Khan  
Mardan Medical Complex, Mardan, Pakistan  
Email: modestgaze@yahoo.com

Date of Acceptance: 22-06-2022  
Date of Online Publishing: 30-06-2022  
Date of Print: 30-06-2022

Date of Submission: 13-05-2022  
Date of Revision: 20-06-2022

**DOI:** 10.36552/pjns.v26i2.692

## INTRODUCTION

Worldwide 10 million people were infected with tuberculosis with the second number in South East Asia prevalence.<sup>1</sup> It is primarily a disease of the lungs, but extra pulmonary involvement is not uncommon. The most common second type of extra-pulmonary tuberculosis is spine tuberculosis.<sup>2</sup> The most common site of involvement in the thoracolumbar spine followed by lumbar and then the cervical spine.<sup>3</sup> Spinal TB presents a variety of symptoms, but its nature is always insidious in onset, and its progress at a slow pace.<sup>4</sup> The manifestation depends on the severity, duration, site, and complications (abscess, sinuses, deformity, and neurological deficit) caused by the disease. The neurological deficit can occur in both the early disease process and also in the late healed stage. In the active stage, it is direct compression of the spinal cord by abscess, sequestrum, inflammatory tissue, or the spinal column instability which results in neurological compromise. In the healed stage, it is the stretching of the spinal cord over the gibbus or rarely ossification of the ligamentum flavum proximal to the kyphosis which causes the neurological compromise.<sup>5</sup> Tuberculosis and human beings have a symbiotic relationship and with advancements in medical sciences, the goal of treatment has changed. In the pre-era of antibiotics, they were treated with a high protein diet, rest, and fresh air hoping for natural quiescence of disease.<sup>6</sup> Historically the treatment for spine tuberculosis was conservative such as body cast and a good nutrition diet while later W.H.O was under the agenda to provide better treatment presented with anti-tuberculosis therapy which changed the lives of affected patients.<sup>7</sup> The thoracic spine is the most affected region; MRI has changed the era by providing better-advanced diagnosis which has helped the treatment with conservative management, surgery, and Anti-tuberculosis therapy.<sup>8-10</sup>

The purpose of this study is to focus on the results of spinal decompression in patients with

spine TB. Not all patients are candidates for anti-TB drugs and surgery becomes the mainstay of management in those patients.

## MATERIALS AND METHODS

### Study Design and Setting

This prospective study was conducted after approval from the ethical committee from June 2018 to June 2021 at the department of neurosurgery, Prime teaching hospital Peshawar.

### Sampling

Patients who were clinically and radiologically (through MRI dorsal spine) diagnosed with spine tuberculosis were enrolled in the study through consecutive non-probability sampling.

### Inclusion Criteria

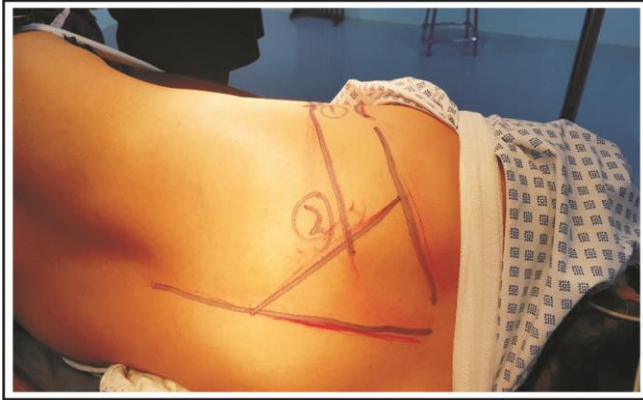
Inclusive criteria for patients were aged from 18 – 60 years of either gender. Patients who were having deteriorating neurology, Para spinal abscess/cord compression, and refractory to conservative therapy were included in the study.

### Exclusion Criteria

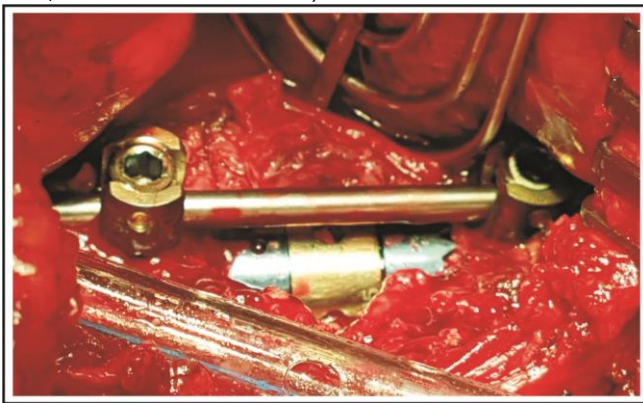
Patients which were not fit for surgery, improved with conservative management, and were not willing for study/surgery were excluded.

### Clinical Management

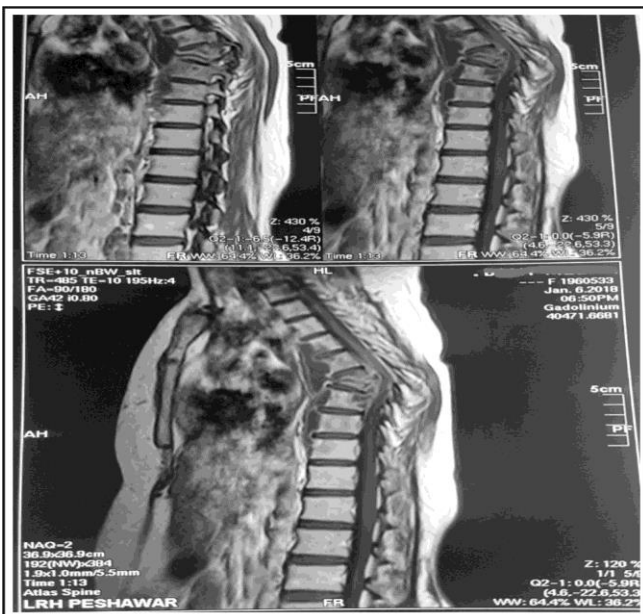The main procedure followed was decompression ± fusion through lateral thoracotomy and patients were followed for at least three months post-operatively. Results were analyzed through SPSS-VER 26.0.



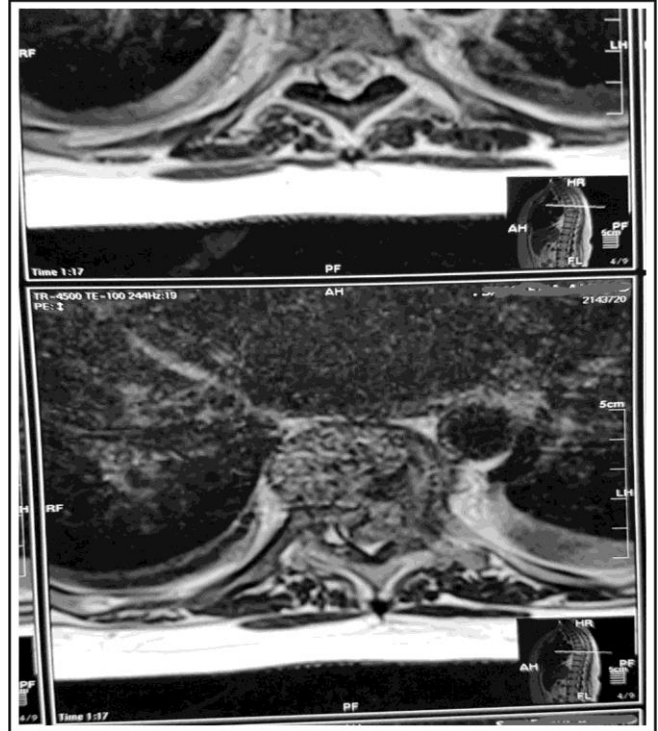
**Figure 1:** A pre-op surgical landmarks for thoracotomy (for scan, informed consent taken).



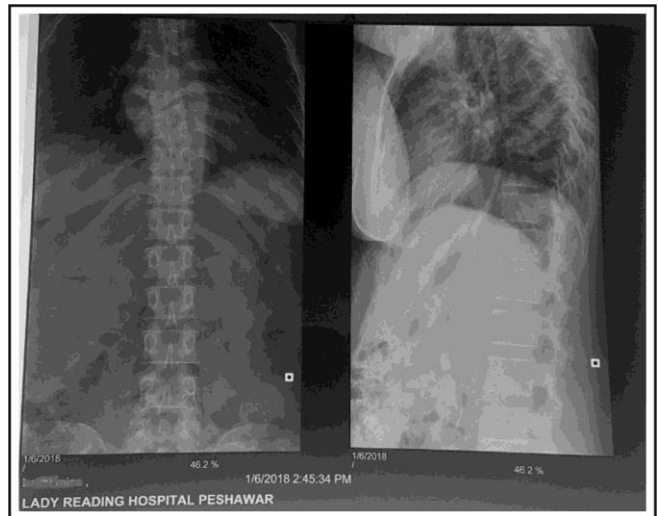**Figure 2:** A post-op picture after surgical decompression and cage placement (for scan, informed consent taken).



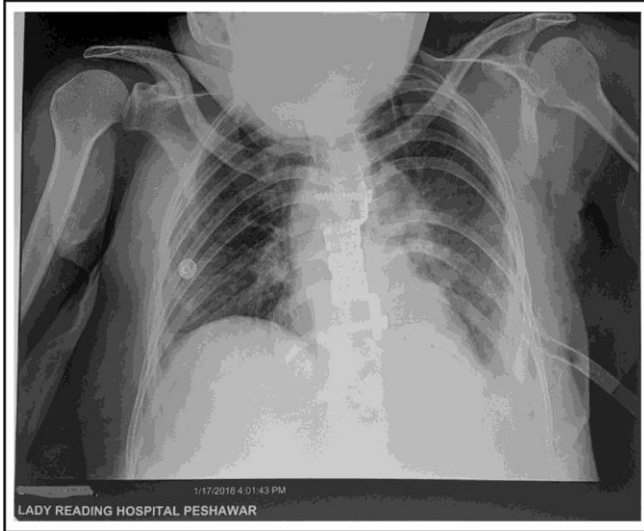
**Figure 3:** Sagittal MRI showing dorsal spine TB. (Image included with permission)



**Figure 4:** Axial MRI showing cord compression due to TB. (Image included with permission)



**Figure 5:** A pre-op X-ray showing dorsal spine TB. (Image used with permission)



**Figure 6:** A post-op X-ray after dorsal spine decompression and cage placement. (Image used with permission)

## RESULTS

### Age and Gender Distribution

A total of 38 patients were enrolled in this study that underwent a surgical procedure. Total percentages which were obtained from the study for males were 42% (16) and 58% (22) for females. The mean age of presentation was  $34 \pm 5$ .

### Clinical Information

The main procedure followed was decompression  $\pm$  fusion through the lateral thoracotomy approach. There was a neurological improvement

in 35 patients while 3 patients experienced worsening neurological symptoms. 2 patients were complicated by excessive intraoperative bleeding and postoperative CSF leak which were managed successfully. 1 patient expired as a result of a complication of the surgical procedure.

**Table 1:** Age distribution of patients included in the study (n = 38).

18 – 30 Years	08
31 – 40 Years	13
41 – 50 Years	11
51 – 60 Years	06

**Table 2:** The distribution of spinal levels involved in tuberculosis (n = 38).

Level of Disease	Presented	Percentage
D4 – D8	17	44.8%
D9 – D12	21	55.2%

**Table 3:** Distribution of procedures performed (total patients = 38).

Procedures	Presented	Percentages
Corpectomy +Cage	34	89.47%
Fixation		
Corpectomy+ Bone Graft	3	7.89%
Fixation		
Corpectomy Without	1	2.63%
Fusion		

**Table 4:** Pre-operative and post-operative Frankel grading distribution.

Type of Grading	Frankle – A	Frankle – B	Frankle – C	Frankle – D	Frankle – E
Pre-Op	5.6% (2)	11.1% (4)	47.3% (17)	33.3% (12)	8.3% (3)
Post-Op	2.8% (1)	5.6% (2)	22.2% (8)	47.3% (17)	27.8% (10)

## DISCUSSION

Spinal tuberculosis is considered a medical condition till the patient has a neurological deficit and surgery is required for decompression despite ongoing anti-tuberculosis therapy.<sup>11-12</sup> There are no straightforward guidelines for the

diagnosis and treatment of spinal tuberculosis.<sup>13</sup> Studies show that anti-tuberculosis therapy and conservative treatment have shown successful medical results in patients without surgery.<sup>14-15</sup> Certain conditions necessitate surgical options over medical treatment alone. These are lack of

improvement or recurrence following medical treatment, severe weakness in the lower limbs at presentation, and static structural or functional instability in the form of incapacitating pain or deformity.<sup>16</sup> Early diagnosis and treatment are necessary to prevent permanent neurological disability and minimize spinal deformity.<sup>17</sup>

In our study, there were 38 patients in which 42% (16) were male and 58% (22) female with a mean age of 34 years, which was compared to the previous study.<sup>18-19</sup> Neurological complications seen in our study were three patients which is less than in another study.<sup>20</sup> Studies have shown results of neurological improvement in Frankle grading following surgery which is similar to our result.<sup>21-22</sup> As can be seen from the results of our study, post-operatively highest number of patients falls into Frankle D (17/38) and Frankle E (10/38) which is the neurological grade of a healthy individual as for motor in the limbs is concerned. Complications are part of surgery and the ratio of our study was compared to another study which was more than our result.<sup>23</sup>

## CONCLUSION

Anti-TB drugs have revolutionized the treatment of tuberculosis and remain the 1<sup>st</sup> choice of management. However, in complicated cases, especially with patients having neurological deficits due to spinal TB, surgery is a useful alternative. Surgery remains the preferred mode of treatment, especially for complicated spine tuberculosis. Functional outcomes are affected by pain and spinal cord compression.

## REFERENCES

- MacNeil A, Glaziou P, Sismanidis C, Maloney S, Floyd K. Global Epidemiology of Tuberculosis and Progress Toward Achieving Global Targets — 2017. *MMWR Morb Mortal Wkly Rep.* 2019; 68: 263–266.
- Singh S, Dawar H, Das K, Mohapatra B, Prasad S. Functional and Radiological Outcomes of Anterior Decompression and Posterior Stabilization via Posterior Transpedicular Approach in Thoracic and Thoracolumbar Pott's Disease: A Retrospective Study. *Asian Spine J.* 2017; 11 (4): 618–626.
- Schirmer P, Renault CA, Holodniy M. Is spinal tuberculosis contagious? *Int J Infect Dis.* 2010; 14: e659–e666.
- Ansari S, Amanullah F, Ahmad K, Rauniyar RK. Pott's spine: diagnostic imaging modalities and technology advancements. *N Am J Med Sci.* 2013; 5: 404–411.
- Subramani S, Shetty AP, Kanna RM, Shanmuganathan R. Ossified ligamentum flavum causing neurological deficit above the level of post-tuberculous kyphotic deformity. *J Clin Orthop Trauma.* 2017; 8: 174–177.
- Jain AK. Tuberculosis of spine: Research evidence to treatment guidelines. *Indian Journal of Orthopaedics,* 2016; 50 (1): 3.
- WHO G. Global tuberculosis control. World Health Organization, 2011: 2011.
- Turgut M. Spinal tuberculosis (Pott's disease): its clinical presentation, surgical management, and outcome: a survey study on 694 patients. *Neurosurg Rev.* 2001; 24 (1): 8–13.
- Nussbaum ES, Rockswold GL, Bergman TA, Erickson DL, Seljeskog EL. Spinal tuberculosis: a diagnostic and management challenge. *J Neurosurg.* 1995; 83 (2): 243–247.
- Lee TC, Lu K, Yang LC, Huang HY, Liang CL. Transpedicular instrumentation as an adjunct in the treatment of thoracolumbar and lumbar spine tuberculosis with early stage bone destruction. *Journal of Neurosurgery: Spine,* 1999; 91 (2): 163–169.
- Zaveri G. The role of posterior surgery in spinal tuberculosis. *Argo Spine News & Journal.* 2011; 23 (3): 112–119.
- Khoo LT, Mikawa K, Fessler RG. A surgical revisit of Pott distemper of the spine. *The Spine Journal,* 2003 Mar. 1; 3 (2): 130–45.
- Garg RK, Somvanshi DS. Spinal tuberculosis: a review. *The journal of Spinal Cord Medicine,* 2011; 34 (5): 440–54.
- Rajasekaran S, Shanmugasundaram TK, Prabhakar R, Dheenadhayalan J, Shetty AP, Shetty DK. Tuberculous lesions of the lumbosacral region: a 15-year follow-up of patients treated by ambulant

- chemotherapy. *Spine*, 1998; 23 (10): 1163-1167.
15. Konstam PG, Blesovsky A. The ambulant treatment of spinal tuberculosis. *Journal of British Surgery*, 1962; 50 (219): 26-38.
  16. Shetty A, Kanna RM, Rajasekaran S. TB spine—Current aspects on clinical presentation, diagnosis, and management options. In *Seminars in Spine Surgery*, 2016 Sep 1; Vol. 28, No. 3: pp. 150-162. WB Saunders.
  17. Jain AK, Dhammi IK. Tuberculosis of the spine: a review. *Clinical Orthopaedics and Related Research*, 2007; 460: 39-49.
  18. Liu Z, Liu J, Peng A, Long X, Yang D, Huang S. One-stage posterior debridement and transpedicular screw fixation for treating monosegmental thoracic and lumbar spinal tuberculosis in adults. *The Scientific World Journal*, 2014: 2014.
  19. Alam MS, Phan K, Karim R, Jonayed SA, Munir HK, Chakraborty S, Alam T. Surgery for spinal tuberculosis: a multi-center experience of 582 cases. *Journal of Spine Surgery*, 2015; 1 (1): 65.
  20. Yin H, Wang K, Gao Y, Zhang Y, Liu W, Song Y et al. Surgical approach and management outcomes for junction tuberculous spondylitis: a retrospective study of 77 patients. *J Orthop Surg Res*. 2018; 13: 312.
  21. Jin D, Qu D, Chen J, Zhang H. One-stage anterior interbody autografting and instrumentation in primary surgical management of thoracolumbar spinal tuberculosis. *Eur Spine J*. 2004; 13 (2): 114-121.
  22. Cui X, Ma YZ, Chen X, Cai XJ, Li HW, Bai YB. Outcomes of Different Surgical Procedures in the Treatment of Spinal Tuberculosis in Adults. *Med Princ Pract*. 2013; 22: 346-350.
  23. Xu Z, Wang X, Shen X, Luo C, Zeng H, Zhang P, et al. Posterior only versus combined posterior and anterior approaches for lower lumbar tuberculous spondylitis with neurological deficits in the aged. *Spinal Cord*, 2015; 53 (6): 482-487.

## Additional Information

**Disclosures:** Authors report no conflict of interest.

**Ethical Review Board Approval:** The study was conformed to the ethical review board requirements.

**Human Subjects:** Consent was obtained by all patients/participants in this study.

### Conflicts of Interest:

In compliance with the ICMJE uniform disclosure form, all authors declare the following:

**Financial Relationships:** All authors have declared that they have no financial relationships at present or within the previous three years with any organizations that might have an interest in the submitted work.

**Other Relationships:** All authors have declared that there are no other relationships or activities that could appear to have influenced the submitted work.

## AUTHORS CONTRIBUTIONS

Sr.#	Author's Full Name	Intellectual Contribution to Paper in Terms of:
1.	Arif Hussain	1. Study design and methodology.
2.	Musawer Khan	2. Paper writing and data calculations.
3.	Arif Hussain	3. Data collection and calculations.
4.	Sajid Khan	4. Analysis of data and interpretation of results etc.
5.	Musawer Khan	5. Literature review and referencing.
6.	Mumtaz Ali	6. Analysis of data and quality insurer.