

Original Article (BRAIN)

Surgical Outcome of Traumatic Posterior Fossa Extradural Hematoma in Paediatric Population: Our Experience at UCHS, The Children's Hospital, Lahore

Jamal Nasir¹, Faiq Sheikh², Saba Beenish¹, Laeeq-ur-Rehman¹, Ali Asad³, Lubna Ejaz¹

¹University of Child Health Sciences, The Children's Hospital, ²Punjab Institute of Neurosciences (PINS),

³Services Institute of medical sciences (SIMS), Lahore, Pakistan

ABSTRACT

Objective: Most common location for Extradural hematoma (EDH) is within the supratentorial region. The incidence of Posterior fossa extradural hematoma (PFEDH) is 1.2% to 12.9% of all EDH. The purpose of this study is to evaluate the management, clinical outcomes, and epidemiological features of posterior fossa EDH.

Materials and Methods: A cross-sectional study was conducted at the department of pediatric neurosurgery Children Hospital and the University of child health sciences, Lahore from September 2021 to December 2021. Thirty patients presented with posterior fossa extradural hematoma in the pediatric age group were included. A plain CT scan Brain with the bone window was done for initial diagnosis to assess any injury in the posterior fossa including volume of hematoma and any associated fracture. Glasgow Coma Scale (GCS) was used to evaluate the outcome.

Results: Twenty-five patients were surgically treated, and five patients were managed conservatively. There was no mortality observed and the overall results were good in all the patients.

Conclusion: As compared to supratentorial extradural hematoma the Posterior fossa epidural hematoma is uncommon. For all suspected cases early and serial CT scans must be carried out. There was an excellent prognosis in pediatric patients who underwent surgical management.

Keywords: Extradural Hematoma, Glasgow Coma Scale (GCS), Posterior Cranial Fossa, Occipital Fracture.

Abbreviations: EDH: Extradural Hematoma. PFEDH: Posterior Fossa Extradural Hematoma, GCS: Glasgow Coma Scale.

Corresponding Author: Dr. Jamal Nasir
University of Child Health Sciences, The Children's Hospital,
Lahore, Pakistan
Email:

Date of Online Publishing: 30-06-2022

Date of Print: 30-06-2022

DOI: 10.36552/pjns.v26i2.677

Date of Submission: 10-04-2022

Date of Revision: 15-05-2022

Date of Acceptance: 29-06-2022

INTRODUCTION

Hematoma occupying the space between the

inner table of the skull and the outer layer of the duramater is known as Extradural hematoma. It occurs in approximately 10% of all traumatic brain injuries requiring hospitalization.² Traumatic causes include physical assaults, roadside accidents, and accidental falls. While abscess, coagulopathy, hemorrhagic tumors, infection, and vascular malformations are non-traumatic causes of EDH. The most common source of bleeding is the middle meningeal artery.³ Diploic venous bleed and dural venous injury can also cause EDH. EDH is unilateral in 95% of cases.⁴ Bilateral and multiple EDH have also been reported. Most commonly EDH occurs in the Temporoparietal region (60%) followed by the Frontal (20%) and Parieto-occipital (20%) regions. Less than 5% EDH are Infratentorial in posterior fossa.⁵ Anterior and middle cranial fossa EDH can be caused by injury sphenoparietal sinus. A lucid interval is a period between regaining consciousness after a short period of unconsciousness. This is an important symptom of EDH. But it may not occur in all patients. Irritability, pallor, altered level of consciousness and convulsions are the most important symptoms in infants.⁶ Important signs are bulging fontanelle, bradycardia, and respiratory distress. The classical pattern after trauma in toddlers is lucid interval followed by rapid progression of neurological symptoms which include contralateral hemiparesis, ipsilateral oculomotor nerve paresis, obtundation, decerebrate rigidity, arterial hypertension, cardiac arrhythmias, respiratory disturbances leading to apnea and mortality. The most common symptoms in children include vomiting, headache, loss of consciousness, and fits. A history of head trauma with presenting complaints of loss of consciousness and vomiting directed toward EDH. Although a patient with PFEDH remains conscious until late in the evolution of hematoma then there is a sudden loss of consciousness and apnea leading to death. The lesions can strip off the duramater over transverse sinus swelling extending into the supratentorial compartment

and causing a significant amount of intracranial bleed. Signs of raised intracranial pressure are observed with enlarging hematoma, which includes an increase in blood pressure, decreased heart rate, and irregular breathing (Cushing reflex).⁷ Patients with signs of raised intracranial pressure need emergency surgery to prevent CNS depression and death. CT brain plain is the mainstay of diagnosis. Due to the fixed attachment of dura mater and cranial sutures the blood is confined there, thus it is seen as a lens-shaped mass or biconvex on a CT scan. But in the case of sutural diastasis, as the continuation of the parietal layer (periosteal) component of the dura is disrupted, EDH can cross sutures. Some studies state that approximately 11% of EDH cross sutures in the pediatric population.⁸

But in the case of posterior fossa EDH surgical evacuation is needed if the volume is 15 ml or more, midline shift of 5mm or more and cistern obliteration is present. PFEDH can be managed conservatively if Volume is less than 15 ml, GCS more than 8 along with no focal neurological abnormalities, clot diameter is less than 15 mm, and MLS less than 5 mm.⁹

EDH has an excellent prognosis if treated early, therefore a CT brain should be done within six to eight hours following head injury. Many factors influence the outcome including the age of the patient, the time interval between treatment and injury, presence of pupillary abnormalities (non-reactive pupil unilaterally or bilaterally), low GCS upon admission or intervention, raised intracranial pressure, Volume greater than 30 ml, MLS > than 5 to 10 mm,¹⁰ Swirl sign: Immediate intracranial bleed associated with intracranial lesions such as contusions, intracranial or subarachnoid hemorrhage.¹¹ Complications of EDH may include brain herniation, infarction, hydrocephalus, and seizures.¹² Therefore, PFEDH requires urgent and aggressive management as it is an acute emergency. As head injury is a major issue in our society, urgent management especially in cases of

PFEDH can significantly lead to reduced morbidity and mortality.

MATERIALS AND METHODS

Study Design and Setting

Our study was a cross-sectional study conducted at the department of pediatric neurosurgery Children Hospital and the University of child health sciences, Lahore over 3 months including 3 months follow-ups, after the approval from the hospital's ethical review committee.

Inclusion Criteria

Patients with posterior fossa extradural hematoma due to traumatic head injury aged less than 15 years.

Exclusion Criteria

Patients with clotting and bleeding disorders or taking anticoagulants and the ones with polytrauma were excluded from the study.

Clinical Management and Data Collection

After approval of the study from the ethical review committee, all the patients presenting to pediatric Neurosurgical emergency were evaluated and patients satisfying the inclusion criteria were enrolled in the study after taking informed consent. Assessment of level of consciousness (according to Glasgow Coma Scale, GCS) and pupillary size/reactivity were carried out. The imaging modality of choice was plain CT Brain. Initially, intravenous fluids, analgesics, and antibiotics were administered, and routine biochemical investigations were done. X-rays of the skull, cervical spine, and chest along with FAST scans were conducted whenever needed. Patients with severe head injuries were shifted to intensive care and ventilation was done in such cases. Surgery was performed where indicated.

Patients were followed up for 3 months after discharge to assess outcomes and complications. The outcome was measured by the Glasgow coma scale.

Data collection was according to the age and gender, mechanism and mode of injury, GCS score on admission, mode of arrival and prehospitalization delay, presenting complaints of ALOC, vomiting, seizures, ENT bleed, findings on CT brain, any surgical intervention, and social status of the family.

Surgical Management

Unilateral Hematoma: Posterior midline skin incision given, unilateral craniotomy done, and EDH was evacuated. Uplifting of dura matter done with 4/0 vicryl. Bilateral Hematoma: Bilateral craniectomy was done and EDH was evacuated, uplifting of dura matter was done with 4/0 vicryl.

RESULTS

Age and Gender Distribution

Patients from age 1 year to 12 years presented to us with a mean age of 5 years. Out of the patients who presented to us there were twenty-one males and nine females with a male to female ratio of 70:30.

The Pattern of Injury

The most common cause of PFEDH was from falls (90%) followed by road traffic accidents (10%).

Most of the patients (N = 25) were admitted within 4 hours of head injury, while four were admitted within 24 hours and only one presented after 24 hours.

Twenty patients presented with a moderate head injury, while six presented with mild and four with a severe head injury. The mean GCS on presentation was 12.

Vomiting was the most common symptom on presentation followed by headache.

We observed occipital bone fracture in all the patients. The volume of hematoma ranged in-between 3 ml to 25 ml. The average hematoma volume in surgical patients was 20ml while it was 8ml in patients managed conservatively as shown in Table 1.

Table 1: Summary of Management and the average volume of Hematoma.

| Management | Average Volume of Hematoma |
|--------------|----------------------------|
| Surgical | 20ml |
| Conservative | 8 ml |

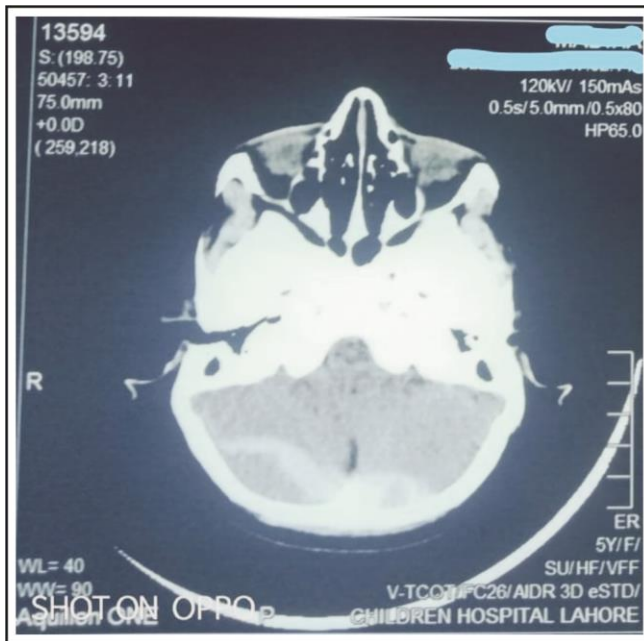


Figure 1: Plaintiff CT Brain with Bilateral PFEDH (Image was used after patient consent).

Clinical Management

Twenty-five patients underwent a surgical procedure while 5 were managed conservatively. Patients who underwent surgical management were discharged on the 3rd day with a GCS of 15/15. Patients who were managed conservatively were kept in the intensive care unit and had minimal neurological defects. Serial CT scans were done and all of them were discharged on the 5th day with a GCS of 15/15. Clinical data regarding

the management of patients is summarized in Table 2.

Table 2: Data of patients with PFEDH.

| Clinical Data | Number of Patients | | |
|---------------------------------|--------------------|--------------|-------|
| | Operative | Conservative | Total |
| Mode of Injury | | | |
| Fall | 23 | 4 | 27 |
| RTA | 2 | 1 | 03 |
| Time of Arrival | | | |
| <4 Hrs | 23 | 2 | 25 |
| 4-24Hrs | 2 | 2 | 4 |
| >24 Hrs | 0 | 1 | 1 |
| Symptoms | | | |
| ASOC | 2 | 0 | |
| Vomiting | 25 | 5 | 30 |
| Seizures | 2 | 0 | 2 |
| Headache | 18 | 4 | 0 |
| Ventilatory Support | 4 | 0 | 4 |
| Asymptomatic | 0 | 0 | 0 |
| GCS on Admission | | | |
| 3-8 | 4 | 0 | 4 |
| 9-12 | 18 | 2 | 20 |
| 13-15 | 3 | 3 | 6 |
| Head CT and scan Finding | | | |
| Subarachnoid | 6 | 4 | 10 |
| Hemorrhage | 26 | 4 | 30 |
| Brain Edema | 0 | 0 | 0 |
| Linear Skull Fracture | 0 | 2 | 2 |
| Depressed skull Fracture | 0 | 0 | 0 |
| Contusion | 0 | 0 | 0 |
| Pneumocephalus | 2 | 0 | 2 |
| Intra ventricular Hemorrhage | 0 | 0 | 0 |
| Hydrocephalus | 0 | 0 | 0 |
| Infarction | | | |

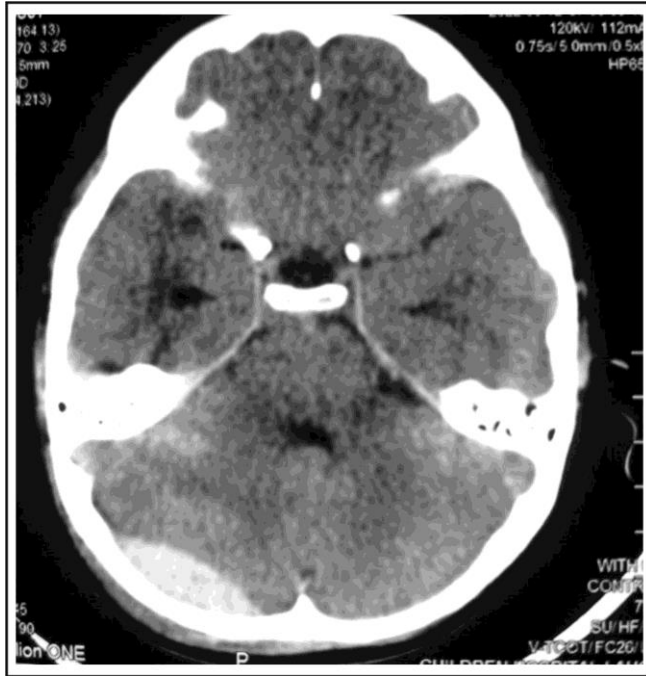


Figure 2: Plain CT brain with Right-sided PFEDH (Image was used after patient consent).

DISCUSSION

PFEDH in pediatric patients is not very common.^{13,16-18} There are few clinical reports regarding it in the literature in recent times.¹³⁻¹⁸ But we frequently encounter cases of PFEDH as our institution is the only pediatric neurosurgery unit in the largest province of Pakistan, with an expert team of trained pediatric neurosurgeons.

Fall (90% of the patients) was the most common cause of PFEDHs in our study, and it was consistent with previous studies in the pediatric population.^{13,16,17,18} Second most common cause was a road traffic accident.

The most common clinical findings in our study population were vomiting followed by headache which is consistent with previous studies. Although lucid interval is seen in patients with EDH, it is more often noted in patients with supratentorial lesions, it was uncommon in our study as it was observed in three patients only.¹⁶⁻¹⁸

There were four cases of severe head injury, while twenty were moderate and six were mild.

Patients with severe head injuries were admitted for 5 days while the rest were discharged on the 3rd day. Our study was consistent with previous studies which concluded that the main determinant of the outcome in a pediatric population with PFEDH was the GCS score upon admission.

A plain CT is the most useful imaging tool upon admission. In addition, we advise serial CT scans as well in cases that are to be treated conservatively, especially for the first 72 hours, and patients who have hydrocephalus preoperatively on CT scan. It can detect the volume and location of hematomas, fracture of the occipital bone, and associated lesions in the supratentorial region well before the clinical signs appear. Although hydrocephalus or ventricular dilation is less frequent in pediatric PFEDHs, their presence is considered a sign of poor prognosis. In our study, 3 such cases were immediately surgically resolved. While Chaoguo et al. noted 6 such cases.²¹ There were 2 cases of Hydrocephalus in our study which were successfully treated after surgery and discharged with a GCS of 15.

In our study, all the patients had an occipital bone fracture of which 3 patients had midline fracture which resulted in bilateral PFEDH which is consistent with previous studies shown in figure 1.0.^{16,19} While, Sencer et al. and Chaoguo et al. noted a high incidence of occipital bone fracture occurring in 87.5% and 79.2% of the study population respectively.²¹

In this study, all patients with a hematoma volume of more than 14 mL or compression of the fourth ventricle or displacement and/or obstructive ventriculomegaly were immediately surgically treated. The average volume of hematoma in surgically treated patients was 20ml.

The most trusted treatment for PFEHD is surgical evacuation. Concrete studies list the following as indications for urgent surgical treatment: But in the case of posterior fossa EDH, surgical evacuation is needed if volume > 15 ml

or more, $MLS > 5\text{mm}$, Cistern obliteration.¹¹ Prasad et al, suggested a hematoma with a volume of more than 20 mL or radiological evidence of posterior fossa compression in the form of fourth ventricle distortion or compression and/or obstructive ventriculomegaly, regardless of the GCS score as an indication for surgical evacuation. While, Chaoguo et al, stated Clot volume of more than 14 mL or compression of the fourth ventricle or displacement and/or obstructive ventriculomegaly is a surgical indication. Furthermore, it was suggested by Sencer et al. on the importance of hematoma thickness rather than volume as surgical important criteria. In the forty cases, he studied all the patients with a hematoma thickness of less than 5 mm were followed up conservatively.^{18,21}

Kumar et al concluded that the patients with GCS less than 8 and hematoma size more than 3 cm should undergo surgical intervention within 12 hours. Patients with GCS less than 8 had a poor outcome. He also stated that patients with PFEDH can be managed conservatively if they have a hematoma size of less than 3 cm and GCS of more than 13. Thus, it was concluded that the main factor for outcome was GCS. Patients having GCS 8 or less and hematoma volume of 3.5 cm in the posterior fossa causing a shift were operated on within hours in our study.²⁰

Recent studies have indicated that the prognosis of PFEDH is good if treated aggressively. Chaoguo et al. reported a good outcome for patients with no mortality. Similarly, Berker et al, the study showed only one case of mortality and moderate disability each, while Sencer et al. reported forty cases with good outcomes.^{13,18,21} The result of our study showed good outcomes in all the patients as all were discharged with a GCS of 15/15. Therefore, we suggest that for a good outcome, and reduced mortality, and morbidity the surgical evacuation of a hematoma should be done timely.

CONCLUSION

When compared with supratentorial epidural Hematoma, PFEDH is less frequent but early and serial CT must be done in a suspicious case. Surgical evacuation is the preferred mode of treatment for PFEDH as the overall prognosis is good.

REFERENCES

1. Rosenthal AA, Solomon RJ, Eyerly-Webb SA, Sanchez R, Lee SK, Kiffin C, Davare DL, Hranjec T, Carrillo EH. Traumatic epidural hematoma: patient characteristics and management. *The American Surgeon*. 2017; 83 (11): 438-40.
2. Tamburrelli FC, Meluzio MC, Masci G, Perna A, Burrofato A, Proietti L. Etiopathogenesis of traumatic spinal epidural hematoma. *Neurospine*. 2018; 15 (1): 101.
3. Pryse-Phillips W. *Companion to clinical neurology*. Oxford University Press; 2009 Jun 3.
4. Takeuchi S, Wada K, Takasato Y, Masaoka H, Hayakawa T, Yatsushige H, Shigeta K, Momose T, Otani N, Nawashiro H, Shima K. Traumatic hematoma of the posterior fossa. In *Brain Edema XV 2013*: pp. 135-138. Springer, Vienna.
5. Huisman TA, Tschirch FT. Epidural hematoma in children: do cranial sutures act as a barrier? *Journal of Neuroradiology*. 2009; 36 (2): 93-7.
6. Ciurea AV, Kapsalaki EZ, Coman TC, Roberts JL, Robinson J3, Tascu A, Brehar F, Fountas KN. Supratentorial epidural hematoma of traumatic etiology in infants. *Child's nervous system*. 2007; 23 (3): 335-41.
7. Agrawal A, Timothy J et-al Bradycardia in neurosurgery *clinNeurol Neurosurg*. 2008 Apr; 110 (4): 321-7.
8. Hisman TA, Tscirch FT. Epidural hematoma in children: do cranial sutures act as abarrier? *Neuroradial*. 2009; 36 (2): 93-7.
9. Bedry T, Tadele H. Pattern and outcome of pediatric traumatic brain injury at hawassa university comprehensive specialized hospital, southern Ethiopia: observational cross-sectional study. *Emergency Medicine International*. 2020; 2020.

10. Khairat A, Waseem M. Epidural hematoma. In Stat Pearls [Internet] 2021 Aug 2. Stat Pearls Publishing.
11. Al-Nakshabandi NA. The swirl sign. Radiology. 2001; 218 (2): 433-.
12. Shahlaie K, Zweienenberg-Lee M, Muizelaar JP. Clinical pathophysiology of traumatic brain injury. In: Winn HR, ed. Youmans and Winn Neurological Surgery. 7th ed. Philadelphia, PA: Elsevier, 2017: Chap 346.
13. Berker M, Cataltepe O, Özcan OE. Traumatic epidural haematoma of the posterior fossa in childhood: 16 new cases and a review of the literature. British Journal of Neurosurgery. 2003; 17 (3): 226-9.
14. Ciurea AV, Nuteanu L, Simionescu N, Georgescu S. Posterior fossa extradural hematomas in children: report of nine cases. Child's Nervous System. 1993; 9 (4): 224-8.
15. Ersahin Y, Mutluer S: Posterior fossa extradural hematomas in children. Pediatr Neurosurg. 1993; 19: 31-33.
16. Gupta PK, Mahapatra AK, Lad SD: Posterior fossa extradural hematoma. Indian J Pediatr. 2002; 69: 489-494.
17. Prasad GL, Gupta DK, Sharma BS, Mahapatra AK: Traumatic pediatric posterior fossa extradural hematomas: a tertiary-care trauma center experience from India. Pediatr Neurosurg. 2015; 50: 250-256.
18. Sencer A, Aras Y, AkcAkAyA MO, Goker B, Kiris T, Canbolat AT. Posterior fossa epidural hematomas in children: clinical experience with 40 cases. Journal of Neurosurgery: Pediatrics. 2012; 9 (2): 139-43.
19. Malik NK, Makhdoomi R, Indira B, Shankar S, Sastry K. Posterior fossa extradural hematoma: our experience and review of the literature. Surgical Neurology. 2007; 68 (2): 155-8.
20. Kumar JS, Kumar GT, Gaurav J, Kumar LV, Patel P. Traumatic isolated intracerebellar haematoma without any supratentorial lesion. A rare entity. Management strategy. Romanian Neurosurgery, 2020; 34 (4).
21. Chaoguo Y, Xiu L, Liuxun H, Hansong S, Nu Z. Traumatic posterior fossa epidural hematomas in children: experience with 48 cases and a review of the literature. Journal of Korean Neurosurgical Society. 2019; 62 (2): 225.

Additional Information

Disclosures: Authors report no conflict of interest.

Ethical Review Board Approval: The study was conformed to the ethical review board requirements.

Human Subjects: Consent was obtained by all patients/participants in this study.

Conflicts of Interest:

In compliance with the ICMJE uniform disclosure form, all authors declare the following:

Financial Relationships: All authors have declared that they have no financial relationships at present or within the previous three years with any organizations that might have an interest in the submitted work.

Other Relationships: All authors have declared that there are no other relationships or activities that could appear to have influenced the submitted work.

AUTHORS CONTRIBUTIONS

| Sr.# | Author's Full Name | Intellectual Contribution to Paper in Terms of: |
|-------------|---------------------------|--|
| 1. | Jamal Nasir | Study design and methodology. |
| 2. | Faiq Sheikh | Analysis of data and quality insurer. |
| 3. | Saba Benish | Data calculations. |
| 4. | Laeq-ur-Rehman | Literature review. |
| 5. | Ali Asad | Paper writing and referencing. |
| 6. | Lubna Ejaz | Analysis of data and interpretation of results. |