

Original Article (SPINE)

An Emerging Minimally Invasive Ozone Therapy for Spinal Disc Disease and Its Outcome

Fahmida Arab Mallah¹, Syed Aamir Shah², Imran Mirbaheer¹, Muzamil Dilbar¹
Abdul Razaque Mari, Obaidullah²

¹Peoples University of Medical and Health Sciences for Women (PUMHSW), Nawabshah – Shaheed Benazirabad, Pakistan

²Shaheed Zulfiqar Ali Bhutto Medical University (SZABMU), PIMS, Islamabad, Pakistan

ABSTRACT

Objectives: To analyze the effect and outcome of ozone therapy in herniated cervical and lumbar disc disease.

Material and Methods: A prospective study was conducted in the Neurosurgery Department of Federal Medical, Teaching Hospital Islamabad from March 2015 to December 2019. 310 patients with neck ache, and backache with radiculopathy were enrolled. Magnetic resonance imaging and the computed tomographic scan were done. 4 to 6 ml of ozone were inserted in disc space. Periodic follow-up was done for up to 6 months of therapy. A single session of therapy was required in 55%, twice in 22.5%, and multiple in 13% of patients.

Results: Out of 310 patients, n = 220 were male and 90 females. Cervical herniated discs were 30 and lumbar 280, single cervical disc herniation was found in n = 26 and multiple in n = 4 while the single-level herniated lumbar disc was n = 220 and multiple in n = 60. Self-analysis of pain before intervention was assessed by visual analog, scored was VAS 4 in n = 80, VAS 5 – 6 in n = 120, VAS 7 – 9 in n = 70, and VAS 10 in n = 40 patients. Post-intervention prognosis according to Modified Mac nab was Excellent in 54%, good in 29%, Fair in 13%, and poor in 3.2% of patients.

Conclusions: Ozone discolysis can be considered as a bridging therapy between nonsurgical versus surgical methods for herniated cervical and lumbar disc, it is a relatively safe, inexpensive, minimally invasive method that effectively reduces the intensity of pain related to herniated spinal disc and improves the quality of life.

Keywords: Ozone therapy. Minimally Invasive. Prolapsed disc. Neckache. Backache. Radiculopathy, Chemodiscolysis.

Correspondence Author: Fahmida Arab Mallah
Assistant Professor, Neurosurgery
Peoples University of Medical and Health Sciences
For Women, Nawabshah – Shaheed Benazirabad
Email: fahmidamallah25@gmail.com

Date of Revision: 00-00-2022
Date of Acceptance: 00-00-2022
Date of Online Publishing: 31-3-2022
Date of Print: 31-3-2022

DOI: 10.36552/pjns.v26i1.648

Date of Submission: 00-00-2022

INTRODUCTION

Degenerative spinal disease with disc herniation may present with a variety of clinical features the most common are pain and radiculopathy depending on the involved segment of the spine. Acute or chronic cervical disc herniation may present with neckache, radiculopathy, and myelopathy of the concerned level while lumbar disc herniation may present with low backache, sciatica, sensory or motor deficit.^{1,2}

Radicular pain in a herniated disc, most of the time is due to direct mechanical compression of a nerve root or dorsal root ganglion and indirectly when peri-neural vessels are compressed.³

When annulus fibrosis is injured and disc contents prolapsed, inflamed epidural tissue surrounding the nerve root and facet capsule produces a series of inflammatory factors that mediate inflammation and activation and sensitization of afferent nociceptive receptors to mild pressure or manipulation. Because of this inflammatory cascade patient may feel severe pain in the absence of significant direct disc herniation and nerve compression.^{4,5}

The natural history of disc herniation explains that most of the time in two-thirds of patients herniated segment spontaneously regresses and acute pain may resolve in approximately 6 – 12 weeks from onset.⁶ For ages Magnetic resonance imaging to evaluate soft tissue physiological and pathological lesions is considered to be the modality of excellence however one cannot deny the usefulness of computed tomographic scan to rectify bony structural changes. Both have got an advantage in the diagnosis of spinal degenerative and pathological lesions.⁷

Symptomatic disc herniation was initially managed conservatively with bed rest, analgesics, muscle relaxants physical therapy, and lifestyle non-invasive modification.⁸ Both invasive and noninvasive therapy is considered in patients with failure of the above-mentioned therapy for at least 4 to 6 months, or the presence of new neuro-deficit and intolerant pain.⁹

No doubt open surgery has the most promising results, due to maximal tissue manipulations most treating physicians and patients preferred less invasive methods. Among such minimal invasive methods intradiscal ozone injection has been considered the safest and most effective procedure.¹⁰

In our study, we used only an intradiscal ozone solution of about 3ml to 5ml in selected cases of herniated cervical and lumbar disc, and the outcome was monitored.

MATERIAL AND METHODS

A prospective type of study was conducted in the department of neurosurgery federal medical and teaching hospital Islamabad from March 2015 to December 2019.

Inclusion Criteria

Patients aged between 25 to 90 years, neckache with radiculopathy with or without sensory loss, low backache with sciatica with and without sensory loss, visual analog score 5 and above, failure of pharmacological and physical therapy more than 3 months, failed back syndrome, refuse to take multiple analgesics and patient preference for minimally invasive therapy were included in the study.

Radiological Criteria

Annulus tear with diffuse disc bulge at cervical or lumbar level and findings correlated with clinical assessment were included.

Exclusion criteria

Age less than 25 years (visual analog score) VAS score less than 5, acute traumatic disc and neuro-deficit, cauda equine syndrome, bleeding disorder, uncontrolled diabetes mellitus, hypertension, and active ischemic heart disease were excluded from the study.

Radiological Criteria

Calcified disc, extruded disc, dorsal spine disc, Inflammatory and neoplastic lesions involving the spine and paravertebral muscles, structural deformity of the spine, and pregnancy were excluded.

Clinical Management & Data collection

The patient who presented to us with clinical features of disc herniation, backache, sciatica, neck ache, and brachialgia was admitted to the neurosurgery ward and plain magnetic resonance imaging was utilized to identify the herniated spinal disc, and a Computed tomographic scan was done to clarify calcified disc. Pre-intervention of ozone therapy, the pain was analyzed by visual analog score and post-intervention assessment was done by modified Macnab criteria by excellent, good, fair, and poor prognosis. All patients have clearly described the percutaneous insertion of ozone solution into disc space and use of fluoroscope, procedure-related prognosis and consequences, dose and effect of ozone solution was mentioned in proforma. An approval from the hospital ethical committee was received and guardians were well informed, confabulated, and consented in writing.

Data Analysis

All collected data were analyzed by using SPSS (statistical package for social services), version 25 data analyzer.

Numerical Data

Mean and standard deviations were calculated for numerical data like age.

Categorical Data

Like gender location and type of prolapsed disc, a dose of ozone solution, clinical grading of pain,

and prognosis of the patient were presented as percentages and frequencies.

RESULTS

Age and Demographic Assessment

Among 310 patients with degenerative cervical and lumbar disc herniation, a male was 220 and a female was 90 with a male to female ratio of 3:1.

Radiological Investigations

All patients who presented with Pain including neck ache or backache with radiculopathy without major motor deficit were investigated thoroughly and Magnetic resonance imaging (MRI) and computed tomographic scan (CT Scan) of the lumbar and cervical spine was mandatory done in all patients.

Location of Herniated Discs

The cervical herniated disc was found in 30 patients with a single-level cervical disc in 86% and multiple in 13% (detail in Table 1). The herniated lumbar disc was found in 280 patients with a single-level lumbar herniated disc was found in 79% and multiple was in 21% of patients further (detail in Table 1). Careful selection of patients was done by co-relating clinical features with radiological findings.

Clinical Assessment

A visual analog scale was used to assess the pain experienced by individual patients and scoring by them. VAS grade 5 (moderate pain) was found in (25%), VAS 6(severe) in 38%, VAS 7 – 9 (very severe) in 22%, VAS 10(worst) in 12% of patients with a mean duration of pain was 12 to 16 weeks. The patient who met the sample criteria were admitted for daycare procedures and prepared for ozone therapy.

Ozone Therapy Procedure

The procedure was done in the operation theater in the prone position, the concerned area was scrubbed with an aseptic solution, and sterilized draping was applied. Before insertion of Chiba needle of 24-gauge subcutaneous infiltration of 2 ml of xylocaine and adrenaline was done to reduce local pain bleeding. In the case of a lumbar herniated disc, the Chiba needle was introduced through posterolateral through superior articular space then directed medially into the center of disc space within nucleus pulposus and exact localization was confirmed by anterior-posterior and lateral images by intraoperative fluoroscope or image intensifier. Figure 1. In the case of cervical disc, herniation patient was kept in the supine position, the procedure was performed from the right side with head tilted slightly 15 degrees to the opposite side with slight neck extension of 15-degree position of needle maintained under the control of c arm fluoroscopy. Sternocleidomastoid muscle was used as a key landmark and Chiba needle was introduced carefully in between neurovascular bundle that Internal carotid artery laterally and trachea and esophagus medially about 3 to 5 ml of ozone mixture was introduced inside the disc space into and around nucleus pulposus and exact localization was confirmed by C-arm fluoroscope. The ozone mixture was automatically made by a real-time ozone machine. It takes about 2 to 3 minutes for the solution to spread along with herniated disc space. When the procedure is finalized, the

patient is kept on the procedure table for a maximum of 10 minutes and then shifted to the recovery room for 1-hour observation. Immediately after the procedure, the pain was evaluated and compared with the pre-operative VAS score. Immediate pain resolution was found in 54% and scored from VAS 6 to VAS 0.

Follow-up and Outcome

Within 1st week Pain resolution in 29% of patients was from VAS 5 to VAS 1 and after a month remarkable improvement was found in 3.2% of patients from VAS 10 to VAS 1.

Frequency of Ozone Therapy Procedures

Further estimation of pain and numbness was done at regular follow-up for up to 6 months. Figures 2 and 3. Patients who fail to improve within 1st week of a single shot of ozone therapy were booked for 2nd and 3rd trials (Table 2). In our study most of our patients got improvement within three trials of ozone therapy, none of them need 4th trial of ozone therapy. Further outcome and prognosis were judged by Modified Macnab criteria by Excellent in 54%, good in 29%, Fair in 13% and poor in 3.2% of patients. Patients with cervical disc prolapsed had more severe neck - ache and radiculopathy as compared to lumbar prolapsed disc with backache and radiculopathy has got dramatic improvement in pain, we also noticed a relatively better prognosis in elderly patients with a dehydrated disc.

Table 1: Distribution of Prolapse Disc at Different Levels.

Level of Disc Herniation	Distribution of Disc Herniation			
	Single Level	No. of Patients with Percentage	Multiple Levels	
Cervical	C4 – C6	7 (2.2%)	C4 – C5 – C6	4 (1.2%)
	C5 – C6	14 (4.5%)		
	C6 – C7	5 (1.6%)		
Lumber	L2 – L3	30 (9.6%)	L2 – L3 – L4	2 (0.6%)
	L4 – L5	130 (42%)	L3 – L4 – L5	18 (5.8%)
	L5 – S1	60 (19%)	L4 – L5 – S1	40 (13%)

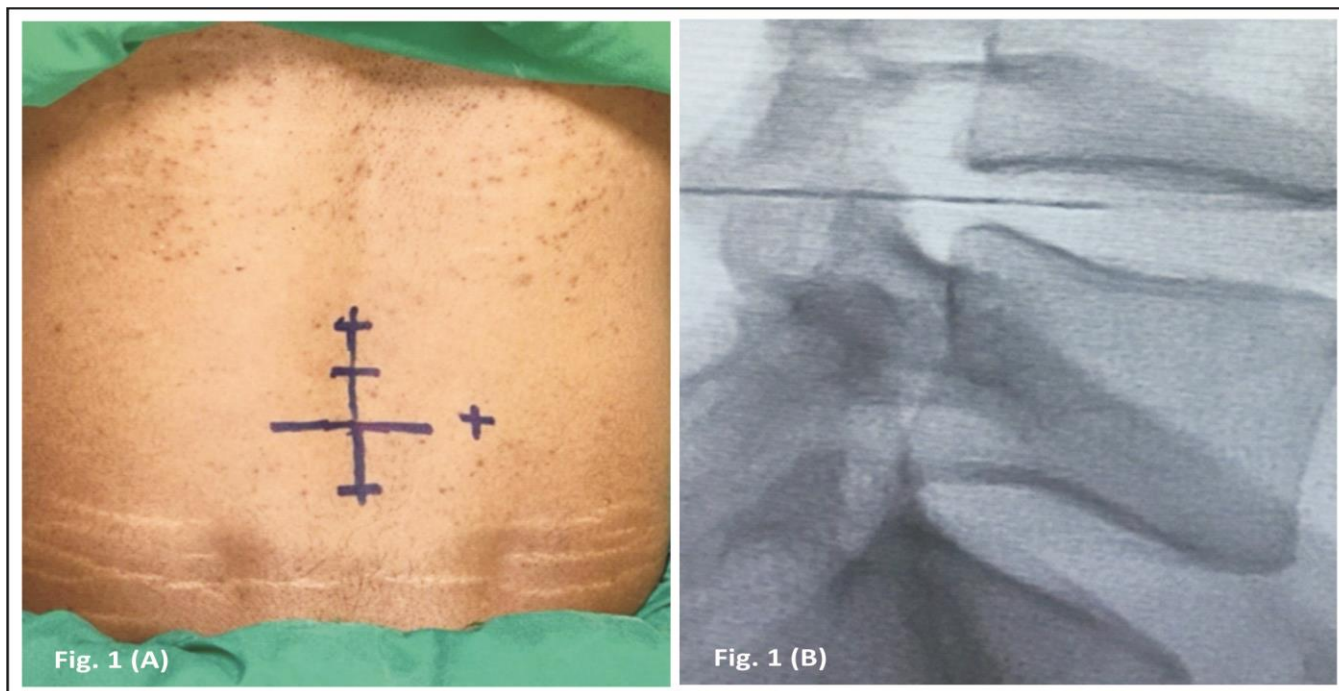


Figure 1: (Pictures included with patients' consent).

Fig 1(A): Intra procedural marking and site of insertion of Chiba needle.

Fig 1(B): Use of Intra operative image intensifier showing site of Chiba needle and ozone infiltration at L4-L5 intervertebral disc.

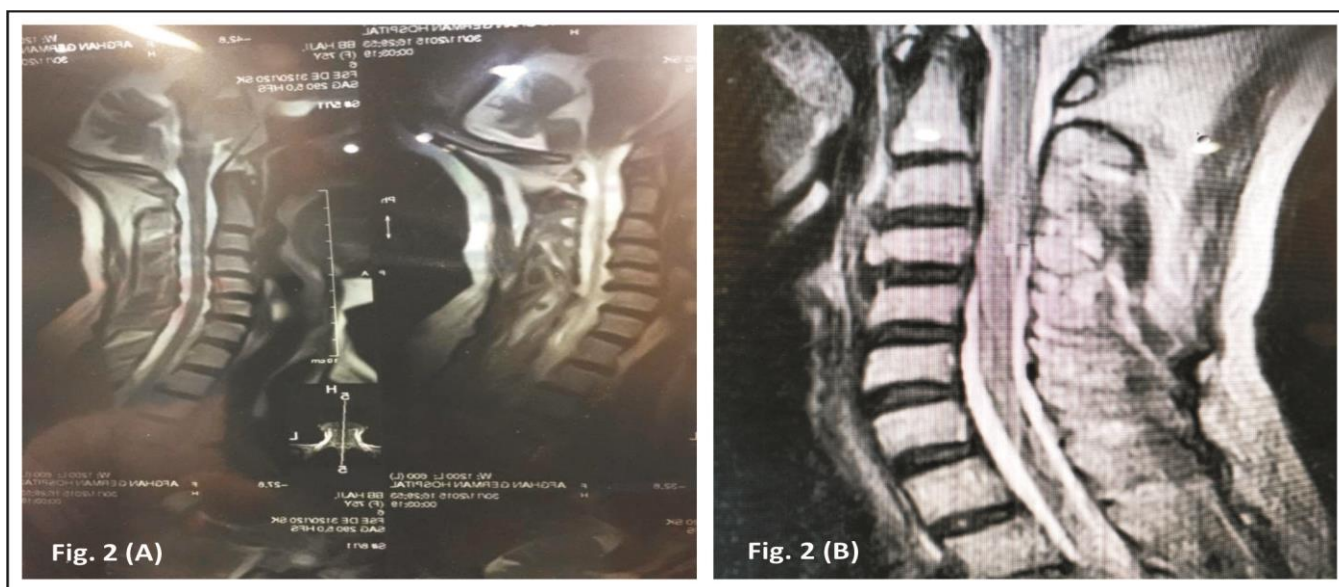


Figure 2: (Scans included with patients' consent).

Figure 2(A): Pre-Ozone therapy images of cervical disc herniation at C3-C4 and C6-C6

Figure 2(B): Post ozone therapy complete obliteration of herniated disc at C3-C4 and C5-C6 level

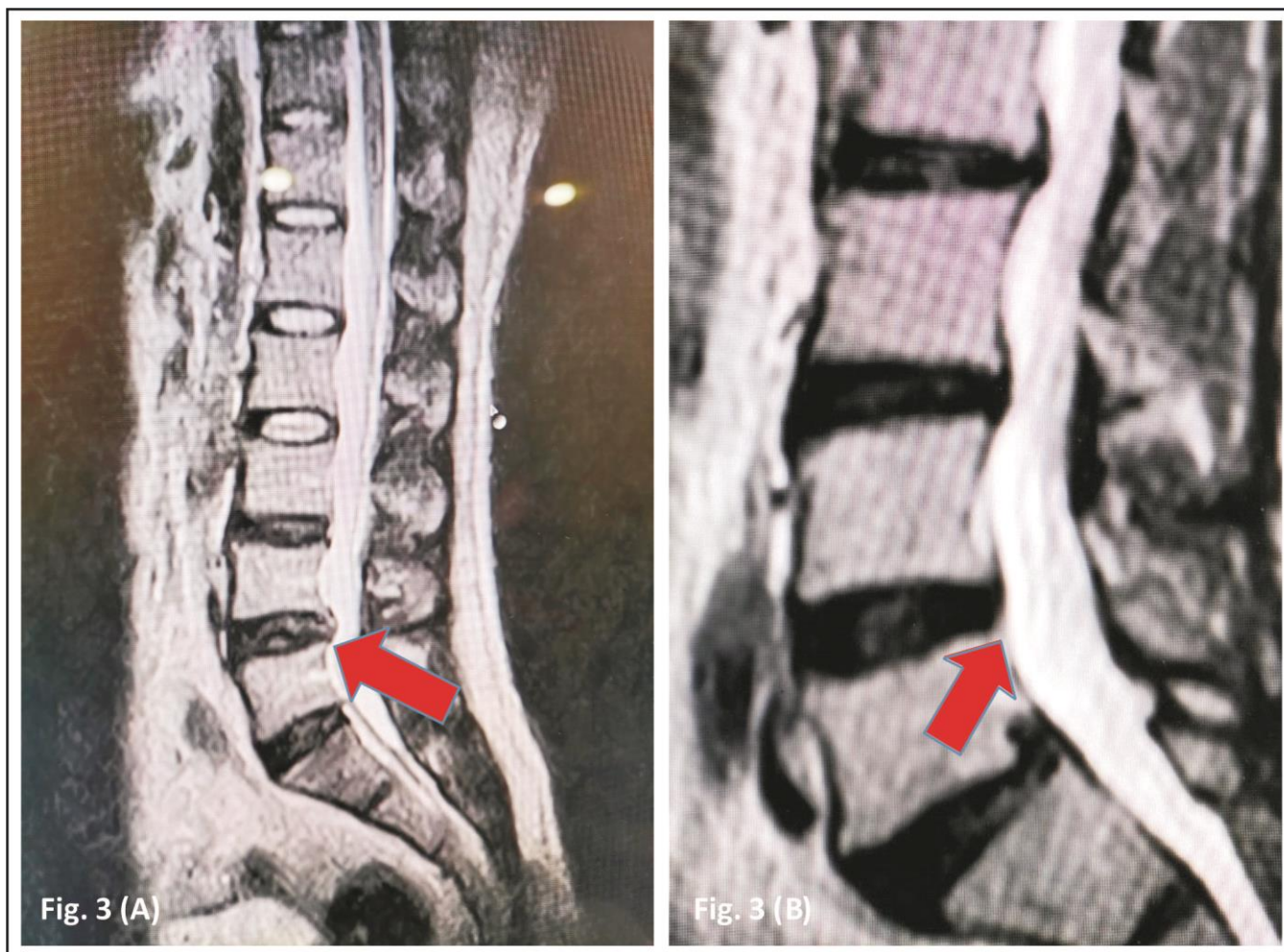


Figure 3: (Scans included with patients’ consent).

Fig: 3(A): Pre procedure images of herniated Lumbar disc at L4 –L5.

Fig: 3(B): Post-procedure complete shrinkage of herniated Lumbar disc at L4-L5.

Table 2: Frequency of ozone therapy procedure.

Number of Sessions	Number of Patients	Percentage
Single session	170	55%
Repeated once	70	22.5%
Repeated Twice	40	13%

DISCUSSION

A variety of surgical methods are utilized to manage herniated spinal disc herniation which includes maximally invasive like open surgery both macroscopic as well as endoscopic to minimally invasive like laser decompression,

radiofrequency ablation, and ozone chemonucleolysis. Minimally invasive is relatively less expensive and has satisfactory outcomes along with time and tissue-friendly procedures, nowadays minimally invasive methods are preferred over open surgery.^{11,12.}

In our study, we used ozone chemonucleolysis for both symptomatic herniated lumbar disc and as well as herniated cervical disc. Ozone chemonucleolysis caused a profound reduction of pain due to its anti-inflammatory, anti-oxidative, immune modulation properties it results in disc shrinkage and immediate pain relief even in failed back spinal surgery.^{13,14}

In our study all procedures were performed by a single neurosurgeon with help of operating C arm fluoroscopy, being sound knowledge and experience in dealing with disc herniation patients, a neurosurgeon can have a better idea about the patient selection for minimally as well as maximally invasive procedures. That point was proved by DALL'OLIO et al. an intervention neurologist who preferred to take an opinion from a neurosurgeon before intervening for ozone therapy in a herniated disc with a motor deficit.¹⁰

A variety of factors affect the outcomes of intradiscal ozone therapy, including the age of the patient, disc consistency, chronicity of disc, and degree of disc prolapse. A relatively better prognosis was observed in elderly patients with disc degeneration.¹⁵

In our study, the VAS score was remarkably reduced immediately after ozone therapy in about 55% of patients, and VAS progression of about 5 scales closely correlates with the study conducted by Kilic Mustafa. et al, that experienced a 50% reduction in VAS score and progression of about 4 VAS scale.¹⁶

In our study after a month, the overall prognosis of the patient was assessed by the Macnab performance scale and we found excellent performance in 54%, Good in 29%, Fair in 12.6%, and poor in 3.2% which was assessed by routinely performed task by individual patients' activity. Almost Similar outcome was reported by Andreula. CF et al. excellent in 50.3%, good in 20%, and poor in 25% of patients.¹⁷ Reason for almost double poor performance than us could be patient selection because they had included patients with the motor deficit as well and they performed single shot of therapy while in our study we repeated twice therapy as well depended on the patient's response and performance.

In our study we didn't experience any minor or major complications during or after the

procedure also zero complications were reported by Gallucci M.et al.¹²

LIMITATIONS

This study was limited to relatively small sample size and limited period for follow-up of up to 6 months, we only tried intradiscal space and a single therapeutic modality with ozone solution. All procedures were done by a single neurosurgeon

RECOMMENDATION

Other therapeutic modalities in a combination of ozone and steroids should be tried. Both intradiscal and peri-ganglionic insertion of ozone solution alone or in combination with corticosteroids should be given at a large scale keeping in mind the safety of the patient and efficacy of the procedure at firsthand.

Pre-operative diagnostic modalities like diffusion-weighted MRI especially for the degenerative disc may help to assess prognosis and intraoperative use of a Computed tomographic scan may be helpful to give more accurate localization of needle and ozone infiltration.

Multimodality approach by experts and mutual agreement of neuroradiologists and neurosurgeons can enhance the quality of life and prognosis.

CONCLUSION

Minimally invasive ozone chemodiscolysis can be considered as a bridging therapy between nonsurgical and surgical methods for the herniated cervical and lumbar disc, which is a relatively safe, inexpensive, minimally invasive method that effectively reduces the intensity of pain related to herniated spinal disc with neck ache, backache or radiculopathy within a shorter period and improves the quality of life. Even can

be repeated multiple times to achieve the desired effect.

REFERENCES

1. Apuzzo D, Giotti C, Pasqualetti C, et al. An observational retrospective/horizontal study to compare oxygen-ozone therapy and/or global postural re-education in complicated chronic low back pain. *Funct Neurol.* 2014; 29: 31–39.
2. Niu XK, Bhetuwal A and Yang HF. Diffusion-weighted imaging for pretreatment evaluation and prediction of treatment effect in patients undergoing CT-guided injection for lumbar disc herniation. *Korean J Radiol* 2015; 16: 874–880.
3. De Oliveira Magalhaes F, Dotta L, Sasse A, et al. Ozone therapy as a treatment for low back pain secondary to herniated disc: A systematic review and meta-analysis of randomized controlled trials. *Pain Physician*, 2012; 15: E115–E129.
4. Crockett MT, Moynagh M, Long N, et al. Ozone-augmented percutaneous discectomy: A novel treatment option for refractory discogenic sciatica. *Clin Radiol.* 2014; 69: 1280–1286.
5. Murphy K, Muto M, Steppan J, et al. Treatment of contained herniated lumbar discs with ozone and corticosteroids: A pilot clinical study. *J. Can Assoc Radiol.* 2015; 66: 337–384.
6. Splendiani A, Perri M, Conchiglia A, et al. MR assessment of lumbar disk herniation treated with oxygen-ozone discolysis: The role of DWI and related ADC versus intervertebral disk volumetric analysis for detecting treatment response. *Neuroradiol J.* 2013; 26: 347–356.
7. Negro. Alberto, Paolucci. Aldo, Russo. Camilla. Predictive factors of volumetric reduction in lumbar disc herniation treated by o₂-o₃ chemiodiscolysis J. *Acta Biomed.* 2020; (91) 8: 89-87.
8. Shah MK, Stewart GW. Sacral stress fractures: an unusual cause of low back pain in an athlete. *Spine (Phila Pa 1976)* 2002; 27: E104-8.
9. Vanni D, Galzio R, Kazakova A, et al. Intraforaminal ozone therapy and particular side effects: Preliminary results and early warning. *Acta Neurochir.* Epub Ahead of Print 21 August 2015.
10. Dall'Olio M, Princiotta C, Cirillo L, et al. Oxygen-ozone therapy for a herniated lumbar disc in patients with subacute partial motor weakness due to nerve root compression. *Interv Neuroradiol.* 2014; 20: 547–554.
11. Magalhaes FN, Dotta L, Sasse A, Teixeira MJ, Fonoff ET. Ozone therapy as a treatment for low back pain secondary to herniated disc: A systematic review and meta-analysis of randomized controlled trials. *J of Pain Physician*, 2012; 15: E115-E129.
12. Gallucci M, Limbucci N, Zugaro L, Barile A, Stavroulis E, Ricci A, Galzio R, Masciocchi C. Sciatica. Treatment with intradiscal and intraforaminal injections of steroid and oxygen-ozone versus steroid only. *J of Radiology*, 2007; 242: 907-913.
13. Vaillant JD, Fraga A, Díaz MT, Mallok A, Viebahn-Hänsler R, Fahmy Z, et al. Ozone oxidative postconditioning ameliorates joint damage and decreases pro-inflammatory cytokine levels and oxidative stress in PG/PS-induced arthritis in rats. *Eur J Pharmacol.* 2013; 714: 318-324.
14. Chang JD, Lu HS, Chang YF, Wang D. Ameliorative effect on ozone on cytokine production in mice injected with human rheumatoid arthritis synovial fibroblast cells. *Rheumatol Int.* 2005; 26: 141-151.
15. Ahn SH, Ahn MW, Byun WM. Effect of the transligamentous extension of lumbar disc herniations on their regression and the clinical outcome of sciatica. *Spine (Phila Pa 1976)* 2000; 25: 475-80.
16. Kilic Mustafa. Ozdemir Buraq et al. Lumbar Intradiscal Ozone Chemonucleolysis applied together with the Epidural Steroid Treatment. *Med Bull Sisli Etfal Hosp.* 2021; 55 (2): 203–209.
17. Andreula CF, Simonetti L, De Santis F, Agati R, Ricci R, Leonardi M. Minimally invasive oxygen-ozone therapy for lumbar disk herniation. *AJNR Am J Neuroradiol.* 2003; 24: 99.

Additional Information:

Disclosures: Authors report on conflict of interest.

Ethical Review Board Approval: The study was confirmed to the ethical review board requirements.

Human Subject: Consent was obtained by all patients/participants in this study.

Conflict of Interest:

In compliance with the ICMJE uniform disclosures form, all authors declare the following:

Financial Relationships: all authors have declared that they have no financial relationship at present or within the previous three years with any organizations that might have an interest in the submitted work.

Other Relationships: all authors have declared that there are no other relationships or activities that could appear to have influenced the submitted work.

Funding or sponsorship: Nil.

AUTHORS CONTRIBUTIONS

Ser #	Authors Full Name	Intellectual Contribution to Paper in Term of:
1.	Fahmida Arab Mallah	Study design and methodology.
2.	Syed Aamir Shah	Paper writing, referencing, data calculations and
3.	Imran Mirbahar	Data collection and calculations.
4.	Muzammil Dilbar	Analysis of data and interpretation of results.
5.	Abdul Razaque Mari	Literature review and manuscript writing.
6.	Ubaidullah khan	Analysis of data and quality insurer.