

Original Article

## Frequency and Progression of Gliomas in Pregnancy in Population Presenting at Lahore General Hospital, Pakistan

Omair Afzal<sup>1</sup>, Zahra Safdar<sup>2</sup>, Javeria Khan<sup>1</sup>, Fouzia Rahat<sup>3</sup>, Khalid Mahmood<sup>1</sup>

<sup>1</sup>Punjab Institute of Neurosciences (PINS), Lahore General Hospital, <sup>2</sup>Central Park Medical College, Kasur Road, <sup>3</sup>Obstetrics & Gynae, Unit 1, Lahore General Hospital, Lahore – Pakistan

### ABSTRACT

**Introduction:** Gliomas are the most common intracranial tumors diagnosed during pregnancy. They present a challenge as to how to treat them and proceed with the pregnancy. The risk of recurrence in a previously treated patient or progression of low grade to high-grade glioma during pregnancy merits a debate regarding the patient's decision to conceive or to proceed with the pregnancy.

**Objective:** To study the frequency and progression of gliomas in pregnant patients in our population.

**Materials and Methods:** A retrospective study of 30 pregnant patients between 18 to 40 years of age with confirmed gliomas from July 2015 to July 2020 was conducted at the Department of Neurosurgery, Punjab Institute of Neurosciences, Lahore. Time of diagnosis, grade of glioma, the outcome of pregnancy, and mode of treatment were studied in these patients.

**Results:** Out of 30 patients, 29 were freshly diagnosed during pregnancy. All patients underwent cesarean section. If the patient presented before 30 weeks of pregnancy, irrespective of the outcome of the baby, the caesarian section was done. If a patient presented after 7 months, in case of low-grade glioma, the patient was in-house transferred and operated for tumor after delivery. A total of 17 patients had low-grade glioma and 12 patients had high-grade glioma. One patient had a recurrent disease during pregnancy, with the progression of tumor from low grade to high grade.

**Conclusion:** There is an association between pregnancy and the incidence of gliomas. They can be both high or low grades. The mode of delivery is preferably the caesarian section because the stress of labor causes an increase in the frequency of seizures. There is the possibility of recurrence as well as progression to higher grade during pregnancy.

**Keywords:** Glioma; intracranial tumors; Pregnancy; glioblastoma; astrocytoma.

**Corresponding Author:** Omair Afzal  
Punjab Institute of Neurosciences (PINS)  
Lahore General Hospital, Lahore – Pakistan  
\*Corresponding Author: dr.omairafzal@hotmail.com

Date of Revision: 26-12-2021  
Date of Acceptance: 27-12-2021  
Date of Online Publishing: 31-12-2021  
Date of Print: 31-12-2021

Date of Submission: 01-11-2021

DOI: 10.36552/pjns.v25i4.627

## INTRODUCTION

Gliomas are the most common intracranial tumors diagnosed during pregnancy. They present a challenge as to how to treat them and proceed with pregnancy.<sup>1</sup> Progression of low-grade tumors to high grade can lead to increased morbidity and mortality.<sup>2</sup> There are no standard recommendations for the management of gliomas during pregnancy.<sup>3</sup> A study showed that there was evidence of clinical deterioration and tumor progression on MRI during pregnancy but there was no effect on long-term survival in low-grade gliomas. There was also no evidence of any superior mode of delivery in these patients.<sup>4</sup>

During pregnancy, it is difficult to decide the tumor and the unborn life of a mother. Many studies showed that pregnancy itself does not influence the creation of gliomas.<sup>1,2</sup> Obstetric causes reduce the mortality rate of the mother. The morbidity, as well as mortality of a mother, has greatly linked with non-obstetric causes which mainly include diseases related to the central nervous system.<sup>3</sup> In low-grade gliomas, dedifferentiation and progression have been seen in patients.<sup>4,5</sup> There has been observed behavior alteration in gliomas size, growth, volume, and symptoms.

The risk of recurrence in a previously treated patient or progression of low-grade to high-grade glioma during pregnancy merits a debate regarding the patient's decision to conceive or to proceed with the pregnancy. There is also an issue of radiotherapy during pregnancy without affecting fetal development. Most importantly, no study was conducted regarding the maternal and fetal health in a pregnant patient, either freshly diagnosed or with recurrent disease, at our institution. The study focused to find frequency and progression of gliomas in pregnant patients, presenting in our unit.

## MATERIAL AND METHODS

### Study Design

Retrospective study.

### Settings

Department of Neurosurgery, Punjab Institute of Neurosciences, Lahore.

### Sampling Method

30 patients with histopathologically confirmed glioma and ultrasonographical confirmed pregnancy.

A retrospective study of 30 pregnant patients having age between 18 to 40 years with confirmed gliomas from July 2015 to July 2020 was conducted at the Department of Neurosurgery, Punjab Institute of Neurosciences, Lahore. Time of diagnosis, grade of glioma, the outcome of pregnancy, and mode of treatment were studied in these patients.

## RESULTS

29 patients were diagnosed with glioma during pregnancy, for the first time. The symptoms varied in range depending upon the site of the tumor. They included headache, weakness of one side of the body, weakness of one limb, dysphasia, seizures, an altered state of consciousness. 16 patients underwent elective caesarian section to prevent the stress of labor and 4 patients underwent cesarean section due to pregnancy-related complications like eclampsia and breech position. 17 patients with low-grade glioma underwent craniotomy and excision of glioma after delivery while the rest of them were operated during pregnancy. 17 of them were diagnosed as diffuse astrocytoma grade II and 12 were diagnosed as glioblastoma grade 4. They were referred for radiotherapy. One patient was diagnosed with diffuse astrocytoma before marriage, was operated and had a complete

course of radiotherapy done. She had the recurrent disease during pregnancy, was operated on after delivery and the biopsy came back as glioblastoma grade 4. She also was referred for radiotherapy.

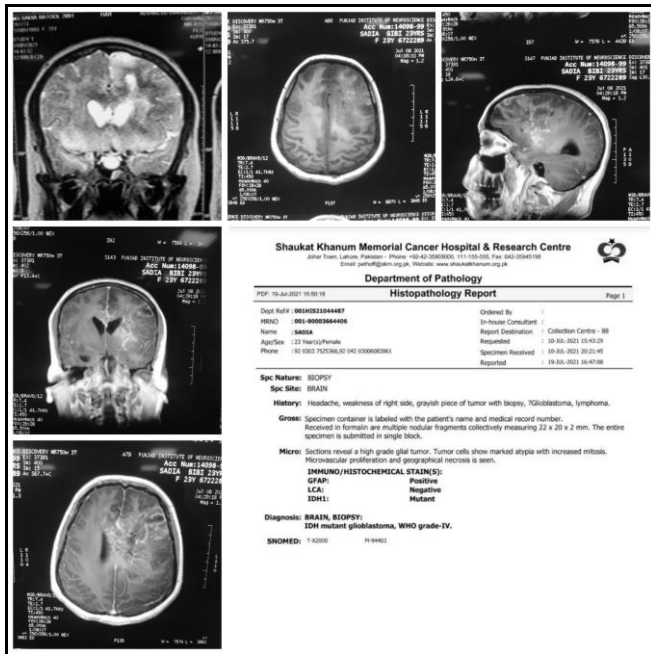


Fig. 1a: Glioblastoma WHO grade IV IDH 1 Mutant.

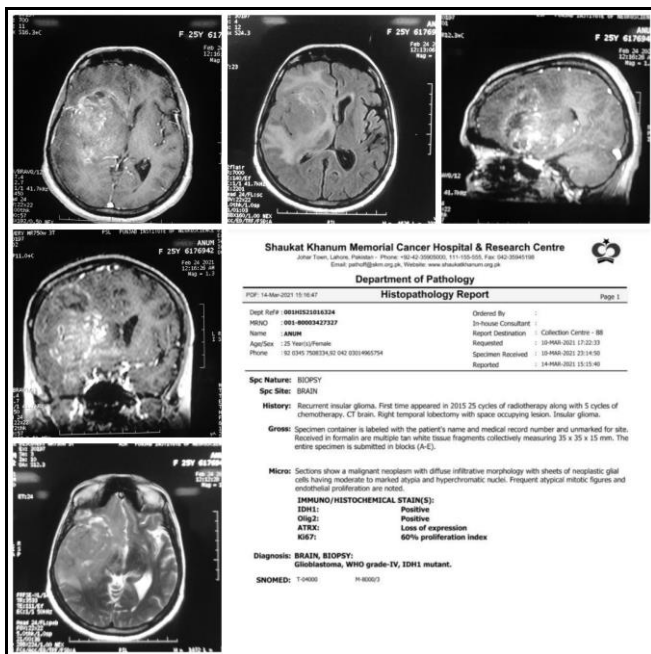


Fig. 1b: IDH Mutant Glioblastoma WHO Grade IV.

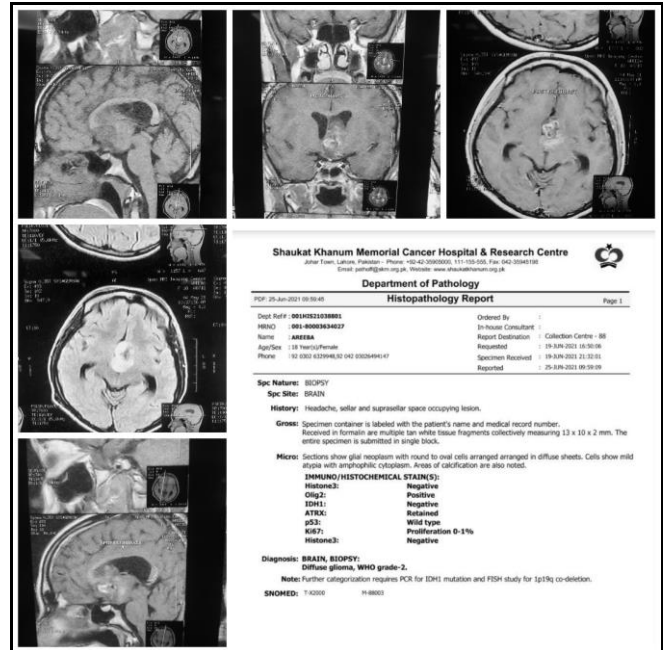


Fig. 1c: Diffuse Glioma WHO Grade II.

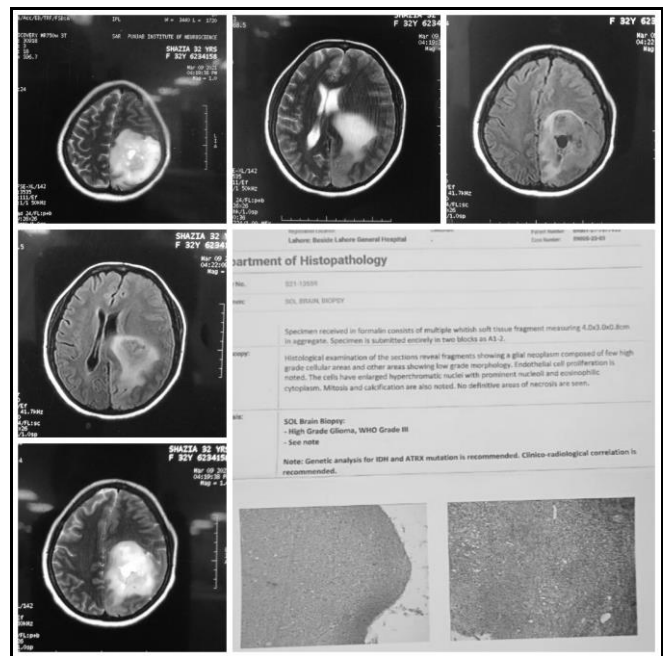
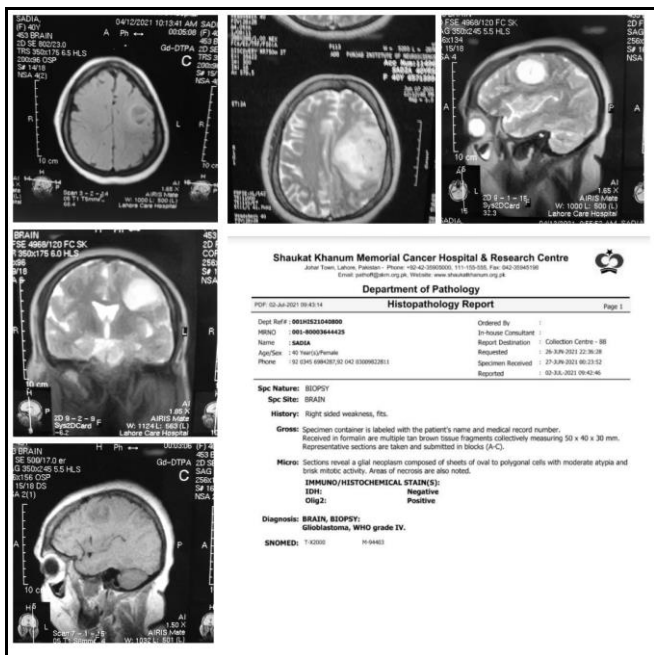


Fig. 1d: High-Grade Glioma WHO grade III.



**Figure 1e:** Effect of Glioma on Pregnancy Imaging (Report Detail in Supplementary).

Outcome of Pregnancy	
Good Outcomes	24 (80%)
Respiratory Issues	4 (13)
Baby Expired	2 (6%)
Patients Outcome after Craniotomy	
Patient Expired	1 (3%)
Re-operate Due to CSF Leakage	2 (6%)
Re-operate Due to Hematoma Evacuation	1 (3%)
Uneventful Course	26 (86%)
Medical Follow-ups	Referred to An Oncologist for Radiotherapy and Chemotherapy

## DISCUSSION

In this study, we present 30 cases of pregnant patients with Glioma. Pregnancy can change the behavior of brain gliomas with increased growth rate, increased frequency of seizures, and anaplastic transformation.<sup>6</sup> The possibility that a previously undiagnosed patient was diagnosed during pregnancy is very low because of a pattern of presentation of symptoms for the first time and diagnosis of glioma during 1<sup>st</sup> pregnancy, suggesting that there is an association between pregnancy and incidence of tumor.<sup>7</sup> In pregnancy, a previously diagnosed case could clinically get worse or result in the progression of the tumor from low to high grade.<sup>8</sup>

## Clinical Presentation

The clinical presentation of glioma during pregnancy is comparable to the reported values.<sup>9</sup> During pregnancy, the glioma is diagnosed in the 2<sup>nd</sup> or 3<sup>rd</sup> trimester and if the patient has the previous history, she will face clinical deterioration during pregnancy. The clinical presentation as indicated in Table 1 shows that patients experience many neurological symptoms which may precipitate obstetrical emergencies.<sup>10</sup>

## Grade II Glioma (GIIG)

In this current study, 15 patients have grade IV glioma, 07 have grade III, 5 have grade II and 03

Variable	No. of Pregnancies
<b>During Pregnancy</b>	
Median Age at Glioma Diagnosis, Yrs	28 (18 – 40)
<b>WHO glioma grade</b>	
<b>IV (Glioblastoma)</b>	15 (50%)
III (Anaplastic)	7 (23%)
II (Astrocytoma)	5 (16%)
Pilocytic Astrocytoma	3 (10%)
<b>Clinical Presentation</b>	
Headache	24 (80%)
Weakness of One Side of the Body	04 (13%)
Weakness of One Limb	01 (3%)
Dysphasia	04 (13%)
Seizures and Altered State of Consciousness	16 (53%)
<b>Treatment</b>	
Craniotomy	30 (100%)
Excision of Glioma	30 (100%)
Radiotherapy	26 (86%)
<b>Delivery Mode</b>	
The Cesarean Section after 30 Weeks	17 (56%)
The Cesarean Section Before 30 Weeks	13 (43%)

have pilocytic astrocytoma. Regardless of the WHO glioma grading, all the patients delivered via cesarean section 17 before 30 weeks and 13 after 30 weeks depending on the medical condition. Premature delivery via section was preferable as compared to vaginal delivery to reduce maternal stress as it was reported in the literature that there is an increase in grade II glioma (GIIg) during pregnancy. Out of all cases, 40% indicated that there increased the seizure of Glioma, and 75% cases reported with VDE increased during pregnancy.<sup>9,11</sup>

### Treatments

The treatments involved in all 30 patients were craniotomy to lower the intracranial pressure by removing the blood clot followed by excision of glioma.<sup>12</sup> After the surgery, 26 patients require radiotherapy to reduce the chances of regrowth.<sup>13</sup> Radiotherapy is used in both ways pre-partum and post-partum to reduce the risk of bad prognosis for the patient, by early treatment of tumor. There is major ambiguity about radiotherapy in pregnancy whether it affects the mother or the fetus. The major factor of radiation

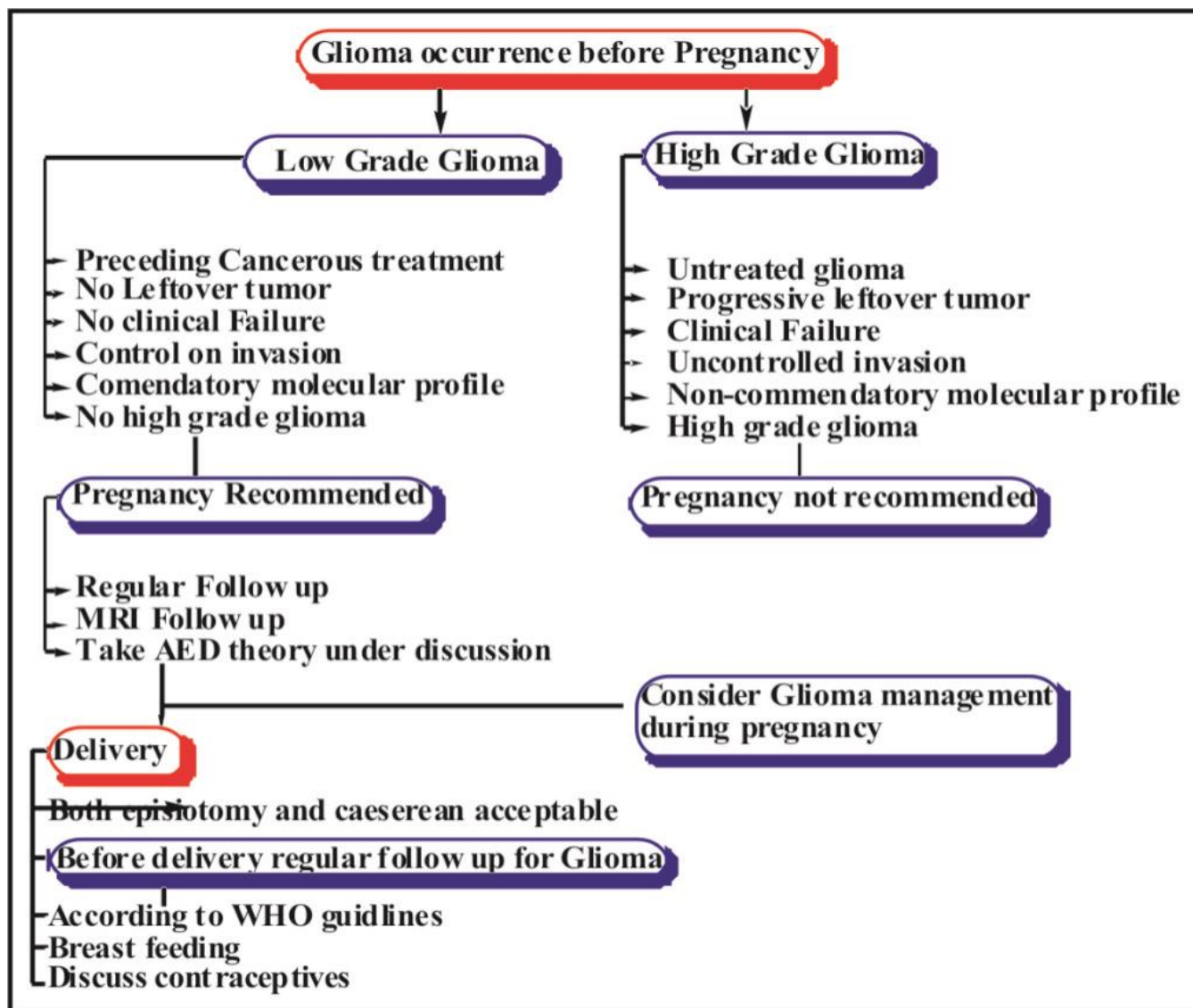


Figure 1: Scheme for Management of glioma before Pregnancy.

would cause radiation cancer to the fetus. It would cause CNS retardation to the patient. There are greater effects of radiation on the fetus during pregnancy rather than the mother.<sup>3,14</sup>

In patients who have a strong family history of diagnosed patients with a desire to conceive, the merits and demerits of surgery and radiotherapy should be thoroughly assessed to prevent a difficult pregnancy with poor outcomes at expense of maternal health.<sup>15</sup>

The already retrospective study was shown that gliomas before pregnancy were reported as not deteriorated clinically, increased VDE, progression in the image is about 87%, deterioration clinically occurred in 38% (Figure 1), After delivery only seizure involved about 57.2%, 42% needed oncological treatment after delivery. They've diagnosed tumors after the second and third trimester with a percentage of 29 and 54 respectively.<sup>9</sup>

The outcomes of pregnancy with glioma are uncertain, as in this study 24 patients have good outcomes with healthy babies, 04 experiences postoperative respiratory conditions and in 02 cases babies expired. It all depends on the maternal condition and stage of glioma<sup>16</sup>.

The patients should know the consequences of the pregnancy with glioma as in this study outcome after craniotomy (Table 1) in 26 patients was uneventful, 02 have to re-operate due to CSF leakage, 01 Re-operate due to hematoma evacuation and 01 patient expired.

All the patients were referred to an oncologist for radiotherapy and chemotherapy for further treatment.

## CONCLUSION

Glioma patients include a large number of young pregnant females who are pregnant before or after their diagnosis of glioma. Alterations in the behavior of glioma have been observed during pregnancy which has increased in the growth, volume, and quenching of seizure of glioma. The

study of 30 patients indicates that the only mode of delivery suitable for such conditions is cesarean section and delivery is preferable at the earliest. The craniotomy is preferable before excision of glioma and the patient requires completer follow up with an oncologist. Pregnancies with glioma are risky not only for the patients but also for the fetus. Medication and radiation could result in harmful effects.

## Funding

No funding but authors like to acknowledge PINS for providing for data access.

## Study Limitations

The sample size was small and cannot be applied on a largerscale although it gives us an overview of the glioma behavior during pregnancies a larger group is required to further evaluate and confirm the results of our study.

## Ethical Consideration

There were no ethical issues as all procedures performed in this study were following the ethical standards of the institutional and/or national research committee.

## REFERENCES

1. Cicutini FM, Hurley SF, Forbes A, Donnan GA, Salzberg M, Giles GG, McNeil JJ. Association of adult glioma with medical conditions, family and reproductive history. *International Journal of Cancer*, 1997; 71 (2): 203-07.
2. MichaudDS, Gallo V, Schlehofer B, Tjønneland A, Olsen A, Overvad K, Dahm CC, Kaaks R, Lukanova A, Boeing H, et. al. Reproductive factors and exogenous hormone use in relation to risk of glioma and meningioma in a large European cohort study.*Cancer Epidemiol Biomarkers Prev*, 2010; 19 (10): 2562-69.
3. Wu J, Ma YH, Wang TL. Glioma in the third trimester of pregnancy: Two cases and a review of

- the literature. *Oncology Letters*, 2013; 5 (3): 943-46.
4. Lynch JC, Gouvêa F, Emmerich JC, Kokinovrachos G, Pereira C, Welling L, Kislakov S. Management strategy for brain tumour diagnosed during pregnancy. *British Journal of Neurosurgery*, 2011; 25 (2): 225-30.
  5. Daras M, Cone C, Peters KB. Tumor progression and transformation of low-grade glial tumors associated with pregnancy. *Journal of Neurooncology*, 2014; 116 (1): 113-17.
  6. Stone JB, Kelvin JF, DeAngelis LM. Fertility preservation in primary brain tumor patients. *Neurooncol Practice*, 2017; 4 (1): 40-45.
  7. Bianco A, Fornaro R, Cossandi C, Forgnone S, Crobeddu E, Car P, Panzarasa G. Acute Intratumoral Hemorrhage of a Brain Glioma during Pregnancy: Case Report and Considerations on the Management Strategy. *Neurosurgery: Cases and Reviews*, 2019; 2: 021.
  8. Yust-Katz S, de Groot JF, Liu D, Wu J, Yuan Y, Anderson MD, Conrad CA, Milbourne A, Gilbert MR, Armstrong TS. Pregnancy and glial brain tumors. *Neuro-oncology*, 2014; 16 (9): 1289-94.
  9. Peeters S, Pagès M, Gauchotte G, Miquel C, Cartalat-Carel S, Guillamo JS, Capelle L, Delattre JY, Beauchesne P, Debouverie M, Fontaine D, Jouanneau E, Stecken J, Menei P, De Witte O, Colin P, Frappaz D, Lesimple T, Bauchet L, Lopes M, Bozec L, Moyal E, Deroulers C, Varlet P, Zanella M, Chretien F, Oppenheim C, Duffau H, Taillandier L, Pallud J. Interactions between glioma and pregnancy: insight from a 52-case multicenter series. *Journal of Neurosurgery*, 2018; 128 (1): 3-13.
  10. van Westrhenen A, Senders JT, Martin E, DiRisio AC, Broekman MLD. Clinical challenges of glioma and pregnancy: a systematic review. *Journal of Neurooncology*, 2018; 139 (1): 1-11.
  11. Molina-Botello D, Rodríguez-Sánchez JR, Cuevas-García J, Cárdenas-Almaraz BV, Morales-Acevedo A, Mejía-Pérez SI, Ochoa-Martínez E. Pregnancy and brain tumors; a systematic review of the literature. *Journal of Clinical Neuroscience*, 2021; 86: 211-16.
  12. Al Mashani AM, Ali A, Chatterjee N, Suri N, Das S. Awake Craniotomy During Pregnancy. *Journal of Neurosurgical Anesthesiology*, 2018; 30 (4): 372-73.
  13. Singh P, Mantilla E, Sewell J, Hatanpaa KJ, Pan E. Occurrence of Glioma in Pregnant Patients: An Institutional Case Series and Review of the Literature. *Anticancer Research*, 2020; 40 (6): 3453-57.
  14. Qin C, Long W, Zhang C, Xie Y, Wu C, Li Y, Xiao Q, Ji N, Liu Q. Multidisciplinary Therapy Managed Recurrent Glioblastoma in a BRAF-V600E Mutant Pregnant Female: A Case Report and Review of the Literature. *Frontiers in Oncology*, 2020; 10: 522816.
  15. Al-Rasheedy IM, Al-Hameed FM. Advanced case of glioblastoma multiforme and pregnancy. An ethical dilemma. *Neurosciences (Riyadh)*, 2015; 20 (4): 388-91.
  16. Pallud J, Mandonnet E, Deroulers C, Fontaine D, Badoual M, Capelle L, Guillet-May F, Page P, Peruzzi P, Jouanneau E, Frenay M, Cartalat-Carel S, Duffau H, Taillandier L. Pregnancy Increases the Growth Rates of World Health Organization Grade II Gliomas. *Annals of Neurology*, 2010; 67: 398-404.

### Additional Information

**Disclosures:** Authors report no conflict of interest.

**Human Subjects:** Consent was obtained by all patients/participants in this study.

**Conflicts of Interest:**

In compliance with the ICMJE uniform disclosure form, all authors declare the following:

**Financial Relationships:** All authors have declared that they have no financial relationships at present or within the previous three years with any organizations that might have an interest in the submitted work.

**Other Relationships:** All authors have declared that there are no other relationships or activities that could appear to have influenced the submitted work.

### AUTHORS CONTRIBUTIONS

Sr.#	Author's Full Name	Intellectual Contribution to Paper in Terms of:
1.	Omaid Afzal, Khalid Mahmood	1. Study design and methodology.
2.	Javeria Khan, Fouzia Rahat	2. Paper writing and data calculations.
3.	Zahra Safdar	3. Data collection and calculations.
4.	Fouzia Rahat	4. Analysis of data and interpretation of results.
5.	Javeria Khan	5. Literature review and referencing.
6.	Omaid Afzal, Khalid Mahmood	6. Analysis of data and quality insurer.