

Himmelfarb Health Sciences Library, The George Washington University

Health Sciences Research Commons

Neurology Faculty Publications

Neurology

11-7-2021

Multifocal myoclonus as a presentation of levetiracetam toxicity.

Mei Bou Nasif

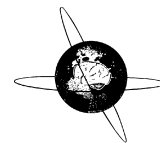
Shweta Varade

Mohamad Z. Koubeissi

Follow this and additional works at: https://hsrc.himmelfarb.gwu.edu/smhs_neuro_facpubs



Part of the [Neurology Commons](#)



Case report

Multifocal myoclonus as a presentation of levetiracetam toxicity

Mei Bou Nasif, Shweta Varade, Mohamad Z. Koubeissi*

Department of Neurology, George-Washington University, Washington, DC, USA



ARTICLE INFO

Article history:

Received 24 August 2021

Received in revised form 27 September 2021

Accepted 9 October 2021

Available online 7 November 2021

Keywords:

Levetiracetam

Multifocal myoclonus

Pharmacology

ABSTRACT

Background: Levetiracetam (LEV) is widely used for treatment of focal and myoclonic seizures, but reports of LEV toxicity are scarce. Here, we report a rare case of multifocal myoclonus due to LEV toxicity in a patient with chronic renal insufficiency.

Case presentation: A 52-year-old woman with history of chronic kidney disease was admitted to the ICU for sedation and intubation after a cardiac arrest. She developed nonconvulsive status epilepticus that resolved after administration of propofol while receiving LEV 1500 mg twice a day. After holding the propofol infusion, the patient started having multifocal myoclonic jerks, documented on video-EEG recordings with a supratherapeutic level of LEV. After discontinuation of LEV, the myoclonus resolved.

Conclusion: This is a unique manifestation of LEV toxicity, which has been scarce in the literature. It suggests an inverted U-shaped dose–response of the antimyoclonic effect of LEV.

© 2021 International Federation of Clinical Neurophysiology. Published by Elsevier B.V. This is an open access article under the CC BY-NC-ND license (<http://creativecommons.org/licenses/by-nc-nd/4.0/>).

1. Introduction

Levetiracetam (LEV) is a widely used antiseizure medication (ASM) that is approved for the treatment of focal and myoclonic seizures (Abou-Khalil, 2008). Its widespread use is related to its favorable properties including linear pharmacokinetics, lack of hepatic metabolism and protein binding, and lack of drug–drug interactions (Beran et al., 2005). Though studies reporting LEV toxicity are scarce, it is well-established that dose adjustment of LEV is especially necessary in cases of renal impairment due to the drug being predominantly excreted unchanged in the urine (Patsalos, 2004). We report a patient with renal insufficiency who developed multifocal myoclonus in the setting of elevated serum levels of LEV, which subsequently subsided as the drug levels normalized.

2. Case report

A 52-year-old woman with a past medical history of chronic kidney disease requiring hemodialysis, hypertension, and hypothyroidism was admitted to the George Washington University Hospital for cauterization following heavy vaginal bleeding secondary to a loop electrosurgical excision procedure that had been performed 17 days prior. She suffered an intra-operative cardiac arrest with subsequent return of spontaneous circulation after 6 min of Advanced Cardiac Life Support (ACLS) protocol. Thereafter, she

remained intubated and sedated on propofol and dexmedetomidine HCl in the intensive care unit (ICU). Post-operatively, the patient was noted to be moving all extremities spontaneously. The following day, she developed rhythmic twitching of her facial muscles for which she was treated intravenously with 6 mg of lorazepam and 1000 mg of LEV, as the semiology of her twitches was suggestive of an epileptic seizure, though the patient had not yet been connected to electroencephalogram.

Upon evaluation by the neurology team later in the same day, she was noted to have persistent uprolling of the eyes with occasional spontaneous blinks. The rest of her neurological exam revealed increased tone in all four extremities, withdrawal to noxious stimulus in the right lower extremity, and clonus in the left lower extremity. Blood tests were normal with the exception of elevated creatinine (5.7 mg/dL [reference value for adult women 0.59–1.04 mg/dL], clearance: 8.29 mL/min [reference value in women 88–128 mL/min]), elevated blood urea nitrogen (BUN: 42 mg/dL [reference value 5–20 mg/dL]), respiratory acidosis (pH: 7.31 [reference value 7.35–7.45], pCO₂ 45.2 mmHg [reference value 35–45 mmHg]), and anemia (Ht: 32.1% [reference in women 36–48%]). Appropriate work-up was initiated to determine the etiology of the multiple neurological deficits noted on examination. Computed Tomography (CT) and Magnetic Resonance Imaging (MRI) of the brain showed no evidence of neither acute intracranial pathology such as stroke, hemorrhage, or post-anoxic injury, nor chronic conditions. Continuous Electroencephalogram (EEG) monitoring was started to rule out status epilepticus. The first twenty-four hours of EEG recording showed evidence of bifrontal seizures and frontal bilateral lateralized periodic discharges (LPDs), more

* Corresponding author at: Department of Neurology, George Washington University, 2150 Pennsylvania Ave, NW, Washington, DC 20037, USA.

E-mail address: mkoubeissi@mfa.gwu.edu (M.Z. Koubeissi).

amplified in the left, without any apparent clinical correlate which coalesced into nonconvulsive status epilepticus that ultimately resolved over the course of the day after step-wise uptitration of propofol. At that stage, she was receiving LEV at a dose of 1500 mg BID, lacosamide at 200 mg BID and propofol at 60 mcg/kg/min. The patient’s neurological exam at this time was consistent with a comatose state without any clinical evidence of seizure activity, presumably secondary to propofol.

Her neurological examination improved upon weaning of Propofol, revealing spontaneous blinks, spontaneous movements of all four extremities, and symmetric withdrawal of all limbs to noxious stimuli although she remained in a vegetative state. Given that the patient remained seizure-free while on EEG for five days with no further concern for clinical seizures, EEG was discontinued at that time.

However, the patient’s neurologic status deteriorated in the following days with episodes of multifocal myoclonic jerks that were noted only upon holding the propofol infusion. Thus, the patient was reconnected to continuous EEG monitoring to rule out non-convulsive status epilepticus. Her myoclonic twitching was noted as asynchronously affecting in the left shoulder, forehead, abdomen, and extremities. The EEG showed evidence of generalized dysfunction, as seen previously, in addition to a new finding of muscle artifact, specifically in the right frontal and left occipital leads, suggestive of multifocal myoclonic activity, without an ictal correlate (Fig. 1).

Suspecting that the myoclonus was caused by LEV toxicity, LEV was first decreased to 500 mg BID with an additional 500 mg of LEV after each hemodialysis session. Valproic acid was added to the medication regimen with a 1500 mg loading dose, followed by 1000 mg BID. LEV levels were obtained for the first time due to concern for toxicity and resulted as supratherapeutic at 49.8 mg/L (therapeutic levels range between 20 and 40 mg/L).

Subsequently, LEV was stopped. After discontinuation of LEV, the myoclonus stopped concomitantly while the drug levels normalized; initially to 38.4 mg/L, then continued to decrease until they were undetectable over the course of four days. The patient remained on continuous EEG monitoring during this period without any recurrence of the myoclonus after discontinuation of LEV. The patient remained on dual therapy with lacosamide and

valproic acid for the remainder of her hospital course due to her history of NCSE in the context of anoxic insult.

3. Discussion

The favorable pharmacological properties, safety profile, and broad spectrum coverage across seizure types facilitate the use of LEV in a variety of clinical situations. It has multiple mechanisms of action which include binding to the synaptic vesicle protein SV2A to reduce the rate of exocytotic neurotransmitter release, AMPA receptor antagonism, and decreasing the calcium currents (Abou-Khalil, 2008). Adverse effects due to LEV are minimal, with fatigue, somnolence, headache, and dizziness being the most frequently reported (Beran et al., 2005). Other side effects include hepatotoxicity (Tan et al., 2008), cutaneous adverse reactions (Estébanez et al., 2020; Kim et al., 2020; Rashid et al., 2020), blood dyscrasias (Gallerani et al., 2009), and behavioral problems (Sirsi and Safdieh, 2007). The range that is commonly used as a therapeutic reference varies between 20 and 40 mg/L (Stepanova and Beran, 2014), rendering a dose superior to 40 mg/L toxic.

In this case report, we describe new-onset multifocal myoclonus induced by LEV toxicity in the context of renal insufficiency. Although a moderate dose was administered, the patient’s renal disease led to the accumulation of its metabolites ultimately leading to a toxicity, as evidenced by plasma drug level of 49.8 mg/L. Although multiple ASMs were included in the regimen, the improvement of the myoclonus after discontinuation of the LEV and simultaneous normalization of the plasma drug levels support LEV toxicity as the etiology of this unique clinical presentation.

LEV has been shown to be a very efficient anti-myoclonic agent. This case report suggests that an excess of this ASM could possibly lead to a paradoxical effect, with possible loss of the inhibitory effect that is expected at therapeutic doses. One could hypothesize the presence of a dose-dependent inverted U-shaped curve effect on myoclonus. This could perhaps be due to better binding activation of SV2A receptors at low or therapeutic drug concentrations and quiescence at higher concentrations. It could also be theorized that the drug’s mechanisms of action are more complex, with receptor activation being dominant at lower concentrations of the drug, and inhibition taking precedence at higher concentrations.

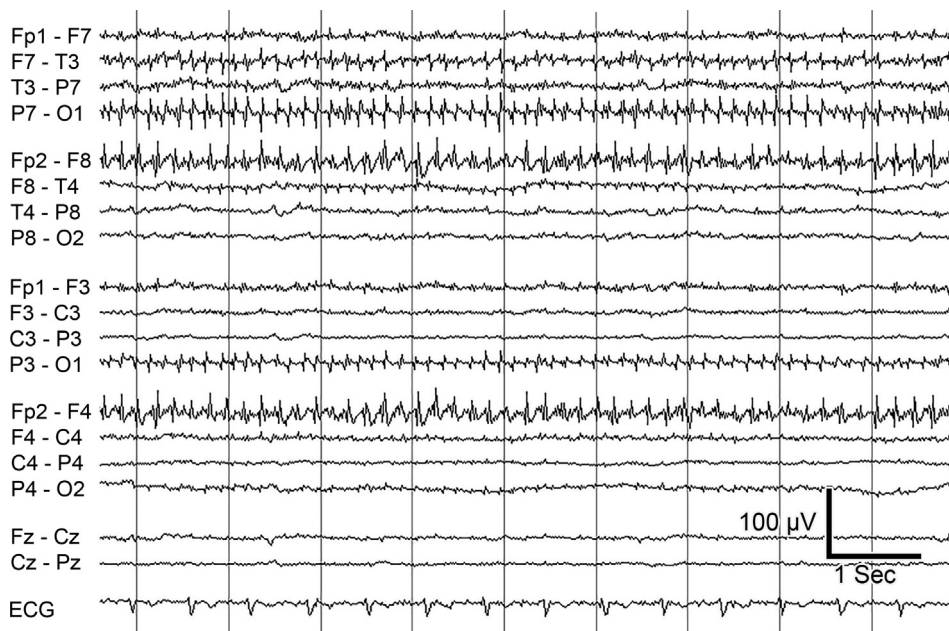


Fig. 1.

Table 1
Summary of reported cases of LEV toxicity.

Reference	Sex	Age	Dose	Levels	Concomitant medical conditions	Symptoms
Barrueto et al., 2002	F	38 yo	30 000 mg	400 µg/ml	Bipolar disorder	Sedation and respiratory depression
Larkin et al., 2013	M	49 yo	22 500 mg	N/A	COPD, HTN, hepatitis C, seizures of unknown etiology	No symptoms
Awaad, 2007	F	2 yo	10 × recommended dose	Not obtained	Cerebral palsy and seizures Epilepsy	No symptoms
	F	5 yo	4x recommended dose			
Glauer et al., 2002	N/A	N/A	71.4 mg/kg/day	46.1 µg/ml	N/A	No symptoms
Chayasisobhon et al., 2010	M	41 yo	63000 mg	220 µg/ml	Epilepsy	Transient mild blurred vision, mild ataxia, mild leucopenia and mild thrombocytopenia
Ozturk et al., 2017	F	3 yo	115 mg/kg/day	Could not be measured	Epilepsy New onset seizures	No symptoms No symptoms
	F	3 months old	300 mg/kg/day			
Vellinga et al., 2015	F	50 yo	20 000–27000 mg	26 µg/ml	Obesity, aneurysmal subarachnoid hemorrhage, epilepsy	Comatose and required intubation and ventilatory support for 24 h
Sarfaz and Syeda, 2017	F	21 yo	40 000 mg 30 000 mg	Could not be measured	Epilepsy	No symptoms
Page et al., 2016	F	43 yo	60 000–80 000 mg	462.5 mcg/ml	Epilepsy, asthma	Bradycardia, hypotension
Vulliemoz et al., 2009	F	80 yo	2000 mg/day	184 µmol/l	Chronic renal insufficiency, hypertension, diabetes, vascular parkinsonism	Metabolic encephalopathy with triphasic waves, myoclonic jerks, confusion
Stepanova and Beran, 2014	N/A	N/A	Between 250 and 6000 mg/day	86 mg/L	Epilepsy	Increased seizure rate
Current paper	F	52	1000 mg	58.8 mg/L	Chronic kidney disease, hypertension, hypothyroidism	Multifocal myoclonus

F: Female, M: Male, DTR: deep tendon reflexes, HTN: Hypertension, COPD: Chronic obstructive pulmonary disease.

In the literature, there is only one other case report describing similar findings, which describes an 80-year-old patient with chronic renal insufficiency who developed metabolic encephalopathy and myoclonic jerks following LEV administration. Myoclonus was generalized also involving the diaphragm, and evolved into a generalized tonic-clonic seizure ([Vulliemoz et al., 2009](#)). Similar to our case, the patient had chronic renal insufficiency, which reinforces the necessity of appropriate dose-adjustment in patients with sub-optimal renal function. Another case report found an increase in seizure rate following LEV toxicity ([Stepanova and Beran, 2014](#)).

There are only a handful of reports describing LEV toxicity, with the findings detailed in [Table 1](#). In the majority of cases, only mild transient symptoms were described.

4. Conclusion

Based on available case reports, the majority of LEV toxicities result in mild reversible symptoms. We describe a case in which a patient with renal insufficiency developed a unique clinical manifestation of symptomatic multifocal myoclonus secondary to supra-therapeutic levels of LEV. Similar cases are rare in the literature, however the clinical course in this report suggests a potential loss of LEV's expected inhibitory effects at high concentrations, elucidating the hypothesis of an inverted U-shaped dose-response of the anti-myoclonic effect of this ASM. This case is of clinical relevance not only because it adds to the limited body of literature pertaining to LEV toxicity but also because it illustrates the neces-

sity of close monitoring of drug levels and dose-adjustments of a very commonly used ASM, especially in patients with medical comorbidities, specifically renal disease. Detailed review of additional cases and the risks of potential toxicities are integral in further understanding LEV's properties and mechanisms of action.

Ethical statement

We confirm that we have read the Journal's position on issues involved in ethical publication and affirm that this report is consistent with those guidelines.

Funding

This research did not receive any specific grant from funding agencies in the public, commercial, or not-for-profit sectors.

Declaration of Competing Interest

The authors declare that they have no known competing financial interests or personal relationships that could have appeared to influence the work reported in this paper.

References

- [Abou-Khalil, B., 2008. Levetiracetam in the treatment of epilepsy. *Neuropsychiatr. Dis. Treat.* 4 \(3\), 507–523.](#)
- [Awaad, Y., 2007. Accidental overdosage of levetiracetam in two children caused no side effects. *Epilepsy Behav.* 11 \(2\), 247.](#)

- Barrueto, F., Williams, K., Howland, M.A., Hoffman, R.S., Nelson, L.S., 2002. A case of levetiracetam (Keppra) poisoning with clinical and toxicokinetic data. *J. Toxicol. Clin. Toxicol.* 40 (7), 881–884.
- Beran, R.G., Berkovic, S.F., Black, A.B., Danta, G., Hiersemenzel, R., Schapel, G.J., Vajda, F.J.E., 2005. Efficacy and safety of levetiracetam 1000–3000 mg/day in patients with refractory partial-onset seizures: a multicenter, open-label single-arm study. *Epilepsy Res.* 63 (1), 1–9.
- Chayasisobhon, S., Chayasisobhon, W.V., Tsay, C.C., 2010. Acute levetiracetam overdose presented with mild adverse events. *Acta Neurol. Taiwan* 19 (4), 292–295.
- Estébanez, A., Sáez-Martín, L.C., Muñoz, J.I., Silva, E., Monrabal, A., Monteagudo, C., Ramón, M.D., 2020. Levetiracetam-induced pediatric toxic epidermal necrolysis successfully treated with etanercept. *Pediatr. Dermatol.* 37 (4), 701–705.
- Gallerani, M., Mari, E., Boari, B., Carletti, R., Marra, A., Cavallo, M., 2009. Pancytopenia associated with levetiracetam treatment. *Clin. Drug Invest.* 29 (11), 747–751.
- Glauser, T.A., Pellock, J.M., Bebin, E.M., Fountain, N.B., Ritter, F.J., Jensen, C.M., et al., 2002. Efficacy and safety of levetiracetam in children with partial seizures: an open-label trial. *Epilepsia* 43 (5), 518–524.
- Kim, H.K., Kim, D.Y., Bae, E.K., Kim, D.W., 2020. Adverse skin reactions with antiepileptic drugs using Korea adverse event reporting system database, 2008–2017. *J. Korean Med. Sci.* 35, (4). <https://doi.org/10.3346/jkms.2020.35.e17> e17.
- Larkin, T.M., Cohen-Oram, A.N., Catalano, G., Catalano, M.C., 2013. Overdose with levetiracetam: a case report and review of the literature. *J. Clin. Pharm. Ther.* 38 (1), 68–70.
- Ozturk, Z., Havalı, C., Serdaroglu, A., Hirfanoglu, T., Akbas, Y., Tekin Olgun, L., et al., 2017. Two cases of levetiracetam overdose without any serious side effects. *Gazi Med. J.* 28, 137–138. <https://doi.org/10.12996/gmj.2017.39>.
- Page, C.B., Mostafa, A., Saiao, A., Grice, J.E., Roberts, M.S., Isbister, G.K., et al., 2016. Cardiovascular toxicity with levetiracetam overdose. *Clin. Toxicol. (Phila.)* 54 (2), 152–154.
- Patsalos, P.N., 2004. Clinical pharmacokinetics of levetiracetam. *Clin. Pharmacokinet.* 43 (11), 707–724.
- Rashid, M., Rajan, A.K., Chhabra, M., Kashyap, A., 2020. Levetiracetam and cutaneous adverse reactions: A systematic review of descriptive studies. *Seizure* 75, 101–109. <https://doi.org/10.1016/j.seizure.2020.01.002>.
- Sarfaraz, M., Syeda, R.H., 2017. Levetiracetam and topiramate poisoning: Two overdoses on those drugs with no lasting effects. *Drug Discov. Ther.* 11, 115–117.
- Sirsi, D., Safdieh, J.E., 2007. The safety of levetiracetam. *Expert. Opin. Drug Saf.* 6 (3), 241–250.
- Stepanova, D., Beran, R.G., 2014. measurement of levetiracetam drug levels to assist with seizure control and monitoring of drug interactions with other anti-epileptic medications (AEMs). *Seizure* 23 (5), 371–376. <https://doi.org/10.1016/j.seizure.2014.02.003>.
- Tan, T.C.H., de Boer, B.W., Mitchell, A., Delriviere, L., Adams, L.A., Jeffrey, G.P., MacQuillan, G., 2008. Levetiracetam as a possible cause of fulminant liver failure. *Neurology* 71 (9), 685–686.
- Vellinga, S.E., Van Der Jagt, M., Hunfeld, N.G.M., 2015. Coma after levetiracetam overdose. *Neth. J. Crit. Care* 20, 29–32.
- Vulliamoz, S., Iwanowski, P., Landis, T., Jallon, P., 2009. Levetiracetam accumulation in renal failure causing myoclonic encephalopathy with triphasic waves. *Seizure* 18 (5), 376–378.