



# Association of long-term outcome of long cervical fusion with sagittal balance: the significance of T1 slope minus cervical lordosis

Witold Janusz<sup>1</sup> , Tomasz Szmuda<sup>2</sup> , Piotr Morasiewicz<sup>3</sup> , Samuel D. Pettersson<sup>2</sup> ,  
Grzegorz Miękiński<sup>3</sup> 

<sup>1</sup>Department of Orthopaedics and Traumatology, Medical University, Lublin, Poland

<sup>2</sup>Department of Neurosurgery, Faculty of Medicine, Medical University of Gdansk, Poland

<sup>3</sup>Faculty of Medicine, Opole University, Opole, Poland

## ABSTRACT

**Introduction.** Retrospective study to assess correlation between the sagittal alignment of the cervical spine and the long-term outcomes of long cervical fusion due to cervical spondylotic myelopathy (CSM), with the emphasis on T1 slope minus cervical lordosis (T1S-CL).

**Summary of background data.** Growing evidence shows that the sagittal profile can play a major role in the outcomes of treatment, but the role of its correction is yet to be established.

**Material and methods.** We conducted a retrospective analysis of 54 patients treated for CSM from 2006 to 2012. The neck pain-related disability was measured using NDI, the myelopathy was measured with the mJOA and Nurick scales. Six years after the surgery, standardised X-ray measurements were obtained, including C2–C7 lordosis (CL), C2–C7 sagittal vertical alignment (SVAC2–C7), T1 slope (T1S), and T1S minus CL (T1S-CL). The patients were divided based on the T1S-CL into two groups, using the threshold value of 16.5 degrees.

**Results.** A statistically significant improvement was noted in the mean NDI, mJOA, and median Nurick scale during the initial two years in both groups. The better aligned group had a better outcome measured with NDI at all follow-ups. The mJOA was significantly better in the better aligned group, but only preoperatively; at all follow-ups, the difference was not significant. T1S-CL had the strongest correlation with the NDI at the final follow-up.

**Conclusions.** T1S-CL is an effective prognostic factor of the long term outcome after long cervical fusion in CSM treatment.

**Key words:** cervical spine, cervical lordosis, spinal deformity, kyphosis, cervical spondylotic myelopathy

(*Neurol Neurochir Pol* 2022; 56 (3): 261–266)

## Introduction

There is substantial evidence that the sagittal spinal balance is correlated with the health-related quality of life (HRQOL) [1] in the lumbosacral segment. The key parameters for describing the global spinal alignment include lumbar lordosis,

sacral slope, pelvic incidence, pelvic tilt, and thoracic kyphosis [2]. Of these, pelvic incidence-lumbar lordosis (PI-LL: PI minus LL) mismatch has been identified as a major predictor of surgical outcomes [3]. Similar parameters have also been established in the cervical spine. Recently, another parameter, T1 slope minus cervical lordosis (T1S-CL) as equivalent to the

**Address for correspondence:** Grzegorz Miękiński, Faculty of Medicine, Opole University, Opole, Poland; e-mail: gmiekisiak@gmail.com

Received: 09.02.2022; Accepted: 04.04.2022; Early publication date: 13.05.2022

This article is available in open access under Creative Common Attribution-Non-Commercial-No Derivatives 4.0 International (CC BY-NC-ND 4.0) license, allowing to download articles and share them with others as long as they credit the authors and the publisher, but without permission to change them in any way or use them commercially.

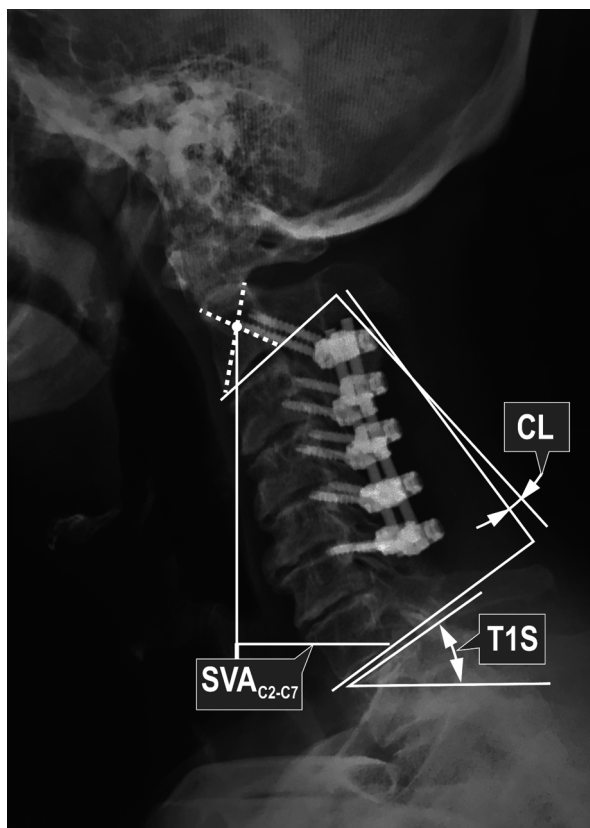
lumbar PI-LL, has been under intensive focus [4]. Moreover, T1S-CL has been shown to correlate negatively with the severity of myelopathy [5] and preoperative HRQOL [6]. A recent article by Staub et al. [7] has identified  $16.5 \pm 2$  degrees as a normative value for this parameter.

Cervical spondylotic myelopathy (CSM) is the most common progressive spinal cord disorder in patients > 55 years [8]. Current evidence shows that spinal malalignment exerts a vital role in the pathomechanism of CSM [9] and affects the outcome of surgical treatment [10]. In addition, surgical treatment often requires long fusion with decompression, and hence proper sagittal balance is a critical issue.

Some studies have demonstrated a correlation between HRQOL and sagittal alignment; however, the long-term (> 5 years) data has not yet been reported. The present study aimed to evaluate the sagittal cervical alignment with emphasis on T1S-CL in the long-term (6 years) outcomes of long fusion surgery for CSM.

### Material and methods

The Ethics Committee of the Medical University of Lublin approval was obtained prior to accessing patient medical records; the need for the patient's informed consent was waived. A retrospective analysis of clinical outcomes and sagittal radiographic parameters was performed for patients who had undergone multilevel ( $\geq 4$  levels) posterior cervical surgery from 2006–2012, either single-stage posterior only or combined 360° fusion. They were all operated by a single surgeon [WJ]. In all cases, the indication for surgery was CSM, and the subjects underwent a follow-up evaluation of clinical outcomes at two, four, and six years. Each patient was subjected to standing radiographic measurements at a minimum of six years after surgery, and the data was obtained using a standard lateral cervical X-ray protocol [11]. The patients were instructed to look straight ahead in a neutral position with knees flexed and hands hanging freely by the side of their body. This protocol was strictly followed in each case. The following parameters were assessed (Fig. 1): (1) C2–C7 lordosis (CL), (2) C2–C7 sagittal vertical alignment ( $SVA_{C2-C7}$ ), (3) T1 slope (T1S), and (4) T1S minus CL (T1S-CL). CL was measured according to the sagittal Cobb angles between the lines drawn parallel to the inferior endplates of the C2 and C7 vertebral bodies.  $SVA_{C2-C7}$  was defined as the distance between the C2 plumb line and the posterior-superior endplate of C7. T1S is an angle between the line parallel to the superior endplate of T1 and the horizontal line. T1S-CL is a mathematical difference between CL and T1S. The degree of cervical deformity was evaluated using the ISSG classification [12]. In this scale, four factors are taken into account:  $SVA_{C2-C7}$ , Chin-Brow Vertical Angle (CBVA), T1S-CL, and the severity of myelopathy measured with a modified JOA (mJOA) scale. In order to assess the functional disability due to CSM, the Nurick [13] classification, as well as the modified



**Figure 1.** Visual representation of technique used to measure cervical sagittal parameters. CL was measured according to sagittal Cobb angles between lines drawn parallel to inferior endplates of C2 and C7 vertebral bodies.  $SVA_{C2-C7}$  was defined as distance between C2 plumb line and posterior-superior endplate of C7. T1S is an angle between line parallel to superior endplate of T1 and horizontal line

JOA (mJOA) scale, was used [14]. The myelopathy recovery rate (RecR) was calculated using the formula:  $(\text{postoperative JOA} - \text{preoperative JOA}) / (18 - \text{preoperative JOA}) \times 100$  [15]. The health-related quality of life was evaluated using the neck disability index (NDI) [16].

The entire population studied was then divided into two groups, based on the last available T1S-CL: the  $\leq 16.5$  group and the 16.5+ group. The cut-off point was 16.5 degrees as per the recommendations of the International Spine Study Group (ISSG) [7], which proposed this as a normative value for predicting an ideal cervical lordosis. A poor outcome was defined as an NDI score of 30 or more, this approach being adapted from other authors [17, 18]. Univariate logistic regression analysis of factors associated with a poor outcome was performed to evaluate the role of confounders such as age, sex, number of levels fused and, most importantly, the type of surgery (posterior only vs. 360 degrees fusion). In the same analysis, the odds ratio for a bad outcome was evaluated for the value of T1S-CL of 16.5 or more.

**Table 1.** Comparison of groups

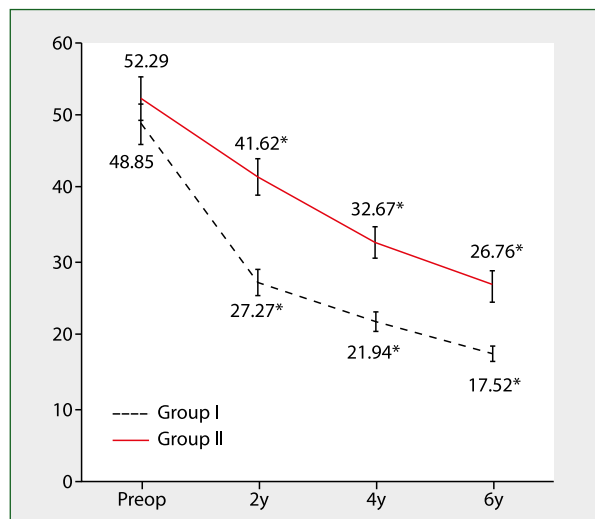
	≤ 16.5 group	16.5 + group	P-value
<b>Demographics</b>			
N	33	21	
Age	50.33 (11.39)	55.14 (9.11)	0.1092
M:F	1.75	2	0.8218
% of 360 degree fusion	52.38	33.33	0.1688
<b>Radiographic parameters at 6 years</b>			
T1S-CL	<b>7.21 (6.82)</b>	<b>22.88 (5.48)</b>	<b>&lt; 0.0001</b>
SVA	28.82 (11.89)	40 (21.72)	0.0343
CL	<b>19.03 (10.05)</b>	<b>2.41 (11.36)</b>	<b>&lt; 0.0001</b>
T1S	28.82 (9.38)	25.35 (10)	0.6207
CDC [median]	<b>1</b>	<b>4</b>	<b>&lt; 0.0001</b>
<b>Outcomes at 6 years</b>			
Nurick	1	1	0.498
Odom	2	2	0.0624
RecR	52.44 (16.31)	51.81 (13.53)	0.6707

Finally, the Pearson correlation coefficient *r* was calculated to evaluate the correlation between the final NDI score and T1S-CL, CL and SVA.

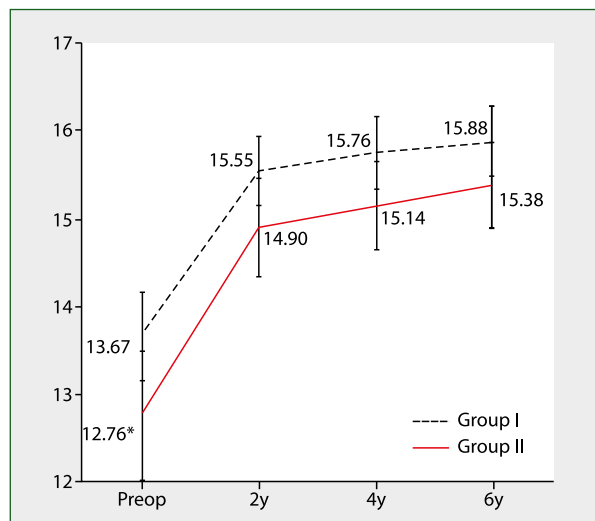
All calculations were performed using MedCalc statistical software v.12 (MedCalc Software, Ostend, Belgium).

### Results

Fifty-four surgically treated CSM patients matched the criteria and were included in this study. There were 17 females and 37 males, with a mean age of 52.2 (range 28–67) years. Thirty-two patients underwent posterolateral fusion with facet screws, and in 22 cases the multilevel ACDF with posterolateral fusion and facet screws was performed. The baseline characteristics are set out in Table 1. There were 33 patients in the ≤ 16.5 group and 21 in the 16.5+ group. The initial NDI was 48.85 (SD 15.08) in the ≤ 16.5 group and 52.29 (SD 13.48) in the 16.5+ group. The difference was not statistically significant. These values decreased gradually at each follow-up, significantly more in the former group (*p* < 0.05 at each timepoint) (Fig. 2). The initial mJOA score was 12.76 (SD 3.34) in the ≤ 16.5 group and 13.67 (SD 2.86) in the 16.5+ group. The difference was statistically significant at *p* < 0.05. These values increased at a similar rate in both groups (Fig. 3). The differences at each follow-up were not statistically significant. The median Nurick score was 2 before admission in both groups at the time of surgery. This decreased to 1 at two years postoperatively and was maintained subsequently (Tab. 1). The mean recovery rate of mJOA (RecR) at the final follow-up was 52.44 (SD 16.31) in the ≤ 16.5 group and 51.81 (SD 13.53) in the 16.5+ group, as calculated using the formula described above. The differences were not statistically significant. Similarly, Odom scores were not different at the final



**Figure 2.** Change in NDI over time in each group. Error bars represent SE, \* - *p* < 0.05



**Figure 3.** Change in mJOA over time in each group. Error bars represent SE, \* - *p* < 0.05

follow-up (Tab. 1). At six years postoperatively, the values for the follow-up sagittal parameters were as follows: mean CL was 12.17 (range 17–37), mean SVA<sub>C2-C7</sub> was 32.69 (range 4–110), mean T1s was 25.72 (range 5–55), and T1S-CL was 13.54 (range 12–36). There were substantial differences in radiographic parameters at the time of the last follow-up. The mean T1S-CL was 7.21 (SD 6.82) in the ≤ 16.5 group and 22.88 (SD 5.48) in the 16.5+ group. This and other measurements are shown in Table 1. Univariate logistic regression analysis revealed that T1S-CL was a strong predictor of bad outcome, with an odds ratio of 10.07 (CI 95% 1.60–63.36, *p* < 0.05). Other variables were not associated with a bad outcome (Tab. 2). There was a moderate positive correlation of T1S-CL and the final NDI

**Table 2.** Logistic regression analysis of factors associated with poor outcomes

Variable	Odds ratio	Low	High	P-value
Age	0.9752	0.8945	1.0632	0.5687
Female sex	0.9304	0.1639	5.2828	0.9351
<b>T1S-CL &gt; 16.5</b>	<b>10.0697</b>	<b>1.6005</b>	<b>63.3559</b>	<b>0.0138</b>
360 degree fusion	1.8295	0.3253	10.2881	0.493
Number of levels fused	2.5397	0.7469	8.636	0.1355

**Table 3.** Correlation of selected measurements with final NDI

Variable	Pearson correlation coefficient	Low	High	P-value
<b>T1-CL</b>	<b>0.47</b>	<b>0.23</b>	<b>0.66</b>	<b>0.0003</b>
<b>CL</b>	<b>-0.38</b>	<b>-0.59</b>	<b>-0.12</b>	<b>0.0049</b>
SVA	0.25	-0.02	0.49	0.0669

( $r = 0.47$ ,  $p < 0.001$ ), weak but statistically significant for the CL ( $r = -0.38$ ,  $p < 0.01$ ), and not significant for SVA (Tab. 3).

## Discussion

A significant malalignment after fusion surgery in the lumbosacral area results in poor outcomes and an increased rate of severe complications [19, 20]. Patients with deformity have demonstrated that a positive sagittal balance is proportional to a progressive sagittal imbalance [21]. Thus far, only a few studies have investigated this topic in regard to the cervical spine. Similar to the lumbar spine, several radiographic parameters can be measured in the cervical segment. In order to assess the global alignment, an appropriate protocol, especially the positioning of subjects, is critical before obtaining X-ray imaging. In the present study, the protocol described by Park et al. [11] was followed, i.e. hands hanging freely by the side of the body, instead of placing over the clavicles. The study found that the clavicle position during the whole-spine radiograph causes a substantial decrease in the T1-slope and CL. The most widely used measurement in routine clinical practice is CL, which can be measured in several ways. Nevertheless, the Cobb C2-C7 is the leading method in clinical application [22], in which the lordosis is measured as the angle between the inferior endplates of C2 and C7; this method was utilised in the present study. The SVA is an indicator of sagittal translation and was measured as a distance between the vertical line dropped from the middle of C2 and the superior posterior aspect of C7. This approach has been frequently used previously, as it is clinically relevant and directly correlated with the clinical outcomes [23]. The T1S is defined as the angle between the upper endplate and the horizontal line, similarly to the sacral slope in the lumbar spine. The derivative of T1S is T1S-CL, which is used to determine the so-called 'ideal' cervical lordosis and discern the kyphotic deformity [7, 24].

The main objective of our study was to evaluate the role of sagittal profile of the cervical spine on the HRQOL after long fusion over the long term, with the emphasis on the T1S-CL parameter. Our results indicate that sagittal malalignment is indeed associated with poor outcomes.

The literature on this topic is somewhat scarce and ambiguous. Villavicencio et al. conducted a prospective, randomised, double-blind clinical study to evaluate the correlation between clinical outcomes and cervical sagittal alignment [25]. They found that the cervical Cobb angle alignment did not correlate significantly with the clinical outcomes. In addition, improved segmental sagittal alignment positively affected the clinical outcomes measured with NDI and SF-36. Another study by Sielatycki et al. [4] failed to show any association between C2-C7 lordosis and the postoperative HRQOL.

In the present study, the correlation between SVA<sub>C2-C7</sub> and 6-year NDI was weak and statistically insignificant. This finding is in contrast to Tang et al. [23], wherein a positive association was detected with the endpoint NDI. Moreover, the positive balance of  $\geq 40$  mm was associated with a bad outcome, similar to that described previously [26]. Another study demonstrated that most patients with SVA<sub>C2-C7</sub>  $> 40$  mm did not show an overall improvement in HRQOL. Furthermore, regression models predicted a threshold SVA<sub>C2-C7</sub> value of 50mm, beyond which the correlations were significant [27].

The primary focus of our work was T1S-CL, as it has recently been identified as a potentially helpful marker of cervical malalignment. The T1S-CL mismatch is associated with a marked degree of cervical malalignment and disability, as defined by C2-C7 SVA and NDI scores, respectively [26]. In a recent article, Staub et al. [7] from the International Spine Study Group, proposed a value of 16.5 degrees as a normative value according to the formula  $CL = T1S - 16.5^\circ \pm 2^\circ$ . This formula provides a threshold for cervical deformity, but it also implies a goal for surgical correction. Another study [4]

on cervical sagittal deformity in patients undergoing thoracolumbar osteotomy established threshold values for a compensated cervical spine: T1S-CL of 17° and SVA<sub>C2-C7</sub> of 4 cm; these threshold values were used to categorise the patients into compensated and uncompensated groups. In the present study, T1S-CL correlated well with the clinical outcome. Our most important finding was that the NDI at all follow-ups was significantly different in favour of the ≤ 16.5 group. Patients with a T1S-CL greater than 16.5 degrees were more than 10 times more likely (10.07, CI 95% 1.60–63.36,  $p < 0.05$ ) to experience unfavourable outcomes measured with the NDI, according to the logistic regression model. A recent article by Jeon et al. demonstrated a significant correlation between postoperative T1S-CL and changes in NDI [28]. Lan et al. [29] presented preoperative T1S-CL as a valuable predictor of poor postoperative HRQOL, more reliable than SVA<sub>C2-C7</sub> although these values are correlated [28]. All remaining potential confounders failed to demonstrate a significant effect on the outcomes (Tab. 2).

The present study failed to demonstrate any significant correlation between the radiographic parameters and the neurological outcomes of surgical treatment of CSM, despite clear benefits achieved at all follow-ups. Historically, CSM has been viewed as a result of multilevel spondylosis [22]; however, new evidence indicates spine deformity to be a major contributor towards chronic spinal cord injury. Kyphotic deformity leads to cord flattening, increased tension, and thus increased intramedullary pressure [30]. Experimental models of CSM have revealed that cervical kyphotic deformity is associated with demyelination, atrophy, and neuronal loss of the anterior horn, together with a decreased vascular supply of the anterior spinal cord [9, 31]. Contrary to our results, a correlation between the CSM severity and the preoperative [32] or postoperative [33] local kyphotic deformity was found in recent studies.

This study has its limitations. The preoperative sagittal parameters were not available, and thus the role of surgery in the final sagittal profile is impossible to assess. Instead, this study shows that the endpoint imbalance, expressed as T1S-CL greater than 16.5, is merely correlated with worse outcomes measured with the NDI. Another issue is that T1S is not a constant parameter, and it is likely to be affected by even miniscule changes in patient posture during the X-ray examination. To account for that, we followed a strict protocol in each case. Last but not least, our work did not assess the thoracic inlet, which is now being speculated as an equivalent to the pelvic incidence [24], which is a critical value in the lumbosacral sagittal profile.

## Conclusions

Our study showed that T1S-CL is an effective prognostic factor of the long-term outcome after long cervical fusion in CSM treatment. On the other hand, the long-term neurological outcome of surgical treatment of CSM is independent of this value.

**Conflicts of interest:** None.

**Funding:** None.

## References

1. Le Huec JC, Faundez A, Dominguez D, et al. Evidence showing the relationship between sagittal balance and clinical outcomes in surgical treatment of degenerative spinal diseases: a literature review. *Int Orthop*. 2015; 39(1): 87–95, doi: [10.1007/s00264-014-2516-6](https://doi.org/10.1007/s00264-014-2516-6), indexed in Pubmed: [25192690](https://pubmed.ncbi.nlm.nih.gov/25192690/).
2. Vialle R, Levassor N, Rillardon L, et al. Radiographic analysis of the sagittal alignment and balance of the spine in asymptomatic subjects. *J Bone Joint Surg Am*. 2005; 87(2): 260–267, doi: [10.2106/JBJS.D.02043](https://doi.org/10.2106/JBJS.D.02043), indexed in Pubmed: [15687145](https://pubmed.ncbi.nlm.nih.gov/15687145/).
3. Aoki Y, Nakajima A, Takahashi H, et al. Influence of pelvic incidence-lumbar lordosis mismatch on surgical outcomes of short-segment transforaminal lumbar interbody fusion. *BMC Musculoskelet Disord*. 2015; 16: 213, doi: [10.1186/s12891-015-0676-1](https://doi.org/10.1186/s12891-015-0676-1), indexed in Pubmed: [26289077](https://pubmed.ncbi.nlm.nih.gov/26289077/).
4. Protopsaltis T, Terran J, Soroceanu A, et al. INTERNATIONAL SPINE STUDY GROUP. T1 Slope Minus Cervical Lordosis (TS-CL), the Cervical Answer to PI-LL, Defines Cervical Sagittal Deformity in Patients Undergoing Thoracolumbar Osteotomy. *Int J Spine Surg*. 2018; 12(3): 362–370, doi: [10.14444/5042](https://doi.org/10.14444/5042), indexed in Pubmed: [30276093](https://pubmed.ncbi.nlm.nih.gov/30276093/).
5. Smith JS, Lafage V, Ryan D, et al. Association of myelopathy scores with cervical sagittal balance and normalized spinal cord volume. *Spine*. 2013; 38: S161–S170, doi: [10.1097/brs.0b013e3182a7eb9e](https://doi.org/10.1097/brs.0b013e3182a7eb9e).
6. Iyer S, Nemani VM, Nguyen J, et al. Impact of Cervical Sagittal Alignment Parameters on Neck Disability. *Spine (Phila Pa 1976)*. 2016; 41(5): 371–377, doi: [10.1097/BRS.0000000000001221](https://doi.org/10.1097/BRS.0000000000001221), indexed in Pubmed: [26571157](https://pubmed.ncbi.nlm.nih.gov/26571157/).
7. Staub BN, Lafage R, Kim HJo, et al. International Spine Study Group. Cervical mismatch: the normative value of T1 slope minus cervical lordosis and its ability to predict ideal cervical lordosis. *J Neurosurg Spine*. 2018; 30(1): 31–37, doi: [10.3171/2018.5.SPINE171232](https://doi.org/10.3171/2018.5.SPINE171232), indexed in Pubmed: [30485176](https://pubmed.ncbi.nlm.nih.gov/30485176/).
8. Klineberg E. Cervical spondylotic myelopathy: a review of the evidence. *Orthop Clin North Am*. 2010; 41(2): 193–202, doi: [10.1016/j.ocl.2009.12.010](https://doi.org/10.1016/j.ocl.2009.12.010), indexed in Pubmed: [20399358](https://pubmed.ncbi.nlm.nih.gov/20399358/).
9. Shimizu K, Nakamura M, Nishikawa Y, et al. Spinal kyphosis causes demyelination and neuronal loss in the spinal cord: a new model of kyphotic deformity using juvenile Japanese small game fowls. *Spine (Phila Pa 1976)*. 2005; 30(21): 2388–2392, doi: [10.1097/01.brs.0000184378.67465.5c](https://doi.org/10.1097/01.brs.0000184378.67465.5c), indexed in Pubmed: [16261114](https://pubmed.ncbi.nlm.nih.gov/16261114/).
10. Sakai K, Yoshii T, Hirai T, et al. Cervical sagittal imbalance is a predictor of kyphotic deformity after laminoplasty in cervical spondylotic myelopathy patients without preoperative kyphotic alignment. *Spine (Phila Pa 1976)*. 2016; 41(4): 299–305, doi: [10.1097/BRS.0000000000001206](https://doi.org/10.1097/BRS.0000000000001206), indexed in Pubmed: [26579963](https://pubmed.ncbi.nlm.nih.gov/26579963/).
11. Park SM, Song KS, Park SH, et al. Does whole-spine lateral radiograph with clavicle positioning reflect the correct cervical sagittal alignment? *Eur Spine J*. 2015; 24(1): 57–62, doi: [10.1007/s00586-014-3525-2](https://doi.org/10.1007/s00586-014-3525-2), indexed in Pubmed: [25163548](https://pubmed.ncbi.nlm.nih.gov/25163548/).
12. Ames CP, Smith JS, Eastlack R, et al. International Spine Study Group. Reliability assessment of a novel cervical spine deformity classification system. *J Neurosurg Spine*. 2015; 23(6): 673–683, doi: [10.3171/2014.12.SPINE14780](https://doi.org/10.3171/2014.12.SPINE14780), indexed in Pubmed: [26273762](https://pubmed.ncbi.nlm.nih.gov/26273762/).



13. Nurick S, Nurick S. The natural history and the results of surgical treatment of the spinal cord disorder associated with cervical spondylosis. *Brain*. 1972; 95(1): 101–108, doi: [10.1093/brain/95.1.101](https://doi.org/10.1093/brain/95.1.101), indexed in Pubmed: [5023079](https://pubmed.ncbi.nlm.nih.gov/5023079/).
14. Benzel EC, Lancon J, Kesterson L, et al. Cervical laminectomy and dentate ligament section for cervical spondylotic myelopathy. *J Spinal Disord*. 1991; 4(3): 286–295, doi: [10.1097/00002517-199109000-00005](https://doi.org/10.1097/00002517-199109000-00005), indexed in Pubmed: [1802159](https://pubmed.ncbi.nlm.nih.gov/1802159/).
15. Hirabayashi K, Miyakawa J, Satomi K, et al. Operative results and postoperative progression of ossification among patients with ossification of cervical posterior longitudinal ligament. *Spine (Phila Pa 1976)*. 1981; 6(4): 354–364, doi: [10.1097/00007632-198107000-00005](https://doi.org/10.1097/00007632-198107000-00005), indexed in Pubmed: [6792717](https://pubmed.ncbi.nlm.nih.gov/6792717/).
16. Misterska E, Jankowski R, Glowacki M. Cross-cultural adaptation of the neck disability index and copenhagen neck functional disability scale for patients with neck pain due to degenerative and discopathic disorders. Psychometric properties of the polish versions. *BMC Musculoskelet Disord*. 2011; 12: 84, doi: [10.1186/1471-2474-12-84](https://doi.org/10.1186/1471-2474-12-84), indexed in Pubmed: [21529360](https://pubmed.ncbi.nlm.nih.gov/21529360/).
17. Vernon H. The Neck Disability Index: state-of-the-art, 1991-2008. *J Manipulative Physiol Ther*. 2008; 31(7): 491–502, doi: [10.1016/j.jmpt.2008.08.006](https://doi.org/10.1016/j.jmpt.2008.08.006), indexed in Pubmed: [18803999](https://pubmed.ncbi.nlm.nih.gov/18803999/).
18. Williamson E, Williams MA, Gates S, et al. Risk factors for chronic disability in a cohort of patients with acute whiplash associated disorders seeking physiotherapy treatment for persisting symptoms. *Physiotherapy*. 2015; 101(1): 34–43, doi: [10.1016/j.physio.2014.04.004](https://doi.org/10.1016/j.physio.2014.04.004), indexed in Pubmed: [24996567](https://pubmed.ncbi.nlm.nih.gov/24996567/).
19. Roussouly P, Nnadi C. Sagittal plane deformity: an overview of interpretation and management. *Eur Spine J*. 2010; 19(11): 1824–1836, doi: [10.1007/s00586-010-1476-9](https://doi.org/10.1007/s00586-010-1476-9), indexed in Pubmed: [20567858](https://pubmed.ncbi.nlm.nih.gov/20567858/).
20. Lamartina C, Berjano P. Classification of sagittal imbalance based on spinal alignment and compensatory mechanisms. *Eur Spine J*. 2014; 23(6): 1177–1189, doi: [10.1007/s00586-014-3227-9](https://doi.org/10.1007/s00586-014-3227-9), indexed in Pubmed: [24682355](https://pubmed.ncbi.nlm.nih.gov/24682355/).
21. Glassman SD, Berven S, Bridwell K, et al. Correlation of radiographic parameters and clinical symptoms in adult scoliosis. *Spine (Phila Pa 1976)*. 2005; 30(6): 682–688, doi: [10.1097/01.brs.0000155425.04536.f7](https://doi.org/10.1097/01.brs.0000155425.04536.f7), indexed in Pubmed: [15770185](https://pubmed.ncbi.nlm.nih.gov/15770185/).
22. Ames CP, Blondel B, Scheer JK, et al. Cervical radiographical alignment: comprehensive assessment techniques and potential importance in cervical myelopathy. *Spine (Phila Pa 1976)*. 2013; 38(22 Suppl 1): S149–S160, doi: [10.1097/BRS.0b013e3182a7f449](https://doi.org/10.1097/BRS.0b013e3182a7f449), indexed in Pubmed: [24113358](https://pubmed.ncbi.nlm.nih.gov/24113358/).
23. Tang JA, Scheer JK, Smith JS, et al. ISSG. The impact of standing regional cervical sagittal alignment on outcomes in posterior cervical fusion surgery. *Neurosurgery*. 2012; 71(3): 662–9; discussion 669, doi: [10.1227/NEU.0b013e31826100c9](https://doi.org/10.1227/NEU.0b013e31826100c9), indexed in Pubmed: [22653395](https://pubmed.ncbi.nlm.nih.gov/22653395/).
24. Staub BN, Lafage R, Kim HJo, et al. International Spine Study Group. Cervical mismatch: the normative value of T1 slope minus cervical lordosis and its ability to predict ideal cervical lordosis. *J Neurosurg Spine*. 2018; 30(1): 31–37, doi: [10.3171/2018.5.SPINE171232](https://doi.org/10.3171/2018.5.SPINE171232), indexed in Pubmed: [30485176](https://pubmed.ncbi.nlm.nih.gov/30485176/).
25. Villavicencio AT, Babuska JM, Ashton A, et al. Prospective, randomized, double-blind clinical study evaluating the correlation of clinical outcomes and cervical sagittal alignment. *Neurosurgery*. 2011; 68(5): 1309–16; discussion 1316, doi: [10.1227/NEU.0b013e31820b51f3](https://doi.org/10.1227/NEU.0b013e31820b51f3), indexed in Pubmed: [21792113](https://pubmed.ncbi.nlm.nih.gov/21792113/).
26. Roguski M, Benzel EC, Curran JN, et al. Postoperative cervical sagittal imbalance negatively affects outcomes after surgery for cervical spondylotic myelopathy. *Spine (Phila Pa 1976)*. 2014; 39(25): 2070–2077, doi: [10.1097/BRS.0000000000000641](https://doi.org/10.1097/BRS.0000000000000641), indexed in Pubmed: [25419682](https://pubmed.ncbi.nlm.nih.gov/25419682/).
27. Hyun SJ, Kim KJ, Jahng TA, et al. Relationship Between T1 Slope and Cervical Alignment Following Multilevel Posterior Cervical Fusion Surgery: Impact of T1 Slope Minus Cervical Lordosis. *Spine (Phila Pa 1976)*. 2016; 41(7): E396–E402, doi: [10.1097/BRS.0000000000001264](https://doi.org/10.1097/BRS.0000000000001264), indexed in Pubmed: [26583469](https://pubmed.ncbi.nlm.nih.gov/26583469/).
28. Jeon SI, Hyun SJ, Han S, et al. Relationship Between Cervical Sagittal Alignment and Patient Outcomes After Anterior Cervical Fusion Surgery Involving 3 or More Levels. *World Neurosurg*. 2018; 113: e548–e554, doi: [10.1016/j.wneu.2018.02.088](https://doi.org/10.1016/j.wneu.2018.02.088), indexed in Pubmed: [29476994](https://pubmed.ncbi.nlm.nih.gov/29476994/).
29. Lan Z, Huang Y, Xu W. Relationship Between T1 Slope Minus C2-7 Lordosis and Cervical Alignment Parameters After Adjacent 2-Level Anterior Cervical Discectomy and Fusion of Lower Cervical Spine. *World Neurosurg*. 2019; 122: e1195–e1201, doi: [10.1016/j.wneu.2018.11.016](https://doi.org/10.1016/j.wneu.2018.11.016), indexed in Pubmed: [30447441](https://pubmed.ncbi.nlm.nih.gov/30447441/).
30. Chavanne A, Pettigrew DB, Holtz JR, et al. Spinal cord intramedullary pressure in cervical kyphotic deformity: a cadaveric study. *Spine (Phila Pa 1976)*. 2011; 36(20): 1619–1626, doi: [10.1097/BRS.0b013e3181fc17b0](https://doi.org/10.1097/BRS.0b013e3181fc17b0), indexed in Pubmed: [21289583](https://pubmed.ncbi.nlm.nih.gov/21289583/).
31. Shamji MF, Mohanty C, Massicotte EM, et al. The association of cervical spine alignment with neurologic recovery in a prospective cohort of patients with surgical myelopathy: analysis of a series of 124 cases. *World Neurosurg*. 2016; 86: 112–119, doi: [10.1016/j.wneu.2015.09.044](https://doi.org/10.1016/j.wneu.2015.09.044), indexed in Pubmed: [26409089](https://pubmed.ncbi.nlm.nih.gov/26409089/).
32. Wu B, Liu B, Sang D, et al. The association between cervical focal kyphosis and myelopathy severity in patients with cervical spondylotic myelopathy before surgery. *Eur Spine J*. 2021; 30(6): 1501–1508, doi: [10.1007/s00586-021-06771-x](https://doi.org/10.1007/s00586-021-06771-x), indexed in Pubmed: [33640994](https://pubmed.ncbi.nlm.nih.gov/33640994/).
33. Cheng XJ, Jin L, Wang X, et al. Predictors of poor outcome in cervical spondylotic myelopathy patients underwent anterior hybrid approach: focusing on change of local kyphosis. *J Orthop Surg Res*. 2020; 15(1): 369, doi: [10.1186/s13018-020-01905-1](https://doi.org/10.1186/s13018-020-01905-1), indexed in Pubmed: [32867813](https://pubmed.ncbi.nlm.nih.gov/32867813/).