



Submitted: 10.01.2022  
Accepted: 08.03.2022  
Early publication date: 29.06.2022

Endokrynologia Polska  
DOI: 10.5603/EPa2022.0044  
ISSN 0423-104X, e-ISSN 2299-8306

## Van Wyk-Grumbach syndrome: a rare presentation of a common endocrine disorder

Pankaj Singhania , Rana Bhattacharjee, Subhankar Chowdhury

Department of Endocrinology and Metabolism, IPGME and R/SSKM Hospital, Kolkata, India

**Key words:** Van Wyk and Grumbach; hypothyroidism; puberty; multicystic enlarged ovaries; pituitary; L-thyroxine

Van Wyk and Grumbach first reported a combination of enlarged multicystic ovaries, hypothyroidism, and precocious puberty in 1960 [1]. This rare syndrome must be considered in the differential diagnosis of precocious puberty with enlarged ovaries to avoid unnecessary ovarian surgeries

A girl aged 7 years and 10 months girl presented with menstrual bleeding, which started one year before the presentation. There have been six episodes of menstrual bleeding since then. Along with this, the parents also reported enlargement of both breasts for the same duration. There was no history suggestive of raised intracranial tension. She had an uneventful birth and developmental history. There was no history of precocity in the family members.

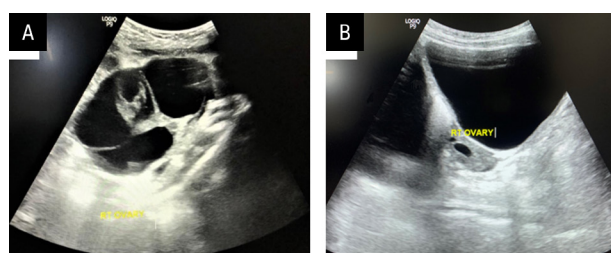
On examination, her height was 115 cm [−1.7 standard deviation score (SDS) for age and sex of the population], and she weighed 30 kg. Her breasts were Tanner stage 5 bilateral. Pubic and axillary hair were absent. The skin was dry and lustreless.

Considering a diagnosis of precocious puberty, the following hormonal investigations were obtained (Tab. 1).

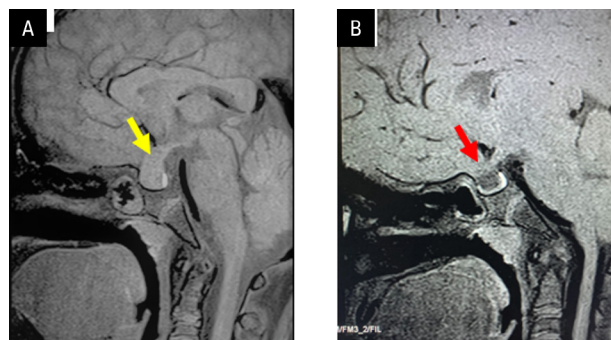
Imaging studies revealed the following:

- X-ray of left hand showed a bone age of 5 years;
- ultrasound (USG) of pelvis showed bulky ovaries (R-97 cc, L-200 cc,) with multiple enlarged cysts (Fig. 1A). The uterine dimension was 7.6 × 2.6 × 4.4 cm. The endometrial thickness was 6.3 mm;
- magnetic resonance imaging (MRI) of brain (plain and contrast) — anterior pituitary was enlarged in size [16 mm transverse (TR) × 12 mm anteroposterior (AP) × 17 mm superior-inferior (SI)] (Fig. 2A).

A diagnosis of precocious puberty secondary to primary autoimmune hypothyroidism, also known as



**Figure 1.** Ultrasound (USG) showing large multicystic ovary with thin-walled fluid-filled cysts (A). Repeat USG done after 3 months of levothyroxine replacement, showing regression of ovarian volume with disappearance of large cysts (B)



**Figure 2.** T1-weighted (T1W) magnetic resonance image (MRI) showing uniformly enlarged pituitary suggestive of pituitary hyperplasia (A) (yellow arrow). Follow-up MRI after 3 months of levothyroxine replacement showing small anterior pituitary with partial empty sella (B) (red arrow)

Van Wyk-Grumbach syndrome, was made, and she was initiated on levothyroxine replacement therapy. At 3-month follow-up, she became euthyroid (Tab. 1), and since then there have been no further episodes of menstrual bleeding. Her serum oestradiol level has also reduced to pre-pubertal levels (Tab. 1). At 3 months,



Dr Pankaj Singhania, Department of Endocrinology and Metabolism, IPGME & R/SSKM Hospital, 244, AJC Bose Road, Kolkata 70020, West Bengal, India, tel: +919153003736; e-mail: drpankaj007@hotmail.com

**Table 1.** Hormonal investigations at diagnosis and after 3 months of levothyroxine treatment

Investigation	At diagnosis	3 months after levothyroxine initiation	Reference range
Serum FT4 [ng/dL]	< 0.350	1.50	0.80–1.90
TSH [mIU/mL]	> 75.000	2.54	0.34–6.00
LH [U/L]	0.365		1.10–11.60
FSH [U/L]	6.790		3.00–14.40
Anti-TPO antibodies [IU/mL]	458.000		< 35.00
Serum prolactin [ng/mL]	71.330	6.65	< 20.00
Serum oestradiol [pg/mL]	78.000	<10.00	< 10.00

FT4 — free thyroxine; TSH — thyroid-stimulating hormone; LH — luteinizing hormone; FSH — follicle-stimulating hormone; TPO — thyroid peroxidase

repeat ultrasonography pelvis showed marked reduction of ovarian volume (right ovary of 10 mL and left ovary of 6 mL) (Fig. 1B). The pituitary hyperplasia also disappeared on repeat MRI done after 3 months (Fig. 2B). The girl has also become active, and the dryness of skin has subsided.

This case highlights an unusual manifestation of primary hypothyroidism known as the Van Wyk and Grumbach syndrome. In girls, severe hypothyroidism generally presents with delayed puberty. In their original work, Van Wyk and Grumbach [1] hypothesized this as a “hormonal overlap in pituitary feedback” causing increased production of thyroid-stimulating hormone (TSH), prolactin, gonadotropins, and oestradiol [1, 2]. Increased prolactin secretion due to thyrotropin-releasing hormone (TRH) causes a slow gonadotropin-releasing hormone (GnRH) pulse frequency, which in turn causes high follicle-stimulating hormone (FSH) secretion and low luteinizing hormone (LH) secretion at the same time [3], as seen in our case. Another cause for the high FSH concentration could be assay cross-reactivity due to very high TSH levels [3].

At the level of the ovaries, excessively high TSH concentration stimulates FSH receptors because of “specificity spillover”, leading to follicular maturation and multi-cystic changes, especially in the vulnerable peripubertal period [2, 3]. Ovarian stimulation also leads to sexual precocity. Multicystic ovaries can vary in size from slightly larger than normal to huge engagement mimicking a neoplastic lesion, as in our case, and if misdiagnosed, unnecessary ovarian surgery

may be disastrous [4, 5]. Prolactin also causes ovarian sensitization to gonadotropins and accelerates follicular maturation [6]. Elevated prolactin level and high thyrotropin (> 75 mIU/mL) levels were seen in our patient, as has been reported in most cases in the past. Feedback adenoma or hyperplasia of the pituitary can occur (as in our patient) due to excessive stimulation of thyrotrophs by TRH. Thyroxine replacement therapy can lead to regression of pubertal changes and ovarian size, and gain in height [7]. It can also reduce pituitary hyperplasia, although the time taken for the shrinkage of the hyperplastic pituitary is variable.

In conclusion, a combination of ovarian cystic enlargement with precocity in preadolescent girls should be investigated for hypothyroidism considering the possibility of Van Wyk and Grumbach syndrome. Awareness about this condition avoids misdiagnosis and potential therapeutic misadventure including unnecessary surgery.

### Disclosure

The authors have nothing to disclose.

### Conflict of interest

None of the authors have any conflict of interest that could be perceived as prejudicing the impartiality of this submission

### Funding

The authors declare that they have no source of funding.

### Consent from patient

Obtained.

### References

- Wyk J, Grumbach M. Syndrome of precocious menstruation and galactorrhoea in juvenile hypothyroidism: an example of hormonal overlap in pituitary feedback. *Journal Pediatr.* 1960; 57(3): 416–435, doi: [10.1016/s0022-3476\(60\)80250-8](https://doi.org/10.1016/s0022-3476(60)80250-8).
- Wormsbecker A, Clarson C. Acquired primary hypothyroidism: vaginal bleeding in a quiet child. *CMAJ.* 2010; 182(6): 588–590, doi: [10.1503/cmaj.090883](https://doi.org/10.1503/cmaj.090883), indexed in Pubmed: [20176756](https://pubmed.ncbi.nlm.nih.gov/20176756/).
- Baranowski E, Högl W. An unusual presentation of acquired hypothyroidism: the Van Wyk-Grumbach syndrome. *Eur J Endocrinol.* 2012; 166(3): 537–542, doi: [10.1530/EJE-11-0494](https://doi.org/10.1530/EJE-11-0494), indexed in Pubmed: [22170796](https://pubmed.ncbi.nlm.nih.gov/22170796/).
- Chattopadhyay A, Kumar V, Marulaiah M. Polycystic ovaries, precocious puberty and acquired hypothyroidism: the Van Wyk and Grumbach syndrome. *J Pediatr Surg.* 2003; 38(9): 1390–1392, doi: [10.1016/s0022-3468\(03\)00403-2](https://doi.org/10.1016/s0022-3468(03)00403-2), indexed in Pubmed: [14523827](https://pubmed.ncbi.nlm.nih.gov/14523827/).
- Indumathi CK, Bantwal G, Patil M. Primary hypothyroidism with precocious puberty and bilateral cystic ovaries. *Indian J Pediatr.* 2007; 74(8): 781–783, doi: [10.1007/s12098-007-0140-9](https://doi.org/10.1007/s12098-007-0140-9), indexed in Pubmed: [17785906](https://pubmed.ncbi.nlm.nih.gov/17785906/).
- Advis JP, Richards JS, Ojeda SR. Hyperprolactinemia-induced precocious puberty: studies on the mechanism(s) by which prolactin enhances ovarian progesterone responsiveness to gonadotropins in prepubertal rats. *Endocrinology.* 1981; 108(4): 1333–1342, doi: [10.1210/endo-108-4-1333](https://doi.org/10.1210/endo-108-4-1333), indexed in Pubmed: [6781872](https://pubmed.ncbi.nlm.nih.gov/6781872/).
- Durbin KL, Diaz-Montes T, Loveless MB. Van wyk and grumbach syndrome: an unusual case and review of the literature. *J Pediatr Adolesc Gynecol.* 2011; 24(4): e93–e96, doi: [10.1016/j.jpjg.2010.08.003](https://doi.org/10.1016/j.jpjg.2010.08.003), indexed in Pubmed: [21600802](https://pubmed.ncbi.nlm.nih.gov/21600802/).