

〈Case Report〉

## A giant axillary mass treated as breast cancer metastasis

Yutaka YAMAMOTO <sup>1)</sup>, Takuya MORIYA <sup>2)</sup>, Yuna FUKUMA <sup>1)</sup>  
Tsuyoshi MIKAMI <sup>1)</sup>, Shiori KAWANO <sup>1)</sup>, Emi KISHINO <sup>1)</sup>, Ryohei OGATA <sup>1)</sup>  
Wataru SAITO <sup>1)</sup>, Yoshikazu KOIKE <sup>1)</sup>, Mai SOHDA <sup>1)</sup>, Tsunehisa NOMURA <sup>1)</sup>  
Katsuhiko TANAKA <sup>1)</sup>, Junichi KUREBAYASHI <sup>1)</sup>

1) Department of Breast and Thyroid Surgery,

2) Department of Pathology, Kawasaki Medical School

**ABSTRACT** A 69-year-old woman with a giant fist-sized left axillary mass was admitted to the Dermatology Department of Kawasaki Medical School. No primary tumor was identified, and she was referred to the Department of Breast and Thyroid Surgery of Kawasaki Medical School Hospital. A 90-mm tumor was found in the left axilla, which exhibited ulceration and infection. Imaging analysis revealed no abnormalities in the breast or other organs such as the lungs. Needle biopsy revealed a poorly differentiated carcinoma exhibiting a mixture of glandular structures and keratinization, and it was difficult to determine the original tumor. The differential diagnoses were primary skin cancer, including adnexal organs, occult breast cancer, accessory breast cancer and metastatic tumor from unknown malignancy. Immunohistochemical analysis revealed that this tumor had no estrogen receptor, progesterone receptor or human epidermal growth factor receptor 2 expression. Primary chemotherapy was initiated because the National Cancer Comprehensive Network guidelines recommend that unclassified axillary epithelial malignancies in women be treated as occult breast cancer. After 4 cycles of epirubicin plus cyclophosphamide followed by 4 cycles of docetaxel plus doxorubicin, the axillary tumor shrunk to 15 mm in size. Axillary lymph node dissection, including skin resection of the axilla, was performed, and radiotherapy to the left breast and left axilla/supraclavicular lymph node area was administered. There has been no recurrence for over 4 years.

doi:10.11482/KMJ-E202147001 (Accepted on December 9, 2020)

Key words : Axillary malignant tumor, Occult breast cancer, Chemotherapy

### INTRODUCTION

Cancers of unknown origin account for 2 to 4% of all cancer cases<sup>1)</sup>. The National Cancer

Comprehensive Network (NCCN) guidelines recommend that unclassified axillary epithelial malignancies in women be treated as occult breast

---

Corresponding author

Yutaka Yamamoto

Department of Breast and Thyroid Surgery, Kawasaki Medical School, 577 Matsushima, Kurashiki, 701-0192, Japan

Phone : 81 86 462 1111

Fax : 81 86 462 1199

E-mail: yamayou@med.kawasaki-m.ac.jp

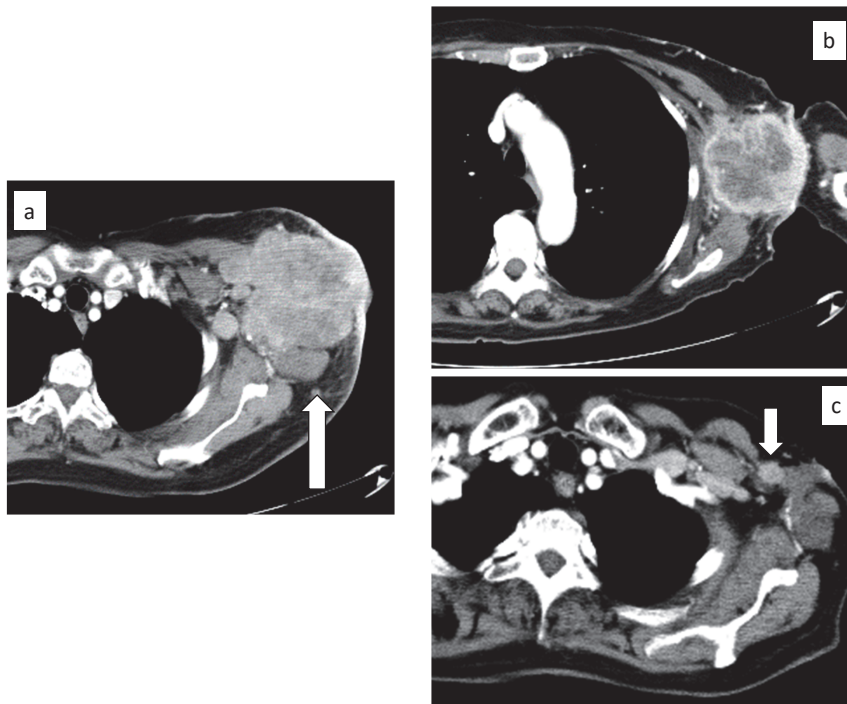


Fig. 1. Contrast-enhanced CT findings. (a) A giant axillary mass (before chemotherapy, arrow), (b) Shrunken axillary mass (after EC therapy), (c) A small axillary mass (after docetaxel plus doxorubicin therapy, arrow).

cancer<sup>2)</sup>. Therefore, a treatment strategy should be set in accordance with stage II or stage III primary breast cancer in clinical practice. Although the prognosis of patients with cancer of unknown origin is generally poor, patients with adenocarcinoma in the axillary lymph nodes have a better prognosis than those with other types of cancers of unknown origin<sup>3)</sup>.

We recently treated a patient with a giant malignant axillary tumor that was treated as occult breast cancer. This patient received primary chemotherapy, radical surgery and radiotherapy for occult breast cancer. The patient has been alive without disease for over 4 years. However, because occult breast cancer is rare and its treatment is controversial, we report this case.

## CASE REPORT

A 69-year-old woman at the first visit to Kawasaki Medical School Hospital

Chief complaint: A giant left axillary mass

Present illness: In 201X, she noted a quail egg-sized subcutaneous nodule in the left axilla. It rapidly increased in size thereafter. She visited the Department of Dermatology of Kawasaki Medical School Hospital in 201X + 4 years. A giant fist-sized subcutaneous mass was found in the left axilla, but imaging analyses did not reveal primary tumors of any origin. She was then referred to the Department of Breast and Thyroid Surgery of Kawasaki Medical School Hospital.

Past history: Not contributory

Family history: Not contributory

Physical findings:

Breast: No palpable mass

Left axilla: A 90-mm mass with ulceration and infection

Image analyses:

Enhanced CT (Fig. 1a): A 92 × 84-mm mass in the left axilla and no primary tumor in other organs

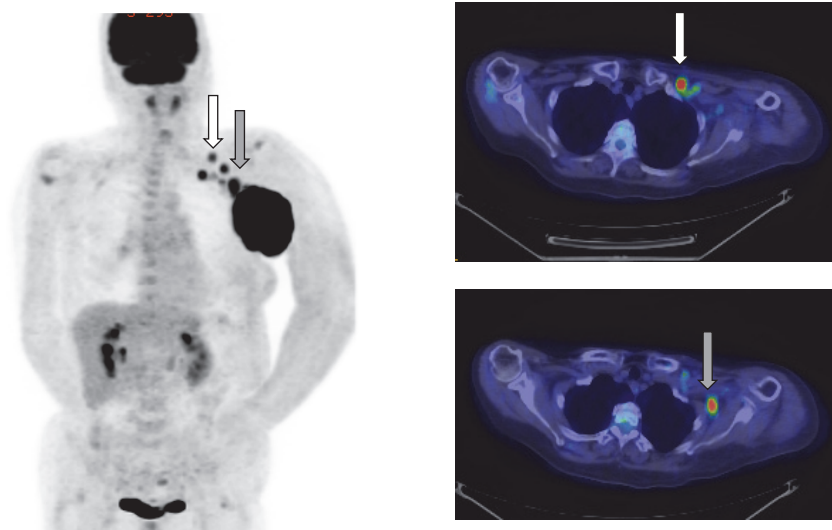


Fig. 2. Fluorodeoxyglucose (FDG) positron emission tomography (PET)/CT showing an axillary mass (gray arrow) and an infraclavicular mass (white arrow).

Positron emission tomography (PET)/CT (Fig. 2): Abnormal high accumulation in the left axillary and subclavicular lesions, but no primary tumor in other organs

Blood tests: White blood cell count of 14,020/ $\mu$ L, C-reactive protein of 3.05 mg/dL, carcinoembryonic antigen of 314 ng/mL and CA15-3 of 168.3 U/mL

Histopathological examination using a biopsied specimen:

Prominent foci of atypical cells with nuclear atypia were observed in the dermis and proliferated to form irregular solid tufts, which were considered to be poorly differentiated carcinoma. There was an area where the gland-like structure was distinguished and an area where keratinization was distinguished. Immunostaining demonstrated a pattern of cytokeratin (CK)7 positivity and CK20 negativity. As squamous cell carcinoma, breast cancer, lung cancer, uterine cancer and non-mucinous ovarian cancer were among the differential diagnoses, GATA3, GCDFP-15, TTF-1, p40 and Pax-8 were examined by immunostaining. All were negative; therefore, a definitive diagnosis was not reached. However, considering the results

of ER / PgR-negative, HER2-negative, EGFR-positive and CK5/6-positive, triple-negative breast cancer of the basal subtype was suggested.

Differential diagnosis:

Primary skin cancer, including adnexal organs, occult breast cancer, accessory breast cancer and metastatic tumor from unknown malignancy were considered.

Treatment:

Primary chemotherapy was initiated based on the NCCN guidelines<sup>2)</sup>. Four cycles of EC (epirubicin plus cyclophosphamide) followed by 4 cycles of docetaxel plus doxorubicin were administered. The axillary tumor shrunk to 15 mm in size (Fig. 1b, c). Thereafter, axillary lymph node dissection, including skin resection of the left axilla, was performed.

Histopathological examination of the resected specimen:

The cancer was infiltrating and poorly differentiated (Fig. 3a  $\times$ 100), and consisted mainly of solid alveolar nests. Areas with a keratinized structure (Fig. 3b  $\times$ 200) and glandular structure (Fig. 3c  $\times$ 400) were recognized. The tumor cells

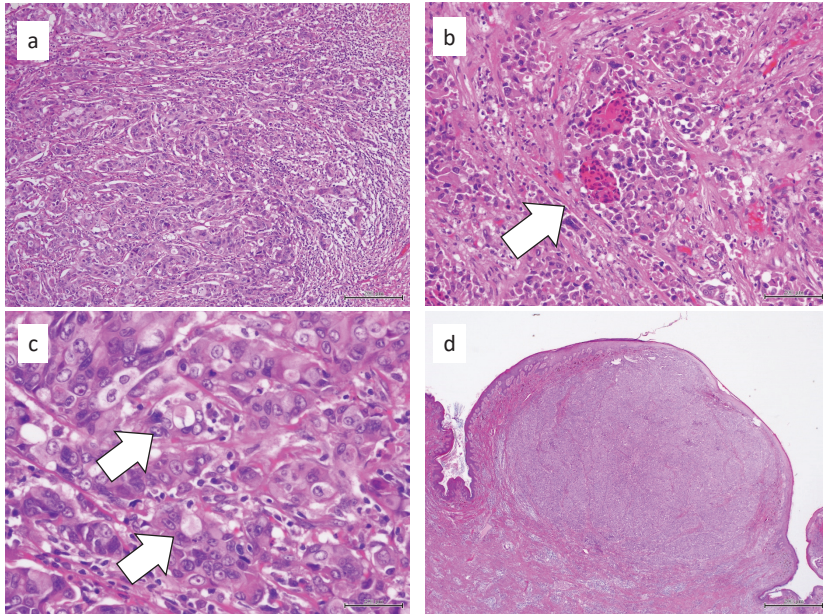


Fig. 3. Histopathological findings of the resected specimen. (a) The cancer was infiltrating and poorly differentiated. (b) Keratinized structure. (c) Glandular structure. (d) The tumor demonstrated extranodal invasion.

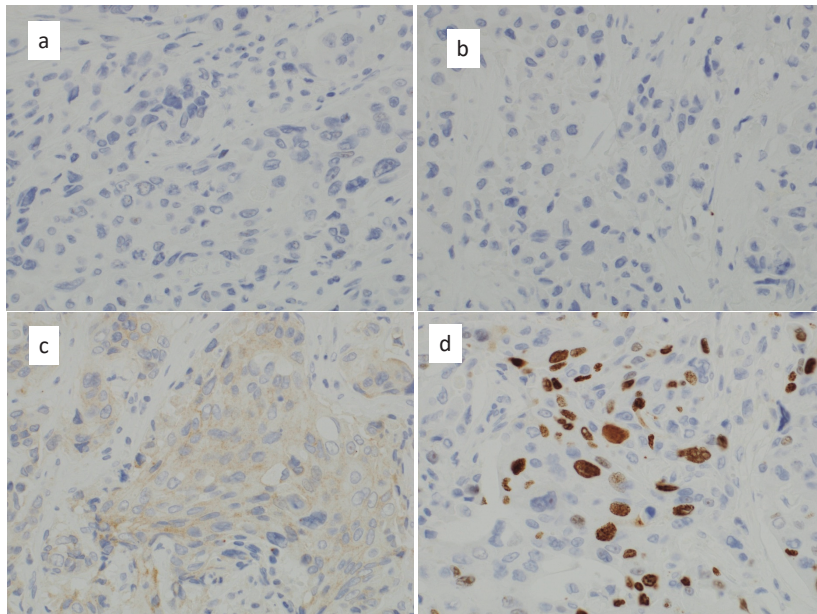


Fig. 4. Microscopic findings based on immunostaining for ER (a), PR (b), HER2 (c) and Ki-67 (d).

exhibited a patchy distribution, and a nodule with a maximum diameter of 13 mm was considered to be a metastatic lesion of the lymph node or extranodal invasion (Fig. 3d  $\times 20$ ), but a 6-mm nodule

formed in part of the skin (dermis). Varying levels of fibrosis, post-hemorrhagic changes, chronic inflammation and histiocyte aggregation, which are considered the effects of preoperative drug therapy,

were observed. Similar to the results of biopsy, the effects of preoperative drug therapy suggested Grade 2a in terms of breast cancer handling regulations<sup>4)</sup>. Lympho-vascular invasion was not clear and no metastasis was observed in other lymph nodes. On immunostaining ( $\times 400$ ), the ER-positive rate was 0% (Fig. 4a), the PR-positive rate was 0% (Fig. 4b), the HER2 score was 1+ (Fig. 4c) and the Ki-67-positive rate was 40.4% (Fig. 4d).

Postoperative course:

No systemic chemotherapy was added, and radiotherapy to the left breast and left axilla/supraclavicular lymph node area was performed. There has been no recurrence for 4 years.

## DISCUSSION

The diagnosis in this case was not definitive even though the clinical course and histopathological findings were considered. This case was treated as occult breast cancer because the main nodule was suggested to be lymph node metastasis with extranodal involvement. In addition, neither primary skin carcinoma nor accessory breast cancer was found.

Female patients with isolated lymph node metastases in the axilla may have Stage II or Stage III primary breast cancer. Reported clinicopathological characteristics of such patients included a median age of 52 years old, their histological classification was often high-grade invasive ductal adenocarcinoma with neither ER nor PR and they frequently had distant metastases at the time of diagnosis<sup>5, 6)</sup>.

In order to select an appropriate treatment strategy for occult breast cancers, it is necessary to biopsy axillary lymph node metastases. Histopathological examination of the biopsied specimen should confirm that the tumor metastasized from carcinoma. In addition, subtype analysis of the tumor should be performed using immunostaining for several biological markers. In this case, carcinoma cells

were detected in the axillary lymph nodes, and no expression of ER, PR or HER2 was detected in tumor cells. Therefore, we decided to treat it as primary triple-negative breast cancer.

In a study of 42 patients with axillary lymphadenopathy of unknown origin, the addition of chemotherapy after local treatment (14 patients) was compared with local treatment alone (28 patients). The 5-year overall survival rate of the former was significantly better than that of the latter (93% and 64%, respectively)<sup>7)</sup>. Chemotherapy before local therapy has also been reported, concluding that if metastatic axillary lymph nodes are large, chemotherapy before local therapy should be considered<sup>8)</sup>. According to the clinical guidelines of the Japan Breast Cancer Society, histopathological examination of axillary lymph nodes should be performed and systemic drug therapy should be administered in addition to local therapy, as for axillary lymph node metastasis-positive breast cancer, when treating patients with axillary lymph node metastases of unknown origin<sup>9)</sup>.

In cases of occult breast cancer, imaging methods for detecting intramammary lesions are essential. In a review of patients with occult breast cancer undergoing contrast-enhanced breast magnetic resonance imaging (MRI), approximately 80% of 220 patients in whom mammography did not detect any lesion had intramammary lesions. Of the 22 patients who underwent surgery, 21 (90%) had minimal cancerous lesions that were pathologically found<sup>10)</sup>. Therefore, contrast-enhanced breast MRI should be performed before the start of treatment in cases in which breast cancer cells are found in the axillary lymph nodes.

Regarding the local treatment of occult breast cancers, the clinical guidelines of the Japan Breast Cancer Society state that "for occult breast cancer cases in which contrast-enhanced breast MRI detects no enhanced lesion in the breast, axillary lymph node dissection followed by whole breast irradiation

should be considered"<sup>11)</sup>. In this case, the size of the axillary mass prevented contrast-enhanced breast MRI. Therefore, although no lesion was found in the breast by other imaging modalities, such as ultrasonography, total mastectomy with axillary lymph node dissection should be considered. As such, we recommended the above treatments, but the patient selected whole breast irradiation plus axillary lymph node dissection as local therapy. She has been alive without recurrence for over 4 years.

### CONFLICTS OF INTEREST

JK received advisory/consultation fees and research funding from Takeda Pharmaceutical Co. JK also received research funding from Eisai Co. The other authors declare that they have no conflicts of interest.

### REFERENCES

- 1) Greco FA, Burris HA 3rd, Erland JB, Gray JR, Kalman LA, Schreeder MT, Hainsworth JD: Carcinoma of unknown primary site. *Cancer*. 2000; 89: 2655-2660.
- 2) <https://www2.tri-kobe.org/nccn/guideline/occult/english/occult.pdf#search='NCCN+guideline%2C+Occult+Primary'> (2020.9.11)
- 3) Pavlidis N: Cancer of unknown primary: biological and clinical characteristics. *Ann Oncol*. 2003; 14: iii11-18. doi: 10.1093/annonc/mdg742.
- 4) Japan Breast Cancer Society (SV): General Rules for Clinical and Pathological Recording of Breast Cancer (The 18<sup>th</sup> version), KANEHARA & CO., LTD. Tokyo, 2018; 94-100.
- 5) Vlastos G, Jean ME, Mirza AN, *et al.*: Feasibility of breast preservation in the treatment of occult primary carcinoma presenting with axillary metastases. *Ann Surg Oncol*. 2001; 8: 425-431. doi: 10.1007/s10434-001-0425-6.
- 6) Jackson B, Scott-Conner C, Moulder J: Axillary metastasis from occult breast carcinoma: diagnosis and management. *Am Surg*. 1995; 61: 431-434.
- 7) Ellerbroek N, Holmes F, Singletary E, Evans H, Oswald M, McNeese M: Treatment of patients with isolated axillary nodal metastases from an occult primary carcinoma consistent with breast origin. *Cancer*. 1990; 66: 1461-1467. doi: 10.1002/1097-0142(19901001)66:7<1461::aid-cncr2820660704>3.0.co;2-z.
- 8) Fayanju OM, Jeffe DB, Margenthaler JA: Occult primary breast cancer at a comprehensive cancer center. *J Surg Res*. 2013; 185: 684-689. doi: 10.1016/j.jss.2013.06.020.
- 9) <http://jbcs.gr.jp/guideline/2018/index/yakubutu/y3-bq-9/> (2020.9.11)
- 10) de Bresser J, de Vos B, van der Ent F, Hulsewé K: Breast MRI in clinically and mammographically occult breast cancer presenting with an axillary metastasis: a systematic review. *Eur J Surg Oncol*. 2010; 36: 114-119. doi: 10.1016/j.ejso.2009.09.007.
- 11) <http://jbcs.gr.jp/guideline/2018/index/gekaryoho/g5-fq-11/> (2020.9.11)