

# Volumetric Soft Tissue Changes After Using Injectable Platelet-Rich Fibrin (I-PRF) Versus Subepithelial Connective Tissue Graft in Interdental Papillae Defects: A Randomized Controlled Clinical Study

Mohamed Wagdy Bissar,<sup>A</sup> Nouran Nasser,<sup>A</sup>  
Mohamed Sherif El-Mofty<sup>A,B</sup>

<sup>A</sup>Department of Oral Medicine, Periodontology, Oral Diagnosis, and Radiology, Faculty of Dental Medicine, Ain Shams University, Cairo, Egypt.

<sup>B</sup>Community Service and Environmental Development Organization, Faculty of Dental Medicine, Nahda University, Beni Suef, Egypt.

Accepted for publication:  
May 18, 2022

## Abstract

**Background:** Lost interdental papillae in the esthetic region are of great concern from the esthetic and functional point of view. We elicit a clinical study of papillary reconstruction in this article using injectable platelet-rich fibrin (I-PRF) as a nonsurgical procedure and compare its results to those of the subepithelial connective tissue graft (SECTG), being considered the gold standard method used to reconstruct interdental papillae. **Methods:** Twenty-four patients seeking treatment for black triangles were randomized into two groups: group A patients were treated with the SECTG technique, and group B patients were treated with I-PRF. Four injections were given at each papilla site at baseline, two-, four-, and six-week intervals to ensure optimal esthetics. Pain, clinical, and volumetric assessments were done. Volumetric assessment was completed through intraoral scanning of the papilla site at baseline and after six months, after which the results were obtained by superimposition of both scans. **Results:** Group A ( $5.08 \pm 2.15$ ) had a significantly higher mean pain score value than group B ( $1.17 \pm 0.94$ ) ( $p < 0.001$ ). Group B ( $0.31 \pm 0.21$ ) had a higher mean value of volumetric changes at the interdental papillae than group A ( $0.25 \pm 0.17$ ), yet the difference was not significant ( $p = 0.517$ ). **Conclusion:** Injectable platelet-rich fibrin gave comparable results to SECTG in Nordland Class I defects only, provided that the injection protocol was once every 15 days for a two-month period. Patients treated with I-PRF were more satisfied with the procedure and the results than patients who were treated with SECTG.

**Keywords:** Interdental papilla; injectable platelet-rich fibrin; volumetric analysis; scanning; subepithelial connective tissue graft

## Introduction

The interdental space is the physical space present between two adjacent teeth. The interdental papilla represents the gingival tissue that fills this space and is formed by dense connective tissue covered by oral epithelium.<sup>1</sup> Gingival black triangles (GBTs) are defined as the embrasures cervical to the interproximal contact that is not filled by gingival tissue and they appear as black pyramidal spaces. Loss of the papilla has a negative effect on an individual's smile and causes phonetic problems and food

accumulation which can negatively affect periodontal health.<sup>2</sup> The etiology of GBTs is known to be multifactorial. They may form as a result of active periodontal disease, osseous surgeries, traumatic extraction, tooth brush trauma, decreased keratinization due to aging, and changes in tooth alignment during orthodontic treatment. Other factors that may influence the formation of GBTs include interproximal root distance, tooth malposition, interproximal bone height in relation to interproximal contact, gingival biotype, and

gingival contour. The contact points of maxillary anterior teeth and their distance from the crest of the interproximal bone plays an important role in the form and shape of interdental papilla. In a landmark study, Tarnow et al. described the '5mm rule.' The rule states that when the distance from the contact point to the interproximal osseous crest is 5 mm or less, there is complete fill of the gingival embrasures with interdental papilla. For every 1 mm above 5 mm, the chance of complete fill is reduced by 50%. When the distance from the contact point to the alveolar crest was less than or equal to 5 mm, the papilla was present 98% of the time, while at 6 mm it dropped to 56%, and at 7 mm it was present only 27% of the time.<sup>3</sup> Nordland and Tarnow classified interdental papilla loss into four classes based on three anatomic landmarks: the contact point interdentally, the coronal level of the cemento-enamel junction (CEJ) interproximally, and the facial apical level of the CEJ. A normal interdental papilla fills up the whole embrasure to the interproximal contact point, in Class I the tip of the papilla is between the interdental contact point and the interproximal CEJ, in Class II the tip of the papilla is at the interproximal CEJ or apical to it but is still coronal to the facial CEJ, and in Class III the tip of the papilla is on the same plane as the facial CEJ or apical to it.<sup>4</sup>

To better manage GBTs, dentists must be aware of the underlying etiology and make an individualized treatment plan for each patient.<sup>5</sup> If the loss of papilla is only related to soft tissue, reconstruction techniques are capable of restoring it completely. If the loss of papilla is caused by periodontal disease with interproximal bone resorption, usually a complete reconstruction is not achieved.<sup>6,7</sup> Periodontal plastic surgery has a long history in overcoming GBTs. However, the papillae's poor blood supply which originates from one direction towards the papilla base was the main limiting factor in all augmentation and reconstruction surgical approaches.<sup>2,6</sup> Surgical approaches for preventing and managing GBTs include papilla recontouring, papilla preservation, papilla reconstruction, and papilla regeneration.<sup>7</sup> The semilunar coronally repositioned flap was

described by Han and Takei in which the semilunar incision is made facial to the interdental area and a pouch-like preparation is created. Intrasulcular incisions are made around the mesial and distal half of the two adjacent teeth to free the connective tissue from the root surfaces in order to allow coronal displacement of the gingival-papillary unit. A connective tissue graft, harvested from the palate, is then placed into the pouch to support the coronally positioned interdental tissue.<sup>8</sup>

Papillary regeneration incorporates tissue engineering, enamel matrix proteins (EMPs), acellular dermal matrices, and platelet concentrates. Platelet concentrate therapy was developed in order to naturally accelerate the regenerative potential of platelets contained in blood.<sup>9</sup> Platelet-rich fibrin was introduced in 2001 by Choukroun as a second-generation platelet concentrate without an anticoagulant. It is defined as an autologous fibrin matrix containing platelet cytokines, growth factors, and cells that settles into three layers: an upper straw-colored acellular plasma, a red-colored lower fraction containing red blood cells (RBCs), and a middle fraction containing the fibrin clot. Injectable platelet-rich fibrin (I-PRF) has been developed as there is still an existing necessity for a fluid biological system in clinical practice. According to the low-speed centrifugation concept (LSCC), further reduction of the relative centrifugal force to 60 g and the use of plastic tubes allowed for the introduction of an I-PRF matrix without using anticoagulants. In contrast to the glass tubes used in solid PRF matrices, the characteristics of the plastic surface do not activate the coagulation cascade during centrifugation. The collected I-PRF maintains its fluid phase for up to 10 to 15 minutes after centrifugation.<sup>10,11</sup> Injectable platelet-rich fibrin is also used in esthetic medicine for skin rejuvenation and as an autologous material, this makes the procedures safer without eliciting a foreign body reaction and lowers the cost as well. When performing lips augmentation and contouring, I-PRF is utilized in combination with PRF to contour the lips. The PRF is able to provide more volume by providing a three-dimensional fibrin scaffold necessary to increase tissue thickness, whereas the I-

PRF provides more leukocytes and a higher concentration of growth factors per volume and therefore an ability to increase wound healing and tissue regeneration. When both PRF and I-PRF are used in combination during augmentation procedures, greater tissue augmentation is expected. This procedure is typically performed once every 15 days for 60 days to ensure optimal esthetics.<sup>12</sup> A study used I-PRF in treating gingival black triangles by repetitively injecting I-PRF for a total of six times at 15-day intervals. An improvement in the height of the interdental papillae was observed at three months with a papilla index score of 3 and the results were quite stable after six months.<sup>13</sup> In a case report that evaluated the effect of hyaluronic acid for repairing interdental papillae in the esthetic area, a volumetric analysis of the interdental papillae was performed by intraoral three-dimensional scanning using CAD/CAM and was measured by overlap using the equipment software itself. It is believed that distortion of the measures in these cases is low due to the high technology equipment being used.<sup>14</sup> The aim of the present study was to clinically evaluate the effect of I-PRF versus subepithelial connective tissue graft (SECTG) for interdental papilla reconstruction in the esthetic zone by assessing volumetric and clinical changes using an intraoral scanner after six months of treatment.

### **Materials and Methods**

The study was conducted on a total of 24 patients recruited from the outpatient clinic of the Oral Medicine, Periodontology, Oral Diagnosis, and Radiology department of the Faculty of Dental Medicine, Ain-Shams University. These patients were seeking treatment for black triangles for esthetic reasons. Patients were considered eligible for the trial according to the following criteria:

1. Both genders aged between 18 to 40 years
2. Patients free from systemic disease as evidenced by Burket's health questionnaire<sup>15</sup> (A complete blood count was requested from the patient to rule out hemoglobin or platelet disorders.)

3. Patients with Nordland Class I or II interdental papilla loss in the anterior region<sup>4</sup>
4. Vertical distance from the interdental contact point to the crest of the interdental bone  $\geq 6$  mm as measured by bone sounding
5. The presence of a band of keratinized tissue  $\geq 2$  mm
6. Patients concerned about esthetics and motivated to go through the treatment of "black triangles" by interdental papillae reconstruction in the esthetic zone

Patients were excluded from the study if any of the following were found:

1. Teeth with acute periapical pathosis
2. Teeth with mild, moderate, or severe periodontitis
3. Pregnancy or lactation
4. Parafunctional habits
5. Smokers, alcoholics, or drug abusers
6. Poor oral hygiene, noncompliance to treatment, or persistence of gingival inflammation following phase I therapy
7. Previous treatment of black triangles (surgical or non-surgical)
8. Vulnerable groups: prisoners, mentally retarded, etc.

The study was introduced to the Ethics Committee of the Faculty of Dental Medicine, Ain Shams University and was approved prior to the start of the study (FDASU-RECIM111609). The study was designed as a randomized comparative clinical trial in which eligible patients were randomized for assigned intervention in a 1:1 ratio into two groups (12 patients in each group). Group A included 12 patients treated with SECTG surgery, and group B included 12 patients treated with I-PRF. The I-PRF procedure was repeated a total of four times at 15-day intervals.

### **I. Preoperative Procedures**

All patients received phase I therapy one month before intervention. After one month, the patients' oral hygiene was re-evaluated before surgery until a full mouth plaque score of  $<10\%$  was achieved. A composite stent was prepared on the day of surgery to standardize measurements from the tip of the papilla to the contact point (TP-CP distance).<sup>16</sup> Volumetric assessment was

done by scanning the site of papilla deficiency with an intraoral scanner.<sup>14</sup>

## II. Surgical Procedures

### Group A (SECTG Group):

The papilla reconstruction procedure was performed in a manner similar to that described by Han and Takei.<sup>8,17</sup>

### Group B (I-PRF Group):

Injectable platelet-rich fibrin was prepared in accordance with the protocol developed by Choukroun et al. and the injection method was done according to Becker et al.<sup>10,11,18</sup> The area was anesthetized using infiltration anaesthesia by inserting the needle 2-3 mm apical to the tip of the interdental papilla and directing it coronally at an angle of 45° to the long axis of the tooth with the bevel directed apically. A multiple point injection technique for I-PRF was performed on the connective tissue of the interdental papilla, which was lightly moulded in an incisal direction for one minute using gauze. Four I-PRF injections were given at each papilla site: at baseline, and at two-, four-, and six-week intervals to ensure optimal esthetics.<sup>12,13</sup>

## III. Postoperative Procedures

Postoperative instructions were given to patients in written form. Patients were advised to stop mechanical plaque control (including interdental aids) 24 hours after the procedure. Oral hygiene reinforcement was provided at each follow up visit whenever indicated until six months postoperatively.

Follow up was done after 10-14 days, and all patients were recalled to evaluate oral hygiene and for suture removal in group A (SECTG group). In group B (I-PRF group), the patients were recalled to assess oral hygiene and to be given their next injection until four injections were administered in a two-month interval. The patients in the follow up visits were asked to give their perception of the procedure concerning general satisfaction and pain. Six months postoperatively, the patients were recalled for clinical and volumetric assessment.

## IV. Assessment

### Clinical Assessment:

Plaque index, gingival index, papillary height, and TP-CP distance were all assessed.<sup>4,19,20</sup>

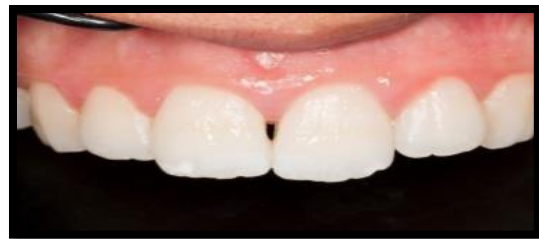### Volumetric Assessment:

The sites to be treated were scanned with an intraoral scanner preoperatively and six months postoperatively, and the scanned data files (STL files) were extracted and saved for interpretation.<sup>21,22</sup>

### Statistical Analysis:

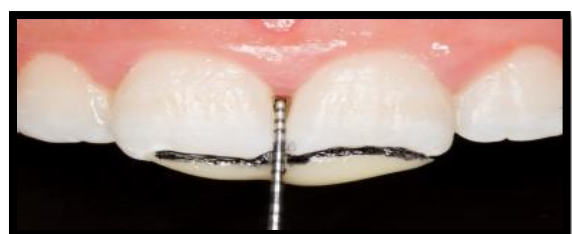The collected data were revised, coded, tabulated, and introduced to a PC using IBM SPSS Statistics (Version 25) for Windows. Statistical tests used were the Kolmogorov-Smirnov and Shapiro-Wilk tests, chi-squared test, independent t-test, and Mann-Whitney U test. The significance level was set at  $p \leq 0.05$ , and  $p \leq 0.001$  was considered highly significant.

### Figure 1.



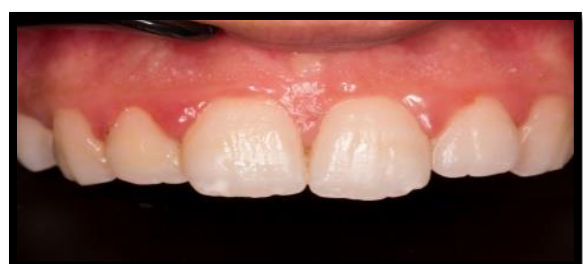Nordland Class I

### Figure 2.



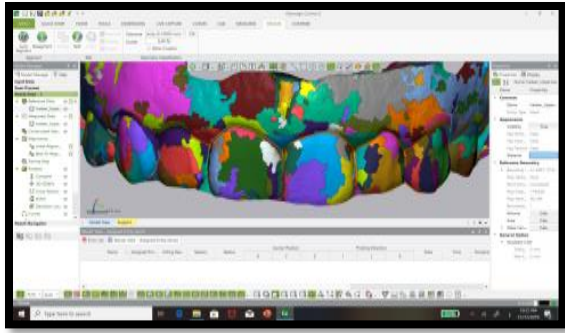
UNC color coded periodontal probe and composite stent with indentation for repeated accurate placement of the probe

### Figure 3.



Six months postoperative following I-PRF injection protocol

**Figure 4.**



3D comparison represented by a color map

**Results**

**I. Plaque Index Assessment**

In group A, there was a significant decline in plaque index from baseline ( $1.77 \pm 0.98$ ) to six months ( $0.70 \pm 0.90$ ) ( $p < 0.001$ ). There was also a significant decline in the plaque index of group B from baseline ( $1.55 \pm 0.87$ ) to six months ( $0.75 \pm 0.91$ ) ( $p < 0.001$ ).

**II. Gingival Index Assessment**

In group A, there was a significant decline in gingival index from baseline ( $1.44 \pm 0.81$ ) to six months ( $0.74 \pm 0.72$ ) ( $p = 0.026$ ). There was also a significant decline in the gingival index of group B from baseline ( $1.48 \pm 0.79$ ) to six months ( $0.36 \pm 0.38$ ) ( $p < 0.001$ ).

**III. TP-CP Distance**

There was a significant decrease in the TP-CP distance in group A ( $p < 0.001$ ) and group B ( $p = 0.001$ ) post-operatively.

**IV. Volumetric Analysis**

Group B had a higher mean value of volumetric changes ( $0.31 \pm 0.21$ ) at the interdental papillae than group A ( $0.25 \pm 0.17$ ) yet the difference was not significant ( $p = 0.517$ ).

**Table 1. Volumetric changes**

Volumetric Changes (Mean $\pm$ SD)		P-Value
Group A	Group B	
$0.25 \pm 0.17$	$0.31 \pm 0.21$	0.517 NS

\*Significant at  $p \leq 0.05$ ; NS: non-significant ( $p > 0.05$ )

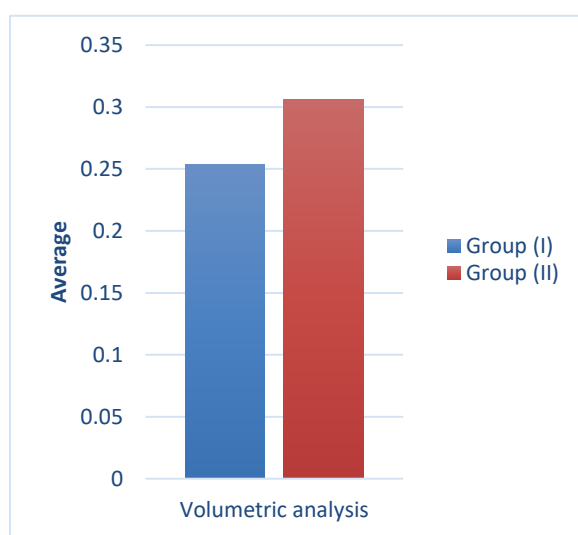
**Discussion**

Most of the research on reconstruction of lost interdental papillae for cosmetic reasons

is limited to case reports, a few of which demonstrate long-term stability.<sup>23</sup> To our knowledge, no controlled clinical trial has addressed the issue except for a case series reported by Nemcovsky on 10 consecutively treated cases for papillae reconstruction using a palatal approach.<sup>24</sup> Interdental papillae augmentation using SECTG yields predictable results as was reported in the literature. However, the need for a second surgical site remains a limitation towards patient satisfaction.<sup>25</sup> Nonsurgical techniques are preferred for their cost effectiveness, minimal stress, and for achieving immediate results with high satisfaction rates.<sup>26</sup> Becker et al. conducted a study that aimed to evaluate the efficacy of commercially available hyaluronic acid (a tissue volumizer) gel to eliminate deficient papillae.<sup>18</sup> Although hyaluronic acid is biocompatible and safe to use, with no evidence of cytotoxicity, it may be associated with allergic reactions and patients should be warned of this possible treatment side effect.<sup>27</sup> Platelet-rich fibrin is a second generation platelet concentrate, and the fact that it is an autologous, not a pharmaceutical, preparation eliminated concerns about immunogenic reactions and disease transmission. Injectable platelet-rich fibrin is a liquid concentrate with growth factors and other components readily available as they are not encapsulated in a fibrin matrix. According to Miron et al., I-PRF forms a small clot which acts as a dynamic hydrogel containing cells that can release additional growth factors over a period of 10 days. Injectable platelet-rich fibrin is utilized in combination with PRF to contour the lips.<sup>28</sup> This procedure is typically performed once every 15 days for 60 days to ensure optimal esthetics.<sup>12</sup> In the present study, I-PRF was used for interdental papillae reconstruction by injecting the I-PRF into the interdental papillae, using the same technique, once every 15 days for a period of two months. Study results were evaluated at six months follow-up and were compared to those of the SECTG group which was considered the control group. Clinical, volumetric, and patient satisfaction parameters were assessed in the present study.

Plaque index and gingival index assessments revealed that there was a significant decrease in their value from baseline to six months in both groups. This reduction in scores could be attributed to the regular oral hygiene instructions given to the patients, thereby enabling more efficient plaque control and improved patient compliance following treatment. It could also imply that both treatments were well tolerated by the host tissues without enhancing plaque accumulation or gingival inflammation. These results were in accordance with Kaushik's study results.<sup>29</sup> Nordland and Tarnow's classification assessment demonstrated that the I-PRF group had a higher percentage of patients who either returned to normal (i.e. they no longer had a papillary deficiency) or whose papillary deficiency became or remained a Class I. These results may be attributed to the greater number of Class I cases in the I-PRF group. Class I cases respond in a preferable way as there is no bone loss and the surface area and volume of the defect is small enough to be within the regenerative capacity of I-PRF.

**Figure 5.**



Bar chart showing volumetric changes in both groups

There was a significant decrease in TP-TC distance in both groups which reflects the positive results of I-PRF in increasing interdental papillae length very similarly to the SECTG group without the need for surgical intervention. These results remained stable in the follow-up period and were in contrast to what was reported by Aspalli et al. in 2015 when they conducted their case report using PRF to treatment lost

interdental papillae. They started at a TP-CP distance of 3 mm and no filling occurred after six months.<sup>30</sup> This may be attributed to the limitation of surgery within the interdental papillae region. However, these results were in accordance with those of Ahila et al. who observed that the mean of TP-CP distance decreased significantly from  $4.28 \pm 0.458$  to  $2.0 \pm 0.500$  after three months and to  $0.30 \pm 0.638$  after six months.<sup>31</sup>

The I-PRF group had a higher mean value of volumetric changes at the interdental papillae than the control group yet this difference was not significant. This may be attributed to the higher percentage of Class I Nordland defects in the I-PRF group. The area, height, and width of the black triangle can be used as diagnostic criteria to predict the effects and possible outcome of interdental papillae reconstruction. The narrower and smaller the defect, the more the expected filling, and that was clearly observed in our study when treating Class I defects which gave more predictable results than Class II defects. In accordance with the results of the present study, Becker et al. conducted a study showing that injectable hyaluronic acid gel can be used to reconstruct interdental papillae in areas with few interdental papillae deficiencies.<sup>18</sup> The results of the present study are also in accordance with the those of Thaiz Zatta da Silva et al. Both studies used nearly the same technique of volumetric assessment and found nearly the same interdental papillae defects after injection of different materials.<sup>14</sup>

On assessing patient satisfaction, there was a significant difference in the responses of both groups. The higher satisfaction level found among patients in the I-PRF group may be attributed to the ease of the procedure and the optimum results reached without the need for surgery or a pharmaceutical preparation. However, the results of the present study were in contrast to the results of a case series presented by Awartani and Tatakis. They evaluated patient satisfaction after hyaluronic acid injection using the same injection technique as this study. Approximately half of the patients (5/9)

rated the first injection as being the worst, while the remaining patients (4/9) rated all the injections the same. Although patient satisfaction with their smile and the amount of space between their teeth improved post treatment, only 66% of patients would opt to undergo the procedure again.<sup>32</sup>

On assessing the pain score, the control group had a significantly higher mean value of pain score than the I-PRF group yet the difference was not significant ( $p < 0.001$ ). This is attributed to the difference between the invasive and noninvasive techniques used in the present study. Patients who were treated with surgical intervention felt more pain during the first 10 days postoperatively compared to patients who were treated with I-PRF. There have been studies of PRF for papilla reconstruction with good results using various surgical and microsurgical methods. In the present study, assessment of clinical, volumetric, and patient satisfaction parameters revealed that I-PRF had a positive effect on interdental papillae regeneration with better patient satisfaction which seemed to be stable at six months follow-up, provided that it is used in a small papillary defect (i.e. Nordland Class I) with an injection protocol of once every 15 days for two months. These results were also in accordance with those of a case report by Pratima and Kour who used I-PRF for papilla reconstruction through repeated injections over a period of three months until favorable results were obtained, which seemed to be stable at six months follow-up.<sup>14</sup> Thus, I-PRF can serve as an easy-to-prepare alternative for gaining interdental papillary height with excellent results that are comparable to SECTG surgery.

Conclusively, the present study shows a novel approach to using I-PRF to reconstruct mild interdental papillae loss. The SECTG group represented the control group due to the fact that its results are well documented in the literature compared to other interdental papillae loss treatment modalities. Subepithelial connective tissue grafts yielded good results in both Nordland Class I and Class II defects, and I-PRF gave comparable results to SECTGs in Nordland Class I

defects only, provided that the cause was removed, meticulous oral hygiene was followed, and the injection protocol was once every 15 days for a period of two months. Patients treated with I-PRF were more satisfied with the procedure and results than were patients treated with SECTGs. Further clinical trials using I-PRF in combination with leukocyte platelet-rich fibrin or connective tissue grafts to increase papillary volume are needed. Studies using slowly degradable materials to augment interdental papillae are also recommended. Furthermore, investigations with a larger sample size and long-term follow-up to confirm stability of the results may be required.

### **References**

1. Sharma AA, Park JH. Esthetic considerations in interdental papilla: remediation and regeneration. *J Esthet Restor Dent*. 2010 Feb; 22(1):18-28. <https://doi.org/10.1111/j.1708-8240.2009.00307.x>
2. Ziahosseini P, Hussain F, Millar BJ. Management of gingival black triangles. *Br Dent J*. 2014 Nov; 217(10):559-563. <https://doi.org/10.1038/sj.bdj.2014.1004>
3. Tarnow DP, Magner AW, Fletcher P. The effect of the distance from the contact point to the crest of bone on the presence or absence of the interproximal dental papilla. *J Periodontol*. 1992 Dec; 63(12):995-996. <https://doi.org/10.1902/jop.1992.63.12.995>
4. Nordland WP, Tarnow DP. A classification system for loss of papillary height. *J Periodontol*. 1998 Oct; 69(10):1124-1126. <https://doi.org/10.1902/jop.1998.69.10.1124>
5. Clark D. Correction of the "black triangle": restoratively driven papilla regeneration. *Dent Today*. 2009 Feb; 28(2):150, 152, 154-155.

6. Dias de Oliveira J, Mueller Storrer C, Sousa AM, Lopes TR, de Sousa Vieira J, Miranda Deliberador T. Papillary regeneration: anatomical aspects and treatment approaches. *Rev Bras Odontol.* 2012; 9(4):448-456.
7. Dandekar SA, Deshpande NC. Management of Black Triangles: A Literature Review. *Glob J Res Anal.* 2016 Jul; 5(7):107-109.
8. Han TJ, Takei HH. Progress in gingival papilla reconstruction. *Periodontology* 2000. 1996 Jun; 11(1):65-68. <https://doi.org/10.1111/j.1600-0757.1996.tb00184.x>
9. Eming SA, Brachvogel B, Odorisio T, Koch M. Regulation of angiogenesis: wound healing as a model. *Prog Histochem Cytochem.* 2007; 42(3):115-170. <https://doi.org/10.1016/j.proghi.2007.06.001>
10. Choukroun A, Diss A, Simonpieri A, et al. Platelet-rich fibrin (PRF): a second-generation platelet concentrate. Part IV: clinical effects on tissue healing. *Oral Surg Oral Med Oral Pathol Oral Radiol Endod.* 2006 Mar; 101(3): e56-60. <https://doi.org/10.1016/j.tripleo.2005.07.011>
11. Choukroun J, Ghanaati S. Reduction of relative centrifugation force within injectable platelet-rich-fibrin (PRF) concentrates advances patients' own inflammatory cells, platelets and growth factors: the first introduction to the low speed centrifugation concept. *Eur J Trauma Emerg Surg.* 2018 Feb; 44(1):87-95. <https://doi.org/10.1007/s00068-017-0767-9>
12. Kim DH, Je YJ, Kim CD, et al. Can Platelet-rich Plasma be Used for Skin Rejuvenation? Evaluation of Effects of Platelet-rich Plasma on Human Dermal Fibroblast. *Ann Dermatol.* 2011 Nov; 23(4):424-431. <https://doi.org/10.5021/ad.2011.23.4.424>
13. Oswal P, Kour P. Free Gingival Graft Along With I-Prf for Recession Coverage and Interdental Papilla Augmentation: A Case Report. *IOSR JDMS.* 2020; 19(6):22-27. <https://doi.org/10.9790/0853-1906092227>
14. Zatta da Silva T, Margonar R, Silveira Faeda R, et al. Hyaluronic acid for repairing interdental papilla in esthetic area: case report. *Rev Clin Periodontol Implantol Rehabil Oral.* 2019; 12(3):157-158. <https://doi.org/10.4067/S0719-01072019000300157>
15. Michael G. *Burket's Oral Medicine, Twelfth Edition.* USA: PMPH-USA; 2015.
16. Singh S, Vandana KL. Stent as an accessory tool in periodontal measurements: An Insight. *J Indian Soc Periodontol.* 2019; 23(1):81-84. [https://doi.org/10.4103/jisp.jisp\\_331\\_18](https://doi.org/10.4103/jisp.jisp_331_18)
17. Shruthi S, Gujjari SK, Mallya KP. Comparison of two surgical techniques for the reconstruction of interdental papilla. *J Interdiscip Dentistry.* 2015; 5(1):17-22. <https://doi.org/10.4103/2229-5194.162739>
18. Becker W, Gabitov I, Stepanov M, Kois J, Smidt A, Becker BE. Minimally invasive treatment for papillae deficiencies in the esthetic zone: a pilot study. *Clin Implant Dent Relat Res.* 2010 Mar; 12(1):1-8. <https://doi.org/10.1111/j.1708-8208.2009.00247.x>
19. Løe H, Silness J. Periodontal disease in pregnancy. I. Prevalence and severity. *Acta Odontol Scand.* 1963 Dec; 21:533-551. <https://doi.org/10.3109/00016356309011240>
20. Silness J, Løe H. Periodontal disease in pregnancy. II. Correlation between oral hygiene and periodontal condition. *Acta Odontol Scand.* 1964 Feb. 22:121-135. <https://doi.org/10.3109/00016356408993968>



21. Strebel J, Ender A, Paqué F, Krähenmann M, Attin T, Schmidlin PR. In vivo validation of a three-dimensional optical method to document volumetric soft tissue changes of the interdental papilla. *J Periodontol.* 2009 Jan; 80(1):56-61. <https://doi.org/10.1902/jop.2009.080288>
22. Thoma DS, Jung RE, Schneider D, et al. Soft tissue volume augmentation by the use of collagen-based matrices: a volumetric analysis. *J Clin Periodontol.* 2010 Jul; 37(7):659-666. <https://doi.org/10.1111/j.1600-051X.2010.01581.x>
23. Yamada Y, Ueda M, Hibi H, Baba S. A novel approach to periodontal tissue regeneration with mesenchymal stem cells and platelet-rich plasma using tissue engineering technology: A clinical case report. *Int J Periodontics Restorative Dent.* 2006 Aug; 26(4):363-369.
24. Nemcovsky CE. Interproximal papilla augmentation procedure: a novel surgical approach and clinical evaluation of 10 consecutive procedures. *Int J Periodontics Restorative Dent.* 2001 Dec; 21(6):553-559.
25. Carnio J. Surgical reconstruction of interdental papilla using an interposed subepithelial connective tissue graft: a case report. *Int J Periodontics Restorative Dent.* 2004 Feb; 24(1):31-37.
26. Mansouri SS, Ghasemi M, Salmani Z, Shams N. Clinical Application of Hyaluronic Acid Gel for Reconstruction of Interdental Papilla at the Esthetic Zone. *J Islam Dent Assoc Iran.* 2013; 25(3):208-214.
27. Tanwar J, Hungund SA. Hyaluronic acid: Hope of light to black triangles. *J Int Soc Prev Community Dent.* 2016 Sep-Oct; 6(5):497-500. <https://doi.org/10.4103/2231-0762.192948>
28. Miron RJ, Fujioka-Kobayashi M, Hernandez M, et al. Injectable platelet rich fibrin (i-PRF): opportunities in regenerative dentistry? *Clin Oral Investig.* 2017 Nov; 21(8):2619-2627. <https://doi.org/10.1007/s00784-017-2063-9>
29. Kaushik A, Pk P, Jhamb K, et al. Clinical evaluation of papilla reconstruction using subepithelial connective tissue graft. *J Clin Diagn Res.* 2014 Sep; 8(9):ZC77-81. <https://doi.org/10.7860/JCDR/2014/9458.4881>
30. Aspalli S, Nagappa G, Jain AS. Platelet rich fibrin: a panacea for lost interdental papilla. *J Dent Spec.* 2015; 3(2):207-210. <https://doi.org/10.5958/2393-9834.2015.00017.0>
31. Ahila E, Saravana Kumar R, Reddy VK, Pratebha B, Jananni M, Priyadharshini V. Augmentation of Interdental Papilla with Platelet-rich Fibrin. *Contemp Clin Dent.* 2018 Apr-Jun; 9(2):213-217. [https://doi.org/10.4103/ccd.ccd\\_812\\_17](https://doi.org/10.4103/ccd.ccd_812_17)
32. Awartani FA, Tatakis DN. Interdental papilla loss: treatment by hyaluronic acid gel injection: a case series. *Clin Oral Investig.* 2016 Sep; 20(7):1775-1780. <https://doi.org/10.1007/s00784-015-1677-z>

**Conflicts of interest:** The authors declared no conflicts of interest related to this work.

**Corresponding author:**

Professor Mohamed Sherif El-Mofty

Professor, Department of Oral Medicine, Periodontology, Oral Diagnosis, and Radiology

Faculty of Dental Medicine  
Ain Shams University  
Cairo, Egypt

Vice Dean, Community Service and Environmental Development Organization  
Faculty of Dental Medicine  
Nahda University  
Beni Suef, Egypt

E-mail: [mohamed.elmofty@nub.edu.eg](mailto:mohamed.elmofty@nub.edu.eg)

Noncommercial-NoDerivatives 4.0  
International (CC BY-NC-ND 4.0) License.

This is an open access article distributed  
under the Creative Commons Attribution-