

Henry Ford Health

## Henry Ford Health Scholarly Commons

---

Internal Medicine Articles

Internal Medicine

---

6-1-2022

### Diagnosis of acute myeloid leukemia made by skin biopsy

Rita W. Rehana

*Henry Ford Health*, rrehana1@hfhs.org

John C. Moad

Rahim A. Jiwani

Follow this and additional works at: [https://scholarlycommons.henryford.com/internalmedicine\\_articles](https://scholarlycommons.henryford.com/internalmedicine_articles)

---

#### Recommended Citation

Rehana RW, Moad JC, and Jiwani RA. Diagnosis of acute myeloid leukemia made by skin biopsy. *Am J Med Sci* 2022; 363(6):e51-e52.

This Article is brought to you for free and open access by the Internal Medicine at Henry Ford Health Scholarly Commons. It has been accepted for inclusion in Internal Medicine Articles by an authorized administrator of Henry Ford Health Scholarly Commons.

# Diagnosis of acute myeloid leukemia made by skin biopsy



Rita W. Rehana,<sup>1,\*</sup> John C. Moad,<sup>2</sup> and Rahim A. Jiwani<sup>3</sup>

<sup>1</sup> Department of Internal Medicine, Henry Ford Macomb, Clinton Township, MI, USA; <sup>2</sup> Department of Dermatopathology, Dermatopathology Laboratory of Central States (DLCS), Dayton, OH, USA; <sup>3</sup> Department of Internal Medicine, Vidant Medical Center, Greenville, NC, USA

\* (E-mail: [Rrehana1@hfhs.org](mailto:Rrehana1@hfhs.org)).

Conflicts of Interest: None

Source of Funding Statement: No costs or funding was used for this research

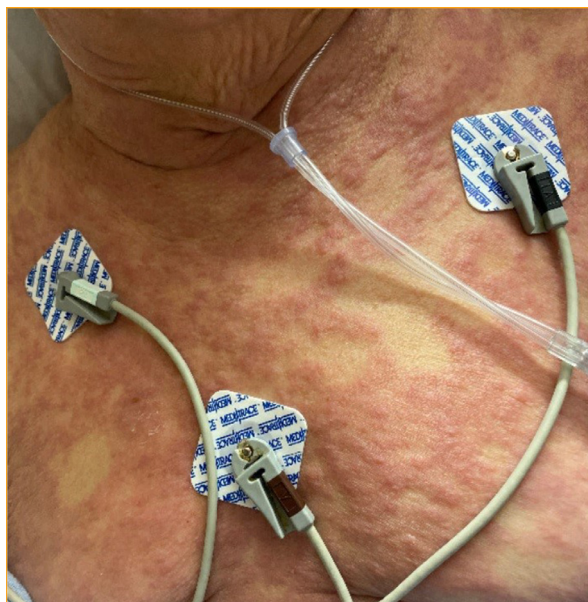

FIGURE 1.

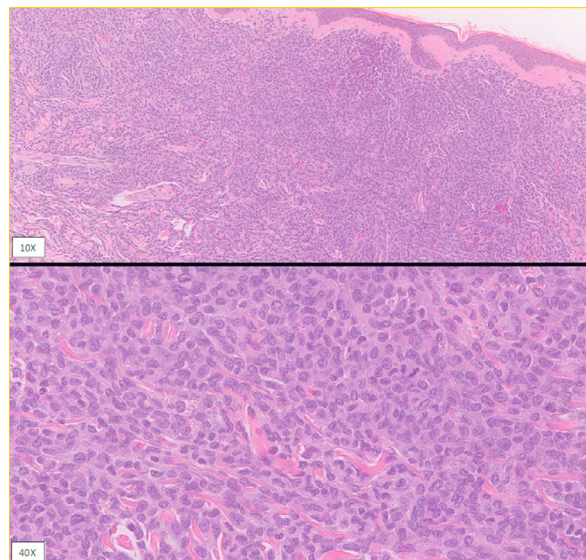


FIGURE 2.

## CASE PRESENTATION

A 79-year-old previously healthy woman presented to her primary care physician with an 8-week history of non-pruritic, erythematous macules coalescing into patches on the trunk and extremities (Fig. 1). Rash was not improving with steroid cream. She described chills but no other B-symptoms. Further evaluation by a punch biopsy showed dermal infiltrate of atypical hematolymphoid cells (Fig. 2). Immunohistochemical studies performed demonstrated that the cells of interest are positive for CD33, CD4, CD56, CD123 and lysozyme. The morphologic and immunophenotypic findings of the cutaneous lesions were consistent with myeloid sarcoma, which can be a rare initial presentation of acute myeloid leukemia (AML). The patient was directed to a hospital for further evaluation for a hematologic malignancy. Upon arrival, the patient had stable vital signs and a diffuse, non-tender, non-pruritic, maculopapular rash noted on the anterior chest, extending towards the neck and across the abdominal region. Admission labs were significant for leukocytosis and acute kidney injury garnering the patient high risk for tumor lysis syndrome.

She was given one dose of rasburicase and started on allopurinol. Peripheral blood smear showed left shifted granulocytic maturation and dysplasia and up to 17% blasts. Bone marrow biopsy revealed up to 78% blasts consistent with AML. She was started on decitabine and venetoclax. The patient was eventually discharged on prophylactic medication and followed up with her hematologist. Despite close follow up, the patient decompensated a few months after initial therapy and unfortunately died.

This is a rare case of AML diagnosed by skin biopsy. Myeloid sarcoma is a rare isolated extramedullary leukemic tumor and should prompt cytogenetic analysis for prognostication and targeted treatment. Myeloid sarcoma can present in four different ways: de novo in the absence of myelodysplasia, concurrently with AML, representation of blast crisis or blast transformation in myeloproliferative disorder and relapse of AML.<sup>1</sup> The prevalence of myeloid sarcoma is reported in 2–8% of patients with AML.<sup>2</sup> It is often misdiagnosed for lymphoma, undifferentiated cancers and malignant melanoma. The use of immunohistochemistry and

immunophenotyping are crucial for accurate diagnosis of myeloid sarcoma.<sup>2</sup> The presentation of myeloid sarcoma is variable and independent of age ranging from infants to elderly. It manifests in 15–35% of AML cases at the time of diagnosis.<sup>1</sup> It occurs after the diagnosis of AML in up to 50% of cases.<sup>1</sup> Additionally, it can appear as the initial finding of relapsed AML.<sup>1</sup> Regarding prognosis, literature reports that patients with myeloid sarcoma due to AML have worse outcomes than de novo myeloid sarcoma.<sup>2,3</sup> Treatment for myeloid sarcoma is indistinguishable to

AML with induction chemotherapy, usually a combination of an anthracycline and cytarabine.<sup>3</sup>

## REFERENCES

1. **Avni B, Koren-michowitz M.** Myeloid sarcoma: current approach and therapeutic options. *Ther Adv Hematol.* 2011;2(5):309–316.
2. **Alexiev BA, Wang W, Ning Y, et al.** Myeloid sarcomas: a histologic, immunohistochemical, and cytogenetic study. *Diagn Pathol.* 2007;2:42.
3. **Menasce LP, Banerjee SS, Beckett E, Harris M.** Extra-medullary myeloid tumour (granulocytic sarcoma) is often misdiagnosed: a study of 26 cases. *Histopathology.* 1999;34(5):391–398.