


JOURNAL OF THE ASSOCIATION OF RADIOGRAPHERS OF NIGERIA

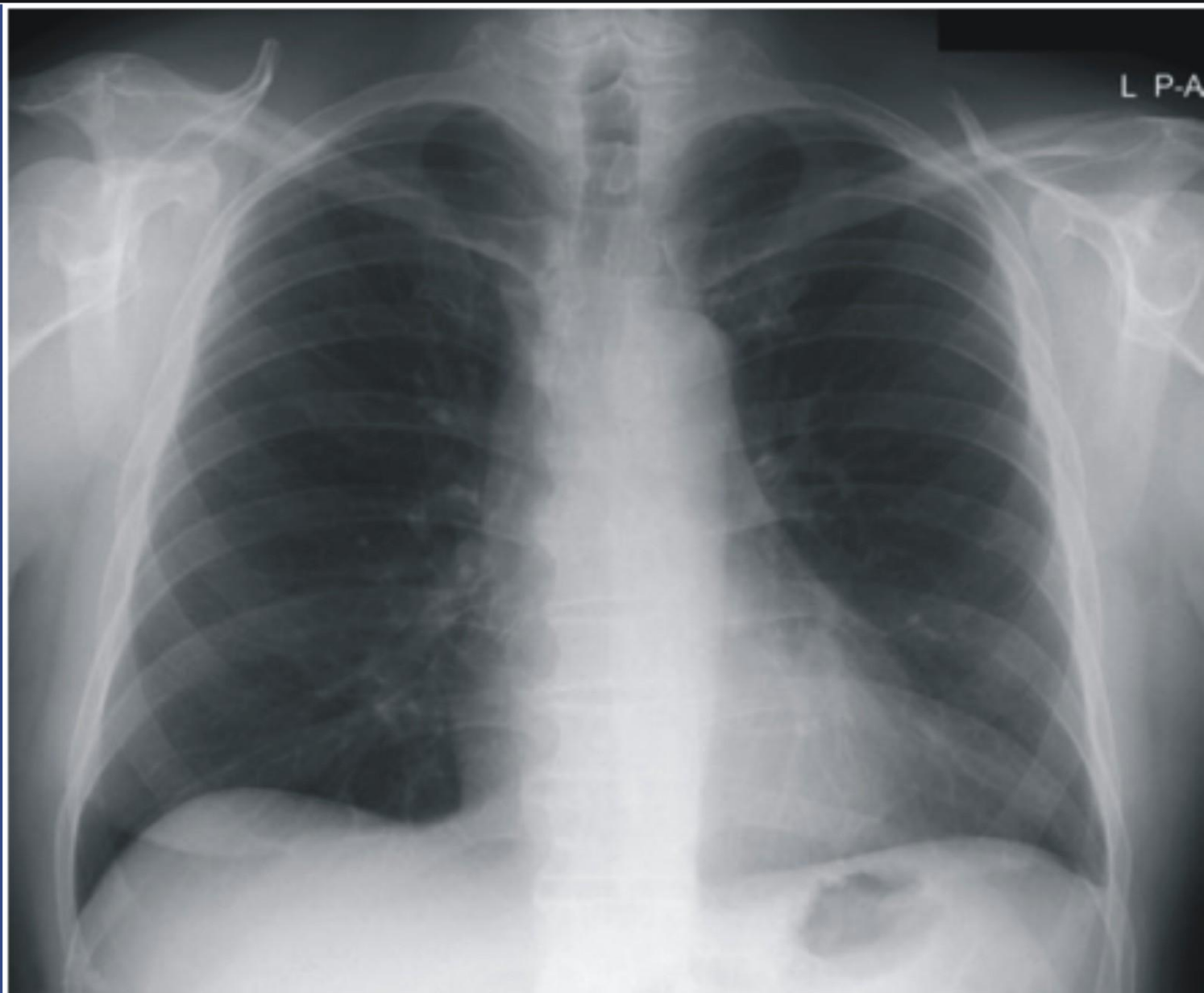


ISSN: 1115- 7976

Vol 30, Issue 1, December, 2016

The Official Journal of The Association of Radiographers of Nigeria

J
A
R
N



Journal homepage: www.jarnxray.org

Correlation between gender and the antero-posterior diameter of normal pancreatic head

Esop Jacob Esop, *Samson Omini Paulinus, Inyene Edem Sampson

Department of Radiography & Radiological Science, College of Medical Sciences, University of Calabar, Nigeria.

*Correspondence: E-mail: esopjavy@gmail.com; +2349052876663

Receive: 6 January, 2015. Received in revised form: 15 March, 2016. Accepted: 12 April, 2016

ABSTRACT

Background: Pancreatic carcinoma involving the head, accounts for most cases of extra hepatic obstruction of the hepato-biliary system and usually go undetected in its early stage. Also, reports show that gender is an independent risk factor for severity of gastrointestinal and non-gastrointestinal diseases and many of these diseases including cases of pancreatic carcinoma, show a gender bias, hence the rationale for the study.

Objective: To assess the relationship between the Antero-Posterior (AP) diameter of the pancreatic head and gender using Contrast Enhanced Computed Tomography (CECT) scan.

Methods: Eighty (80) apparently normal computed tomography (CT) scan images of 41(51.25 %) male and 39 (48.75 %) female subjects were retrospectively, and prospectively, evaluated with their ages which ranged from 19 to 70 years, obtained from Image Diagnostics and the Georges Diagnostic Centres, both in Port-Harcourt, Rivers State, Nigeria for a period of eight months (January - August, 2016).

Results: The mean AP diameter of the pancreatic head in the study population was found to be 2.6 ± 0.3 cm. This result was however, smaller in the males (2.60 ± 0.3 cm) compared to the females (2.70 ± 0.3 cm) in the study population. A weak negative correlation ($r = -0.327$) was observed between pancreatic head AP diameter and gender ($p < 0.05$).

Conclusion: Results obtained from the present study showed no significant relationship between the AP diameter of the pancreatic head and gender in the study population.

Keywords: Pancreatic head, contrast enhanced computed tomography (CECT), gender, Nigerian population.

Introduction

The human pancreas is an elongated, accessory digestive gland which lies retroperitoneally and transversely across the posterior abdominal wall, posterior to the stomach between the duodenum on the right and the spleen on the left. For descriptive purpose, it is divided into four parts namely; the head, the neck, the body and the tail [1]. A normal adult pancreas measures about 15-20cm long, 2.5-3.8cm broad and 1.2-1.8cm thick and weighs about 90g [2]. The pancreas receives its blood supply from the pancreatic branches of the splenic artery, the superior pancreaticoduodenal artery and the inferior pancreaticoduodenal artery.

Like the duodenum developmentally, the pancreas develops at the junction of the foregut and the midgut, supplied by branches from the coeliac and the superior mesenteric arteries [2].

This accessory digestive gland is drained by the splenic, superior mesenteric and portal veins. Its lymphatics follow the arteries and drain into the pancreatico-splenic, coeliac and the superior mesenteric groups of lymph nodes [2].

The pancreas is divided from right to left into head, neck, body and the tail. The head is enlarged and lies within the concavity of the duodenum. The tail reaches the hilum of the spleen [2]. The head of the pancreas is the expanded part of the gland embraced by the C-shaped curve of the duodenum to the right of the superior mesenteric vessels [1]. The head firmly attaches to the medial aspect of the descending and horizontal parts of the duodenum. The uncinate process (a projection from the inferior part of the head) extends medially to the left, posterior to the superior mesenteric artery.

The head of pancreas rests posteriorly to the inferior vena cava, right renal artery and left renal vein [2].

The predominant medical imaging modalities used for the diagnosis of pancreatic diseases include computed tomography (CT), magnetic resonance imaging (MRI), endoscopic retrograde cholangio-pancreatography (ERCP) and endoscopic ultrasound (EUS). Currently, there have been advancements and refinements in all these techniques resulting in an improved imaging of the pancreas which find wide application in the detection and staging of pancreatic cancer, differentiation between cancer and focal pancreatitis, the characterization of cystic lesions and the search for neuro-endocrine tumours [3].

Studies have shown that gender is an independent risk factor for severity of gastrointestinal and non-gastrointestinal diseases and many of these diseases including cases of pancreatic carcinoma (which mostly occurs at the pancreatic head) show a gender bias [4,5]. This research sought to ascertain the relationship between antero-posterior diameter (APD) of the normal pancreatic head with gender, using the contrast enhanced computed tomography (CECT) scan images of 80 sampled subjects in Port-Harcourt, Nigeria.

Material and Methods

A total of 80 apparently normal abdominal and abdomino-pelvic CECT scanned images of 41 males (51.25 %) and 39 females (49.75 %) with ages ranging from 19 years to 70 years, were obtained from a lightspeed 2-slice General Electric (GE) CT scanner.

Images obtained were reviewed with the segments of the pancreas noted with the anatomically related organs and vessels identified as described in literature of human anatomy [1, 2]. The Anterior-posterior diameter of the pancreas was measured with electronic calipers using the widest diameter between two points A and B as shown in Plate 1 with the aid of distance and ellipsoid tools of the DICOM viewer. The results were carefully recorded, grouped and analyzed using students t-test and the Pearson correlation co-efficient at level of significance of $p < 0.05$.

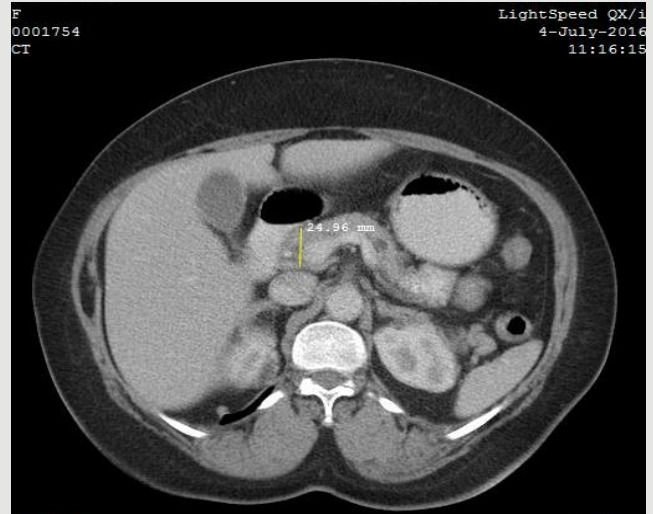


Plate 1: Axial CT Image of the abdomen of an adult female demonstrating the AP measurement of the pancreatic head

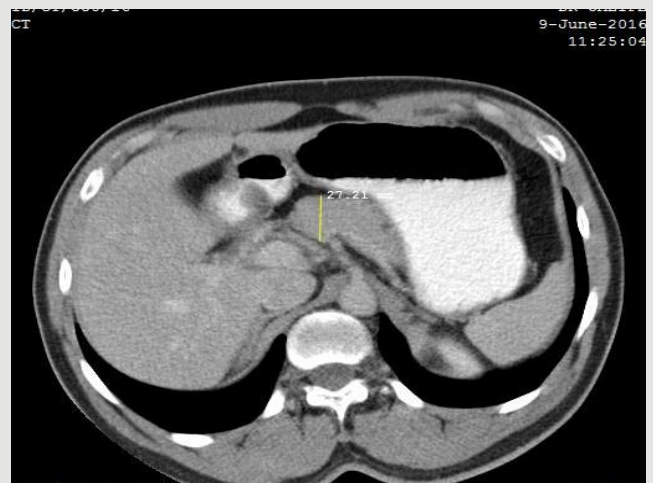


Plate 2: Axial CT Image of the abdomen of an adult male demonstrating the AP measurement of the head of pancreas

Results

The centres used the following user-selected technical specifications; maximum kiloVoltage (140 kV), maximum milliAmperage (160 mA), slice thickness (5 mm), and an 8-slice GE light speed ultra QXCT scanner with the following specifications; maximum kiloVoltage (140 kV), maximum milliAmperage (350 mA). However, the same standard scan protocol was used for both scanners as shown in Table 1.

Of the 80 subjects, 41(51.25 %) were males and 39(48.75 %) were females. Gender distribution was grouped in intervals as follows: 1(1.25 %)

was between 11-19 years; 6 (7.50 %) were between 20-29 years; 12 (15.00%) were between 30-39 years; 19 (23.75%) were between 40-49 years; 23 (28.75%) were between 50-59 years; 9 (11.25%) were between 60-69 years; and 10 (12.50%) were 70 years and above (Table 2). The mean and standard deviation for the 41 male subjects was found to be 2.6 ± 0.3 cm and the minimum and maximum values of the AP diameter recorded were 1.9 cm and 3.3 cm, respectively. While for the 39 female subjects studied, the mean and standard deviation was 2.7 ± 0.3 cm, the minimum and maximum values were 2.0cm and 3.6cm respectively. The result of the Pearson correlation between the AP diameter and gender showed a weak negative correlation, $r = -0.327$ (Table 3).

Discussion

The study evaluated the Anterior-Posterior (AP) diameter of the pancreatic head in a Nigerian population using the CECT scan images obtained from 80 subjects referred for abdominal and abdomino-pelvic CT investigation at the Radiology Departments of the aforementioned diagnostic centres from January - August 2016.

Table 1: Scan Protocol for CECT Abdomen

Parameter	Measurement
Slice thickness	5mm
Pitch	1.375:1
Speed (mm/rotation)	39.37mm
KiloVoltage	120kV
mAs per slice	225mAs
Algorithm	Standard
Scan type	Helical
Tomogram direction	Craniocaudal
Window width	150/100/80
Window level	30
Volume of contrast	<75kg : 100cc 75-90kg : 120cc >90kg : 150cc
Type of contrast	Omnipaque 350
Injection rate	5cc/sec through a 18 gauge IV Catheter

Table 2: Demographic data of subjects (n = 80)

Variable	Frequency	%
Gender		
Male	41	51.25
Female	39	48.75
Total	80	100
Age range		
11-19years	1	1.25
20-29years	6	7.50
30-39years	12	15.00
40-49years	19	23.75
50-59years	23	28.75
60-69years	9	11.25
>70years	10	12.50
Total	80	100

The result of the study showed that the mean AP diameter of the pancreatic head was found to be 2.6 ± 0.3 cm, which agrees with a similar work done amongst Sudanese population [6]. Also, the mean AP diameter of the head of pancreas of the male subjects (2.60 ± 0.3 cm) was observed to be smaller when compared to the female subjects (2.70 ± 0.3 cm) in our study population.

This findings however, contradicts a similar work which evaluated quantitatively, the normal pancreatic size and volume and found them to be smaller in females than in males in the United States of America [7]. This difference could probably be attributed to racial, dietary or a combination of both. On the relationship between the AP diameter of the pancreatic head and gender, our result showed a weak negative correlation ($r = -0.327$) between pancreatic head AP diameter and the gender of the subject ($p < 0.05$) implying that there was no significant relationship between the AP diameter of the head of the pancreas with gender.

Conclusion

Results obtained from the present study showed no significant relationship between the AP diameter of the pancreatic head and gender in the study population.

Table 3: Independent samples test (t-test) and Pearson between normal pancreatic head APD diameter and gender

Gender	n	Mean (cm)	Min	Max	t_{crit} value	p-value	r-value
Male	41	2.6 ± 1.9	3.3	4.157	6.729	0.175	-0.327
Female	39	2.7 ± 2.0	3.6				

Conflict of interest: None declared

References

[1]. Moore K & Dalley A. Clinically Oriented Anatomy. (4th edition). Baltimore United States of America (USA).Lippincott Williams & Wilkins 1999; 257-261.

[2]. Chaurasia B. Human Anatomy, volume 2 (5th edition). CBS publishers and distributors. New Dehli 2010; 305-309.

[3]. Schima W. MRI of the pancreas: tumours and tumour-stimulating process.US National Library of Medicine 2006; 6(1): 199-203.

[4]. Pancreatic cancer symptoms 2015. www. webmed.com/cancer/pancreatic-cancer-symptoms.Accessed 1/10/16.

[5]. Lankisch P, Assmus C, Lehnick D, Maisonneuve P. &Lowenfels A. Acute pancreatitis; does gender matter? Digestive Diseases & Sciences 2001; 46 (11): 2470-2474.

[6]. Omer H. Characterization of pancreas in Sudanese population using computerized tomography. Sudan university of Science and Technology, College of Graduate Studies & Research,2015.http://repository. sustech.edu/handle/accessed 1/10/16.

[7]. Syed A, Mahal R, Schumm L. &Dachman A. Pancreas size and volume on computed tomography in normal adults. Department of Health Studies. United States of America 2012; 41(4): 589-95.

How to cite: Esop Jacob Esop, Samson Omini Paulinus, Inyene Edem Sampson. Correlation Between Gender and the Antero-Posterior Diameter of Normal Pancreatic Head. J Assoc Rad Niger, 2016; 30 (1): 8 – 11.