

The Prognostic Value of CD133 in Ovarian Surface Epithelial Tumors

Fatma El-Zahraa Salah El-Deen Yassin^{1*}, Sarah R. Dawood Mejalaa², Afaf Taha Ebrahim El Nashar¹

¹Department of Pathology, Faculty of Medicine, Sohag University, Sohag, Egypt

²Department of Pathology, Sohag Oncology Center, Sohag, Egypt

*Corresponding author: Fatma El-Zahraa Salah El-Deen Yassin, Mobile: (+20)01007970144,

Email: fatmaf2002@yahoo.com

ABSTRACT

Background: Ovarian cancer, the fifth leading cause of cancer-related death in women, is a highly lethal disease among all gynecologic malignancies. Stem cells (SCs) are undifferentiated cells destined to replenish the pool of mature cells whenever needed. In recent years, accumulating data demonstrate that a small subset of cells exists within a tumor, termed cancer stem cells (CSC), responsible for cancer development and recurrence. CD133 is considered a CSC marker in several non-ovarian cancers including cancers of the colon, the lung, and the brain.

Objective: To evaluate the expression of the stem cells marker CD133 in surface epithelial tumors of the ovary and its correlation with clinic-pathological parameters.

Patients and methods: 60 cases, divided into 39 cases of serous tumors, 12 cases of mucinous tumors, 6 cases of endometrioid carcinoma and 3 Brenner tumors from 2018 to 2020, were stained for CD133 antibodies by immunohistochemistry. All clinical data were obtained from patients reports.

Results: CD133 expression was found in 84.62% of ovarian epithelial cancer and in 37.5% of borderline tumors. CD133 expression showed a significant correlation with histopathological subtypes: high-grade serous carcinoma and mucinous tumors ($P=0.001$). Evaluation of CD133 in relation to other histopathological parameters: CD133 showed significant correlation with presence of psammoma bodies, and presence of necrosis ($P= 0.049$, and 0.005) respectively. Also, statistical evaluation of CD133 expression according to presence of lymphovascular emboli, peritoneal nodules, and infiltration to other organs showed high significance with ($P= 0.001$) similarly to all.

Conclusion: CD133 expression could be a predictor of poor clinical outcome for patients with ovarian surface epithelial tumors as its expression was associated with high-grade serous carcinoma, necrosis, lympho-vascular emboli and peritoneal nodules.

Keywords: Stem cell, Ovarian cancer, CD133.

INTRODUCTION

Ovarian cancer is a heterogeneous disease composed of different types of tumors. Malignant epithelial tumors are the most common ovarian cancers and the most lethal gynecological malignancies. Cancer stem cells (CSCs) have been isolated from several malignant tumors including leukemia, breast, brain, and colon cancers. Furthermore, studies in different organs have shown that CSCs are more resistant than non-CSCs to conventional cytotoxic treatment. In early stage of ovarian cancer, the number of epithelial ovarian cancer (EOC) stem cells can be used to predict the progression of the disease^[1].

Cancer stem cells or tumor-initiating cells (CSC/TICs), which can undergo self-renewal and differentiation, are thought to play critical roles in tumorigenesis, therapy resistance, tumor recurrence, and metastasis. Tumor recurrence and chemoresistance are major causes of poor survival rates of ovarian cancer patients, which may be due in part to the existence of CSC/TIC^[2].

CD133, also known as prominin or AC133, is a marker frequently found on multipotent progenitor cells, including immature hematopoietic stem and progenitor cells. The protein has been extensively used

as a stem cell marker for normal and cancerous tissues^[3].

CD 133 positive tumor cells of ovarian cancer displayed a greater resistance to chemotherapy. In addition and they have hyperactivity in migration and invasion due to activation of chemokines (c-c motif) ligand 5 (CCL5)^[4].

Aim of the work to evaluate the expression of the stem cells marker CD133 in surface epithelial tumors of the ovary and its correlation with clinic-pathological parameters.

PATIENTS AND METHODS

60 specimens were obtained from Pathology Department, Sohag University Hospital and Sohag Oncology Center at the period from 2018 to 2020. All specimens were formalin- fixed and paraffin-embedded. H&E stained sections were examined, diagnosed and graded according to the FIGO Committee on Gynecologic Oncology^[5].

Inclusion criteria: Patients who had undergone total hysterectomy, subtotal hysterectomy and adnexectomy specimens.



This article is an open access article distributed under the terms and conditions of the Creative Commons Attribution (CC BY-SA) license (<http://creativecommons.org/licenses/by/4.0/>)

Exclusion criteria: Patient received preoperative chemotherapy or radiotherapy with insufficient clinical data

Immunohistochemical staining (IHC):

We used Rabbit CD133/Prominin-1(PROM1) [MD49R]: RM0202, RM0202RTU7 and labeled streptavidin–biotin immunoenzymatic antigen detection kit (Universal Staining Kit) (Cat # TP-015-HD, LABVISION Corporation, Fremont, USA). It contains Hydrogen peroxide block, Biotinylated goat anti-polyvalent, Streptavidine peroxidase, diaminobenzidine (DAB) chromogen, DAB substrate. We used mouse monoclonal Rabbit Anti-CD133 antibody at a dilution of 1/25. Positive controls (normal kidney) were used.

Immunohistochemical scoring:

Staining degree was scored, and the staining pattern—membrane and/or cytoplasmic reactivity of the cells—was noted. The immunostaining scores criteria were defined as the cell staining intensity (0 = nil; 1 = weak; 2 = moderate; and 3 = strong) multiplied by the percentage of stained cells (0–100%), resulting in scores from 0 to 300. A score, higher than the mean score was defined as ‘high’ immunostaining, while a score equal to or lower than the mean score was categorized as ‘low’ in tumor^[6].

Statistical Analysis

Results were statistically analyzed using Statistical Package for Social Sciences 16 (SPSS 16) for windows, Chi-Square and T test were used to evaluate Statistical significance of various parameters with p value less than 0.05 was considered statistically significant.

RESULTS

This study included 60 specimens. Their age range was 24-85 years, and the median age was 52.50 years. The mean ± SD for patient's age was 52.32 ± 11.565. Twenty-one out of sixty cases (35%) were bilateral whereas 39/60 (65%) cases were unilateral. Regarding tumor size, the largest case size was 40 cm, the smallest case size was 3 cm, and the median size was 9 cm. The mean ± SD for tumor size was 11.008 ± 8.0362.

The representative H&E stained sections of the collected 60 specimens of ovarian cancer were evaluated and were graded according to the WHO classification ^[7] into the following histological types: Serous tumor (16 low, 18 high and 5 borderline), Mucinous tumor (5 low, 4 high and 3 borderline), Endometrioid (6) and Brenner tumor (3 low versus 6 high).

Immunohistochemical features:

CD133 was expressed in 47/60 cases and negative in 13/60 cases. Combined cytoplasmic and membranous expression was noted in 13 cases: seven cases serous adenocarcinoma (Figure 1), 3 cases mucinous adenocarcinoma, 2 cases other types (endometrioid, and Brenner) adenocarcinoma (Figure 4), and one case borderline tumor (Table 1).

Cytoplasmic staining was detected in 14 cases: 12 were serous adenocarcinoma (Figure 1&2) and two were mucinous adenocarcinoma (Figure 3). The membranous expression with apical accentuation was observed in 20 cases: Serous adenocarcinoma (11), mucinous adenocarcinoma (5), borderline tumors (2) and others (2).

The immunostaining scores range from 0 to 270. A score higher than mean score 122.08 was defined as ‘high’ immunostaining, while a score equal to/ or lower than mean score was categorized as ‘low’ in tumor.

High immunostaining score was detected in 9/18 high-grade serous carcinoma cases and in 6/16 of low grade serous carcinoma (Figure 1&2). All mucinous tumors scores (borderline and malignant) were high while 3/6 of endometrioid carcinoma was high (Figure 3). The low scores were noticed in malignant Brenner tumor while negative expression was seen in all borderline serous tumors

As regard the correlation between CD133 expression and different histopathological parameters: CD133 showed significant correlation with presence of psammoma bodies, and presence of necrosis (P= 0.049, and 0.005) respectively. Also, statistical evaluation of CD133 expression according to presence of lymphovascular emboli, peritoneal nodules, and infiltration to other organs showed high significance with (P= 0.001) similarly to all (Table 2).

Table (1): Expression of CD133 in various histopathological types of ovarian surface epithelial tumors.

Histological type	No=60	CD133 expression			P value
		-ve	+ve		
			Low	High	
High grade serous ca.	18	0	9	9	0.001 (HS)
Low grade serous ca.	16	4	6	6	
Mucinous ca.	9	0	0	9	
Other types	9	4	2	3	
Borderline tumors	8	5	0	3	

Table (2): The correlation between CD133 expression and other histopathological parameters.

Parameter	No=60	CD133 expression			P value
		-ve	+ve		
			High	Low	
-Psammoma bodies					
Present	11	0	7	4	0.049 (S)
Absent	49	13	23	13	
-Necrosis					
Present	19	1	15	3	0.005 (S)
Absent	41	12	15	14	
-LV emboli					
Present	16	0	14	2	0.001 (HS)
Absent	44	13	16	15	
- Peritoneal nodules					
Present	13	0	13	0	0.001 (HS)
Absent	47	13	17	17	
- Infiltrate of other organs					
Present	15	0	15	0	0.001 (HS)
Absent	45	13	15	17	

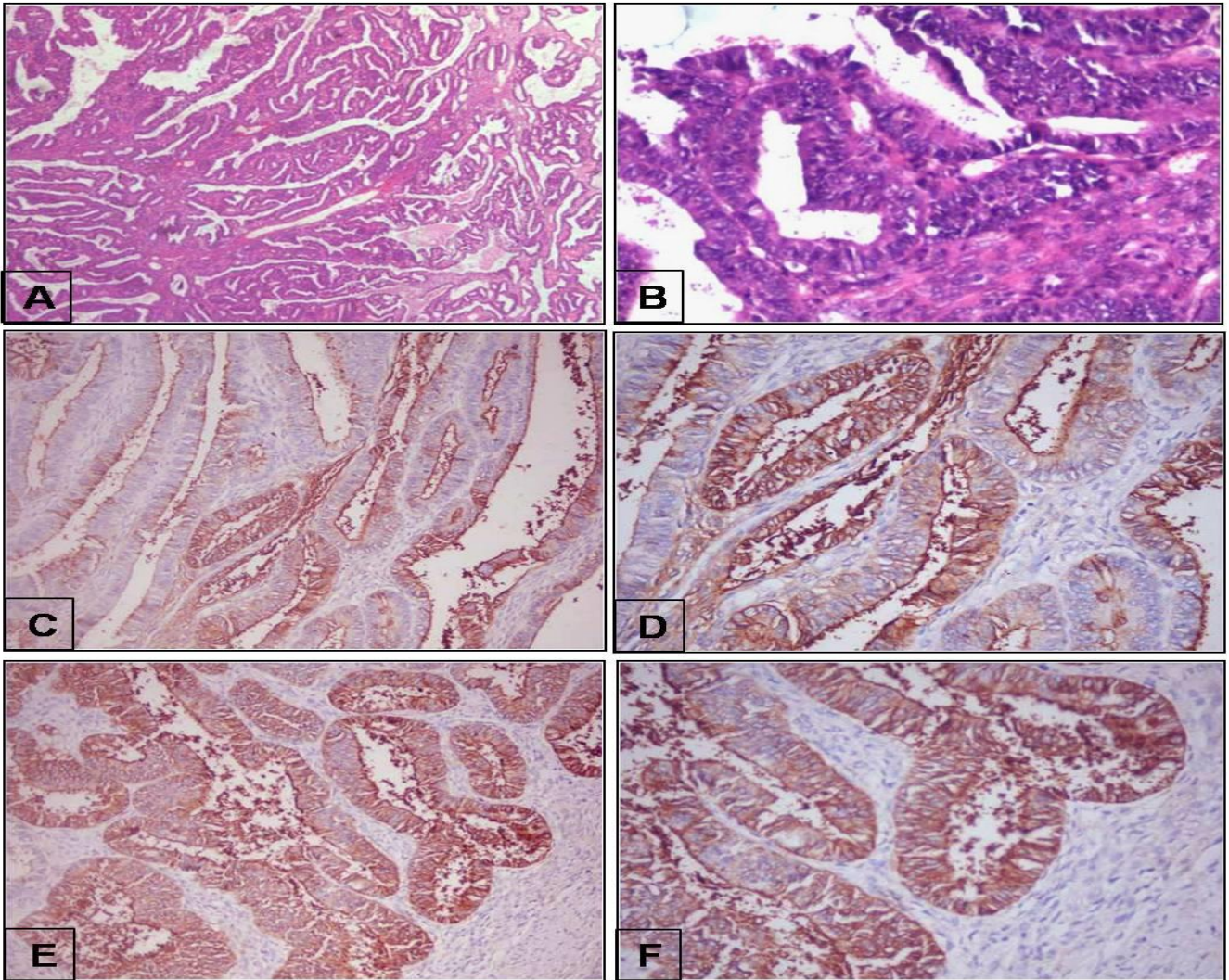


Figure (1): A-B): High grade serous carcinoma of the ovary. C-D): Strong membranous expression of CD133 in the same case. E-F): Another case of high grade serous carcinoma showed combined pattern of CD133 expression (cytoplasmic with membranous accentuation). (HE;x40,200, CD133;x200,400,200,400. Original).

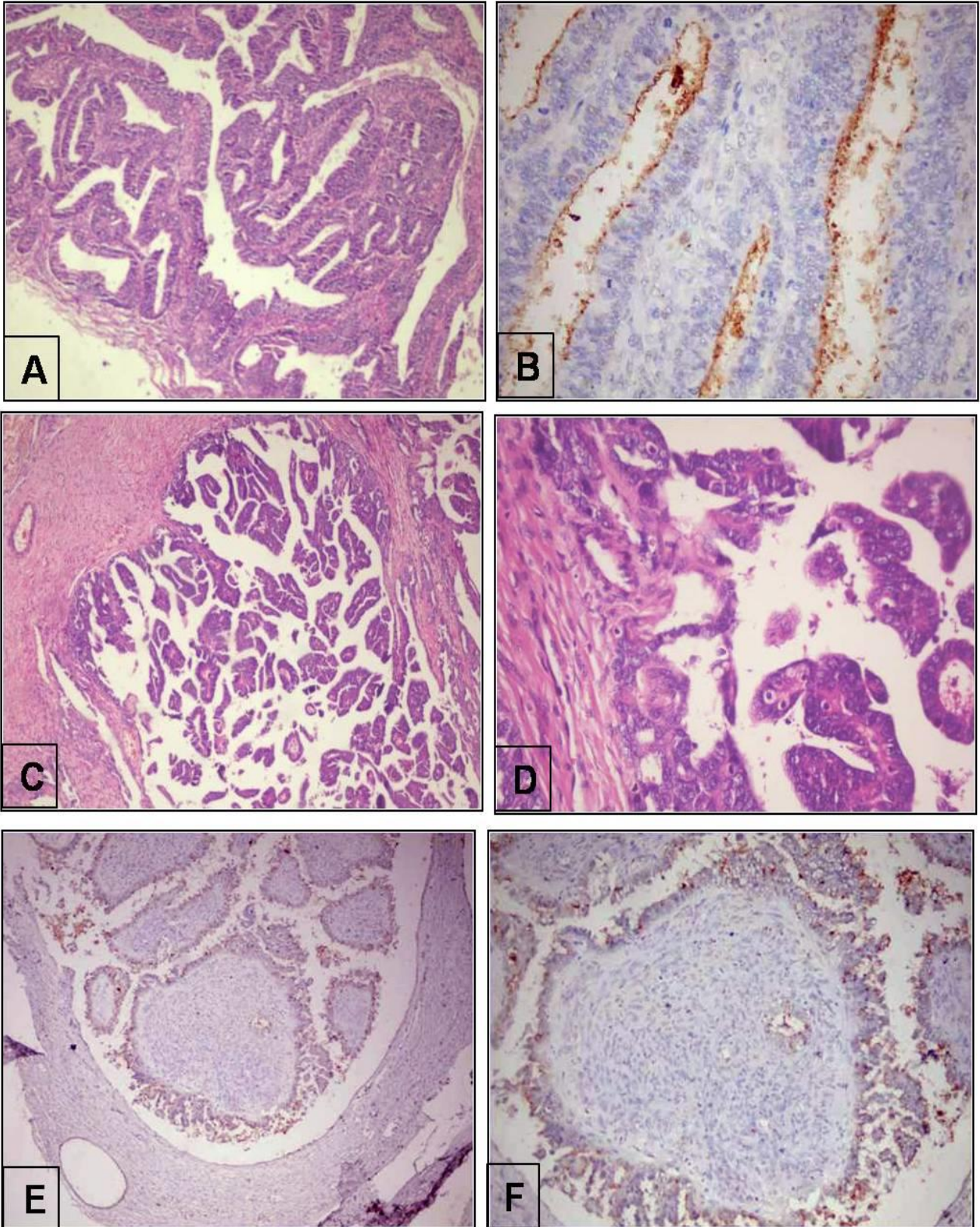


Figure (2): A-B): Low grade serous carcinoma of the ovary with moderate apical membranous expression of CD133. (HE;x100,CD133;x400. Original). C-D): Borderline serous tumor of the ovary. E-F): Weak apical membranous expression of CD133 in borderline serous tumor (HE;x100,400, CD133; x100,200. Original).

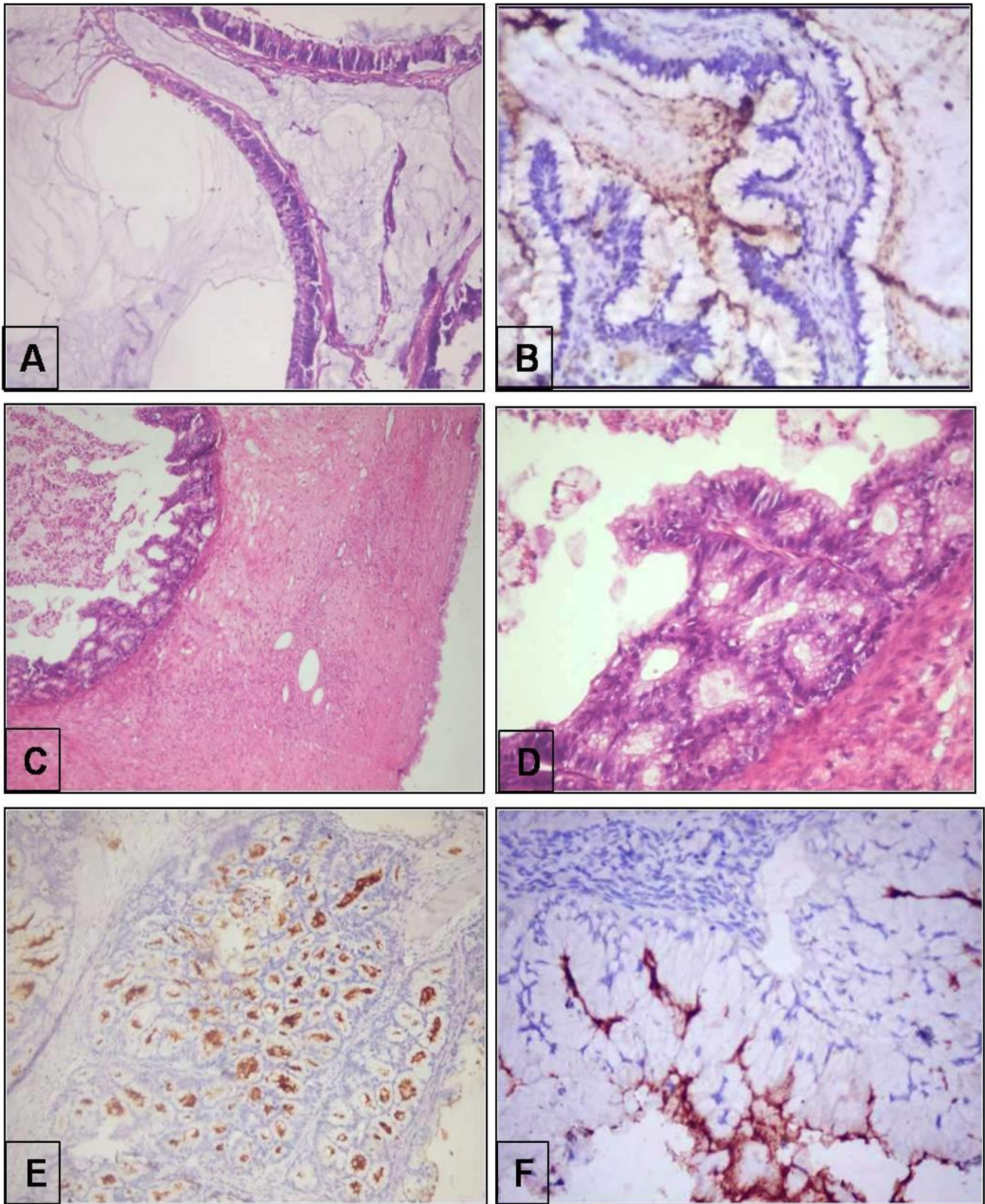


Figure (3): A-B): Mucinous carcinoma of the ovary with moderate apical membranous expression of CD133 (HE;x200. CD133;x400. Original). C-D): Borderline mucinous tumor of the ovary. E-F): Strong apical membranous expression of CD133 in borderline mucinous tumors (HE;x100,400. CD133;x200,x400. Original).

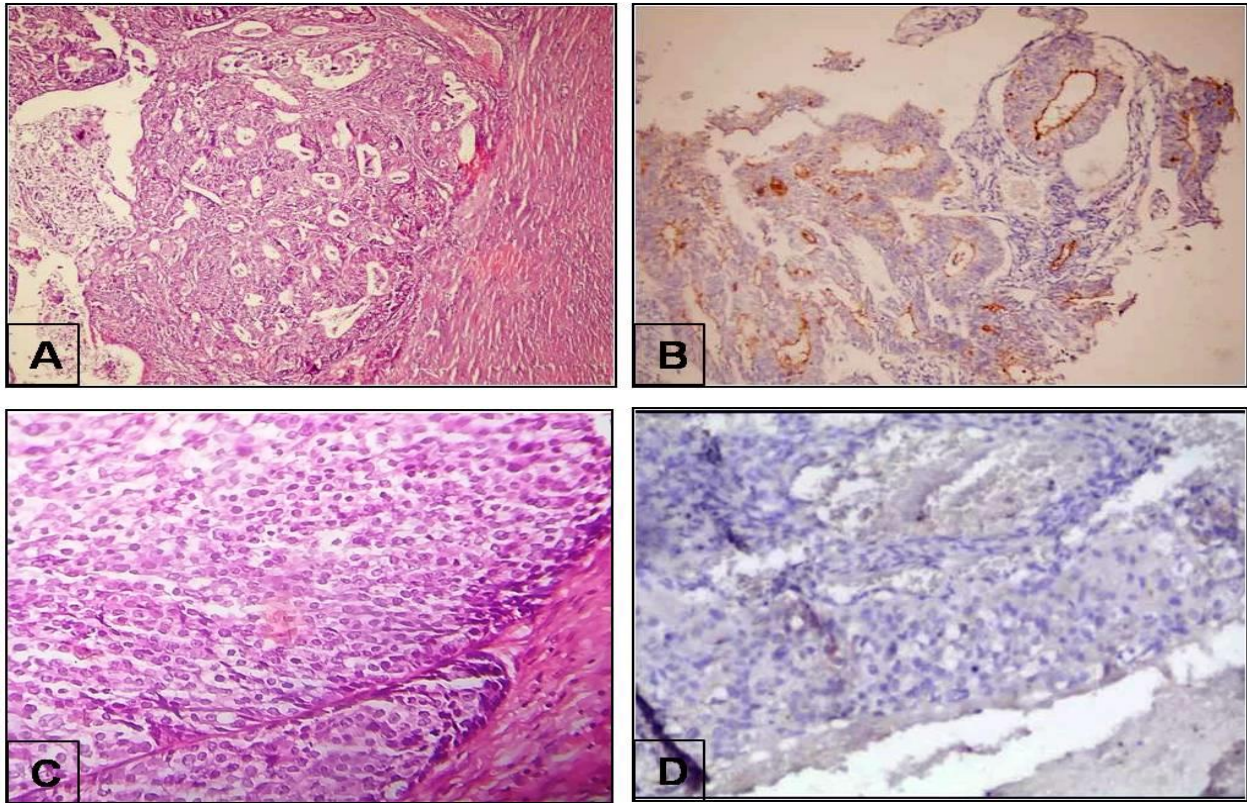


Figure (4): A-B Endometrioid carcinoma with moderate apical membranous expression (HE;x200. CD133; x100. Original).C-D Malignant Brenner tumor with areas of necrosis (not shown) showed negative CD133 expression (HE;x200.CD133;x 200. Original).

DISCUSSION

We aimed to evaluate the expression of the stem cell marker CD133 in surface epithelial ovarian tumors and correlate its expression with histopathological parameters. The current study included 8/60 (13.33%) cases of borderline tumors, 57/60 (95%) cases of malignant tumors. Sixty-five percent of cases were serous adenocarcinoma, 20% were mucinous adenocarcinoma, 10% were endometrioid adenocarcinoma and only 5% were malignant Brenner tumor. Serous adenocarcinoma was graded into low (16/34) and high (18/34).

Several studies^[8, 9] have demonstrated that CD133 expression may serve as a promising biomarker in the prognosis of colorectal, gastric cancers and non-small cell lung cancer.

One of the first researchers; **Curley et al.**^[10] mentioned that ovarian cancer contains CD133 expressing cells, which is essential for tumor cell propagation and metastasis.

Moreover, several studies^[11, 12] reported that CD133 expression was positively associated with poor prognosis. While other investigators^[13] demonstrated that negatively expressed CD133 cells can show the same characteristics of positively expressed ones.

Ricci and his colleagues^[12] reported that ovarian cancer patients whose tumor tissue overexpressed a CSC marker, their response to clinical treatment, recurrence rate, or overall survival was not always worse than the negative ones.

In this study, CD133 was expressed in 47 cases (78.3%) of all 60 studied cases. CD133 was expressed in 12 (75%) cases of low-grade serous adenocarcinoma, all 9 cases (100%) of mucinous adenocarcinoma, and 5 (62.5%) cases of other types of adenocarcinomas. Furthermore, CD133 was expressed in all 18 (100%) cases of high-grade serous adenocarcinoma and 3 out of 8 (37.5%) cases of borderline tumors which were of mucinous type. In a study of **Štemberger-Papić et al.**^[14], CD133 positivity was seen in the 61% of tumors which is lower than our percentage.

In this study, Immunostaining score of high-grade serous carcinoma was high in 9 cases out of 18 cases, in low-grade serous carcinoma was high in 6 cases out of 16 cases, high in all mucinous tumors (borderline, and malignant), was high in endometrioid carcinoma 3 out of 6 cases, was negative in all borderline serous tumors, and was low in malignant Brenner tumor.

Zhang et al.^[11] reported positive expression of CD133 in 123 (31%) of 400 ovarian carcinoma tissues. Among these 123 cases, the CD133-positive distributions were sparse and scattered in 31%, focal in 24%, and diffuse in 45%.

Although CD133 has been reported to be a cell surface marker^[15], in their samples a membrane staining pattern was evident in only 16% (20/123) of CD133-positive cases. More frequently, CD133-positive cells showed moderate-to-strong, dense, brownish cytoplasmic staining (84% (103/123) of CD133-positive cases). CD133 immunoreactivity was

also found in the cytoplasm of stromal fibroblasts as mentioned by **Zhang et al.**^[11] as they used primary rabbit polyclonal antibody against CD133.

In the current study, there was a high significant difference ($p < 0.001$) between CD133 positive and negative patients regarding peritoneal nodules, infiltrate other organs, lymphovascular emboli, and significant difference between them regarding necrosis and psammoma bodies ($p = 0.005, 0.049$ respectively).

This was similar to results obtained by **Zhou and his colleagues**^[16], they performed a meta-analysis to identify the association between CD133 and clinicopathological outcomes. They clarified that positive CD133 expression was significantly associated with tumor stage, although CD133 expression was not associated with the patients' age, response to clinical treatment.

Results of Tao et al.^[17] indicate that positive CD133 expression can effectively predict several clinicopathological features and poor outcomes in patients with ovarian cancer.

Ferrandina et al.^[18] was the first to identify CD133 expression in human ovarian cancer tissue. In a study of 160 cases, they found that CD133 expression seemed not to provide additional prognostic information for ovarian cancer patients but, in the large study (400 ovarian cancer patients) **Zhang et al.**^[11] found that CD133 expression is associated with various clinicopathologic characteristics of primary ovarian cancer patients, with shorter disease-free survival time, and with lack of response to chemotherapy.

CONCLUSIONS

We concluded that the CD133 expression is a predictor of poor clinical outcomes in patients with ovarian surface epithelial tumors. CD133 expression is associated with high-grade serous carcinoma, necrosis, and the presence of bad prognostic signs as lymphovascular emboli, and peritoneal nodules.

Financial support and sponsorship: Nil.

Conflict of interest: Nil.

REFERENCES

1. **Steffensen K, Alvero A, Yang Y et al. (2011):**Prevalence of Epithelial Ovarian Cancer Stem Cells Correlates with Recurrence in Early-Stage Ovarian Cancer. *Journal of Oncology*, 8: 620523.
2. **Kwon M, Shin Y (2013):**Regulation of Ovarian Cancer Stem Cells or Tumor-Initiating Cells. *International Journal of Molecular Sciences*, 14(4): 6624–48.
3. **Mohammad G, Vandooren J, Siddiquei Met al. (2014):**Functional Links between Gelatinase B/Matrix Metalloproteinase-9 and Prominin-1/CD133 in Diabetic Retinal Vasculopathy and Neuropathy. *Progress in Retinal and Eye Research*, 43: 76–91.
4. **Burgos-Ojeda D, Rueda B, Buckanovich R (2012):**Ovarian Cancer Stem Cell Markers: Prognostic and Therapeutic Implications. *Cancer Letters*, 322(1): 1–7.
5. **Zeppernick F, Meinholt-Heerlein I (2014):**The new FIGO staging system for ovarian, fallopian tube, and primary peritoneal cancer. *Arch Gynecol Obstet.*, 290:839–842.
6. **Chen Y, Lin P, Ming Y et al. (2017):**The Effects of the Location of Cancer Stem Cell Marker CD133 on the Prognosis of Hepatocellular Carcinoma Patients. *BMC Cancer*, 17(1): 1–9.
7. **Cheung A, Ellenson L, Gilks C et al. (2017):**Tumours of the ovary. In: WHO Classification of Tumours Editorial Board. *Female genital tumours* [Internet]. Lyon (France): International Agency for Research on Cancer. (WHO classification of tumours series, 5th ed; vol 4. <https://tumoursclassification.iarc.who.int/chapters/1>).
8. **Wang W, Chen Y, Deng J et al. (2014):**The Prognostic Value of CD133 Expression in Non-Small Cell Lung Cancer: A Meta-Analysis. *Tumor Biology*, 35(10): 9769–75.
9. **Wu H, Qi X, Yan G et al. (2014):**Is CD133 Expression a Prognostic Biomarker of Non-Small-Cell Lung Cancer? A Systematic Review and Meta-Analysis. *William B. Coleman. PLoS One*, 9(6): 168-173.
10. **Curley M, Therrien V, Cummings C et al. (2009):**CD133 Expression Defines a Tumor Initiating Cell Population in Primary Human Ovarian Cancer. *Stem Cells*, 27(12): 1-5.
11. **Zhang J, Guo X, Chang D et al. (2012):**CD133 Expression Associated with Poor Prognosis in Ovarian Cancer. *Modern Pathology*, 25(3): 456–64.
12. **Ricci F, Broggin M, Damia G (2013):**Revisiting Ovarian Cancer Preclinical Models: Implications for a Better Management of the Disease. *Cancer Treatment Reviews*, 39(6): 561–68.
13. **Irollo E, Pirozzi G (2013):**CD133: To Be or Not to Be, Is This the Real Question? *American Journal of Translational Research*, 5(6): 563–81.
14. **Štemberger-Papić S, Vrdoljak-Mozetič D, Ostojić DV et al. (2015):** Expression of CD133 and CD117 in 64 Serous Ovarian Cancer Cases. *Collegium Antropologicum*, 39 (3): 745-753.
15. **Dyall S, Gayther S, Dafou D (2010):**Cancer Stem Cells and Epithelial Ovarian Cancer. *Journal of Oncology*, 10: 1-9.
16. **Zhou Q, Chen A, Song H et al. (2015):**Prognostic Value of Cancer Stem Cell Marker CD133 in Ovarian Cancer: A Meta-Analysis. *International Journal of Clinical and Experimental Medicine*, 8(3): 3080–88.
17. **Tao Y, Li H, Huang R et al. (2018):**Clinicopathological and Prognostic Significance of Cancer Stem Cell Markers in Ovarian Cancer Patients: Evidence from 52 Studies. *Cellular Physiology and Biochemistry*, 46(4): 1716–26.
18. **Ferrandina G, Bonanno G, Pierelli L et al. (2008):**Expression of CD133-1 and CD133-2 in Ovarian Cancer. *International Journal of Gynecological Cancer*, 18(3): 506–514.