

# Anatomical Variations of The Fifth Lumbar Artery in A Sample Kenyan Population

Ibsen Ongidi<sup>1</sup>, Thomas Amuti<sup>1</sup>, Joseph Mageto<sup>1</sup>, Nick Dennis<sup>1</sup>, Innocent Ouko<sup>1</sup>, Rebecca Murerwa<sup>1</sup>, Beda Olabu<sup>1</sup>, Julius Ogeng'o<sup>1</sup>

<sup>1</sup>Department of Human Anatomy, University of Nairobi, Nairobi, Kenya

**Correspondence to:** Thomas Amuti; tomamuti@gmail.com.

Received: 06 Jan 2021; Revised: 27 Feb 2021; Accepted: 06 March 2022; Available online: 26 Mar 2022

**Background:** The fifth lumbar arteries have a more variable presence and origin as compared to the first four arteries. Its anatomical variations may influence lower spine surgical and vascular interventions. **Aim:** Our objective was to determine the variations of the fifth lumbar artery in a cadaveric and contrast computed tomography (CT) study. **Materials and methods:** This descriptive cross-sectional study combined data from 90 cadaveric and 120 post-contrast abdomino-pelvic computed tomography (CT) from Human Anatomy Department, University-of-Nairobi and Radiology Department, Kenyatta-National-Hospital. Cadavers were dissected to expose the arteries. Their prevalence, patterns and position of origin on the 5<sup>th</sup> vertebral bodies were determined. Data were analyzed using SPSS. **Results:** The artery was present in 26.7% of the cadaveric group, and 16.7% of the CT group. It was only noted in males in both the cadaveric and CT groups. It

originated bilaterally as a common stem in 50% and as paired single branches in 50%. It originated at a mean distance of 9.03mm ± 7.23mm from the top of the L5 vertebra, maintaining a consistent relation to the upper third (90%) and the middle third (10%) of the body. **Conclusions:** The arteries were only noted in males and portrayed population specific variations.

**Keywords:** Fifth lumbar artery, lower back pain, endovascular surgery, aortography

Ann Afr Surg. 2022; 19(2): 100-107

**DOI:** <http://dx.doi.org/10.4314/aas.v19i2.7>

**Funding:** None

© 2022 Author. This work is licensed under the Creative Commons Attribution 4.0 International License.

## Introduction

The lumbar arteries constitute the principal arterial supply to the lower back, with branches that extend to supply the anterior abdominal wall. Most studies describe them as four pairs, while a fifth lumbar artery may occasionally be present. While the first four lumbar arteries almost always arise bilaterally from the posterolateral aspect of the aorta, the fifth lumbar arteries may arise either from the aorta, iliolumbar artery or the middle sacral artery (1-3). The fifth lumbar arteries tend to be smaller in size and have a shorter course, supplying mainly the adjacent spine and at times perforators to the

skin of the lower back and gluteal region (4, 5). Studies have reported variable prevalence of the fifth lumbar arteries (ranging from <1% to 38.6%), its pattern of origin either as a common stem or single stem, and level of origin in relation to the lumbar vertebra (4, 6, 7, 8). These variations may influence clinical symptoms of disease as well as surgical and vascular interventions in the lower back. Persons who present with fewer pairs of lumbar arteries or fifth lumbar arteries that have been narrowed due to atherosclerosis, are more likely to report lower back pain (9-11). Such factors reduce

vascular supply to the back hence causing pain. Africans have been noted to have a high lifetime prevalence of lower back pain at 47% (95% CI 37;58) and point prevalence of 39% (95% CI 30;47); a value that is higher than the global prevalence (12). Insufficient arterial blood flow due to lumbar artery variations may be an underlying factor for these observations.

Variations of the fifth lumbar artery may also influence endovascular and surgical procedures for abdominal aortic and lumbar artery aneurysms as well as spine pathology. Variable origin brings about difficulty in accessing these vessels during procedures such as embolization in treatment of vertebral body tumors or aortic stent graft placements emphasizing the need of its quantification (8, 12). When it is present, inadvertent injury to the fifth lumbar artery is likely occur during percutaneous vertebroplasty and other spine surgical interventions, especially due to its abnormal trajectory in relation to the spine compared to the other four lumbar arteries (8, 13, 14).

Owing to these important clinical applications, it is imperative to understand the anatomy of the fifth lumbar arteries. There is a paucity of data especially in the African setting, and thus, we report on the variant anatomy of the lumbar artery in the Kenyan setting.

### Materials and methods

We designed a descriptive cross-sectional study, which combined both cadaveric and computed tomography (CT) analysis of the 5<sup>th</sup> lumbar vessels. A total of 90 cadavers were obtained from the department of Human Anatomy and Chiromo Funeral Parlour of the University of Nairobi for the cadaveric study. A total of 120 post contrast abdominopelvic CT scans from patients were sought from the Kenyatta National Hospital Radiology Department for the CT study. The sample size was

arrived at using the formula shown: 
$$n \geq \frac{4 \times SD^2}{m^2}$$
 where n is the sample size, SD is standard deviation of a variable from previous studies, and m is the margin of error.

In calculating the sample size, the variable chosen was the mean diameter of the artery. This objective was chosen out of the rest, even though it is not a current variable of interest in this paper, because the data

required for sample size calculation was more present from previous studies as compared to the other variables. The measurement of this objective was also represented in standard deviation, a criterion needed for using the formula chosen. The Standard deviation (SD) used was the mean of the standard deviations of the left and right 5<sup>th</sup> lumbar arteries, which was 0.27 (15). The margin of error was taken at 0.05, having a confidence interval of 0.95. Therefore:

$$N = 4 \times (0.27^2) / (0.5 \times 0.5) = 120$$

Since the study had 2 groups: CT and cadaveric, 240 samples were to be collected.

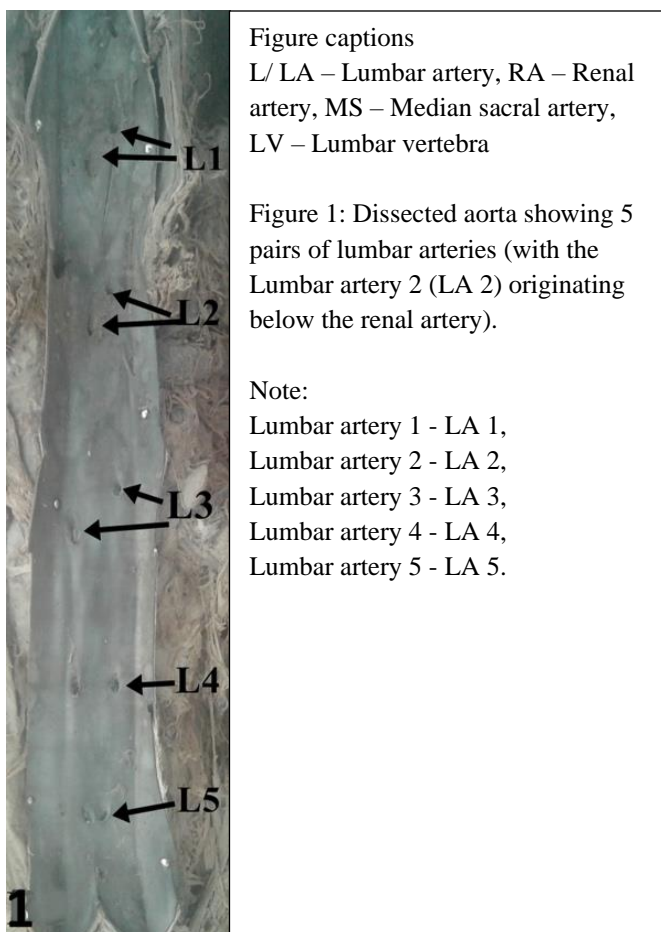
All the post contrast abdominopelvic CT scans were conducted by radiologists at the hospital. Those who had traumatic injury or surgery to the back were excluded from the study. Similarly, those with vascular lesions affecting the lumbar arteries, abdominal aortic aneurysms and lumbosacral transitional vertebra were also excluded. Demographic data were taken for analysis.

Prior to the data collection, approval for use of cadaveric materials is provided for in the Human Anatomy Act Cap 249 (1967) AND 252 (1958) respectively in the Kenyan constitution, and hence institutional ethical approval was waived. For the CT section of the study, ethical approval was sought from the Kenyatta National Hospital/University of Nairobi Ethics and Research Committee, UP401/05/2021.

### *Dissection of cadaveric specimen to expose the fifth lumbar artery.*

After removing the abdominal viscera and exposing the retro-peritoneum, the abdominal aorta was identified and carefully exposed from the kidneys to the pelvic brim. The infra-renal lumbar arteries were then located as branching from posterolateral aorta and coursing to the back muscles. The lumbar arteries were numbered to locate the fourth lumbar artery, which most often corresponded to the 4<sup>th</sup> lumbar vertebra.

The presence of an extra pair of lumbar arteries arising from the aorta, iliolumbar artery or middle sacral artery was then noted as the fifth lumbar artery. The number of specimens which had the fifth lumbar arteries was also noted (Figure 1).



arteries as well as the pattern of origin was done in the same way as that of the cadaveric samples.

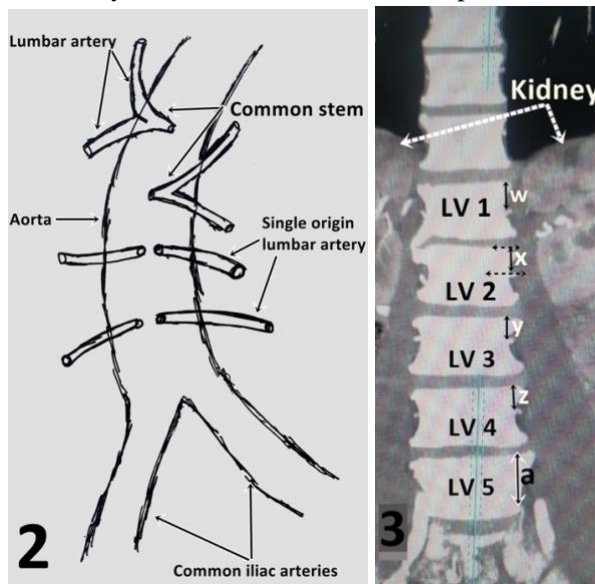


Figure 2. Figure demonstrating the different patterns of origin of the lumbar arteries.

Figure 3. CT showing the 5 lumbar arteries and the measurement of the distance between their origins and the top of their respective vertebra. Note: Lumbar vertebra 1 - LV 1, Lumbar vertebra 2 - LV 2, Lumbar vertebra 3 - LV 3, Lumbar vertebra 4 - LV 4, Lumbar vertebra 5 - LV 5. w = distance between the top of LV 1 and the point of origin of LA 1 on LV 1; x = distance between the top of LV 2 and the point of origin of LA 2 on LV 2; y = distance between the top of LV 3 and the point of origin of LA 3 on LV 3; z = distance between the top of LV 4 and the point of origin of LA 4 on LV 4; a = distance between the top of LV 5 and the point of origin of LA 5 on LV 5.

The site of origin of the artery was documented as either from the aorta or its branches such as the middle sacral artery or iliolumbar arteries. The corresponding vertebra was recorded as the vertebral level of origin. The pattern of origin of the fifth lumbar arteries was documented as either arising as a common stem giving rise to the two bilateral branches, or paired single origin of individual arteries (Figure 2). The distance between the bifurcation of the aorta and the respective lumbar arteries was documented (Figure 3).

*Analysis of Computer tomography studies*

Post contrast abdominopelvic CT scans taken by a Siemens CT machine were imported into a Di-chrome software program for reformatting, standardizing and labelling. Thereafter, they were reviewed for analysis of vasculature of the lumbar region by two independent radiologists. Determination of the number of lumbar

The CT images were further used to determine the position of the fifth lumbar artery ostium with respect to the 5<sup>th</sup> vertebral body (Figure 3). The distance between the top of each vertebral body and the origin of the fifth lumbar artery was determined. The distance of the whole vertebral body height was also taken and divided into upper, mid and lower thirds. The position of the fifth lumbar artery was then compared to the subdivisions of the vertebral body (Figure 4).

*Data management and analysis*

Data obtained was coded and analyzed using SPSS (version 21.0). Prevalence of the fifth lumbar arteries, pattern of origin and location on the vertebral bodies were calculated in percentages. Distance from the aortic bifurcation was calculated as means. Shapiro Wilk test was run to assess for normalcy of data. A P value  $\leq 0.05$  was considered significant at 95% confidence interval. Data was presented in tables and photomacrographs.

**Results**

A total of 210 specimen, 90 were cadaveric and 120 were from Computer Tomography (CT) were assessed. We were able to collect 120 samples for the CT portion of the study but were unable to fully collect the 120 samples for the cadaveric one owing to unavailability of samples, given the study duration. All the cadaveric samples were male whereas on computer tomography, 60 (50%) were male and 60 females (50%). The mean age was 53 years (16 years – 81 years) (median 59 years). (Figure 1, 3).

*Prevalence of fifth lumbar artery*

The fifth lumbar arteries was observed among 24/90(26.7%) in the cadaveric group, and in 20/120 (16.7%) among the CT group. Since all cadavers were male, the vessel among them was noted in males. In the CT group where both gender was represented, the vessel was also only noted in males. In both cadaveric and CT examination, the fifth lumbar arteries occurred bilaterally in pairs that supplied each side of the back. Our findings were not normally distributed according to results from a Shapiro Wilk test (p value = 0.000). There was no statistically significant difference noted in the prevalence of the fifth lumbar arteries between cadaveric vs CT groups (p value = 0.515).

*Pattern of origin of the fifth lumbar arteries*

From our findings in both the cadaveric and CT group, 50% of the fifth lumbar arteries arose as a common stem that subsequently divided into two branches bilaterally while in 50%, it arose as single branches that were paired.

*Position of origin of the fifth lumbar arteries relative to the L5 vertebral body as noted from the CT findings*

The fifth lumbar arteries were noted to originate at the level of the corresponding 5<sup>th</sup> vertebral bodies (Figure 2). Estimation of location on the vertebral bodies from the top of the respective vertebra was done among the CT group since this was difficult to determine among the cadavers.

Table 1: Table showing the distance of the fifth lumbar artery from the top of the vertebra and vertebral body heights as seen on CT scans.

Gender	Vertebral body height $\pm$ SD (mm)	Distance from the top of the vertebra (Mean)	Standard deviation
Male	26.6 $\pm$ 1.45	13.55	2.37
Female	26.2 $\pm$ 3.45	12.35	1.25

The mean distances of origin of the fifth lumbar artery from the top of L5 vertebra was 9.03mm  $\pm$  7.23mm. The vertebral heights were as tabulated (Table 1)

To derive the position of the origin of the fifth lumbar arteries with respect to the vertebra, their distance of origin was divided by the vertebral height as tabulated (Table 1). The fifth lumbar arteries had a consistent relation to the upper third of their corresponding vertebral bodies in 90% and the middle third in 10% of the samples.

**Discussion**

This study analyzed a total of 210 samples for the characteristics of the fifth lumbar artery, with 90 being from cadaveric samples while 120 were from CT scans. Our sample size were generally similar to other studies that have been done to assess the same, hence we compared our findings with these studies (Table 2).

*Prevalence of the fifth lumbar arteries*

The fifth lumbar arteries, from our findings, were noted in 26.7% and 16.7% of the cadaveric and CT samples respectively. It is worth mentioning that the fifth lumbar artery was noted only in males in both the cadaveric and CT groups. The observation made among the cadaveric group could be due to lack of availability of female cadavers in the laboratory from which the dissection was

done. For the observations made in the CT group, this could be due to low sample size representation.

Previous studies have noted a wide range of prevalence of these arteries (<1% to 38.6%) (Table 2). The finding of the fifth lumbar arteries may vary with the modality of investigations used. Imaging studies such as aortography and CT may reveal a lower prevalence of fifth lumbar arteries. This is a result of less flow of contrast media due to the smaller size of the arteries or

reduction of luminal size with age and atherosclerosis (2). This may also explain the lower prevalence of fifth lumbar arteries in our study among the CT samples compared to cadaveric samples. The difference was however not statistically significant. Radiologists and surgeons should therefore be aware that radiographic studies alone may miss the fifth lumbar arteries. They should therefore give longer periods to allow infiltration

Table 2: Table summarizing demographics and prevalence of the fifth lumbar arteries from different studies.

Study, Population studied	Type of study	n	Gender distribution	Age distribution	Prevalence of fifth lumbar artery
Ratliffe et al 1982, Caucasian [2]	Aortography (X-ray)	100	34 female, 66 males	2days – 72 years (median age group 0 – 60 years)	38% (14% only unilateral)
(Seker et al., 2005), Turkish [16]	Cadaveric (Fetuses)	120	50 male, 70 female	-	10%
(Karunanayake and Pathmeswaran, 2013), Sri Lankan [6]	Cadaveric	109	62males, 47 females	40-90 years; (mean 70.1 years)	1/109 (0.9%)
(Beveridge et al., 2015), Canadian [7]	Cadaveric and CT	22; 41 respectively	-	Cadaver – 76.6 years Ct – 71.6 years	-
(Tezuka et al., 2016), Japanese [14]	CT	323	204 men and 119 women	15 to 89 years (mean 66.5).	4.6% on right side, 8.7% on the left
(Orita et al., 2017), Japanese [8]	MRI	272	-	Mean age 62.7 years	38.6%
(Can et al., 2020), Turkish [15]	Cadaver	15	8 males, 7 were female	27 and 58 years (mean age, 40.8 years)	3/15 (20%)
<b>Present study, Kenyan</b>	<b>Cadaveric and CT</b>	<b>90; 120 respectively</b>	<b>150 males, 60 females (but the vessel was noted among males solely)</b>	<b>16-81 years; mean 53 years</b>	<b>26.7% Cadaveric and 16.7% CT</b>

of contrast material or directly identify fifth lumbar arteries visually in minimally invasive procedures and open surgeries.

The fifth lumbar arteries predominantly supply the fifth lumbar vertebra, lower back and gluteal region (2, 5, 16). Missing lumbar vessels have been associated with lower back pains (9, 10). Kenyans and African, in general,



have been shown to bear a significant prevalence and associated burden of low back pains (11). It is therefore plausible that some of these back pains are attributable to less vascular supply to lumbar regions especially where the are missing fifth lumbar arteries.

In patients where the fifth lumbar arteries are present, surgeons performing open or minimally invasive surgeries in the spine and retro-peritoneum should beware that these arteries have a unique relation to the vertebral body compared to the other lumbar arteries (8). Sometimes a an anastomosis may be present over the L5 vertebral bodies connecting the fifth lumbar artery, fourth lumbar artery and iliolumbar artery (2). The surgeon must beware to prevent iatrogenic injury to these variant fifth lumbar arteries. The increasing use of minimally invasive spine surgeries has especially increased the risk of injuries to lumbar arteries especially at L4 and L5 (8, 13, 18). A prior knowledge of the prevalence and anatomy of the fifth lumbar arteries is therefore indispensable to a clinician performing these procedures.

#### *Pattern of origin of fifth lumbar arteries*

The fifth lumbar arteries from our study originated directly from the aorta with 50% arising as one common stem and branching into two, while 50% arose singly. Most previous studies have reported that the fifth lumbar arteries originate from the middle sacral artery or the aorta (2, 14, 16, 17). This may be due to the embryological development of the intersegmental branches of the dorsal aorta in the fetus. Most of the lumbar pairs of intersegmental branches of the dorsal aorta become the first to fourth lumbar arteries, while the fifth pairs become the common iliac arteries while the caudal end forms the middle sacral artery (11, 16). The fifth lumbar intersegmental arteries may however persist to form the fifth lumbar arteries which often arise with the middle sacral arteries. Occasionally, the arteries may arise from the iliolumbar arteries (1) but this was not observed in our samples.

The origin of the fifth lumbar arteries as a common stem has similarly been observed in other studies. Beveridge et al., (2015) (7) noted this in 16% from a Canadian sample while Karunanayake et al., (2013) (6) observed

that the only case noted of a L5 in the Sri-Lanka populace, also originated as common trunk. Formation of common trunks of the lumbar arteries had been shown to have an embryological basis, as dorsal intersegmental arteries may fuse to form a common trunk during the fusion of the dorsal aortae sometime in the third to seventh week of gestation (7, 16).

Variations in the pattern of origin of the fifth lumbar arteries may have clinical significance. In the case of single origin, anastomotic connections between the contralateral branches of fifth lumbar arteries of the right and left sides may provide alternative supply if one artery is obstructed in atherosclerotic disease (6). This may not be the case when both arteries arise from a common stem as both sides will not receive blood supply leading to ischemia and pain. During surgeries, care must be taken in ligation of arteries arising as a common trunk. Additionally, the presence of common truncal origin of the fifth lumbar arteries may lead to increased failure in injection of contrast media during aortography.

#### *Position of ostia (origins) of the fifth lumbar arteries in relation to the vertebral body*

The fifth lumbar arteries in our setting were mostly located on the upper 1/3 of the L5 vertebral body. When present, the fifth lumbar arteries have been noted to have unique courses with relation to the vertebral bodies, sometimes coursing over the L4/L5 intervertebral disk (8). The fifth lumbar arteries are usually much smaller and shorter, and may not have branches to the spine or abdominal wall. The position of the lumbar artery on the vertebral body is highly important especially during minimally invasive surgery of the lower spine. Due to the unique relation of the fifth lumbar arteries to the corresponding vertebral bodies and intervertebral disk, care should be taken during procedures to avoid inadvertent injury (8, 13).

#### **Conclusion**

In conclusion, the fifth lumbar arteries were only noted among males. Similarly, half of the arteries originated as a common stem while half originated singly predisposing half of the population to possible lower

back pains. These and other variations should be taken into consideration by surgeons performing minimally invasive procedures in the spine or retro-peritoneum at the level of the lower lumbar vertebra in order to avoid inadvertent injury.

### Limitations and suggestions for future studies

The sample size obtained in the study was limited due to the availability of cadavers as well as CT specimen at the time. We therefore plan to conduct subsequent studies with larger sample sizes, and hopefully this can better clarify whether the fifth lumbar arteries are only located in males as noted in this study.

### Clinical perspective

Knowledge on the anatomical variations fifth lumbar arteries is indispensable to a clinician performing procedures involving these arteries such as endovascular and surgical procedures for abdominal aortic and lumbar artery aneurysms as well as spine pathology. Its variable origin may complicate procedures such as embolization in treatment of vertebral body tumors or aortic stent graft placements. Additionally, when present, inadvertent injury to the fifth lumbar artery is likely occur during percutaneous vertebroplasty and other spine surgical interventions, especially due to its abnormal trajectory in relation to the spine compared to the other four lumbar arteries. The anatomy of the lumbar artery is also important in appreciating blood supply to the lower back and as such, in persons with fewer pairs of lumbar arteries or arteries narrowed due to atherosclerosis, lower back pain is a common feature and should be kept in mind when handling these patients.

### Acknowledgments

We would like to sincerely thank the next of kin of the deceased for allowing the use of the specimen from their loved ones, in this research. We also extend our sincere gratitude to the deceased themselves; without them, this research would not have been possible.

### Consent to participate

Approval for use of cadaveric materials is provided for in the Human Anatomy Act Cap 249 (1967) AND 252

(1958) respectively in the Kenyan constitution, and hence institutional ethical approval was waived. For the CT section of the study, ethical approval was sought from the Kenyatta National Hospital/University of Nairobi Ethics and Research Committee, UP401/05/2021.

### Declaration of interests

The authors declare no conflict of interest.

### Author contributions

IO and TM lead in writing the original draft. All other authors contributed to editing and reviewing the manuscript.

### References

1. Caglar S, Dolgun H, Ugur HC et al. Extraforaminal lumbar arterial anatomy. *Surg Neurol* 2004; 61: 29–33
2. Ratcliffe JF. The anatomy of the fourth and fifth lumbar arteries in humans: an arteriographic study in one hundred live subjects. *J Anat* 1982; 135: 753–761.
3. Standring S. *Gray's Anatomy*. 40th Ed. New York 2008: Churchill Livingstone: 444–445
4. Arslan M, Comert A, Acar HI et al. Surgical View of the Lumbar Arteries and Their Branches: An Anatomical Study. *Oper Neurosurg (Hagerstown)* 2011; 68:16–22.
5. Vigato E, De Antoni E, Tiengo C et al. Radiological anatomy of the perforators of the gluteal region: The “radiosome” based anatomy. *Microsurgery* 2018; 38: 76–84.
6. Karunanayake AL, Pathmeswaran A. Anatomical Variations of Lumbar Arteries and Their Clinical Implications: A Cadaveric Study. *ISRN Anatomy* 2013.
7. Beveridge TS, Power A, Johnson M et al. The lumbar arteries and veins: Quantification of variable anatomical positioning with application to retroperitoneal surgery. *Clinical Anatomy* 2015; 28: 649–660.
8. Orita S, Inage K, Sainoh T et al. Lower Lumbar Segmental Arteries Can Intersect Over the Intervertebral Disc in the Oblique Lateral Interbody Fusion Approach With a Risk for Arterial Injury: Radiological Analysis of Lumbar Segmental Arteries by Using Magnetic Resonance Imaging. *Spine* 2017; 42: 135–142.
9. Kauppila LI. Atherosclerosis and disc degeneration/low-back pain--a systematic review. *Eur J Vasc Endovasc Surg* 2009; 37: 661–670.
10. Kauppila LI and Tallroth K. Postmortem angiographic findings for arteries supplying the lumbar spine: their relationship to low-back symptoms. *J Spinal Disord* 1993; 6: 124–129.

11. Morris LD, Daniels KJ, Ganguli B et al. An update on the prevalence of low back pain in Africa: a systematic review and meta-analyses. *BMC Musculoskelet Disord* 2018; 19.
12. Neubauer U. Retroperitoneal vascular injuries in lumbar intervertebral disk operation: report of 2 cases with a special course]. *Neurochirurgia (Stuttg)* 1990; 33: 199–201.
13. Liu L, Cheng S, Wang Q et al. An anatomical study on lumbar arteries related to the extrapedicular approach applied during lumbar PVP (PKP). *PLoS ONE* 2019; 14: e0213164.
14. Tezuka F, Sakai T, Nishisho T et al. Variations in arterial supply to the lower lumbar spine. *Eur Spine J* 2016; 25: 4181–4187.
15. Dunsker B, Sukru C, Habibullah D et al. Extraforaminal lumbar arterial anatomy. *Surgical Neurology* 2004; 61: 29-33
16. Seker M, Çiçekcibaşı AE, Salbacak A et al. A morphometric study and variations on the lumbar arteries of human fetuses. *Ann. Anat* 2005; 187: 135–140.
17. Can H, Diren F, Peker B et al. Morphometric Analysis of Lumbar Arteries and Relationship with Intervertebral Discs: A study of Surgical Anatomy on Human Fresh Cadavers. *Turkish Neurosurgery* 2020; 30.
18. Moore KL, Persaud TVN, Torchia MG. *The Developing Human - E-Book: Clinically Oriented Embryology* 2018. Elsevier Health Sciences.