

Original Research Article

Treatment of vulval condyloma with a combination of paiteling and cryotherapy, and its effect on late recurrence

Lijun Wang¹, Hongshuai Tian², Guiqing Liu³, Yan Yu³, Haili Li⁴, Leilei Chen³, Hongwei Xiong^{5*}

¹Department of Dermatology & Sexually Transmitted Diseases (STD), ²Department of Reproductive Health, ³Department of Obstetrics and Gynecology, The Second Children & Women's Health Care of Jinan City, ⁴Department of Obstetrics and Gynecology, Laiwu People's Hospital, Jinan 271100, Shandong, ⁵Department of Obstetrics and Gynecology, The Second People's Hospital of Huludao, Huludao 125000, Liaoning Province, China

*For correspondence: **Email:** hldexhw@163.com

Sent for review: 11 March 2021

Revised accepted: 26 July 2021

Abstract

Purpose: To study the clinical effectiveness of a combination of Paiteling and cryotherapy in the treatment of vulval condyloma acuminatum (VCA), and its effect on late recurrence.

Methods: Eighty-six VCA patients were chosen as research subjects, and were randomized into group A and group B. Group A patients were treated with combination of Paiteling and cryotherapy, while group B patients received cryotherapy only. The clinical effects of the two treatment methods on VCA were evaluated by measuring area of damaged skin, levels of interleukin-6 (IL-6) and C-reactive protein (CRP), as well as degree of recurrence of VCA in the two groups, before and after treatment.

Results: Total clinical treatment effectiveness in group A was significantly higher compared with group B ($p < 0.05$). After treatment, the area of damaged skin, and levels of IL-6 and CRP were markedly lower in group A than in group B ($p < 0.001$). After 6 months of treatment, disease control was higher in group A than in group B ($p < 0.05$). There was also a lower incidence of adverse reactions in group A than in group B ($p < 0.05$).

Conclusion: These results indicate that the combination of Paiteling and cryotherapy is more effective than cryotherapy alone in improving treatment effectiveness and reducing late recurrence of VCA. Therefore, the combined treatment has potentials clinical application in the management of VCA.

Keywords: Paiteling, Cryotherapy, Vulval condyloma acuminatum (VCA), Clinical efficacy, Late recurrence

This is an Open Access article that uses a funding model which does not charge readers or their institutions for access and distributed under the terms of the Creative Commons Attribution License (<http://creativecommons.org/licenses/by/4.0>) and the Budapest Open Access Initiative (<http://www.budapestopenaccessinitiative.org/read>), which permit unrestricted use, distribution, and reproduction in any medium, provided the original work is properly credited.

Tropical Journal of Pharmaceutical Research is indexed by Science Citation Index (SciSearch), Scopus, International Pharmaceutical Abstract, Chemical Abstracts, Embase, Index Copernicus, EBSCO, African Index Medicus, JournalSeek, Journal Citation Reports/Science Edition, Directory of Open Access Journals (DOAJ), African Journal Online, Bioline International, Open-J-Gate and Pharmacy Abstracts

INTRODUCTION

Vulval condyloma acuminatum (VCA), also known as genital warts, is caused by human papillomavirus (HPV). The disease is transmitted through sexual contact, and its incidence is second only to that of gonorrhoea.

Vulval condyloma acuminatum (VCA) is a very contagious disease which affects the genital and anal regions, and it is more prevalent in younger people [1]. Social psychology studies have found that due to stigma and condemnation, many patients do not seek medical treatment in time, and some may even maliciously spread

the disease in revenge, resulting in an increased prevalence [2]. At present, there are no radical treatment for VCA. This has led to difficulties in clinical treatment and ready recurrence of the disease. The commonly used treatment measures involve localized drug therapy, laser, cryotherapy and surgery [3].

Cryotherapy is a physical therapy which uses low temperature to cause necrosis of warts in the affected areas. However, the healing of wounds from simple cryotherapy is a slow process, and the effect of cryotherapy is usually unsatisfactory. Therefore, it has been speculated that the combination of physical therapy and drug therapy may reduce wound area in patients, while achieving rapid curative effect.

In recent years, Chinese medicine has made great progress in the treatment of condyloma acuminatum. *Paiteling* is a traditional Chinese medicinal preparation used for detoxification, *clearing of heat* and detumescence. It enhances metabolic capability of epidermal cells, promotes rapid shedding of warts, and inhibits the proliferation of HPV, resulting in radical treatment of the disease [4]. This study was carried out to investigate the clinical efficacy of combination of *Paiteling* and cryotherapy in the treatment of VCA, and its effect on late recurrence. The study involved a total of 86 VCA patients.

METHODS

General information on subjects

Eighty-six VCA patients treated in *The Second Children & Women's Health Care of Jinan City* from September 2019 to September 2020 were chosen as the subjects for this study. They were randomized into group A and group B, with 43 cases in each group. The study was conducted in accordance with the Declaration of Helsinki (as revised in 2013) [5].

Inclusion criteria

Patients who satisfied the following criteria were included in the study: those who met the diagnostic criteria for VCA in *Pathology* [6], and those for whom histological examination showed proliferation of spinous cells under the microscope.

Exclusion criteria

Patients in the following categories were excluded from the study: pregnant patients,

patients infected with syphilis and human immunodeficiency virus (HIV), patients who received antiviral treatment prior to the study, patients who were allergic to the drugs used, patients who had severe organ dysfunction, and patients with impaired consciousness, cognitive impairment and mental disorder.

This study was approved by the ethics committee of *The Second Children & Women's Health Care of Jinan City* (approval no. 2019-07-09), and the purpose of the study and study protocols were duly explained to the patients and their families, prior to obtaining signed informed consent from them.

Treatments

Group B patients were treated with cryotherapy only. Before treatment, local anaesthesia was performed with lidocaine aerosol (SFDA approval no.: H20031189); Guangzhou Xiangxue Pharmaceutical Co. Ltd; specification: 50 g). After spraying lidocaine aerosol for 2 min, cotton swabs dipped in liquid nitrogen were gently used to press the affected areas for 4 - 8 sec until the area and surroundings (within 1 mm) became frozen, whitened and slowly thawed. The process was repeated 2 - 3 times, once a day. After one week of treatment, the effect was examined. If the warts did not completely disappear, cryotherapy was continued until the warts completely fell off [7].

Group A patients were treated with combination of *Paiteling* and cryotherapy. Cryotherapy was performed as described above. Prior to *Paiteling* treatment, the affected areas were routinely disinfected. Then, the warts were smeared using cotton swabs dipped in the original solution of *Paiteling* (Yunnan Long'en Pharmaceutical Co. Ltd.; specification: 10 ml; Yumen Hygiene & Sanitation authorized approval number: 2018/0001). For patients with large number of warts, wet dressing with *Paiteling* was done on the affected areas for 15 min four times daily, using a gauze. A course of treatment was 7 days, after which the medication was suspended. During withdrawal of *Paiteling*, the patients were treated with fusidic acid cream (registration No: HC20090034; Bright Future Pharmaceutical Lab. Ltd.; specification: 10 g) to prevent wound infection. If the warts did not fall off completely, the next course of treatment was performed, but the total course of treatment did not exceed 3. To prevent recurrence, diluted *Paiteling* (1:50) was used for wet dressing on the affected area for 10 min at a time, and the frequency of dressing was gradually reduced in the course of 3 months. All patients were

subjected to followed up observation for 6 months.

Indices of treatment outcomes

The clinical therapeutic effects of the two treatments were evaluated according to *Diagnosis and Treatment of Condyloma Acuminatum (2015 edition)* [8]. If all the warts disappeared after treatment, and there was no damaged skin, the patients were deemed *cured*. If all the warts disappeared and the area of damaged skin was reduced by 70 - 99 % (excluding 99 %), the treatment was deemed *markedly effective*. If all the warts disappeared and the damaged skin area was reduced by 35 - 69 % (excluding 69 %), the treatment was classified as *effective*. However, if all the warts disappeared and the damaged skin area was reduced by < 34 %, the treatment was *ineffective*. Total treatment effectiveness (TTE) was calculated as shown in Eq 1.

$$TTE = C + ME + E \dots\dots\dots (1)$$

where *TTE* = total treatment effectiveness; *C* = cured cases; *ME* = markedly effective cases, and *E* = effective cases.

The area of damaged skin was measured before and after treatment

Fasting venous blood samples (3-mL portions) were collected from each subject in the two groups before and after treatment, and serum samples were obtained after centrifugation. The serum levels of IL-6 and CRP were measured using enzyme-linked immunosorbent assay (ELISA) kits (Jiangsu Jingmei Biotechnology Co.

Ltd), strictly according to the instructions of the kit manufacturer.

Disease recurrence during the follow-up period (2 months after treatment and 6 months post-treatment) was monitored. The occurrence of adverse reactions during the follow-up was recorded and compared between the two groups.

Statistical analysis

The data were statistically analyzed and processed using SPSS21.0 software. GraphPad Prism 7 (GraphPad Software, San Diego, USA) was used for graphics. Count data were expressed as numbers and percentages [n (%)], and were statistically compared between the two groups using chi squared (χ^2) test. Measurement data are presented as mean \pm SD, and were compared with *t*-test. Differences were considered statistically significant at $p < 0.05$.

RESULTS

Demographic and clinical profile of patients

No obvious differences in mean age, BMI, mean height, average disease course, number of warts, diameter of warts, educational status and calibre of residential area were observed between the two groups ($p > 0.05$, Table 1).

Clinical effectiveness of treatments

Total effectiveness of clinical treatment in group A was higher compared with group B ($p < 0.05$), as shown in Table 2.

Table 1: Demographic and clinical profile of patients

Item	Group A (n = 43)	Group B (n = 43)	χ^2/t	P-value
Mean age (years)	28.37 \pm 4.26	28.39 \pm 4.28	0.022	0.983
BMI (kg/m ²)	21.43 \pm 0.65	21.39 \pm 0.67	0.281	0.779
Mean height (cm)	163.21 \pm 3.44	163.24 \pm 3.46	0.040	0.968
Mean disease course (d)	36.54 \pm 4.35	36.57 \pm 4.37	0.032	0.975
Number of warts	1.24 \pm 0.25	1.26 \pm 0.27	0.356	0.722
Diameter of warts (mm)	3.28 \pm 0.18	3.31 \pm 0.22	0.692	0.491
Educational status				
University	14 (32.56%)	16 (37.21%)	0.205	0.651
Middle school	23 (53.49%)	25 (58.14%)	0.189	0.664
Primary school	6 (13.95%)	2 (4.65%)	2.205	0.138
Residential area			0.422	0.516
Urban	18 (41.86%)	21 (48.84%)		
Rural	25 (58.14%)	22 (51.16%)		

Table 2: Comparison of clinical efficacy between the two groups {n (%)}

Group	Cured	Markedly effective	Effective	Ineffective	Total effectiveness
A	12 (27.91%)	13 (30.23%)	16 (37.21%)	2 (4.65%)	95.35% (41/43)
B	7 (16.28%)	14 (32.56%)	14 (32.56%)	8 (18.60%)	81.40% (35/43)
χ^2					4.074
P-value					0.044

Area of damaged skin before and after treatment

The area of damaged skin of patients in group A was $1.72 \pm 0.25 \text{ cm}^2$ before treatment, and $0.81 \pm 0.14 \text{ cm}^2$ after treatment, while in group B patients, that was $1.74 \pm 0.26 \text{ cm}^2$ before treatment, and $1.24 \pm 0.16 \text{ cm}^2$ after treatment. The area of damaged skin in both groups after treatment was notably lower than the corresponding area before treatment ($p < 0.001$). However, the area of damaged skin in group A after treatment was markedly reduced, relative to that in group B ($p < 0.001$). See Figure 1.

Levels of IL-6 and CRP

Prior to treatment, no differences in the serum levels of IL-6 and CRP were observed between the two groups ($p > 0.05$). However, after treatment, the IL-6 and CRP levels in group A were lower compared with group B ($p < 0.05$). See Table 3.

Late recurrence of VCA

No obvious difference in disease control were found between the two groups after 2 months of treatment ($p > 0.05$). However, after 6 months of

treatment, disease control was markedly higher in group A than in group B ($p < 0.05$; Table 4).

Adverse reactions

There was significantly lower incidence of adverse reactions in group A than in group B ($p < 0.05$), see Table 5.

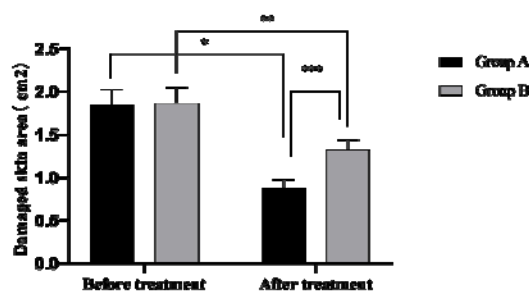


Figure 1: Comparison of damaged skin area between the two groups before and after treatment. Data are presented as mean \pm SD; * $p < 0.001$, damaged skin area in group A before treatment vs value after treatment ($t = 20.826$); ** $p < 0.001$, damaged skin area in group B before treatment vs value after treatment ($t = 10.740$); *** $p < 0.001$, damaged skin area in group A after treatment vs damaged skin area in group B after treatment ($t = 13.263$)

Table 3: Comparison of IL-6 and CRP levels between the two groups before and after treatment (mg/L)

Group	IL-6		CRP	
	Before treatment	After treatment	Before treatment	After treatment
A	34.84 \pm 5.43	12.05 \pm 3.25	12.18 \pm 2.09	5.76 \pm 1.35
B	34.82 \pm 5.42	19.84 \pm 3.21	12.21 \pm 2.05	9.74 \pm 1.29
t	0.017	11.183	0.067	13.977
P	0.986	0.000	0.947	0.000

Values are expressed as mean \pm SD

Table 4: Comparison of late disease recurrence between the two groups [n(%)]

Group	2 months after treatment			6 months after treatment		
	No recurrence	Recurrence	Control (%)	No recurrence	Recurrence	Control (%)
A	29	14	67.44%	34	9	79.07%
B	31	12	72.09%	23	20	53.49%
χ^2			0.221			6.295
P-value			0.639			0.012

Table 5: Comparison of adverse reactions between the two groups [n(%)]

Group	Pruritus	Swelling and pain	Erosion	Total incidence
Group A	1 (2.33%)	0 (0.00%)	0 (0.00%)	2.33% (1/43)
Group B	2 (4.65%)	3 (6.98%)	1 (2.33%)	13.95% (6/43)
χ^2				3.888
P-value				0.049

DISCUSSION

Studies have shown that the prevalence of condyloma acuminatum in China has increased in recent years due to changes in people's attitude towards sexual life. In particular, some young women engage in frequent sexual activities with multiple partners at the same time, without taking self-protection measures, resulting in a high incidence of sexually transmitted diseases [9-11].

Vulval condyloma acuminatum (VCA) is a common sexually transmitted disease. Most VCA patients exhibit no significant clinical symptoms, while a few patients present with pruritus, pain and vulval bleeding. This disease is often related to cervical intraepithelial neoplasia which increases the incidence of cervical cancer and adversely affects the quality of life of patients. Therefore, VCA has attracted much attention from the medical community. Cryotherapy uses the low temperature produced by liquid nitrogen to form ice crystals inside the warts, resulting in viral deformation and necrosis [12-14]. However, this treatment method cannot fundamentally solve the problem because it produces poor effect on warts with large diameters, and it is also associated with high degree of late recurrence.

Traditional Chinese medicine believes that VCA is mostly caused by improper sexual habits and viral infection. It is believed that the lesions are due to *qi* and *blood imbalance*, and impaired immune function. *Paiteling* is a traditional Chinese medicinal preparation used for *clearing heat*, detoxification, alleviation of swelling, stoppage of itching, and sterilization [15,16]. The drug penetrates the basal tissues of the patient, but not the dermis, thereby reducing skin damage. In addition, *Paiteling* changes the microenvironment of HPV, accelerates the metabolism of epidermal cells, enhances shedding of warts, and inhibits viral cell replication, thereby producing beneficial therapeutic effects.

In this study, the total treatment effectiveness produced by the combination of *Paiteling* and cryotherapy was significantly higher than that produced by simple cryotherapy. Moreover, the

area of damaged skin in patients after treatment was significantly less than that before treatment, with a significant difference between the two treatment methods. Gundogdu *et al* [17] have reported that the total treatment effectiveness in patients with giant condyloma acuminatum who received *Paiteling* and cryotherapy was 92.76 %, which was significantly higher than the corresponding value of 79.85 % in patients treated with carbon dioxide laser only. This indicated that the combined treatment with *Paiteling* and cryotherapy effectively improved the clinical treatment effect of VCA, and facilitated rehabilitation of the patients.

The high degree of recurrence of VCA has always been a difficult problem in the medical field. Some scholars believe that HPV virus can be detected in the skin within 1 cm of the affected area. Thus, complete eradication of the virus and removal of latent infection are the key to reducing the recurrence of VCA.

Studies have shown that most HPV infections in the anal and reproductive tract are sub-clinical infection i.e., the invasion of pathogens only induces the body to produce specific immune response without causing any serious tissue damage. Sub-clinical infection does not produce any clinical symptoms, and can only be diagnosed through immunological examination. This is also an important reason for the recurrence of VCA [18]. In addition, by comparing the degree of late recurrence in the two groups, this study found that although there was no significant difference in recurrence between the two groups after 2 months of treatment, the recurrence in the combined treatment group was significantly lower than that in the cryotherapy group after 6 months of treatment. This clearly indicates that the combined treatment not only effectively improved the clinical treatment efficacy of VCA, but also effectively reduced the extent of its late recurrence.

Limitations of the study

This study has some shortcomings. For example, the small number of selected cases may lead to bias in the research results. Therefore, the sample size should be expanded

in subsequent studies to increase the reliability of the results.

CONCLUSION

These results indicate that the combination of *Paiteling* and cryotherapy is more effective than cryotherapy alone in improving treatment effectiveness and reducing late recurrence of VCA. Thus, the combined treatment can potentially be used for the management of VCA.

DECLARATIONS

Conflict of interest

No conflict of interest is associated with this work.

Contribution of authors

We declare that this work was done by the authors named in this article and all liabilities pertaining to claims relating to the content of this article will be borne by the authors. Both Lijun Wang and Hongshuai Tian contributed equally to this article

Open Access

This is an Open Access article that uses a funding model which does not charge readers or their institutions for access and distributed under the terms of the Creative Commons Attribution License (<http://creativecommons.org/licenses/by/4.0>) and the Budapest Open Access Initiative (<http://www.budapestopenaccessinitiative.org/read>), which permit unrestricted use, distribution, and reproduction in any medium, provided the original work is properly credited.

REFERENCES

- Meng X, Li Y, Luan H, Shi X. Therapeutic effect of photodynamic therapy combined with imiquimod in the treatment of anal condyloma acuminatum and its effect on immune function. *Exp Ther Med* 2018; 16(5): 3909-3912.
- Na K, Sung JY, Kim HS. Clinicopathological Characteristics of High-grade Squamous Intraepithelial Lesions Involving Condyloma Acuminatum. *Anticancer Res* 2018; 38(3): 1767-1774.
- Furukawa S, Uota S, Yamana T, Sahara R, Iihara K, Yokomaku Y, Iwatani Y, Sugiura W. Distribution of Human Papillomavirus Genotype in Anal Condyloma Acuminatum Among Japanese Men: The Higher Prevalence of High-Risk Human Papillomavirus in Men Who Have Sex with Men with HIV Infection. *AIDS Res Hum Retroviruses* 2018; 34(4): 375-381.
- Zhong Q, Li K, Chen D, Wang H, Lin Q, Liu W. Rapid detection and subtyping of human papillomaviruses in condyloma acuminatum using loop-mediated isothermal amplification with hydroxynaphthol blue dye. *Br J Biomed Sci* 2018; 75(3): 110-115.
- World Medical Association. World Medical Association Declaration of Helsinki: ethical principles for medical research involving human subjects. *JAMA* 2013; 310(20):2191-4.
- Xie J, Ao C, Li J, Jiang L, Liu H, Zeng K. 5-aminolevulinic acid photodynamic therapy for condyloma acuminatum of urethral meatus. *J Dermatolog Treat* 2019; 30(7): 714-717.
- Hu Y, Lu Y, Qi X, Chen X, Liu K, Zhou X, Yang Y, Mao Z, Wu Z, Hu Y. Clinical efficacy of paiteling in the treatment of condyloma acuminatum infected with different subtypes of HPV. *Dermatol Ther* 2019; 32(5): e13065.
- Cui T, Huang J, Lv B, Yao Q. Giant condyloma acuminatum in pregnancy: A case report. *Dermatol Ther* 2019; 32(4): e12972.
- Yin GW, Xia XX, Song FJ, Huang YH. Expression of Wnt-1 and TSLC1 in condyloma acuminatum. *Clin Exp Dermatol* 2019; 44(6): 620-624.
- Combaud V, Verhaeghe C, El Hachem H, Legendre G, Descamps P, Martin L, Bouet PE. Giant condyloma acuminatum of the vulva: Successful management with imiquimod. *JAAD Case Rep* 2018; 4(7): 692-694.
- Bu J, Bu X, Chen P, Liu B, Chen F. Differences in expression of EGFR, Ki67 and p-EPK in oral cavity squamous cell carcinoma. *Trop J Pharm Res* 2015; 14(12):2213-2216.
- Thota PN, Arora Z, Dumot JA, Falk G, Benjamin T, Goldblum J, Jang S, Lopez R, Vargo JJ. Cryotherapy and Radiofrequency Ablation for Eradication of Barrett's Esophagus with Dysplasia or Intramucosal Cancer. *Dig Dis Sci* 2018; 63(5): 1311-1319.
- Sefiddashti L, Ghotbi N, Salavati M, Farhadi A, Mazaheri M. The effects of cryotherapy versus cryostretching on clinical and functional outcomes in athletes with acute hamstring strain. *J Bodyw Mov Ther* 2018; 22(3): 805-809.
- Sadoghi P, Hasenhütl S, Gruber G, Leitner L, Leithner A, Rumpold-Seitlinger G, Kastner N, Poolman RW, Glehr M. Impact of a new cryotherapy device on early rehabilitation after primary total knee arthroplasty (TKA): a prospective randomised controlled trial. *Int Orthop* 2018; 42(6): 1265-1273.
- Shaddel M, Sharifi I, Karvar M, Keyhani A, Baziar Z. Cryotherapy of cutaneous leishmaniasis caused by *Leishmania major* in BALB/c mice: A comparative experimental study. *J Vector Borne Dis* 2018; 55(1): 42-46.
- Zhao L, Wang MR, Cui ZH, Chen L, Volk GM, Wang QC. Combining Thermotherapy with Cryotherapy for Efficient Eradication of Apple stem grooving virus from Infected

- In-vitro-cultured Apple Shoots. Plant Dis* 2018; 102(8): 1574-1580.
17. Gundogdu EC, Arslan H. *Effects of Various Cryotherapy Applications on Postoperative Pain in Molar Teeth with Symptomatic Apical Periodontitis: A Preliminary Randomized Prospective Clinical Trial. J Endod* 2018; 44(3): 349-354.
18. Spencer CY, Harkin TJ, Vicencio AG. *Cryotherapy to treat and prevent airway stenosis in a patient with granulomatosis with polyangiitis. Pediatr Pulmonol* 2018; 53(1): E1-E3.