

## Original Research Article

# Effect of a combination of infrared irradiation and magnesium sulfate wet compress on infection and healing of episiotomy incision in puerperae

Shangfang Li<sup>1</sup>, Hua Gao<sup>2</sup>, Zhonggang Zhang<sup>2</sup>, Zhenhui Mi<sup>2\*</sup>

<sup>1</sup>Department of Gynaecology and Obstetrics, Jinan Maternal and Child Care Hospital, Jinan, 250001 Shandong, China, <sup>2</sup>The Fourth People's Hospital of Jinan, No. 50, Shifan Road, Tianqiao District, Jinan, Shandong, China

\*For correspondence: **Email:** [qubenweihuang221@163.com](mailto:qubenweihuang221@163.com); **Tel:** +86-18053153238

Sent for review: 19 April 2021

Revised accepted: 30 June 2021

### Abstract

**Purpose:** To investigate the effect of a combination of infrared irradiation and magnesium sulfate wet compress on infection and healing of episiotomy incision in puerperae during spontaneous delivery.

**Methods:** A total of 120 puerperae who underwent lateral episiotomy in Jinan Maternity and Child Hospital Affiliated to Shandong First Medical University from January 2019 to January 2020 were used as study subjects. They were randomly assigned to group A (n = 60) and group B (n = 60). Group B received external application of anerdian, while group A was treated with infrared irradiation and magnesium sulfate wet compress, in addition to receiving the treatment given to group B. The two groups were compared with respect to perineal edema, levels of inflammatory factors, wound pain grading, degree of incision healing, incision healing time, and incidence of infection.

**Results:** Group A patients had significantly lighter perineal edema and more pronounced pain relief than group B patients ( $p < 0.05$ ). The number of puerperae with grade A healing and grade C healing in group A was significantly higher than that in group B ( $p < 0.05$ ). Incision healing time and incidence of infection were lower in group A than in group B ( $p < 0.05$ ).

**Conclusion:** The combination of infrared irradiation and magnesium sulfate wet compress effectively mitigates perineal edema in puerperae, reduces pain, enhances the healing of incision, and lowers maternal infection. Thus, this combination strategy may have some merit in clinical practice.

**Keywords:** Infrared irradiation, Magnesium sulfate, Wet compress, Perineal edema, Puerperae, Maternal infection, Spontaneous delivery

This is an Open Access article that uses a fund-ing model which does not charge readers or their institutions for access and distributed under the terms of the Creative Commons Attribution License (<http://creativecommons.org/licenses/by/4.0>) and the Budapest Open Access Initiative (<http://www.budapestopenaccessinitiative.org/read>), which permit unrestricted use, distribution, and reproduction in any medium, provided the original work is properly credited.

Tropical Journal of Pharmaceutical Research is indexed by Science Citation Index (SciSearch), Scopus, International Pharmaceutical Abstract, Chemical Abstracts, Embase, Index Copernicus, EBSCO, African Index Medicus, JournalSeek, Journal Citation Reports/Science Edition, Directory of Open Access Journals (DOAJ), African Journal Online, Bioline International, Open-J-Gate and Pharmacy Abstracts

## INTRODUCTION

Spontaneous delivery, or vaginal delivery, the most common delivery mode for women, is likely to cause maternal perineal laceration. Therefore, lateral episiotomy is often used clinically to avoid the laceration [1-3]. However, lateral episiotomy

and perineal laceration hurt the perineum and cause edema. This is irritating to puerperae, some of whom suffer from severe pain which impairs postpartum recuperation and breastfeeding. Therefore, puerperae who have undergone lateral episiotomy should be treated with perineal physiotherapy to accelerate their

healing [4-7].

External application of anerdian is usually used for the treatment of lateral episiotomy. However, since it is slow in the elimination of the perineal swelling of the puerperae, it is not conducive to postpartum recovery. Infrared irradiation is a commonly-used method in wound treatment. It accelerates the repair of maternal tissue, while magnesium sulfate wet compress is effective for treating tumescence. On the basis of these qualities, this study was carried out in order to investigate the effect of the combination of the two methods on puerperae. A total of 120 selected puerperae who had lateral episiotomy and who were admitted to our hospital from January 2019 to January 2020 were used as the study subjects.

## METHODS

### General information

A total of 120 puerperae who underwent lateral episiotomy and who were admitted to our hospital from January 2019 to January 2020 were selected and randomly assigned to two groups: group A and group B, with 60 patients in each group ( $n = 60$ ). There were no significant differences in general data between the two groups ( $p > 0.05$ ; Table 1).

### Inclusion and exclusion criteria

#### Inclusion criteria

Puerperae and their families who had full understanding of the purpose of the study, and signed informed consent form; and those who had vaginal delivery and full-term pregnancy, were included in the study.

#### Exclusion criteria

Puerperae in the following categories were excluded from the study: (1) those who had mental problems or disability in communication;

(2) those who had other organic diseases; (3) puerperae with non-singleton pregnancy; (4) those whose duration of first stage of labor lasted more than 24 hours, and the second stage was above 2 hours; and (5) those with pregnancy complications.

The protocol has been approved by the Medical Science Research Ethics Committee of *Jinan Maternity and Child Hospital Affiliated to Shandong First Medical University*, (approved no. 2018-23(014)) and followed international guidelines for human studies [8].

### Treatments

Puerperae in two groups were instructed to keep the perineum clean and dry, and to adopt an appropriate posture during defecation to avoid wound dehiscence, and to clean the perineum thereafter. They were also advised to replace the perineal pad timely, and to eat balanced diets and foods that enhance wound healing. Puerperae in group B were treated with anerdian which was applied externally, while those in group A received treatment with magnesium sulfate wet compress, infrared irradiation, and external application of anerdian, in that sequence.

### External application of anerdian

Three-layer disinfected gauze infiltrated with 10% anerdian solution (Shanghai Likang Disinfection High-tech Co., Ltd., Huwei Xiaozhengzi 2003 No. 0001) was applied onto the perineal incisions of puerperae for 30 min every morning and evening.

### Magnesium sulfate wet compress

Puerperae were asked to lie down in supine position with knees dawn up, and the perineal incision wound, pubic region, labia majora and minora, buttocks and pubic region were disinfected,

**Table 1:** Comparison of general information between the two groups

Variable	Group A (n = 60)	Group B (n = 60)	X <sup>2</sup> /t	P-value
Mean age (weeks)	24.2 ± 3.5	24.3 ± 3.6	0.154	0.878
Fetal mass (kg)	38.4 ± 1.5	38.6 ± 1.2	0.806	0.422
First stage of labor (h)	3.2 ± 0.3	3.3 ± 0.4	1.549	0.124
Second stage of labor (h)	16.4 ± 2.9	16.3 ± 2.6	0.199	0.843
Incision suture time (min)	1.2 ± 0.3	1.3 ± 0.2	2.148	0.034
Gestational weight gain (kg)	5.7 ± 1.3	5.8 ± 1.2	0.438	0.662
	22.3 ± 3.2	22.5 ± 3.1	0.348	0.729

in that sequence, followed by application of wet compress with 50% magnesium sulfate gauze (Zigong Honghe Pharmaceutical Co. Ltd., GYZZ H51021263) for 30 min twice daily.

### Infrared irradiation

The infrared therapeutic apparatus (Beijing Zhongke Zhaoyang Medical Technology Co. Ltd., no. 20172260575) was set at a voltage of 220 V and power of 250 W, placed on the location between the legs of each puerpera at a distance of 0.4 m from the skin, for 30 min twice daily for 3 days. During the treatment, the height of irradiation lamp was adjusted if puerperae indicated a feeling of burning sensation on their skin.

### Assessment of treatment outcome indices

#### Perineal edema

The treatment outcomes were classified as *excellent*, *good recovery* or *poor recovery*, based on status of perineal edema and symptoms. If the edema and symptoms of puerpera disappeared after 3 days of the treatment, the outcome was regarded as *excellent recovery*; if the edema and symptoms of puerpera were significantly mitigated after 3 days of the treatment, the outcome was regarded as *good recovery*. However, if the outcome did not meet the above criteria, it was regarded as *poor*.

#### Levels of inflammatory factors

Levels of C-reactive protein (CRP) before and after treatment were compared between the two groups.

#### Grading of wound pain

The maternal pain was assessed and classified into levels I - IV. Level I indicated that the puerpera had no pain and could breastfeed; level II was for puerpera who had slight pain and could breastfeed in lateral position; level III was for puerperae with obvious pain and inability to breastfeed. Puerperae in level IV were those who had severe pain and needed drugs for pain relief. Thus, levels I and II reflected mitigation of pain, while there were no pain relief in levels III - IV [9].

#### Healing of incision

Incision healing was categorized into three levels. Level A reflected ideal healing condition, with the puerpera showing no adverse symptoms. Level B was for presence of

inflammatory reaction at incision, but without occurrence of suppuration, while level C reflected unhealed incision wound, and suppuration reaction [10].

### Incision healing time

Incision healing time was compared between the two groups of puerperae.

### Incidence of infection

Infection was indicated if the perineum was reddish and swollen, with tenderness and discharge. The number of puerperae with infection was counted and the proportion was calculated.

### Statistical analysis

Statistical analysis was conducted with SPSS 20.0 software, while graphics were carried out with GraphPad Prism 7 (GraphPad Software, San Diego, USA). Measurement data were analyzed with *t*-test, while enumeration data were analyzed using  $\chi^2$  test. Values of  $p < 0.05$  indicated statistically significant differences.

## RESULTS

### Perineal edema

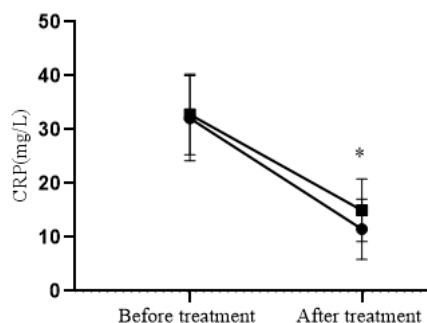
Perineal edema in group A was significantly smaller than that in group B ( $p < 0.05$ ), as shown in Table 2.

**Table 2:** Comparison of recovery from perineal edema between the two groups [n (%)]

Group	Excellent	Good	Poor	Excellent + Good
A	28 (46.7)	30 (50.0)	2 (3.3)	58 (96.7)
B	18 (30.0)	32 (53.3)	10 (16.7)	50 (83.3)
$\chi^2$	3.525	0.134	5.926	5.926
P	0.060	0.715	0.015	0.015

### Levels of inflammatory factors

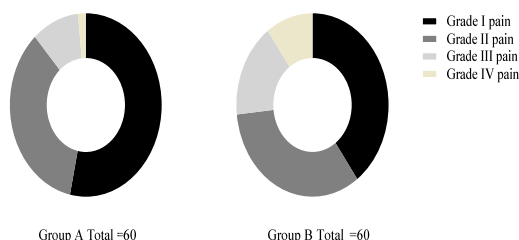
Figure 1 shows that group A had significantly lower level of inflammatory factors than group B ( $p < 0.05$ ). The horizontal axis in Figure 1 presents two points in time, before treatment and after treatment, while the vertical axis presents CRP levels (mg/L). The CRP values before treatment in groups A and B were  $32.1 \pm 7.9$  and  $32.8 \pm 7.5$  mg/L, respectively, while the corresponding post-treatment values were  $11.5 \pm 5.6$  and  $15.0 \pm 5.8$  mg/L, respectively. \* $P < 0.05$ .



**Figure 1:** Comparison of inflammatory factor levels

### Wound pain

There were 53 cases of pain improvement in group A, and 44 cases in group B. Group A significantly outnumbered group B in this aspect ( $X^2 = 4.357, p < 0.05$ ). These results are shown in Figure 2.



**Figure 2:** Comparison of grades of wound pain. There were 32 grade I pain cases in group A, and 24 cases in group B; there were 21 pain grade II cases in group A, and 20 cases in group B, while 6 cases with grade III pain were seen in group A, with 10 cases in group B. One patient had grade IV pain in group A, while 6 patients had grade IV pain in group B.

### Grades of healing of incision wound

There were no significant differences in the number of puerperae with grade A healing and grade C healing between group A and group B ( $p < 0.05$ ). These results are shown in Table 3.

**Table 3:** Comparison of healing of incision [n (%)]

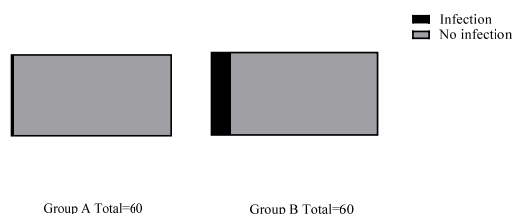
Group	No. of cases	Grade A	Grade B	Grade C
A	60	35 (58.3)	24 (40.0)	1 (1.7)
B	60	24 (40.0)	26 (43.3)	10 (16.7)
$X^2$		4.035	0.137	8.107
<i>P</i> -value		0.045	0.711	0.004

### Incision healing time

The incision healing time for puerperae in group A was much shorter than that for puerperae in group B [(6.2 ± 1.2) d vs (8.3 ± 1.5)d] ( $p < 0.05$ ).

### Incidence of infection

The incidence of incision infection in group A was significantly lower than that in group B ( $X^2 = 4.821, p < 0.05$ ). These data are presented in Figure 4.



**Figure 4:** Comparison of incidence of infection [n (%)]. The black area indicates infection in incision, while the gray area indicates no infection. There was 1 case (1.7 %) of incision infection in group A, and 7 cases (11.7%) in group B; 59 patients (98.3%) had no infection in group A, while 53 patients (88.3%) had no infection in group B

### DISCUSSION

Lateral episiotomy is clinically used to reduce the probability of perineal tear and improve the possibility of successful delivery. However, the incision at this site which is close to the anus is easily affected by feces or lochia, which often leads to poor healing of incision in puerperae [11,12]. In addition, the perineum is a rich network of vascular tissue which is very sensitive to pain. Thus, puerperae are susceptible to pain which may impair their postpartum recovery and breastfeeding. Therefore, it is necessary to deepen studies on the healing of lateral episiotomy and prevention of infection to ensure the health of puerperae [13,14].

Anerdian, a popular topical drug, kills microorganisms without much irritation, which makes it readily acceptable to puerperae. Studies on previous results from external application of anerdian in the treatment of episiotomy have shown that this class of drugs has limited effect on wound swelling, and cannot reduce the possibility of incision infection [15]. Magnesium sulfate is also a well-known wet compress drug which uses high osmotic pressure to allow for quick wound detumescence. Therefore, it is extremely effective in reducing local edema in puerperae. This accounts for the significantly lower degree of perineal edema in group A than in group B.

In addition, infrared irradiation is a common method used to accelerate wound healing. Its

mode of action involves dilation of blood vessels at the wound to enhance local blood circulation and metabolic capacity, thereby facilitating wound repair and absorption of inflammatory substances [16,17]. Therefore, there were significant differences in the number of puerperae with grade A healing and grade C healing in group A, when compared with group B. Moreover, incision healing time and the incidence of infection were significantly lower in group A than in group B. In a previous study, puerperae with lateral episiotomy (study group) received infrared irradiation, magnesium sulfate wet compress and anerdian external application, while puerpera in control group were given external application of anerdian. The results showed that incision healing time of puerpera in study group was significantly shorter than that in control group [17]. This indicates that this comprehensive physiotherapy method can accelerate the incision healing process in puerperae. Moreover, in the present study, more puerperae had reduced pain in group A than in group B, which was due to the fact that infrared irradiation removed the toxic components at the incision, reduced allergy, and relieved swelling and pain.

#### Limitations of the study

Inevitably, this study has several limitations regarding interpretations of results. First, this study was a single-center trial, and the findings might not have universality. Additionally, the sample size was relatively small, thus the results should be interpreted with cautions.

#### CONCLUSION

The results obtained in this study indicate that the combination of infrared irradiation and magnesium sulfate wet compress effectively optimizes the healing of episiotomy incision and reduces the possibility of infection. Thus, the combination treatment may have advantages in clinical practice.

#### DECLARATIONS

##### Conflict of interest

No conflict of interest is associated with this work.

##### Contribution of authors

We declare that this work was done by the authors named in this article and all liabilities

pertaining to claims relating to the content of this article will be borne by the authors.

#### Open Access

This is an Open Access article that uses a funding model which does not charge readers or their institutions for access and distributed under the terms of the Creative Commons Attribution License (<http://creativecommons.org/licenses/by/4.0>) and the Budapest Open Access Initiative (<http://www.budapestopenaccessinitiative.org/read>), which permit unrestricted use, distribution, and reproduction in any medium, provided the original work is properly credited.

#### REFERENCES

1. Klebanoff MA, Snowden JM. Re: Trends in operative vaginal delivery, 2005-2013: a population-based study. *BJOG*. 2018; 125 (1): 97.
2. Sentilhes L, Winer N, Azria E, Sénat MV, Le Ray C, Vardon D, Perrotin F, Desbrière R, Fuchs F, Kayem G, et al; Groupe de Recherche en Obstétrique et Gynécologie. Tranexamic Acid for the Prevention of Blood Loss after Vaginal Delivery. *N Engl J Med*. 2018; 379 (8): 731-742.
3. Daifotis HA, Smith MM, Denoble AE, Dotters-Katz SK. Risk Factors for Postpartum Maternal Infection Following Spontaneous Vaginal Delivery Complicated by Chorioamnionitis. *AJP Rep*. 2020; 10 (2): e159-e164.
4. Rizk DE, Thomas L. Relationship between the length of the perineum and position of the anus and vaginal delivery in primigravidae. *Int Urogynecol J Pelvic Floor Dysfunct*. 2000; 11 (2): 79-83.
5. Brako F, Raimi-Abraham BT, Mahalingam S, Craig DQM, Edirisinghe M. The development of progesterone-loaded nanofibers using pressurized gyration: A novel approach to vaginal delivery for the prevention of pre-term birth. *Int J Pharm*. 2018; 540 (1-2): 31-39.
6. Husslein P. Elective caesarean section versus vaginal delivery. Whither the end of traditional obstetrics? *Arch Gynecol Obstet*. 2001; 265 (4): 169-74.
7. Sánchez-López E, Gómara MJ, Haro I. Nanotechnology-based platforms for vaginal delivery of peptide microbicides. *Curr Med Chem*. 2020 Dec 8.
8. Department of Health, Education, and Welfare; National Commission for the Protection of Human Subjects of Biomedical and Behavioral Research. The Belmont Report. Ethical principles and guidelines for the protection of human subjects of research. *J Am Coll Dent*. 2014; 81: 4-13.
9. de Araujo CC, Coelho SA, Stahlschmidt P, Juliato CRT. Does vaginal delivery cause more damage to the pelvic floor than cesarean section as determined by 3D ultrasound evaluation? A systematic review. *Int Urogynecol J*. 2018; 29 (5): 639-645.

10. Ozdemir ME, Cilingir IU, Ilhan G, Yildiz E, Ohanoglu K. The effect of the systematic birth preparation program on fear of vaginal delivery and quality of life. *Arch Gynecol Obstet.* 2018; 298 (3): 561-565.
11. Zhang M, Zhuang B, Du G, Han G, Jin Y. Curcumin solid dispersion-loaded in situ hydrogels for local treatment of injured vaginal bacterial infection and improvement of vaginal wound healing. *J Pharm Pharmacol.* 2019; 71 (7): 1044-1054.
12. Lanzafame RJ, de la Torre S, Leibaschoff GH. The Rationale for Photobiomodulation Therapy of Vaginal Tissue for Treatment of Genitourinary Syndrome of Menopause: An Analysis of Its Mechanism of Action, and Current Clinical Outcomes. *Photobiomodul Photomed Laser Surg.* 2019; 37 (7): 395-407.
13. Kumar A, Paswan SS, Paswan A, Anand T. An unusual vaginal injury in a young primigravida patient: A rare case report. *Int J Surg Case Rep.* 2020; 75: 172-175.
14. Mori da Cunha MGMC, Giacomazzi G, Callewaert G, Hympanova L, Russo F, Vande Velde G, Gijssbers R, Albersen M, Sampaolesi M, Deprest J. Fate of mesoangioblasts in a vaginal birth injury model: influence of the route of administration. *Sci Rep.* 2018; 8 (1): 10604.
15. García-Mejido JA, Fernández-Palacín A, Bonomi Barby MJ, Castro L, Aquisé A, Sainz JA. A comparable rate of levator ani muscle injury in operative vaginal delivery (forceps and vacuum) according to the characteristics of the instrumentation. *Acta Obstet Gynecol Scand.* 2019; 98 (6): 729-736.
16. Lee HJ, Kim M, Lim BB, Kim YR, Jeon GS, Jung SH. Transcatheter Arterial Embolization in the Management of Postpartum Hemorrhage due to Genital Tract Injury after Vaginal Delivery. *J Vasc Interv Radiol.* 2021; 3(1): 99-105.
17. Meyer R, Rottenstreich A, Zamir M, Ilan H, Ram E, Alcalay M, Levin G. Sonographic fetal head circumference and the risk of obstetric anal sphincter injury following vaginal delivery. *Int Urogynecol J.* 2020; 31 (11): 2285-2290.