

Late Diagnosis of Anencephaly During the Second Trimester of Pregnancy and Obstetric Outcome

Konstantinos Zacharis, Eleni Chrysaopoulou, Stavros Kravvaritis, Theodoros Charitos, Anastasia Fouka

Department of Obstetrics and Gynecology, General Hospital of Lamia, Lamia, Greece

KEY WORDS: *anencephaly, prenatal diagnosis, ultrasound finding, obstetric outcome*

Anencephaly consists one of the most frequent type of neural tube defects, consequent to modification of the embryonic process during brain formation¹. The prevalence of anencephaly at birth is estimated between 1:5000 and 1:2000; restricted legal abortion laws and parents' religious principles may affect the frequency². Regarding our case, a 21-year-old G2P1 woman of low socioeconomic status attended our obstetric

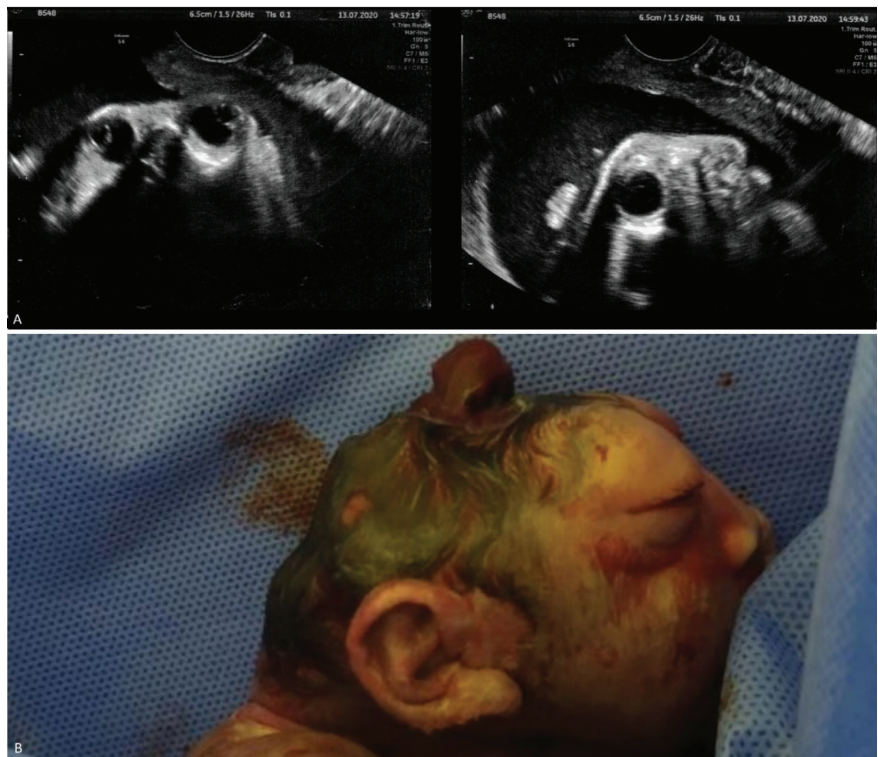


FIGURE. A. Ultrasound findings: Frog eye sign and absence of structures superior to orbits indicating anencephaly. **B.** Macroscopic features of anencephaly characterized by absence of cranial vault, low set ears and protruded eye balls.

Correspondence to:
Konstantinos Zacharis;
Department of Obstetrics
and Gynecology, General Hospital
of Lamia,
Papasiopoulou end of route,
35131 Lamia, Greece,
Tel.: +302231356189,
E-mail: zaxarisk@yahoo.com

Manuscript received June 23, 2021;
Revised manuscript received December 11, 2021;
Accepted December 20, 2021

Conflict of Interest: none declared

emergency department during the second trimester of pregnancy complaining of contractions. The woman experienced amenorrhea the last 6 months and had an unattended pregnancy, since she had never visited a healthcare professional. She also reported a history of preterm birth during her first pregnancy. Ultrasound examination revealed an intrauterine pregnancy with viable fetus and polyhydramnios. Absence of the cranial vault along with absence of cortical tissue and the frog eye sign were identified; hence anencephaly was diagnosed. The woman along with her husband were referred for genetic counseling and decided pregnancy termination. A fetal intracardiac potassium chloride injection was performed followed by an induction of labor with misoprostol. 36 hours later a stillborn male neonate was delivered vaginally. On gross examination of the fetus, protruded eyeballs and low set ears were recognized. Histopathology confirmed the diagnosis. Ultrasonography is the primary modality of imaging and prenatal diagnosis of anencephaly via ultrasound scan can be easily achieved during early gestation and it is considered of great importance. Although, anencephaly can be detected beyond the age of viability when couples neglect standard fetal anatomy scans³. When the diagnosis is delayed until the second trimester of pregnancy, individualized care should be offered by a multidisciplinary team in order to achieve an optimal perinatal outcome⁴. Birth planning is a major part

of perinatal palliative care in cases of life-limiting congenital anomalies⁵. Thus, health professionals should encourage and support parents to control their emotional reactions while find hope and meaning⁶.

REFERENCES

1. Avagliano L, Massa V, George TM, et al. Overview on neural tube defects: From development to physical characteristics. *Birth Defects Res* 2019;111:1455-1467.
2. Ekmekci E, Gencdal S. What's Happening When the Pregnancies Are Not Terminated in Case of Anencephalic Fetuses? *J Clin Med Res* 2019;11:332-336.
3. Al-Obaidly S, Thomas J, Abu Jubara M, et al. Anencephaly and obstetric outcome beyond the age of viability. *J Perinat Med* 2018;46:885-888.
4. O'Connell O, Meaney S, O'Donoghue K. Anencephaly; the maternal experience of continuing with the pregnancy. Incompatible with life but not with love. *Midwifery* 2019;71:12-18.
5. Cortezzo DE, Ellis K, Schlegel A. Perinatal Palliative Care Birth Planning as Advance Care Planning. *Front Pediatr* 2020;8:556. Published 2020 Sep 8.
6. Marc-Aurele KL. Decisions Parents Make When Faced With Potentially Life-Limiting Fetal Diagnoses and the Importance of Perinatal Palliative Care. *Front Pediatr* 2020;8:574556. Published 2020 Oct 22.