

## Ectopic Duodenal Varices in a Noncirrhotic Patient With Inferior Vena Cava Occlusion

Jiten P. Kothadia

*Methodist Transplant Institute, James D. Eason Transplant Institute, University of Tennessee Health Sciences Center, Memphis, TN.*

Abdul Aleem MD

*Lehigh Valley Health Network, Abdul.Aleem@lvhn.org*

Abbas Raza

*Nazih Zuhdi Transplant Institute, INTEGRIS Baptist Medical Center, Oklahoma City, OK.*

Follow this and additional works at: <https://scholarlyworks.lvhn.org/research-historical-works>

---

### Recommended Citation

Kothadia, J. P., Aleem, A., & Raza, A. (2021). Ectopic Duodenal Varices in a Noncirrhotic Patient With Inferior Vena Cava Occlusion. *LVHN Scholarly Works*. Retrieved from <https://scholarlyworks.lvhn.org/research-historical-works/41>

DOI: 10.14309/crj.0000000000000653

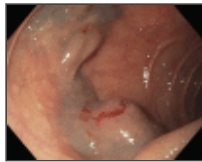This Article is brought to you for free and open access by LVHN Scholarly Works. It has been accepted for inclusion in LVHN Scholarly Works by an authorized administrator. For more information, please contact [LibraryServices@lvhn.org](mailto:LibraryServices@lvhn.org).

## Ectopic Duodenal Varices in a Noncirrhotic Patient With Inferior Vena Cava Occlusion

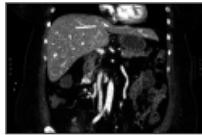
Jiten P. Kothadia, MD, Abdul Aleem, MD, and Abbas Raza, MD

### Case Report

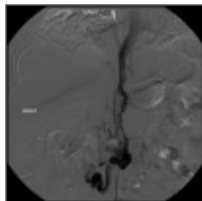
A 58-year-old woman with a medical history significant for end-stage renal disease requiring a kidney transplant presented to the hospital with a complaint of melena. Initial physical examination revealed pallor and tachycardia (110 beats/minutes) and blood pressure of 90/60 mm Hg. The admission laboratory results revealed hemoglobin 6.5 g/dL, white blood cell count  $13.0 \times 10^3$  cells/ $\mu$ L, platelet count  $240 \times 10^3$  cells/ $\mu$ L, aspartate aminotransferase 38 U/L, alanine aminotransferase 50 U/L, alkaline phosphatase 68 U/L, total bilirubin 0.5 mg/dL, prothrombin time of 13 seconds, international normalized ratio 1.0, creatinine 1.36 mg/dL, and blood urea nitrogen 38 mg/dL. She underwent esophagogastroduodenoscopy that revealed isolated large duodenal varices with fresh blood in the duodenum (Figure 1). Abdominal ultrasound showed the liver normal in size and morphology. A triple-phase abdominal computed tomography scan showed numerous varices within and adjacent to the duodenum with complete occlusion of the suprarenal inferior vena cava (IVC) (Figure 2). She underwent digital subtraction angiography with balloon angioplasty with an endograft placement (Figure 3). Digital subtraction angiography of the IVC after stent deployment showed no evidence of stenosis, and no flow is seen in the varices or collateral vessels (Figure 4). Postprocedure, the patient improved with no further drop in hemoglobin.



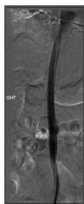
**Figure 1.**  
Esophagogastroduodenoscopy showing large duodenal varices with fresh blood in the duodenum.



**Figure 2.**  
Triple-phase abdominal computed tomography scan showed numerous varices within and adjacent to the duodenum with termination of the inferior vena cava superior to the renal veins suggestive of complete occlusion of the suprarenal inferior vena cava.



**Figure 3.**  
Digital subtraction angiography with balloon angioplasty with the placement of an endograft.



**Figure 4.**  
Digital subtraction angiography of the inferior vena cava after stent deployment showed no evidence of stenosis, and no flow is seen in the varices or collateral vessels.

Ectopic varices (EV) are complex pressurized portosystemic collaterals that can occur anywhere in the gastrointestinal tract apart from gastroesophageal regions and account for 2%–5% of all variceal bleeding.<sup>1,2</sup> Duodenal varices are the most common small bowel varices and are frequently seen in patients with cirrhosis.<sup>2</sup> EV has a 4-fold higher risk of bleeding when compared with gastroesophageal varices and can present with massive hemorrhage with mortality rates as high as 40%.<sup>1,2</sup>

Unfortunately, no treatment guidelines have been established for EV management because the literature is limited to case reports and small case series. Our patient did not have any identifiable hypercoagulation disorder and more likely developed EV due to IVC thrombosis. In the literature,

endoscopic therapy (sclerotherapy, band ligation, or glue injection), percutaneous transcatheter embolization, transjugular intrahepatic portosystemic shunt, and transvenous obliteration through either retrograde or antegrade, percutaneous mesocaval shunt, and surgical procedures have been described for the management of EV.<sup>1–3</sup> In the absence of stigmata of chronic liver disease, further investigation revealed IVC obstruction as a cause of EV that was treated with balloon angioplasty and endograft placement. Although rare, IVC obstruction should be considered as a differential in a noncirrhotic patient with ectopic duodenal varices. The ideal management of EV is to ensure prompt hemostasis and identify and address the etiology of the EV.

## DISCLOSURES

Author contributions: JP Kothadia and A. Aleem wrote the article. A. Raza revised the article for intellectual content. JP Kothadia is the article guarantor.

Financial disclosure: None to report.

Informed consent was obtained for this case report.

## Article information

ACG Case Rep J. 2021 Aug; 8(8): e00653.

Published online 2021 Aug 24. doi: [10.14309/crj.0000000000000653](https://doi.org/10.14309/crj.0000000000000653)

PMCID: PMC8386911

PMID: [34476280](https://pubmed.ncbi.nlm.nih.gov/34476280/)

Jiten P. Kothadia, MD,<sup>1</sup> Abdul Aleem, MD,<sup>2</sup> and Abbas Raza, MD<sup>3</sup>

<sup>1</sup>Methodist Transplant Institute, James D. Eason Transplant Institute, University of Tennessee Health Sciences Center, Memphis, TN

<sup>2</sup>Division of Gastroenterology, Department of Medicine, Lehigh Valley Health Network, Allentown, PA

<sup>3</sup>Nazih Zuhdi Transplant Institute, INTEGRIS Baptist Medical Center, Oklahoma City, OK

 Corresponding author.

Abdul Aleem: [a\\_aleim@live.com](mailto:a_aleim@live.com); Abbas Raza: [abbas.raza@integrisok.com](mailto:abbas.raza@integrisok.com)

**Correspondence:** Jiten P. Kothadia, MD ([kothadia.jiten@gmail.com](mailto:kothadia.jiten@gmail.com)).

Received 2021 Feb 15; Accepted 2021 Apr 29.

Copyright © 2021 The Author(s). Published by Wolters Kluwer Health, Inc. on behalf of The American College of Gastroenterology.

This is an open access article distributed under the terms of the [Creative Commons Attribution-Non Commercial-No Derivatives License 4.0 \(CCBY-NC-ND\)](https://creativecommons.org/licenses/by-nc-nd/4.0/), where it is permissible to download and share the work provided it is properly cited. The work cannot be changed in any way or used commercially without permission from the journal.

Articles from ACG Case Reports Journal are provided here courtesy of **American College of Gastroenterology**

## REFERENCES

1. Bhat AP, Davis RM, Bryan WD. A rare case of bleeding duodenal varices from superior mesenteric vein obstruction -treated with transhepatic recanalization and stent placement. *Indian J Radiol Imaging*. 2019;29(3):313–7. [[PMC free article](#)] [[PubMed](#)] [[Google Scholar](#)]
2. House T, Webb P, Baarson C. Massive hemorrhage from ectopic duodenal varices: Importance of a multidisciplinary approach. *Case Rep Gastroenterol*. 2017;11(1):36–41. [[PMC free article](#)] [[PubMed](#)] [[Google Scholar](#)]
3. Helmy A, Al Kahtani K, Al Fadda M. Updates in the pathogenesis, diagnosis and management of ectopic varices. *Hepatol Int*. 2008;2(3):322–34. [[PMC free article](#)] [[PubMed](#)] [[Google Scholar](#)]