

Isolated Scaphoid Dislocation From Low-Energy Wrist Trauma

Adrian Moy
Morsani School of Medicine

Ethan Song
Morsani School of Medicine

Sean J. Wallace MD
Lehigh Valley Hospital, sean.wallace@lvhn.org

Robert Teixeira MD
Lehigh Valley Health Network, robert.teixeira@lvhn.org

Yee-Cheng Low MD
Lehigh Valley Health Network, YeeCheng.Low@lvhn.org

See next page for additional authors

Follow this and additional works at: <https://scholarlyworks.lvhn.org/surgery>



Part of the [Plastic Surgery Commons](#), and the [Surgery Commons](#)

Published In/Presented At

Moy, A., Song, E., Wallace, S.J., Teixeira, R., Low, Y., & Weiss, L. (2021, March). Isolated scaphoid dislocation from low-energy wrist trauma. *Journal of Hand Surgery Global Online*, 3, 99-102.

This Article is brought to you for free and open access by LVHN Scholarly Works. It has been accepted for inclusion in LVHN Scholarly Works by an authorized administrator. For more information, please contact LibraryServices@lvhn.org.

Authors

Adrian Moy, Ethan Song, Sean J. Wallace MD, Robert Teixeira MD, Yee-Cheng Low MD, and Lawrence Weiss



Contents lists available at ScienceDirect

Journal of Hand Surgery Global Online

journal homepage: www.JHSGO.org

Case Report

Isolated Scaphoid Dislocation From Low-Energy Wrist Trauma

Adrian Moy, MS, * Ethan Y. Song, BA, * Sean J. Wallace, MD, † Robert M. Teixeira, MD, † Yee Cheng Low, MD, † Lawrence E. Weiss, MD ‡

* Morsani College of Medicine, University of South Florida, Tampa, FL

† Department of Surgery, Division of Plastic & Reconstructive Surgery, Lehigh Valley Health Network, Allentown, PA

‡ Division of Orthopedic Hand Surgery, OAA Orthopedic Specialists, Allentown, PA



ARTICLE INFO

Article history:

Received for publication November 28, 2020

Accepted in revised form January 27, 2021

Available online February 17, 2021

Key words:

Isolated scaphoid dislocation

Marfan syndrome

Low-energy trauma

Isolated scaphoid dislocation is an extremely rare injury typically caused by high-energy trauma. We present the first observed case of isolated scaphoid dislocation resulting from a non-traumatic injury of the wrist in power-grip tension in a patient with a questionable history of Marfan Syndrome. A 20-year-old right-hand dominant man presented to the emergency department with right wrist pain and deformation after carrying a table. The patient reported a possible history of Marfan Syndrome, but it had never been definitively diagnosed. Imaging revealed radial dislocation of the scaphoid. Bedside closed reduction was performed followed by outpatient ligament reconstruction with return to normal activities at 6 months. Early diagnosis and management lead to an improved prognosis for isolated scaphoid dislocation. Regardless of patient history or mechanism of injury, treatment options include closed reduction, percutaneous fixation, and/or open reduction with internal fixation and ligamentous reconstruction.

Copyright © 2021, THE AUTHORS. Published by Elsevier Inc. on behalf of The American Society for Surgery of the Hand. This is an open access article under the CC BY-NC-ND license (<http://creativecommons.org/licenses/by-nc-nd/4.0/>).

Isolated scaphoid dislocation is an extremely rare injury. To date, few cases have been published, and no formal investigation into incidence, classification, or management have been performed.^{1,2} These injuries are characteristically associated with high-energy trauma but have occasionally been seen in other scenarios. Currently, diagnosis and management rely on physician experience and preference, although there have been attempts to develop a classification system and management algorithm.³

Cases of joint dislocation and laxity have been observed in patients with Marfan Syndrome (MFS), which is one of the most common inherited disorders affecting connective tissue involving the fibrillin 1 gene. Although patients can often present with ocular dislocation, excess linear growth of long bones, and scoliosis, defects in the extracellular matrix and elastic fibers can also lead to joint laxity. While patellar instability and developmental dysplasia of the hip have been previously described,⁴ there are limited documented cases of dislocation in small joints, such as the hand.^{2,5}

This report describes the presentation, management, and outcome of an isolated scaphoid dislocation with associated scapholunate ligament disruption in a patient with a presumed diagnosis of MFS.

Case Presentation

A 20-year-old right-hand dominant man presented to a level one trauma center with right wrist pain and deformation. The patient reported a questionable history of MFS as a young child, but he never completed fibrillin 1 gene testing. Although tall and thin, the patient denied cardiac issues, prior joint dislocations, or other skeletal anomalies. Prior to presenting at the emergency department, the patient reported carrying a table when he felt his right wrist extend dorsally, and he simultaneously heard a popping noise. Subsequently, the patient lost nearly all range of motion of his wrist and noticed a volar-radial deformity. The patient denied numbness or tingling in the digits, hand, or wrist.

The patient was 1.8 m (72 inch) tall and weighed 94.3 kg (208 lb). Arm span measurement was not recorded. Hand examination revealed decreased range of motion, tenderness to palpation over the scaphoid, and localized swelling. Three-view x-ray imaging

Declaration of interests: No benefits in any form have been received or will be received related directly or indirectly to the subject of this article.

Corresponding Author: Ethan Y. Song, BA, 12901 Bruce B Downs Blvd, Tampa, FL 33612.

E-mail address: esong@usf.edu (E.Y. Song).

<https://doi.org/10.1016/j.jhsg.2021.01.002>

2589-5141/Copyright © 2021, THE AUTHORS. Published by Elsevier Inc. on behalf of The American Society for Surgery of the Hand. This is an open access article under the CC BY-NC-ND license (<http://creativecommons.org/licenses/by-nc-nd/4.0/>).

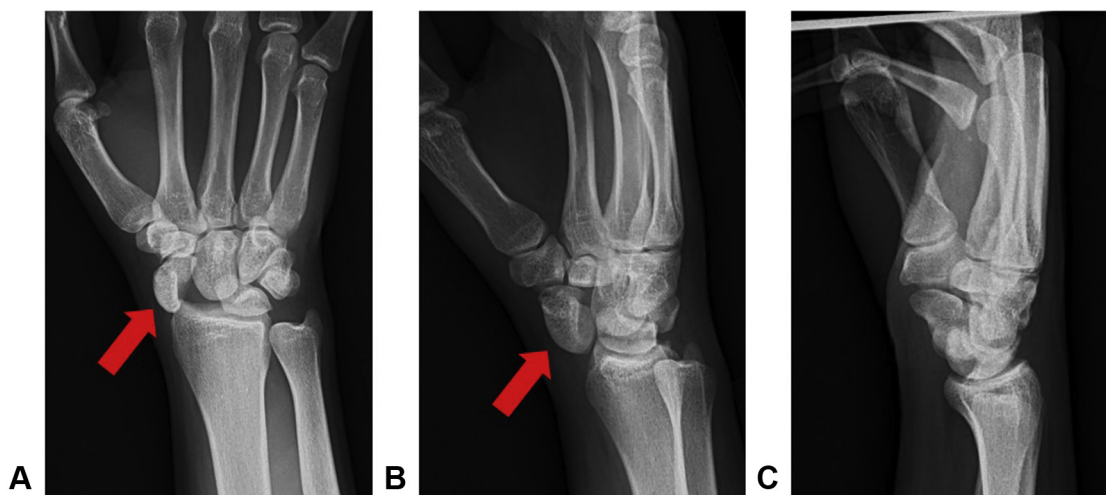


Figure 1. Isolated scaphoid dislocation with proximal migration of capitate and disruption of Gilula's lines. **A** Anteroposterior view. **B** Oblique view. **C** Lateral view.

revealed radial dislocation of the scaphoid with significant widening of the scapholunate (S-L) joint. There was proximal migration of the capitate and disruption of Gilula's lines, without fracture or joint effusion (Fig. 1).

A total wrist block was performed. With the elbow flexed at 90°, the index and long fingers were placed with 2.23 kg (5 lb) of longitudinal traction for 5 min. The wrist was dorsiflexed with ulnar deviation while direct digital pressure was applied over the scaphoid. This maneuver achieved clinical reduction, and the patient regained full movement without re-dislocation. Afterward, a thumb spica orthosis was placed. Post-reduction x-rays confirmed anatomic restoration of the previously dislocated scaphoid and restoration of Gilula's lines, but they also revealed a 1-cm widening of the distance between the scaphoid and the lunate, indicating S-L ligamentous injury (Fig. 2).

Due to complete S-L ligament avulsion and radioscaphoid capitate ligament insufficiency, ligament reconstruction was performed within 1 week following the injury using a flexor carpi radialis tendon graft (modified Ross technique), Kirschner wire pin fixation at the scaphocapitate level, and cast immobilization. The patient was closely followed over the next 8 weeks with serial imaging and casting. After 2 months of immobilization, the Kirschner wires were removed, and the patient transitioned to a removable thermoplastic orthosis. The patient began working with a certified hand therapist to regain motion.

At 6-month follow-up evaluation, the patient reported no pain, and he had regained nearly complete active and passive range of motion and normal grip strength. The wrist appeared stable on stress examination without excessive dorsiflexion. At 6 months, wrist extension was measured at 40° and wrist flexion was measured at 60°, compared to 40° and 45° at 4 months, respectively. Grip strength measured with a Jamar dynamometer on the third setting improved to 22.7 kg (50 lb)/45.4 kg (100 lb) (right/left) at 6 months from 15.9 kg (35 lb)/38.6 kg (85 lb) at 4 months. Imaging showed a slight 4.8-mm S-L gap (Fig. 3), but otherwise the position was secure and unchanged from prior radiographs. The patient returned to all normal activities without restriction. The authors are unaware of any complications or functional deficits at the time of writing, but the patient was unable to be reached for an additional long-term follow-up or Quick Disabilities of Arm, Shoulder & Hand evaluation.

Discussion

Solitary scaphoid dislocation is a sparsely documented and poorly understood injury. First described by Higgs⁶ in 1930, there have only been isolated published case reports, and the epidemiology is currently unexplored.¹ A recent literature review by Amundsen et al¹ identified a total of 55 documented cases of isolated scaphoid dislocation, with the majority of these injuries in males with ages between 18–79 years. Notably, the 20-year-old man we saw is one of the younger reported cases of isolated scaphoid dislocation. The injury pathogenesis has not been fully elucidated, although it generally requires significant force to cause the scaphoid to dislocate out of the fossa.⁷ Such injuries frequently result in concomitant fracture of the radial styloid or the waist of the scaphoid, thus isolated dislocations are rare.⁸ In our patient, the dislocation occurred as the result of carrying a table. The patient's wrist was dorsiflexed with ulnar deviation, like the anatomic positioning first described by Buzby² and found in many other reported cases.¹ However, this case was critically different in that the dislocation was not the result of a traumatic event, such as a motor vehicle accident or a fall from height. His dislocation could have been secondary to his presumed diagnosis of MFS. Notably, this is also the first reported case of an isolated scaphoid dislocation occurring due to wrist placement in relatively static tension, rather than forceful flexion. Therefore, this report highlights the need for awareness and clinical suspicion of scaphoid dislocation, even in the absence of high-energy wrist trauma.

While the patient had an unconfirmed diagnosis of MFS, the presence of a connective tissue disorders such as MFS could have contributed to the genesis of this injury. Previous cases of MFS-associated ligament laxity and joint hypermobility have been reported, including non-traumatic dislocation of the carpal lunate.^{2,5} Patients with a suspected or questionable history of connective tissue disorders could be assessed according to the Carter and Wilkinson⁹ scoring system. This system measured hyperextension of the thumb, fingers, elbow, and knee; and hyper-dorsiflexion or eversion of the ankle. A positive finding in 3 or more joints indicated generalized joint hyperlaxity. Passive extension testing of this patient's joints was not performed, thus a score was not recorded. The relative infrequency of this type of dislocation and unique circumstances of this case serve to provide a greater understanding of the pathogenesis and management of isolated scaphoid dislocations.

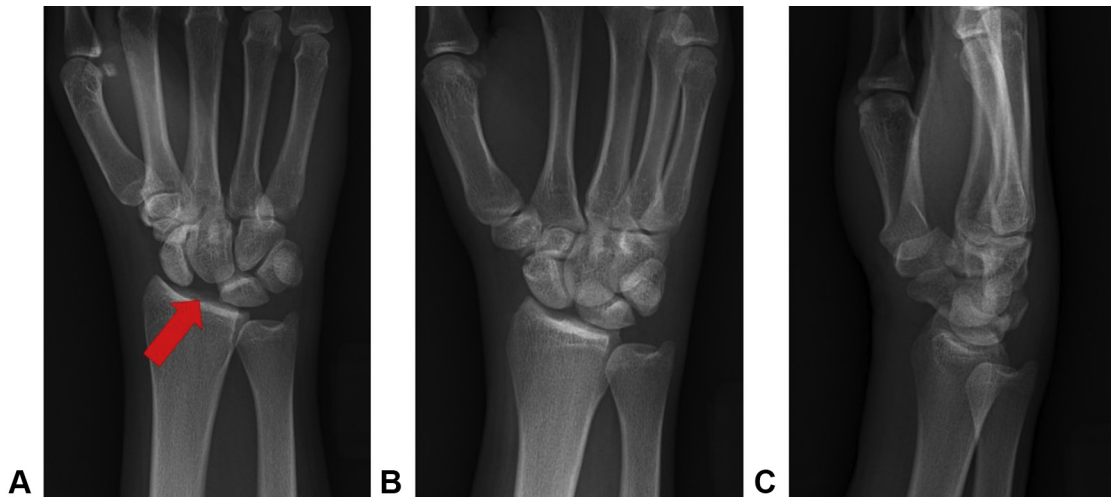


Figure 2. Imaging after closed reduction showing the widening of the scaphoid and the lunette, indicating scapholunate ligamentous injury. **A** Anteroposterior view. **B** Oblique view. **C** Lateral view.

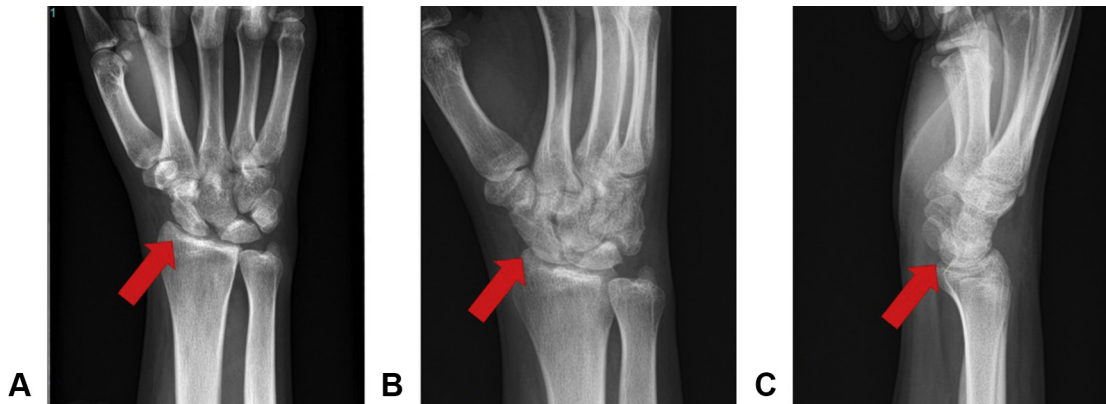


Figure 3. Imaging at 6-month follow-up showing good sagittal and coronal realignment of the scaphoid with a stable 4.8-mm scapholunate gap. **A** Anteroposterior view. **B** Oblique view. **C** Lateral view.

Patients with suspected scaphoid dislocations should undergo thorough evaluation, including medical history and age, gender, hand dominance, mechanism of injury, and coexisting conditions. In addition to history and physical examination, diagnosis can generally be confirmed with 3-view radiographs. Magnetic resonance imaging and computed tomography may aid in identifying associated soft tissue injury and/or bony injury not seen on radiographs.⁵

Leung et al³ developed a classification system for scaphoid dislocations, which categorized dislocations into primary or secondary, simple or complex, partial or total, and direction of dislocation.³ First, the injury was identified as primary if it resulted directly from the injury or secondary if it was due to abnormal articulation after dislocation of the proximal carpus. Next, it was classified as simple or complex, with the presence of any disruption to the distal carpal row qualifying as complex. The injury was then categorized as partial if soft tissue attachments or the distal scaphotrapezium articulation remained; a total dislocation lost all soft tissue attachment. The final category described the direction of the dislocation of the proximal pole, whether palmar, dorsal, or radial. In the palmar and dorsal directions, the deviation could also be in the radial, ulnar, or neutral direction.³ Using the classification system of Leung et al,³ this patient's injury would be classified as a primary, complex, partial, radial scaphoid dislocation.

A management algorithm for isolated scaphoid dislocation by classification of the injury has been described by Chloros.⁷ Early identification and closed reduction has been effective in the resolution of pain and restoration of active range of motion.² Plaster casting should be applied for at least 4 weeks post-reduction. In more complex dislocations or when identification of the isolated dislocation is delayed, the surrounding soft tissue often undergoes inflammatory changes that necessitate open reduction.³ The longer the delay in identification and reduction, the worse the prognosis.

Kirschner wires have been used after reduction to fix the carpals and improve stability of the joint, especially with persistent increased post-reduction widening of the S-L interval.^{7,10} However, outcomes appear to be similar with or without the use of percutaneous fixation in simple cases. As such, Kirschner wires may be best suited for cases in which identification and treatment is delayed.³ In patients with persistent joint instability after closed reduction, additional imaging studies should be considered to evaluate possible ligamentous damage, which may necessitate the need for ligamentous reconstruction.

There are few complications seen with isolated scaphoid dislocation. The most concerning complication is avascular necrosis of the scaphoid bone, although it has only been reported in 1 case that was identified 20 months post-operatively.¹⁰ Median nerve injury may also occur, although it is usually self-limiting after reduction of

the scaphoid.³ In rare cases, there may be a need for urgently performed carpal tunnel release.

Isolated scaphoid dislocations generally have a good prognosis, despite their rarity. Awareness and knowledge of management are essential for a good outcome in patients sustaining scaphoid dislocation. Even in atypical causative incidents, wrist injuries should undergo evaluation by a hand and wrist specialist with appropriate physical examination and imaging. If diagnosed early, closed reduction and casting is appropriate management as first line therapy, although surgical manipulation and fixation remain an option for more complex cases. When coupled with outpatient follow-up at close intervals and a multidisciplinary team, patients can have excellent outcomes after isolated carpal bone dislocation.

References

1. Amundsen A, Bishop SN, Moran SL. Isolated scaphoid dislocation: a case report and review of the literature. *J Wrist Surg.* 2020;9(5):431–439.
2. Buzby BF. Isolated radial dislocation of carpal scaphoid. *Ann Surg.* 1934;100(3):553–555.
3. Leung YF, Wai YL, Kam WL, Ip PS. Solitary dislocation of the scaphoid. From case report to literature review. *J Hand Surg Br.* 1998;23(1):88–92.
4. Al Kaissi A, Zwettler E, Ganger R, Schreiner S, Klaushofer K, Grill F. Musculoskeletal abnormalities in patients with Marfan syndrome. *Clin Med Insights Arthritis Musculoskelet Disord.* 2013;6:1–9.
5. Stevenson M, Levis JT. Image diagnosis: scapholunate dissociation. *Perm J.* 2019;23.
6. Higgs SL. Two cases of dislocation of carpal scaphoid. *Proc R Soc Med.* 1930;23(9):1337–1339.
7. Chloros GD, Themistocleous GS, Zagoreos NP, Korres DS, Efstathopoulos DG, Soucacos PN. Isolated dislocation of the scaphoid. *Arch Orthop Trauma Surg.* 2006;126(3):197–203.
8. Milankov M, Somer T, Jovanović A, Brankov M. Isolated dislocation of the carpal scaphoid: two case reports. *J Trauma.* 1994;36(5):752–754.
9. Carter C, Wilkinson J. Persistent joint laxity and congenital dislocation of the hip. *J Bone Joint Surg Br.* 1964;46:40–45.
10. Szabo RM, Newland CC, Johnson PG, Steinberg DR, Tortosa R. Spectrum of injury and treatment options for isolated dislocation of the scaphoid. A report of three cases. *J Bone Joint Surg Am.* 1995;77(4):608–615.