

Emergency extra-intracranial bypass surgery in a patient with neurologic deficit after an accident in carotid occlusive test: A case report.

Hung M Ngo

Hien T Trinh

Rocky Felbaum

Walter C. Jean MD

Lehigh Valley Health Network, walter.jean@lvhn.org

Follow this and additional works at: <https://scholarlyworks.lvhn.org/surgery>



Part of the [Medicine and Health Sciences Commons](#)

Published In/Presented At

Ngo HM, Trinh HT, Felbaum R, Jean W. Emergency extra-intracranial bypass surgery in a patient with neurologic deficit after an accident in carotid occlusive test: A case report. *Int J Surg Case Rep*. 2022 Apr 12;94:107071. doi: 10.1016/j.ijscr.2022.107071. Epub ahead of print. PMID: 35452942.

This Article is brought to you for free and open access by LVHN Scholarly Works. It has been accepted for inclusion in LVHN Scholarly Works by an authorized administrator. For more information, please contact LibraryServices@lvhn.org.



Case report

Emergency extra-intracranial bypass surgery in a patient with neurologic deficit after an accident in carotid occlusive test: A case report

Hung M. Ngo^{a,b,*}, Hien T. Trinh^c, Rocky Felbaum^{d,e}, Walter Jean^{f,e}^a Department of Neurosurgery, Viet Duc Hospital, Hanoi, Viet Nam^b Faculty of Medicine, University of Medicine and Pharmacy, Vietnam National University, Hanoi, Viet Nam^c Department of Radiology, K Hospital, Hanoi, Viet Nam^d Department of Neurosurgery, Georgetown University Hospital, Washington, DC, USA^e Global Brainsurgery Initiative, Washington, DC, USA^f Neurosurgery at Lehigh Valley Health Network, Allentown, PA, USA

ARTICLE INFO

Keywords:

Balloon test occlusion

Urgent extra-intracranial bypass

Large/giant cerebral aneurysms

Iatrogenic internal carotid artery injury

Case report

ABSTRACT

Objective: BTO is the procedure performed to assess the collateral circulation within the Willis circle in a giant ICA aneurysm. An ICA occlusion after BTO is very rare. We present a case of an internal carotid artery occlusion as a complication of BTO that required urgent revascularization surgery.

Case presentation: A 56-year-old female with a history of transient ischemic attacks for one year was diagnosed with multiple aneurysms: a giant aneurysm of the left supra-clinoid ICA, two small ones on left MCA and right ophthalmic. A BTO was performed to assess collateral supply and determine whether bypass surgery should be necessary. During the procedure, the balloon was detached while insufflating, and the patient had a subsequent neurological decline consistent with an MCA syndrome. EC-IC bypass surgery was performed with an end-to-side anastomosis of STA-MCA by trapping the giant aneurysm and clipping the ipsilateral MCA aneurysm. The patient had a reversal of neurological symptoms and made an uneventful recovery.

Discussion: We discuss the epidemiology of giant ICA aneurysms, the indications for BTO, and its complication. Emergency intracranial and extracranial bypass surgery in case of acute ICA injury is also discussed. We also highlighted the attributable factors to treatment strategies under restrictive conditions in Vietnam.

Conclusions: ICA occlusion due to insufflated balloon detachment is an unreported complication in literature. Emergency bypass surgery is a potential treatment choice for this unusual iatrogenic complication.

1. Introduction

Giant intracranial aneurysms make up roughly 5% of all intracranial aneurysms. Treatment of giant aneurysms via open or endovascular therapy involves deconstructive or reconstructive techniques [1].

To determine the most suitable treatment strategy, a balloon test occlusion (BTO) can be utilized to assess the cerebrovascular collateral reserve to determine the necessity of bypass surgery [2].

We report a case that developed ICA occlusion after BTO with neurological deficiency and was resolved by an emergency bypass

surgery. Approval to conduct the study was obtained from the committee of the Viet-Duc hospital, Vietnam (Decision no. 818/QĐ-VĐ, May 4, 2020).

This case report has been reported in line with the SCARE criteria [3].

2. Case presentation

A 56-year-old female presented with a mild subacute headache. Work-up at a provincial hospital with an MRA revealed several

Abbreviations: BTO, balloon test occlusion; ICA, internal carotid artery; MCA, middle cerebral artery; M1, sphenoidal or horizontal segment of middle cerebral artery; M2, insular segment; EC-IC, extracranial-intracranial; STA-MCA, superficial temporal artery-middle cerebral artery; MRA, magnetic resonance angiography; CTA, computer tomographic angiography; CT, computer tomography; ICU, intensive care unit; DSA, digital subtraction angiography; GOS, Glasgow outcome scale; mRS, modified Rankin scale; LMIC, low-middle income country; AComA, anterior communicating artery.

* Corresponding author at: Department of Neurosurgery II, Viet Duc Hospital, 40 Trang Thi, Hoan Kiem, Hanoi, Viet Nam; Faculty of Medicine, University of Medicine and Pharmacy, Vietnam National University, Hanoi, Viet Nam.

E-mail addresses: ngomanhhung2000@gmail.com (H.M. Ngo), Walter.jean@lvhn.org (W. Jean).

<https://doi.org/10.1016/j.ijscr.2022.107071>

Received 19 February 2022; Received in revised form 7 April 2022; Accepted 8 April 2022

Available online 12 April 2022

2210-2612/© 2022 The Authors. Published by Elsevier Ltd on behalf of IJS Publishing Group Ltd. This is an open access article under the CC BY-NC-ND license (<http://creativecommons.org/licenses/by-nc-nd/4.0/>).

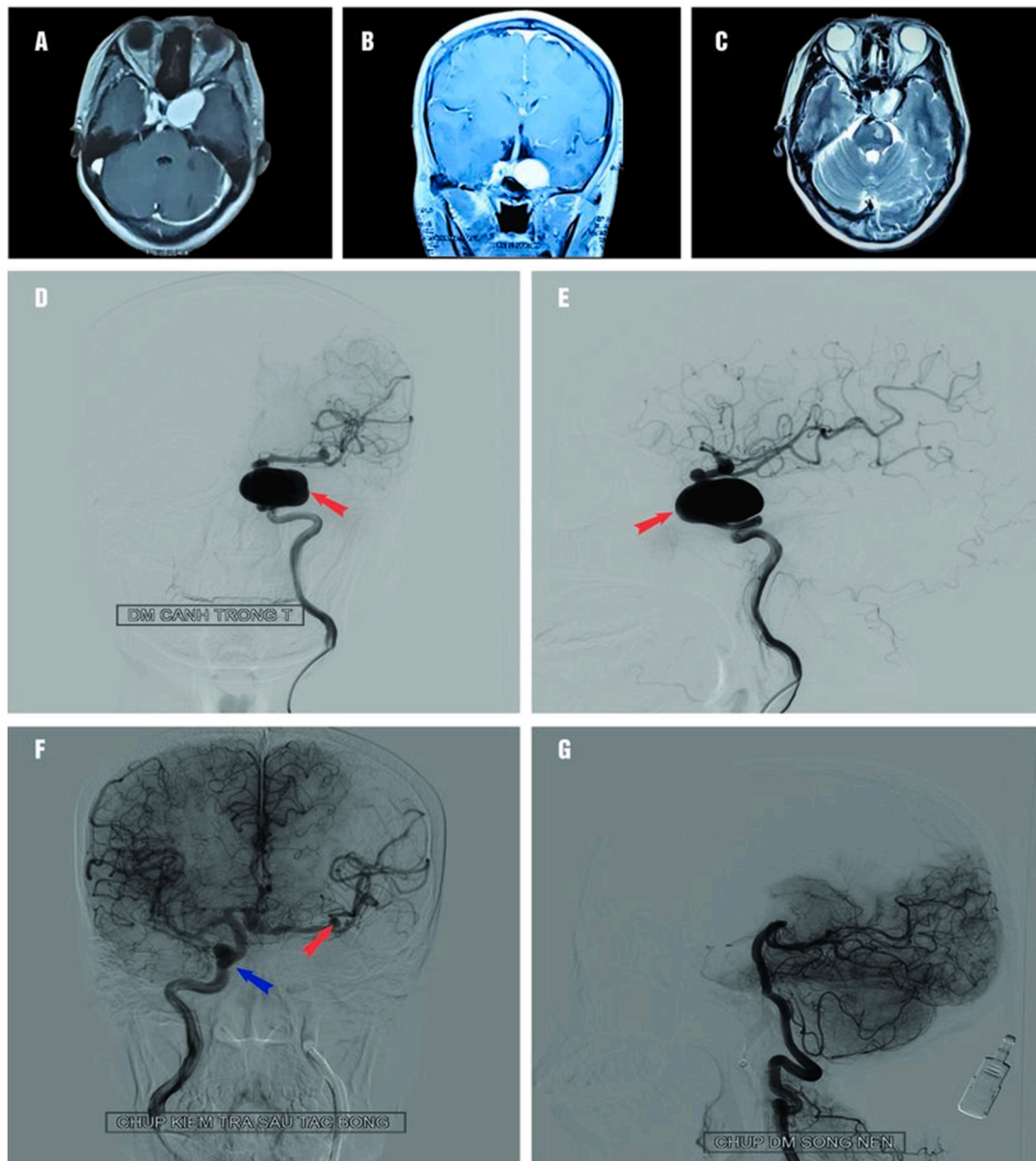


Fig. 1. A, B: MRI demonstrated a heterogeneous lesion at the cavernous ICA with vivid enhancement after gadolinium injection. C: A T2 weighted image demonstrates the partially thrombosed aneurysm.

D, E: DSA before BTO. D, E: AP and lateral view on conventional DSA images of left ICA reveal a giant left supra-clinoid aneurysm (red arrow) and a small left MCA aneurysm. The hemisphere appears isolated without an AComA or PComA complex.

F and G: DSA after left ICA occlusion. F: The right ICA injection showed excellent cross filling of the AComA complex in the left MCA territory. The right ophthalmic artery aneurysm (blue arrow) and middle cerebral artery aneurysm (red arrow) are also seen in this view. G: The DSA of posterior circulation from the left lateral view illustrated the cerebellum's excellent blood flow.

intracranial aneurysms. She was transferred to our teaching hospital for further management and formal cerebral angiography. Angiography showed a right ophthalmic artery aneurysm with a maximum diameter of 12 mm. More dangerously, it showed a giant supra-clinoid ICA aneurysm (32 mm in maximum diameter) and a small irregularly shaped left MCA aneurysm (Fig. 1D and E).

After a multi-disciplinary discussion, we recommended a BTO under local anesthetic [5] and used a detachable balloon (Goldbal4 Balt Extrusion, France). The detachable Balt balloon catheter needs 0.7 ml of contrast agent to detach. We used 0.2 ml of contrast agent during the procedure, and the patient tolerated it without issues. The left hemisphere was cross-filled from the anterior communicating artery segment (Fig. 1F). Unfortunately, the balloon was detached during extraction.

After approximately 1.5 h of temporary ICA occlusion, a second balloon was deployed to complete the parent artery occlusion (Fig. 1F and G). After 1.5 h of follow-up, she developed a left MCA syndrome, including impaired consciousness (Glasgow Coma Scale 11), confusion, aphasia, and right hemiparesis. The patient was taken emergently for bypass revascularization after confirmation of the left MCA hypoperfusion on a CT scan.

2.1. Operative course

A standard frontotemporal curvilinear incision was employed with a pterional craniotomy with care to harvest the donor graft. After a standard Sylvian fissure dissection, the M1 and M2 segments of the MCA

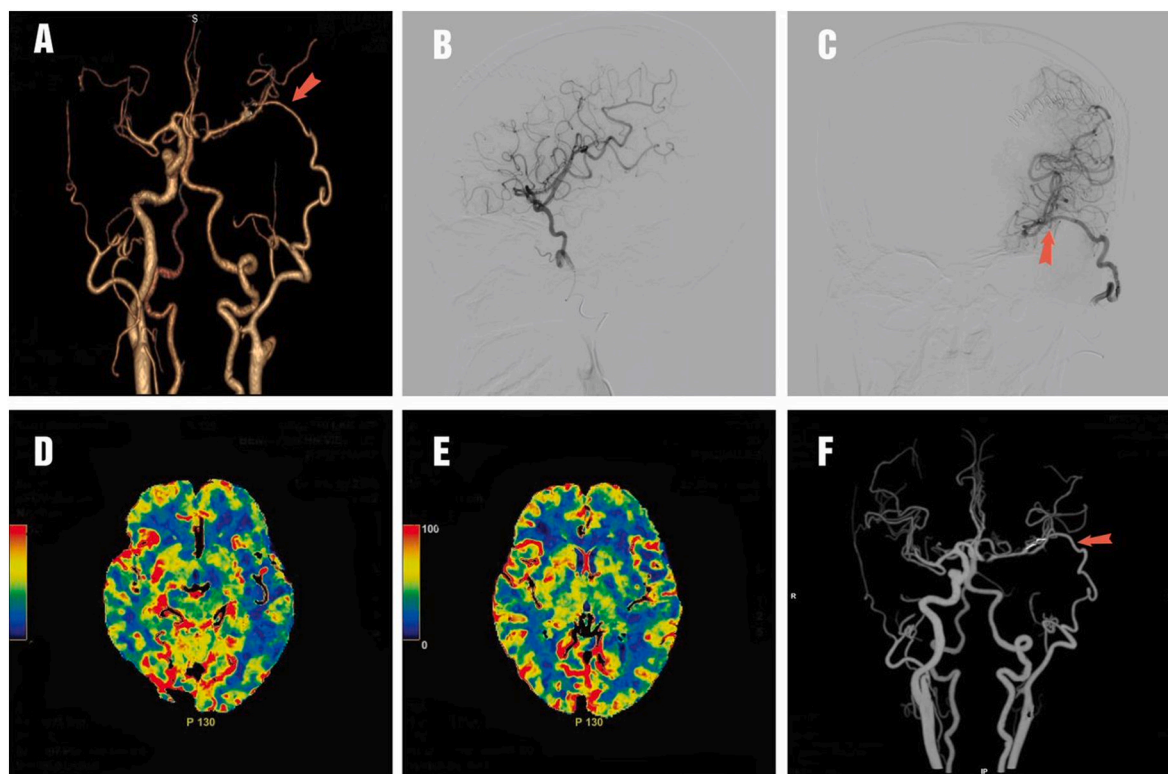


Fig. 2. The CTA (A) and selected DSA (B, C) series after emergency bypass surgery showed good graft patency (red arrow). D, E, F: The CTA and CT perfusion after one month showed good graft patency (F; red arrow), and the color-coded map showed no reduction in the flow on the left as compared to the right side (D and E).

were exposed. A straight clip clipped the M1 aneurysm. The STA-MCA bypass (STA to M2-MCA) was then completed after that.

After the bypass was completed, a clip was placed just distal to the aneurysm neck to complete the aneurysm trapping.

Her ICU management consisted of a low dose heparin drip (10 UI/kg/24 h) for the first three days, followed by Lovenox® IV 1 ampule/day for three days and aspirin 81 mg oral for the following month.

2.2. Postoperative course

Post-operatively, the patient returned to her neurologic baseline, with a resolution of her motor symptoms by day five and near-resolution of her aphasia by day 18. The immediate post-operative CTA demonstrated patency of the bypass (Fig. 2A). The delayed DSA at two weeks confirmed bypass patency with obliteration of her aneurysms (Fig. 2B and C). The perfusion CT after one month showed some small ischemic zones at the left temporal lobe (Fig. 2D, E, and F) without any deficient neurology. After a six-month follow-up, the patient came to us with normal physical health (GOS: 5, mRS: 0); she had no aphasia or hemiparesis. The patient refused to have a CTA.

3. Discussion

Giant aneurysms are reported to occur at approximately 5% of all aneurysms and carry the highest annual risk of rupture rate is as high as 40% [4].

Although endovascular therapy is becoming more widely utilized [5,6], in developing countries, the prohibitive cost of endovascular therapy results in open cerebrovascular surgery being the primary option.

Surgical approaches for giant aneurysms include reconstructive techniques (clip reconstruction, aneurysmorrhaphy, or surgical bypass) [7], or deconstructive techniques (parent artery occlusion, trapping, or

wrapping) [8].

Balloon test occlusion (BTO) of the internal carotid artery is a technique used to evaluate the collateral circulation's efficacy in the circle of Willis. Classically, BTO is used to determine if parent artery sacrifice can be safely performed. In our institution, we perform a BTO routinely as it can help determine the need for low bypass versus high bypass surgery, like the report of Nussbaum [9]. Patients whose clinical status and neuroimaging are inappropriate indicate high-flow bypass; otherwise, the low-flow bypass would be chosen. Others do not have either clinical status or neuroimaging appropriately; low-flow bypass could be used with the consideration of STA diameter. However, we still prioritize the high-flow bypass [2]. Given the initial absence of good collateral supply from the left ICA injection (Fig. 2), it can be argued that a BTO should not have been attempted, and a high flow bypass should have been the first treatment option.

The figure for BTO-related complications was reported as up to 3.7%, including internal carotid artery dissection and permanent neurologic deficit [10]. Mathis et al. also described the proportion of carotid dissection, embolus, and the permanent neurologic deficit as 1.2, 0.2, and 0.4%, respectively [11]. The complication balloon catheter is the first reported case to our best knowledge. Not preferential to use a detachable balloon; due to financial constraints, no other balloons were available.

In the classical basic BTO technique, the patient was performed under local anesthesia, monitored clinically every 5 min, and lasted 30 min. If there is no change in the patient's neurological symptoms for 30 min, it is believed that artery occlusion can be performed [12]. However, it seems that this is not enough. Galego et al. reported a case in which Transcranial Color-coded Doppler and electroencephalographic change monitored blood flow [13]. MRA was used to predict the outcome of [14]. Ikemura et al. recently reported 12 cases using the SPECT technique (99mTc-ethyl cysteinate dimer) and FD-CBV to assess a patient's condition [15]. Under our limited resources, patients can only

Table 1
Literature review for urgent EC-IC bypass.

Authors	No of reference	No. patients	Type of injury	Location	Type of bypass
Lee, C.Y	[16]	1	Acute cerebral ischemia	MCA occlusion	STA-MCA bypass
Mracek	[17]	1	Acute cerebral ischemia	ICA stenosis	STA-MCA bypass
Krayenbuhl	[18]	16	Heterogenesis - During clipping: 11 - Refractory vasospasm: 5	ICA: 5 PComA: 1 AComA: 1 A2: 2 M2: 1	STA-MCA bypass
Nussbaum	[19]	13	Acute cerebral ischemia	ICA dissection: 5 ICA dissection extending into M1: 4 M1 dissection: 2 M1 stenosis: 1 ICA stenosis: 1	STA-MCA bypass
Chen Y	[20]	1	Iatrogenic	ICA	High flow
Range-Castilla	[21]	8	Iatrogenic	ICA	High flow
Kimura	[24]	35	Progressive stroke	No definition	STA-MCA bypass

MCA: middle cerebral artery.

STA: superficial temporal artery.

ICA: internal cerebral artery.

PcomA: posterior communicating artery.

AComA: anterior communication artery.

M1: first segment of middle cerebral artery.

M2: second segment of middle cerebral artery.

A2: second segment of anterior cerebral artery.

be performed the BTO with the basic technique.

Emergent EC-IC bypass is rarely employed nowadays [16–19]. It can be categorized into giant ruptured ICA/MCA aneurysms not amenable to classic reconstructive techniques or blister aneurysms and those with iatrogenic damage to the ICA/MCA (Table 1). Our case is classified as an iatrogenic ICA injury, and to our knowledge, this is the first reported case in the literature.

In case of carotid artery damage during surgery, the surgical bypass will be performed immediately, either as a high-flow bypass with a saphenous graft [20,21] or in the form of STA-MCA bypass [16,22]. The sooner the reperfusion time is, the better the outcome is, although Weis-Muller has reported this time may be up to one week [23]. However, all cases in the Weis-Muller study were caused by intracranial atherosclerotic disease with an acute occlusion. Our patient manifested acute occlusion of ICA, similar to direct injury cases to the carotid artery during surgery by Chen Y [20] and Rangel-Castilla [21]. The onset of symptoms and performing bypass surgery ranges from 6 to 24 h after the first surgery [21]. In our case report, the time from onset to treatment initiation was 3.5 h.

For internal carotid artery damage caused by surgery, both Chen Y [20] and Range-Castilla [21] chose high-flow bypass for brain reperfusion. With an ICA giant aneurysm, Ishishita et al. performed high-flow bypass surgery without using BTO [8]. All three authors had selected a high-flow bypass. In our case, an STA-MCA bypass for the following reasons: (1) the patient tolerated a prolonged BTO; (2) due to excellent cross-fill from the AComA complex and an MCA syndrome, we felt that

revascularizing the MCA territory would be sufficiently covered by the STA.

An emergent CTA helped determine if this was a thromboembolic injury or hypoperfusion injury. As this resource is not available in our setting, the emergent bypass was elected after a trial of raising her blood pressure was completed with persistent MCA syndrome.

4. Conclusions

Emergency ICA occlusion after BTO with a detachable balloon is an uncommon complication, but it can occur in LMIC. STA-MCA surgery should be performed for patients whose ICA occlusion with neurological deficiency. This is effective and safe produce.

Consent to participate

The patient's parents have consented to the submission of the case report for submission to the journal. Written consent form is available upon request.

Consent to publication

Not applicable.

Availability of data and material

Data is available upon reasonable request and with permission of Viet Duc Hospital. No patient or author details are included in the figures.

Provenance and peer review

Not commissioned, externally peer-reviewed.

Ethical approval

The study was approved by the Research Ethics Committee of Viet-Duc hospital, Vietnam. The procedures used in this study adhere to the tenets of the Declarations of Helsinki.

Funding

The authors declare no funding for this study.

Guarantor

Hung Manh NGO, MD, PhD.

Research registration number

1. Name of the registry: N/A¹
2. Unique identifying number or registration ID: N/A¹
3. Hyperlink to your specific registration (must be publicly accessible and will be checked): N/A.¹

CRedit authorship contribution statement

Hung Manh Ngo: the main doctor conceived the original idea and operated the manuscript.

Hien Thi Trinh: followed up and wrote the manuscript.

Rocky Felbau: data curation, followed up, revised manuscript.

Walter Jean: assessed the protocol, summed up, and revised the manuscript.

¹ Exempt: not a first-man-case report.

All authors contributed to the interpretation of the results and discussed the results. All authors read and approved the final manuscript to submit.

Declaration of competing interest

The authors declare that they have no conflicts of interest.

References

- [1] B.G. Thompson, et al., Guidelines for the management of patients with unruptured intracranial aneurysms: a guideline for healthcare professionals from the American Heart Association/American Stroke Association, *Stroke* 46 (8) (2015) 2368–2400.
- [2] H.M. Ngo, L.H. Nguyen, L.V. Nguyen, Extracranial – intracranial bypass surgery for large and complex cerebral aneurysms: an institutional experience in Vietnam, *Interdiscip. Neurosurg.* 23 (2021), 100941.
- [3] R.A. Agha, et al., The SCARE 2020 guideline: updating consensus Surgical CAse REport (SCARE) guidelines, *Int. J. Surg.* 84 (2020) 226–230.
- [4] D.O. Wiebers, et al., Unruptured intracranial aneurysms: natural history, clinical outcome, and risks of surgical and endovascular treatment, *Lancet* 362 (9378) (2003) 103–110.
- [5] N.R. Gonzalez, et al., Challenges in the endovascular treatment of giant intracranial aneurysms, *Neurosurgery* 59 (5 Suppl. 3) (2006) S113–S124, discussion S3–13.
- [6] S. Bracard, et al., Endovascular treatment of giant intracranial aneurysms, *Neurochirurgie* 62 (1) (2016) 25–29.
- [7] Y. Kubo, et al., Revascularization and parent artery occlusion for giant internal carotid artery aneurysms in the intracavernous portion using intraoperative monitoring of cerebral hemodynamics, *Neurosurgery* 58 (1) (2006) 43–50, discussion 43–50.
- [8] Y. Ishishita, et al., Universal extracranial-intracranial graft bypass for large or giant internal carotid aneurysms: techniques and results in 38 consecutive patients, *World Neurosurg.* 82 (1–2) (2014) 130–139.
- [9] E.S. Nussbaum, et al., Cerebral revascularization for the management of complex intracranial aneurysms: a single-center experience, *J. Neurosurg.* (2018) 1–11.
- [10] R.W. Tarr, et al., Complications of preoperative balloon test occlusion of the internal carotid arteries: experience in 300 cases, *Skull Base Surg.* 1 (4) (1991) 240–244.
- [11] J.M. Mathis, et al., Temporary balloon test occlusion of the internal carotid artery: experience in 500 cases, *AJNR Am. J. Neuroradiol.* 16 (4) (1995) 749–754.
- [12] A.E. Elias, et al., Intracranial endovascular balloon test occlusion: indications, methods, and predictive value, *Neuroimaging Clin. N. Am.* 23 (4) (2013) 695–702.
- [13] O. Galego, et al., Monitoring balloon test occlusion of the internal carotid artery with transcranial Doppler. A case report and literature review, *Neuroradiol. J.* 27 (1) (2014) 115–119.
- [14] N. Fukuhara, et al., Magnetic resonance angiography-based prediction of the results of balloon test occlusion, *Neurol. Med. Chir. (Tokyo)* 59 (10) (2019) 384–391.
- [15] A. Ikemura, et al., Evaluation of balloon test occlusion before therapeutic carotid artery occlusion: flat detector computed tomography cerebral blood volume imaging versus single-photon emission computed tomography, *World Neurosurg.* 133 (2020) e522–e528.
- [16] C.Y. Lee, et al., Urgent bypass surgery following failed endovascular treatment in acute symptomatic stroke patient with MCA occlusion, *Neurologist* 22 (1) (2017) 14–17.
- [17] J. Mracek, et al., Urgent extracranial-intracranial bypass in the treatment of acute hemodynamic ischemic stroke: case report, *J. Neurol. Surg. A Cent. Eur. Neurosurg.* 74 (5) (2013) 325–331.
- [18] N. Krayenbuhl, et al., Emergency extra-intracranial bypass surgery in the treatment of cerebral aneurysms, *Acta Neurochir. Suppl.* 103 (2008) 93–101.
- [19] E.S. Nussbaum, et al., Emergency extracranial-intracranial bypass surgery for acute ischemic stroke, *J. Neurosurg.* 112 (3) (2010) 666–673.
- [20] Y. Chen, et al., Emergency extracranial-intracranial bypass during surgery for anterior clinoid process hemangiopericytoma with ICA invasion—case report, *J. Neurol. Disord.* 3 (2) (2015).
- [21] L. Rangel-Castilla, et al., Urgent cerebral revascularization bypass surgery for iatrogenic skull base internal carotid artery injury, *Neurosurgery* 10 (Suppl. 4) (2014) 640–647, discussion 647–8.
- [22] A.D. Nguyen, et al., STA-MCA bypass following sphenoid wing meningioma resection: a case report, *Int. J. Surg. Case Rep.* 59 (2019) 132–135.
- [23] B.T. Weis-Muller, et al., Time is brain?—surgical revascularization of acute symptomatic occlusion of the internal carotid artery up to one week, *Ann. Vasc. Surg.* 27 (4) (2013) 424–432.
- [24] T. Kimura, Y. Ichikawa, T. Inoue, Safety and clinical outcomes of urgent superficial temporal artery-middle cerebral artery bypass—a single-institution retrospective analysis, *Acta Neurochir.* 162 (6) (2020) 1325–1331.