

Case of Altered Mental Status Secondary to Hypercalcemia from Granulomatous Reaction to Silicone Injections

Elizabeth Kim DO

Shanthi P. Lewis MD

Follow this and additional works at: <https://scholarlyworks.lvhn.org/posters>



Part of the [Medicine and Health Sciences Commons](#)

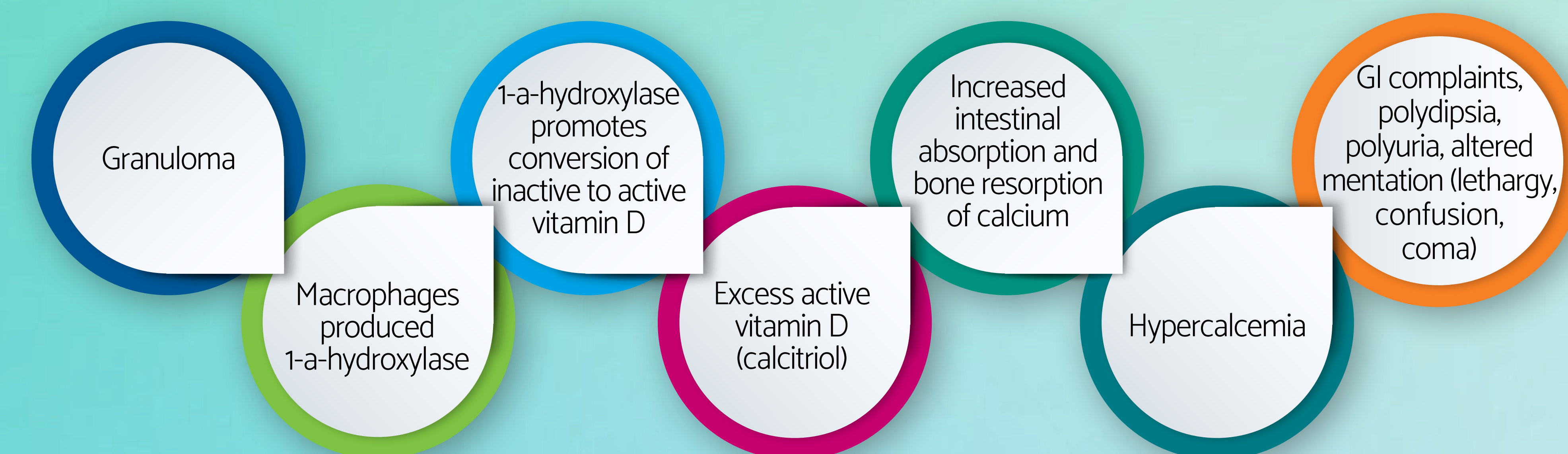
This Article is brought to you for free and open access by LVHN Scholarly Works. It has been accepted for inclusion in LVHN Scholarly Works by an authorized administrator. For more information, please contact LibraryServices@lvhn.org.

Case of Altered Mental Status Secondary to Hypercalcemia from Granulomatous Reaction to Silicone Injections

Elizabeth Kim, DO and Shanthi Lewis, MD
Lehigh Valley Health Network, Allentown, Pa.

Introduction

Reported cases of hypercalcemia from silicone-induced granulomas have been increasing over the last decade.²



- Hypercalcemia from cosmetic surgery is a rare but potentially emerging cause of delirium.
- We present a case of hypoactive delirium from hypercalcemia secondary to granulomatous reaction to silicone injections.

Case Presentation

- Patient was a 39-year-old Hispanic woman with history of gluteal silicone injections 20 years prior.
- She presented with gastrointestinal symptoms, cachexia, anorexia, withdrawn behavior, and dysphoric affect.
- Psychiatry was consulted to evaluate for possible depression and eating disorder.

- On exam, she was dysphoric, lethargic, and confused with waxing and waning alertness.
- She denied any psychiatric history and was reluctant to discuss psychological matters.
- She denied symptoms meeting criteria for MDD, eating disorder, and body dysmorphic disorder.
- EEG revealed encephalopathy.
- Calcium, calcitriol, and PTHrP were elevated, while PTH was low.
- Imaging showed calcifications in gluteal and thigh regions – the sites of her silicone injections.
- She was diagnosed with hypoactive delirium secondary to hypercalcemia from silicone-induced granulomas.
- Aripiprazole was initiated to improve mentation, mood, and energy to good effect.
- However, she became noncompliant as she denied needing psychotropic medications.
- Her calcium levels remained high (12.6, ionized 1.59), and her cachexia worsened over time.
- Although medically unstable with persisting delirium, she was brought home by family against medical advice.

Lab	Patient's Value	Ref
Calcium	17.2	8.5–10.1
Calcium, ionized	1.89	1.18–1.32
Calcitriol	280	19.9–9.3
PTHrP	8.0	0.0–3.4
PTH	9.6	18.5–88.0

Discussion

- Silicone-induced granulomas is an unusual but rising cause of hypercalcemia.
- Unfortunately, treatment is often difficult and noncurative.
 - Mainstay treatment with fluids and steroids temporarily improves hypercalcemia.²
 - Excising the granulomas often fails as granulomas migrate.⁴
- Both medical and surgical treatments were unsuccessful for our patient.
- Studies show that neuropsychiatric disturbances may persist even when hypercalcemia resolves,³ but aripiprazole may improve hypoactive delirium¹ as briefly seen in our patient.

Conclusion

- Cases of granulomatous reactions to silicone injections are rare but increasing.
- Therefore, all CL psychiatrists should consider hypercalcemia from granulomatous reactions in patients with prior cosmetic surgeries presenting with altered mentation.
- Although delirium can persist after correcting hypercalcemia, aripiprazole may be used supportively for hypoactive delirium.

REFERENCES

- ¹Boettger, S., & Breitbart, W. (2011). An open trial of aripiprazole for the treatment of delirium in hospitalized cancer patients. *Palliative and Supportive Care*, 9(4), 351-357. doi:10.1017/s1478951511000368
- ²Dangol, G. M., & Negrete, H. (2019). Silicone-induced granulomatous reaction causing severe hypercalcemia: Case report and literature review. *Case Reports in Nephrology*, 2019, 1-6. doi:10.1155/2019/9126172
- ³Melnick, S., Abaroa-Salvatierra, A., Deshmukh, M., & Patel, A. (2016). Calcitriol mediated hypercalcaemia with silicone granulomas due to cosmetic injection. *BMJ case reports*, 2016, bcr2016217269. https://doi.org/10.1136/bcr-2016-217269
- ⁴Yedla, N., Perez, E., Lagari, V., & Ayala, A. (2019). Silicone granulomatous inflammation resulting in hypercalcemia: A review of the literature. *AACE Clinical Case Reports*, 5(2). doi:10.4158/accr-2018-0277