

EVALI During the COVID-19 Pandemic: A Needle in the Ground Glass

Derek J. Fikse DO

Alexandra Amaducci DO

Kenneth D. Katz MD

Matthew Nimmo DO

Follow this and additional works at: <https://scholarlyworks.lvhn.org/posters>



Part of the [Medicine and Health Sciences Commons](#)

This Article is brought to you for free and open access by LVHN Scholarly Works. It has been accepted for inclusion in LVHN Scholarly Works by an authorized administrator. For more information, please contact LibraryServices@lvhn.org.

EVALI During the COVID-19 Pandemic: A Needle in the Ground Glass

Derek J. Fikse, DO; Alexandra Amaducci, DO; Kenneth Katz, MD; Matthew Nimmo, DO
Lehigh Valley Health Network, Department of Emergency and Hospital Medicine/USF Morsani College of Medicine, Allentown, Pa.

Background

COVID-19 pneumonitis has become a predominant respiratory diagnosis in the Emergency Department (ED). Consequently, other disease processes could be overlooked – especially in younger patients – including E-cigarette or Vaping Product Use-Associated Lung Injury (EVALI). A case of a patient with EVALI mistaken for COVID-19 is presented.

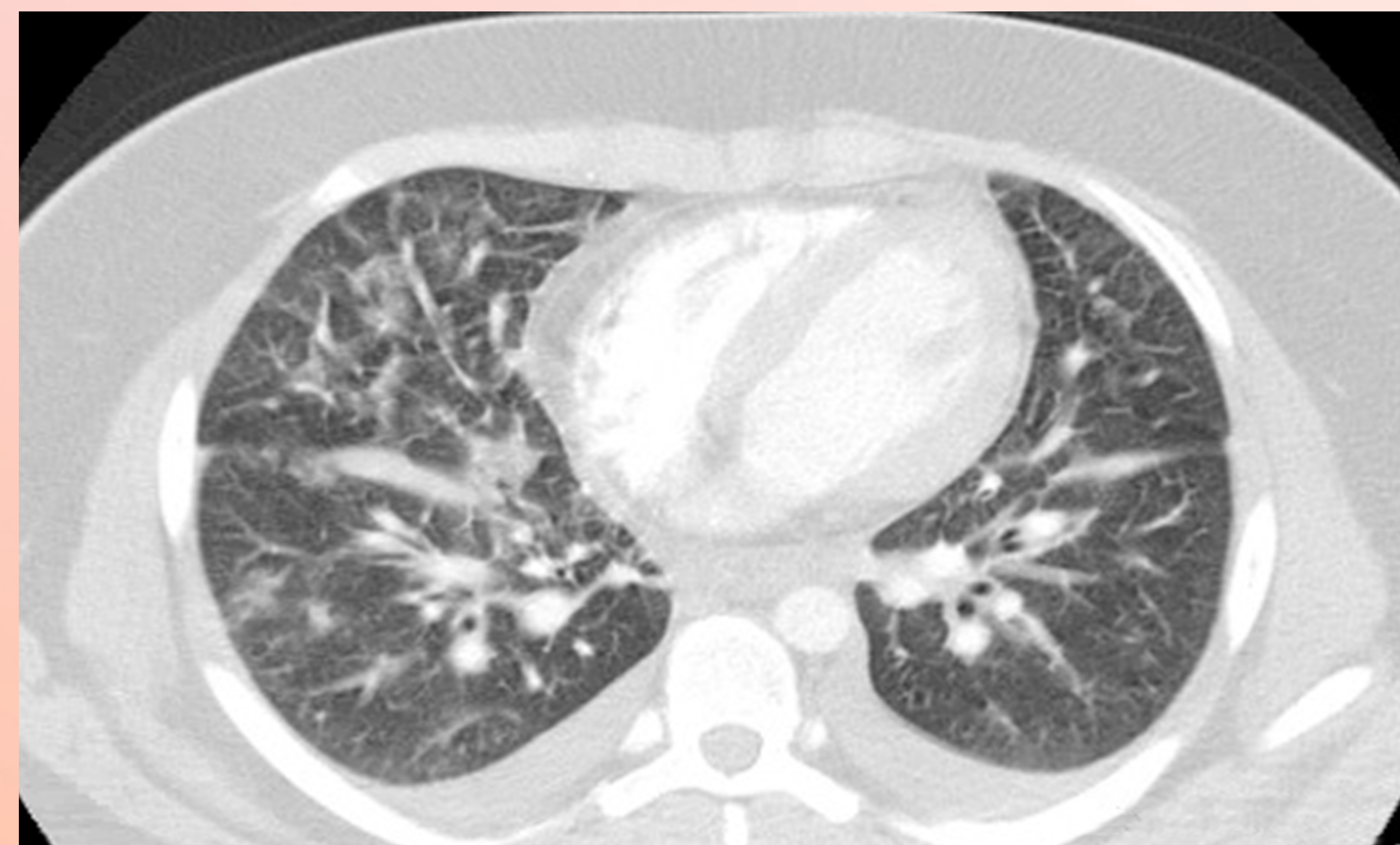

Figure 1

Case Description

A 16-year-old boy with past medical history of asthma presented to the ED with dyspnea and cough of abrupt onset 24 hours prior to ED visit. He had been using his home albuterol without improvement. There were no known sick contacts, but patient was employed at a chain restaurant. Notable vital signs included: heart rate 116 beats per minute, respiratory rate 32, room air pulse oxygenation 90% (with a change to 99% on high flow nasal canula 40L/50%), temperature 100.2°F. Chest x-ray demonstrated bilateral pulmonary infiltrates concerning for multifocal pneumonia and possible evolving acute respiratory distress syndrome (ARDS). Chest computerized tomography (CT) scan revealed: “Diffuse bilateral ground glass opacities. Considerations include viral and atypical pneumonia, including COVID-19 pneumonitis.” Notable blood work included: white blood cell count 19.4 thou/cm

(reference 3.8-10.4 thou/cm) and troponin I 0.27 ng/mL (<0.03 ng/ml). Both urine drug screen of abuse and serum liquid chromatography – mass spectrometry (LC-MS) detected tetrahydrocannabinol (THC). Patient was admitted to the pediatric intensive care unit with presumptive diagnosis of COVID-19 infection. On hospital day (HD) 1 patient was transitioned to BiPAP for worsening tachypnea. Blood culture, urine legionella, and respiratory viral panel (including COVID-19) returned negative. Respiratory viral panel was repeated and again returned negative. Upon further inquiry, patient reported vaping on the day his symptoms began and smoking cannabis regularly. Treatment remained supportive with supplemental oxygen and intermittent albuterol/ipratropium nebulization. Patient was weaned from oxygen by HD 5 and discharged in stable condition on HD 6.

Discussion

EVALI is defined as recent vaping use with development of pulmonary infiltrates on chest imaging in the absence of another identifiable cause. Although EVALI is associated with vape liquid containing THC and vitamin E acetate, no single agent has been definitively implicated. Typically, EVALI is associated with counterfeit or user filled cartridges. However, this patient reported a single use vape pen purchased from a convenience store. EVALI treatment is primarily supportive with supplemental oxygen, bronchodilators, steroids, and vaping cessation.

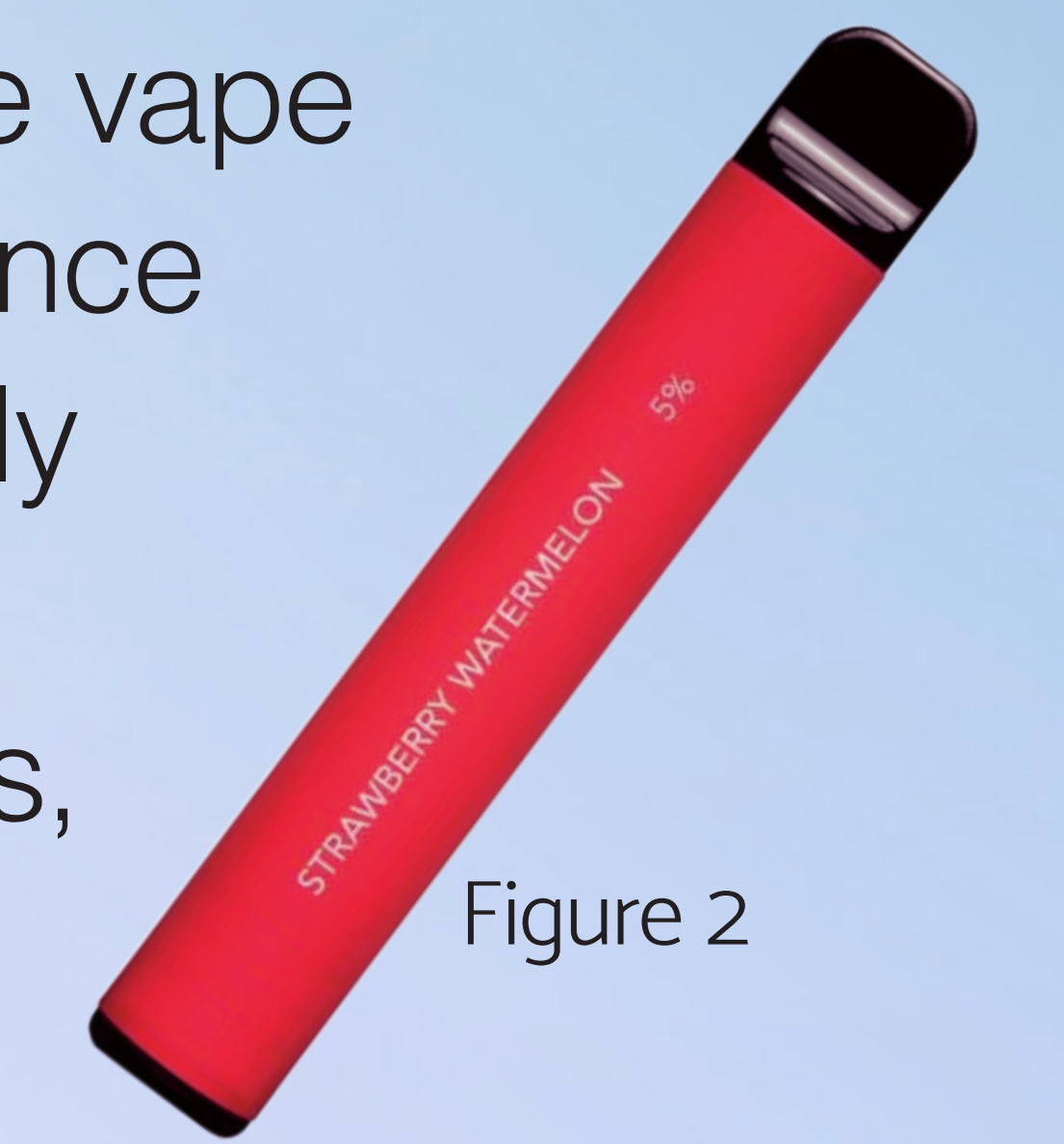


Figure 2

Conclusion

Despite COVID-19, it is imperative to obtain a detailed social history and to maintain a broad differential in patients with acute respiratory complaints.