





Giant luteinized follicular cyst of pregnancy

Cisto folicular luteinizado gigante da gestação

Taíssa Fernandes Lemes¹ , Sheila Jorge Adad² , Eddie Fernando Candido Murta¹ ,
Rosekeila Simões Nomelini¹ 

ABSTRACT

Functional cysts usually do not cause symptoms or require surgical intervention. We reported a 17-year-old primigravida, gestational age of 10 weeks and 2 days, and ultrasound showing anechoic cyst in the right parauterine region without septa, with a larger diameter of 13.5cm, 632ml, and Doppler color without peripheral vascularization. The patient was oligosymptomatic during gestation. At 37 weeks and 6 days, gestation was interrupted, when the cyst had 2600 ml by ultrasonography. Fetal extraction was performed by cesarean delivery, and a large adnexal cyst visualized on the right was removed. The histopathological analysis of the surgical specimen revealed a cystic lesion coated by luteinized cells with discrete hyperchromatic and slightly pleomorphic nuclei, with underlying fibrous stroma with sparse luteinized cells, characterizing a giant luteinized follicular cyst of pregnancy. The prevalence of ovarian masses in pregnancy is rare, usually not exceeding 5 cm in diameter, and disappearing spontaneously in the second trimester. The patient in the case report had a cyst of 632 ml, increasing in volume to 2600 ml at the time of delivery. Definitive preoperative diagnosis of ovarian masses is still difficult, and predictive criteria for malignancy include the use of tumor markers, ultrasound, and Doppler. The association of these tests should guide the clinician to define the best time for surgical intervention. The association of these tests should guide the clinician to define the best time for surgical intervention.

Keywords: Follicular cyst, Ovarian cys, Pregnancy.

RESUMO

Os cistos funcionais geralmente não causam sintomas ou requerem intervenção cirúrgica. Relatamos o caso de uma primigesta de 17 anos, idade gestacional de 10 semanas e 2 dias, e ultrassonografia mostrando cisto anecoico em região parauterina direita sem septos, com maior diâmetro de 13,5cm, volume 632ml e Doppler sem vascularização periférica. A paciente permaneceu oligossintomática durante a gestação. Com 37 semanas e 6 dias, a gestação foi interrompida, quando o cisto apresentava 2.600 ml pela ultrassonografia. A extração fetal foi realizada por cesariana, e um grande cisto anexial visualizado à direita foi removido. A análise histopatológica da peça cirúrgica revelou lesão cística revestida por células luteinizadas com núcleos discretamente hiper Cromáticos e levemente pleomórficos, com estroma fibroso subjacente com células luteinizadas esparsas, caracterizando cisto folicular luteinizado gigante da gravidez. A prevalência de massas ovarianas na gravidez é rara, geralmente não ultrapassam o diâmetro de 5 cm, e desaparecem espontaneamente no segundo trimestre. A paciente do relato de caso apresentou cisto de 632 ml, aumentando de volume para 2600 ml no momento do parto. O diagnóstico pré-operatório definitivo de massas ovarianas ainda é difícil, e os critérios preditivos de malignidade incluem o uso de marcadores tumorais, ultrassonografia e Doppler. A associação desses testes deve orientar o clínico para definir o melhor momento para a intervenção cirúrgica.

Palavras-chave: Cisto folicular, Cisto ovariano, Gravidez.

INTRODUCTION

The prevalence of ovarian masses in pregnancy is 0.19 to 8.8%, and the prevalence of malignancy varies from 0 to 6.8%.¹ Functional cysts

are benign and do not usually cause symptoms or require surgical intervention. They are commonly characterized by cystic masses below 5 cm, are detected up to the 16th week of gestation, and disappear spontaneously by the second trimester.^{2,3}

¹ Department of Gynecology and Obstetrics. Research Institute of Oncology (IPON)

² Federal University of Triângulo Mineiro. Discipline of Special Pathology, Uberaba, (MG), Brazil.



We reported a primigravida whose diagnosis was giant luteinized follicular cyst of pregnancy and we emphasize the importance of the association of tumor markers, ultrasonography and Doppler in the evaluation of adnexal masses.

CASE REPORT

A 17-year-old primigravida, gestational age of 10 weeks and 2 days, was evaluated by the services of Pelvic Mass and Fetal Medicine of the Federal University of Triângulo Mineiro by right adnexal mass. The patient complained of pain in the right iliac fossa. Ultrasound showed anechoic cyst in the right parauterine region without septa, with a larger diameter of 13.5cm, 632ml, and Doppler color without peripheral vascularization. The values of tumor markers were CA125 = 12.48U/ml; CA15.3 = 10.04U/ml; CA19.9 = 28.58U/ml, and alpha - fetoprotein = 36.04ng/ml. Ultrasonography performed at 18 weeks

showed an increase in the cystic volume (805ml) maintaining characteristics of benignity, being performed expectant management with serial ultrasound and prenatal follow-up.

The patient remained oligosymptomatic during gestation. At 37 weeks and 6 days, it was decided to interrupt gestation. Cyst had 2600 ml by ultrasonography. After fetal extraction by cesarean delivery, a large adnexal cyst was visualized on the right, extending to the epigastric region. The right ovary was removed, with preservation of the left ovary. The macroscopy of the surgical specimen showed a cyst with a diameter of 21cm and a weight of 435g. The content was citrus yellow, partly liquid, partly gelatinous. The histopathological analysis of the surgical specimen revealed a cystic lesion coated by luteinized cells with discrete hyperchromatic and slightly pleomorphic nuclei, with underlying fibrous stroma with sparse luteinized cells, characterizing a giant luteinized follicular cyst of pregnancy (Figure 1).

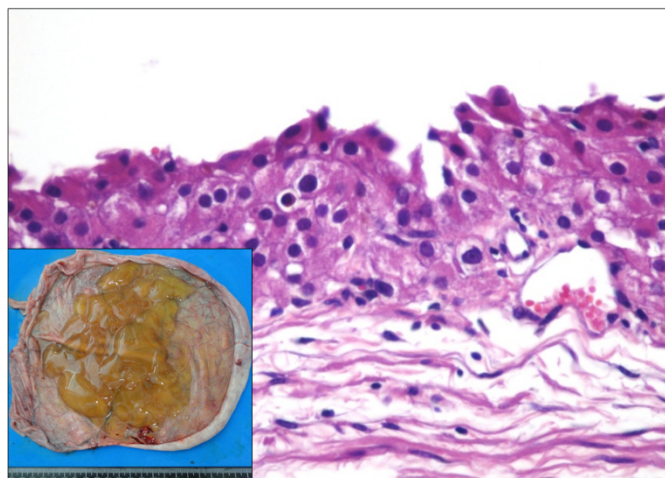


Figure 1: Cystic lesion coated by luteinized cells with discrete hyperchromatic and slightly pleomorphic nuclei, with underlying fibrous stroma with sparse luteinized cells: giant luteinized follicular cyst of pregnancy (H&E stain 400X). **Insert:** Macroscopy: cyst with a diameter of 21cm and a weight of 435g. The cyst wall had a thickness of 0.1cm, was smooth, congested and shiny externally, and discretely opaque internally.

The patient and the newborn evolved well after delivery. The patient reported a positive experience during or follow-up with the medical team.

DISCUSSION

Although the definitive etiological diagnosis of adnexal masses is performed by histopathology, ultrasonography can aid in the prediction of malignancy. It may differentiate the pregnant who may be followed during the gestation of those who need surgical resolution before delivery.⁴ Uniloculated cysts, with no solid component, and no blood flow to the Doppler study are associated with a low risk of malignancy and complications such as torsion, bleeding, rupture and obstruction of the birth canal.² Conservative behavior seems reasonable in these patients. On the other hand, in cases of bulky, rapidly growing cysts, with a strong suspicion of malignancy or increased risk of complications, surgical procedure should be evaluated.⁵ Despite the growth of the cyst in our patient, we chose to wait for the end of gestation because ultrasound and Doppler suggested benignity.

Tumor markers have a limited interpretation for diagnosis and prognosis of adnexal masses during pregnancy, since some of them are altered due to the gravid state, such as CA 125 and Beta-HCG.³ Alpha fetoprotein is also elevated by gestation itself and is used in the screening of neural tube defects and trisomy 21.² In our patient, CA-125, CA-15.3 and CA-19.9 were normal, and Alpha-fetoprotein was 36.4UI/ml.

Surgical removal of ovarian mass prior to resolution of gestation may increase the risk of miscarriage or preterm labor, depending on gestational age. As a large part of the ovarian cysts in pregnancy are benign and of spontaneous resolution, expectant management is the most indicated.^{3,6} Thus, postponing surgery to the postpartum period avoids the side effects of anesthesia in both the fetus and the mother. In addition, if cesarean delivery is chosen, it is possible to perform ovarian cystectomy at the same operative time. In our patient, the sonographic aspect was benign and she was asymptomatic, so we await the third trimester for resolution.

There are few studies in the literature reporting large solitary luteinized follicle cyst of pregnancy.⁷⁻⁹ Large solitary luteinized follicle cyst of pregnancy can also have differential diagnosis with pregnancy luteoma and unilocular cystic granulosa cell tumor. Its pathogenesis is unclear, and may be related to the human chorionic gonadotropin (hCG). But there are cases that occur in the puerperium with low levels of hCG.¹⁰

Therefore, caution should be exercised in the indication of surgery during pregnancy, assessing together maternal and fetal risks. The definitive preoperative diagnosis of ovarian masses is still difficult, and criteria predictive of malignancy include the use of tumor markers, ultrasonography and Doppler. The association of these tests should guide the clinician to define the best time for surgical intervention, but pathological anatomy is still essential for the definitive diagnosis.

The prevalence of ovarian masses in pregnancy is rare, usually not exceeding 5 cm in diameter, and disappearing spontaneously in the second trimester. The patient in the case report had a cyst of 632 ml, increasing in volume to 2600 ml at the time of delivery. This data is a strong point of the case report. One limitation was the fact that pelvis magnetic resonance imaging was not performed, which could add some information about the characteristics of the mass during pregnancy.

Conservative management of adnexal masses during pregnancy should be performed, as long as laboratory and imaging tests do not indicate a high prediction of malignancy. Thus, obstetric complications of surgery during pregnancy can be avoided.

REFERENCES

1. Bignardi T, Condous G. The management of ovarian pathology in pregnancy. *Best Pract Res Clin Obstet Gynaecol* 2009;23(4),539-48.
2. Giuntoli RL, Vang RS, Bristow RE. Evaluation and Management of Adnexal Masses During Pregnancy. *Clin Obstet Gynecol* 2006;49(3), 492-505.
3. Leiserowitz GS. Managing Ovarian Masses During Pregnancy. *Obstet Gynecol Surv* 2006;61(7), 463-470.
4. Bromley B, Benacerraf B. Adnexal masses during pregnancy: accuracy of sonographic diagnosis and outcome. *J Ultrasound Med* 1997; 16(7), 447-452.

5. Marret H, Lhommé C, Lecuru F, Canis M, Lévêque J, Gollfier F et al. Guidelines for the management of ovarian cancer during pregnancy. *Eur J Obstet Gynecol Reprod Biol* 2010;149(1),18-21.
6. Usui R, Minakami H, Kosuge S, Iwasaki R, Ohwada M, Sato I. A retrospective survey of clinical, pathologic, and prognostic features of adnexal masses operated on during pregnancy. *J Obstet Gynaecol Res* 2000; 26(2), 89 -93.
7. Roth LM, Ehrlich CE, Ellis GH. Large luteinized follicular cyst of pregnancy and puerperium. *South Med J* 1988; 81(6),805-6.
8. Fang YM, Gomes J, Lysikiewicz A, Maulik D. Massive luteinized follicular cyst of pregnancy. *Obstet Gynecol* 2005; 105(5 Pt 2),1218-21.
9. Lomme M, Kostadinov S, Zhang C. Large solitary luteinized follicle cyst of pregnancy and puerperium: report of two cases. *Diagn Pathol* 2011;6:3.
10. Clement PB, Scully RE. Large solitary luteinized follicle cyst of pregnancy and puerperium: A clinicopathological analysis of eight cases. *Am J Surg Pathol* 1980; 4(5),431-438.

Consent

Consent was obtained from the patient for publication of this case report. The study was approved by the Research Ethics Committee of the Federal University of the Triângulo Mineiro (protocol number 75479817.7.0000.5154).

Conflict of interests

The authors declare no conflicts of interest.

Acknowledgement

The authors wish to acknowledge CNPq (Conselho Nacional de Desenvolvimento Científico e Tecnológico), FUNEPU (Fundação de Ensino e Pesquisa de Uberaba) and the FAPEMIG (Fundação de Amparo à Pesquisa do Estado de Minas Gerais).

- Taíssa Fernandes Lemes (MD): Obstetrician-gynecologist; Research Institute of Oncology (IPON)/Department of Gynecology and Obstetrics, Federal University of Triângulo Mineiro, Uberaba – MG, Brazil.
- Sheila Jorge Adad (PhD): Associate Professor; Research Institute of Oncology (IPON)/Department of Gynecology and Obstetrics, Discipline of Special Pathology; Federal University of Triângulo Mineiro, Uberaba – MG, Brazil.
- Eddie Fernando Candido Murta (PhD): Titular Professor; Research Institute of Oncology (IPON)/Department of Gynecology and Obstetrics, Federal University of Triângulo Mineiro, Uberaba – MG, Brazil.
- Rosekeila Simões Nomelini (PhD): Associate Professor; Research Institute of Oncology (IPON)/Department of Gynecology and Obstetrics, Federal University of Triângulo Mineiro, Uberaba – MG, Brazil.

Authors' contributions

RSN, SJA and EFCM designed the study. TFL collected the data. RSN and SJA analyzed the data. TFL and RSN wrote the manuscript. EFCM revised the manuscript. All authors contributed to editorial changes in the manuscript. All authors read and approved the final manuscript.

Corresponding Author:
Rosekeila Simões Nomelini,
rosekeila@terra.com.br
rosekeila.nomelini@pq.cnpq.br

Editor:
Prof. Dr. Felipe Villela Gomes

Received: dec 10, 2021
Approved: mar 03, 2022
