


4-hydroxy-2-nonenal as a marker of the oxidative stress in brains of dogs with canine distemper

4-hidroxi-2-nonenal como marcador de estresse oxidativo no cérebro de cães com cinomose

Érica Almeida Viscone¹ ; Lígia Assunção Oliveira¹; Alexandra Ariadine Bittencourt Gonçalves Pereira²; Márcio Botelho Castro²; Paulo Eduardo Brandão³; Sueli Akemi Taniwaki³; Aline Santana da Hora¹; Márcio de Barros Bandarra¹

¹ Universidade Federal de Uberlândia, Faculdade de Medicina Veterinária, Uberlândia – Minas Gerais, Brazil

² Universidade de Brasília, Laboratório de Patologia Veterinária, Brasília – DF, Brazil

³ Universidade de São Paulo, Faculdade de Medicina Veterinária e Zootecnia, Departamento de Medicina Veterinária Preventiva e Saúde Animal, São Paulo – SP, Brazil

ABSTRACT

Canine Distemper is a disease caused by *Canine morbillivirus* (CM), a pantropic virus that can affect the central nervous system (CNS), causing demyelination. However, the pathogenesis of this lesion remains to be clarified. Brain samples of 14 naturally infected dogs by CM were analyzed to evaluate the presence of oxidative stress and demyelination. RT-PCR assay was performed to confirm a diagnosis of canine distemper in the brain, immunohistochemistry anti-CM was used to localize the viral proteins in the tissue, and anti-4-hydroxy-2-nonenal (4-HNE) was a marker of a product of lipid peroxidation. The results showed the presence of viral proteins in the demyelinated area with the presence of 4-HNE. Our results suggest that the CM virus infection causes oxidative stress leading to lipid peroxidation, which causes tissue damage and demyelination. In conclusion, oxidative stress plays a significant role in canine distemper pathogenesis in the CNS.

Keywords: Demyelination. Lipid peroxidation. RT-PCR. Immunohistochemistry. 4-HNE.

RESUMO

A cinomose canina é uma doença causada pelo *Morbilivírus canino* (CM), um vírus pantrópico que pode afetar o sistema nervoso central (SNC), causando desmielinização. No entanto, a patogênese dessa lesão não está totalmente esclarecida. RT-PCR e imuno-histoquímica foram realizadas para confirmação do diagnóstico de cinomose em amostras de encéfalo de 14 cães naturalmente infectados. Após confirmação, foi realizada uma avaliação do estresse oxidativo por imuno-histoquímica com uso de anti-4-hidroxi-nonenal (4HNE) como marcador de produtos resultantes da peroxidação lipídica. Os resultados sugerem que a infecção pelo CM causa estresse oxidativo no tecido, levando a peroxidação lipídica, a qual causa danos ao tecido, culminando com desmielinização. Conclui-se que o estresse oxidativo tem papel importante na patogênese da cinomose canina no sistema nervoso central.

Palavras-chave: Desmielinização. Peroxidação lipídica. RT-PCR. Imuno-histoquímica. 4-HNE.

Correspondence to:

Érica Almeida Viscone
 Universidade Federal de Uberlândia, Faculdade de Medicina
 Veterinária
 Av. Mato Grosso, 3289 - Bloco 2S, Umuarama
 CEP: 38405-314, Uberlândia - MG, Brazil
 e-mail: ericaviscone@gmail.com

Received: July 29, 2021

Approved: March 4, 2022

How to cite: Viscone EA, Oliveira LA, Pereira AABG, Castro MB, Brandão PE, Taniwaki SA, Hora AS, Bandarra MB. 4-hydroxy-2-nonenal as a marker of the oxidative stress in brains of dogs with canine distemper. *Braz J Vet Res Anim Sci.* 2022;59:e188941. <https://doi.org/10.11606/issn.1678-4456.bjvras.2022.188941>

Introduction

Canine morbillivirus - CM (also known as *Canine distemper virus* - CDV) belongs to the genus *Morbillivirus*, family Paramyxoviridae, and is a single-stranded, negative-sense, RNA virus (International Committee on Taxonomy of Viruses, 2018). Viruses with a broad host range such as CDV are highly contagious and cause high morbidity and mortality rates in wild and domestic animal populations (Duque-Valencia et al., 2019). CDV can adapt and evolve in a high range of animal species and is also capable to cross the species barrier, becoming an important target to study (Duque-Valencia et al., 2019).

Canine Distemper Virus induces multiple pathogenic effects, and different receptors are implicated in the infection and delimit the viral tropism in lymphoid and epithelial tissues, including the central nervous system (CNS) (Rendon-Marin et al., 2019). Demyelination is the most common microscopic change in the CNS (Lempp et al., 2014). Many studies have been performed to explain the pathogenesis of this lesion (Vandeveldt et al., 1982; Vandeveldt & Zurbriggen, 2005; Pan et al., 2013; Ulrich et al., 2014; Attig et al., 2019); however, the mechanisms are not entirely understood.

The central nervous system has elevated levels of polyunsaturated lipids in membranes of the neuronal cells, a high rate of oxygen demand, and at some point a weak antioxidative defense (Zarkovic et al., 2017). Ischemic, inflammatory, metabolic, degenerative, and carcinogenic processes in the CNS are related to brain damage by oxidative stress, accumulation of reactive oxygen species (ROS), and reactive aldehydes (Zarkovic et al., 2017). Myelin is sensitive to ROS-induced lipid peroxidation,

and virus-induced activated microglia is an important source of ROS generation in acute demyelinating distemper (Stein et al., 2004).

Oxidative stress (OS) is a condition characterized by the imbalance between the production of ROS, and the level of antioxidants resulting in cellular damage and neurodegeneration. Different substrates in the cell may be targets of ROS causing protein, DNA, RNA oxidation, or lipid peroxidation (Gandhi & Abramov, 2012). Lipid peroxidation (LPO) generates highly toxic reactive aldehydes such as 4-hydroxy-2-nonenal (4-HNE) (Zheng et al., 2014). Omega-6-polyunsaturated fatty acids peroxidation derived from arachidonic and linoleic acids results in the production of 4-HNE (Esterbauer et al., 1991; Guichardant et al., 2002; Spickett, 2013) and forms covalent adducts with nucleophilic functional groups in macromolecule such as proteins, DNA, and lipids (Zhong & Yin, 2015). The evolution process of aerobic organisms has created a defense network and an adaptive system to cope with a moderate level of LPO; however elevated levels of LPO lead to degenerative and pathological consequences (Niki, 2009).

This study aimed to evaluate the presence of 4-HNE in the brain of dogs naturally infected by *Canine morbillivirus* and its relationship with demyelination in canine distemper.

Materials and Methods

Animals

Fourteen dogs naturally infected by *Canine morbillivirus* with a fatal outcome or euthanized due to a poor prognosis were selected. Necropsy of all animals was performed at Laboratório de Patologia Animal, Hospital Veterinário, Universidade Federal de Uberlândia.

All the experimental procedures were conducted per the Animal Use Ethics Committee of Universidade Federal de Uberlândia, under the protocol number A007/18.

Histopathology

Fragments of the frontal lobes and cerebellum were collected, fixed in 10% neutral-buffered formalin, routinely processed, and embedded in paraffin. The 4- μ m-thick sections were stained with hematoxylin and eosin (Fischer et al., 2008).

4-HNE Immunohistochemistry

Immunohistochemistry (IHQ) assay was performed on histological sections of the brain. Antigenic retrieval was performed for 40 min in citrate buffer, pH 6.0, 96°C. Slides were incubated with the primary antibody polyclonal anti-4-HNE (1:200, Bioss, Woburn, MA, USA), at room

temperature for 2 h, and reaction revealed by EnVision™ FLEX, High pH Link (Dako-Agilent, Santa Clara, CA, USA).

Canine morbillivirus Immunohistochemistry

Antigenic retrieval of samples of the cerebellum was performed in a pressure cooker at 121°C for 3 min in citrate buffer, pH 6.0, and incubated with the primary antibody polyclonal anti-Canine Distemper Virus (1:300, VMRD, Pullman, WA, USA), at 4°C for 12 h. The reaction was revealed with ImmunoDetector Bio SB (Bio SB, Santa Barbara, CA, USA). Slides were counterstained with Harris hematoxylin.

RT-PCR

A fragment of the frontal lobe was collected and stored immediately at -80°C in cryotubes. RT-PCR target to the nucleoprotein gene of CDV was conducted according to a previous study (Furtado et al., 2017). All samples were evaluated by RT-PCR for the glyceraldehyde-3-phosphate dehydrogenase (GAPDH) gene as endogenous control (Furtado et al., 2017).

Results

Histopathology

Characterization of histopathological changes was performed in 42 slides. Edema of the myelin sheath, demyelination, astrogliosis with gemistocytes, and inflammation (Gitter cells and mononuclear perivascular infiltration) were observed. The most common alteration found in the cerebellum was demyelination, present in all samples, followed by one or more inflammatory cell types in 78% (11/14) of samples. In all of the cases with inflammation, demyelinated areas were also present.

At the frontal lobe, demyelination occurred in 57% (8/14) of cases and inflammation in 43% (6/14). Demyelination concomitant with inflammation occurred in 36% (5/14) of samples.

4-HNE immunohistochemistry

The evaluation of oxidative stress was performed in 42 slides by immunohistochemistry using antibody anti-4HNE. In general, most of the cells presented staining at some level. However, cells around and in the demyelinated areas were stained stronger.

At the cerebellum, 71% (10/14) of all samples presented stained cells, most of them were hypertrophic astrocytes with compatible morphology to reactive astrocytes (gemistocytic astrocytes), presented in demyelinated areas.

All of the samples showed neurons and astrocytes with low immunoreactivity marked diffusely, but around demyelinated areas, the immunoreactivity was high. Inflammatory cells (activated macrophages/microglia, mononuclear and gitter cells) were positive in 57% (8/14) of cases. Choroid plexus was positive in 50% (7/14) of cases (Figure 1). Neurons at pons were positive in perikaryon and axon (Figure 2).

At the frontal lobe, all samples showed positive neurons in the presence or not of demyelination. However, 36% (5/14) of the samples had stronger immunostaining around the demyelinated area. Into the demyelinated area, 28% (4/14) of all samples showed positive cells. Mononuclear inflammatory cells were present in 36% (5/14) of the samples (Figure 3) and had strong immunostaining.

Canine morbillivirus immunohistochemistry

Immunohistochemistry was performed to detect the presence of virus protein in the cerebellum. All samples showed reactivity anti-CDV, stained in white matter into demyelinated areas (Figure 4).

RT-PCR

All of the samples were positive in RT-PCR for distemper. All 14 samples analyzed were positive to CDV and endogenous control GAPDH gene in RNA extraction.

Discussion

This study demonstrates that lipid peroxidation occurs in the brain of dogs naturally infected by *Canine morbillivirus*. Neurons, glial cells, choroid plexus, and inflammatory cells showed immunoreactivity to 4-HNE and the presence of this aldehyde might lead to demyelination. 4-HNE is recognized as one of the key agents in cell and tissue damage caused by oxidative stress (Zhang & Forman, 2017). It is suggested that the presence of the *Canine morbillivirus* in the brain can trigger oxidative stress.

The initial trigger of oxidative injury induces different cascades of molecular events, leading to cell degeneration and death, which may be different in diverse cell types (Lassmann & van Horssen, 2016). This fact might explain the diffuse immunoreactivity in most of the cell types in the brain, as found here. In the cerebellum, most of the samples showed neurons and glial cells positive for 4-HNE around demyelinated areas. At the frontal lobe, most of the positive cells were neurons, regardless of the presence of demyelination. The brain has diverse types of neurons with their morphologies and biochemical characteristics, in different regions. Due to this diversity, each neuronal

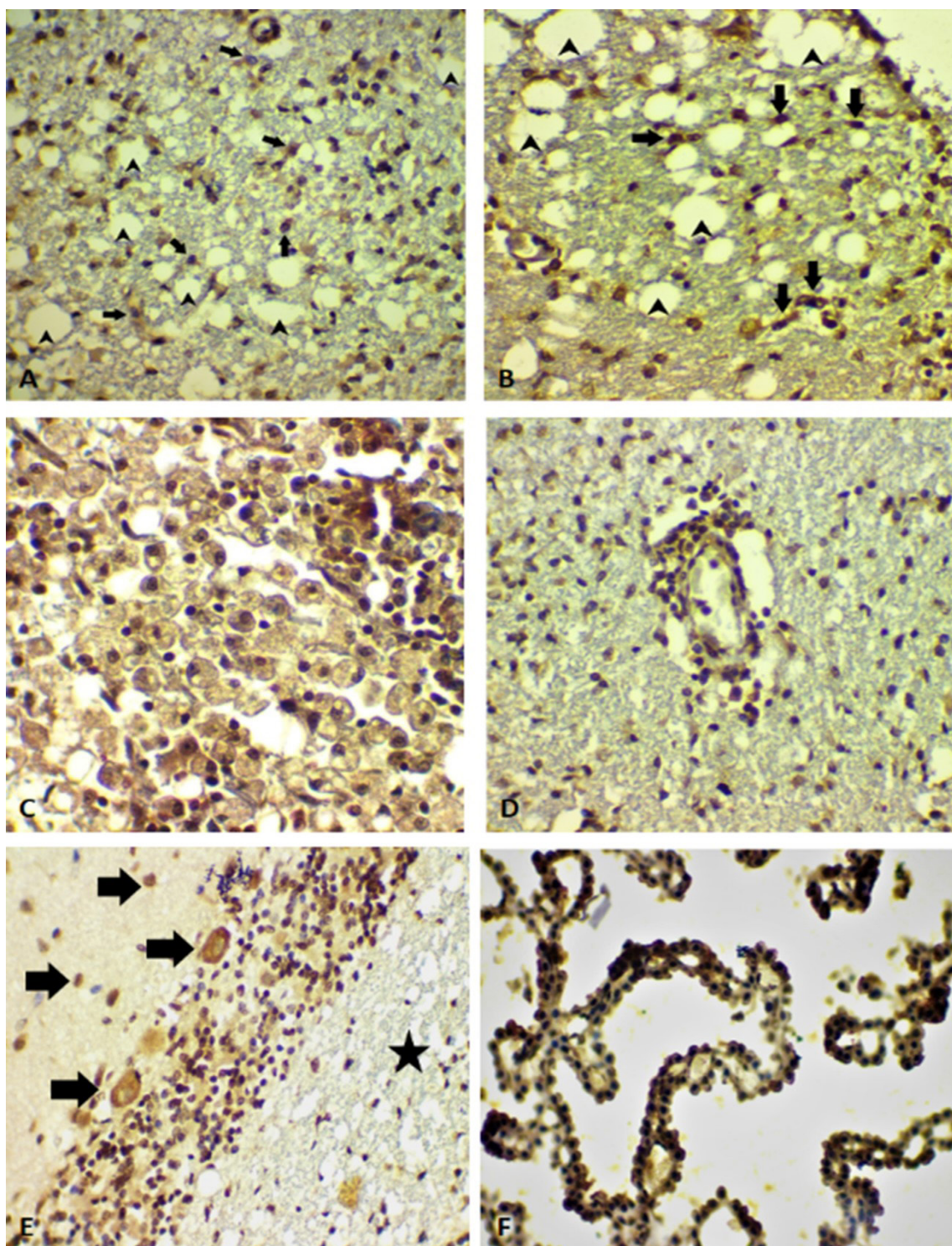


Figure 1 – Immunoreactive cells to 4-HNE in the cerebellum of dogs with canine distemper. A – B: 4-HNE-stained astrocytes (arrows) into the demyelinated areas (arrowheads) (400x). C: 4-HNE-stained Gitter cells (400x). D: Perivascular Cuff with 4-HNE-stained mononuclear inflammatory cells (400x). E: 4-HNE-stained Purkinje and glia cells (arrows) around the demyelinated area with poor immunoreactivity (Black star) (400x). F: 4-HNE-stained choroid plexus cells (400x).

population may have its level of vulnerability to OS (Wang & Michaelis, 2010).

Reactive astrocytes were found before the onset of overt demyelination in acute brain lesions of CDV-infected dogs (Klemens et al., 2019). This study shows 4-HNE-positive astrocytes in the demyelinated areas, showing hypertrophic morphology, which leads us to think that these cells might

begin a cascade process that culminates in tissue damage. Here, it is proposed that the demyelinating process starts at the astrocyte and spread to the tissue around, causing damage.

This can be explained by the fact that in canine distemper reactive astrocytes show neurotoxic properties, with the potential to cause neurodegeneration, demyelination, and impaired remyelination (Klemens et al., 2019). Besides,

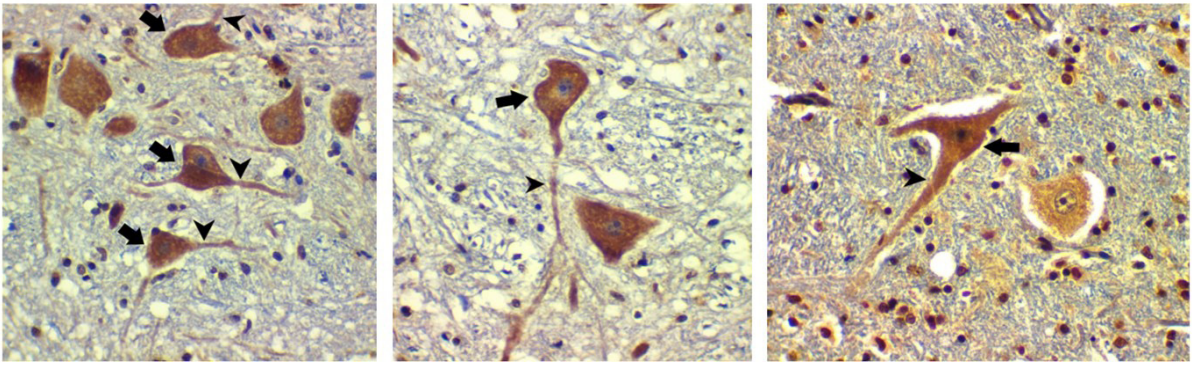


Figure 2 – Immunoreactive neurons and glial cells to 4-HNE in the cerebellum of dogs with canine distemper. A-C: 4-HNE-stained neurons with immunoreactivity in perikaryon (arrows) and axons (arrowheads) (400x). Glial cells with immunoreactivity nearby the neurons.

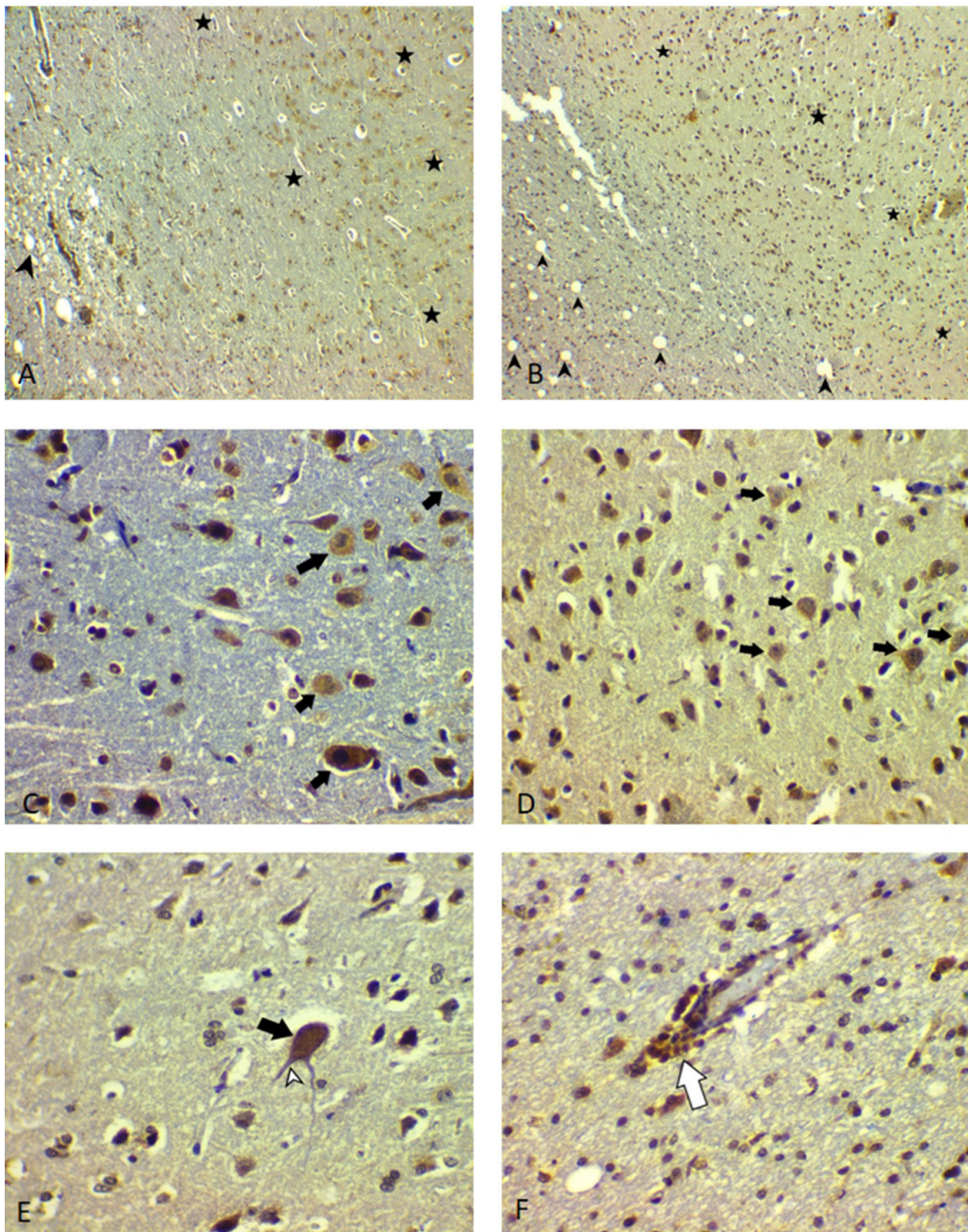


Figure 3 – Immunoreactive cells to 4-HNE in the frontal lobe of dogs with canine distemper. A-B: 4-HNE-stained neurons and glial cells (Black stars) around the demyelinated area with poorly immunoreactivity (arrowheads) (40x). C-D: 4-HNE-stained neurons (arrows) and glia cells (400x). E: 4-HNE-stained neuron with immunoreactivity in perikaryon (arrow) and axon (white arrowhead) (400x). F: Perivascular Cuff with 4-HNE-stained mononuclear inflammatory cells (white arrow) (400x).

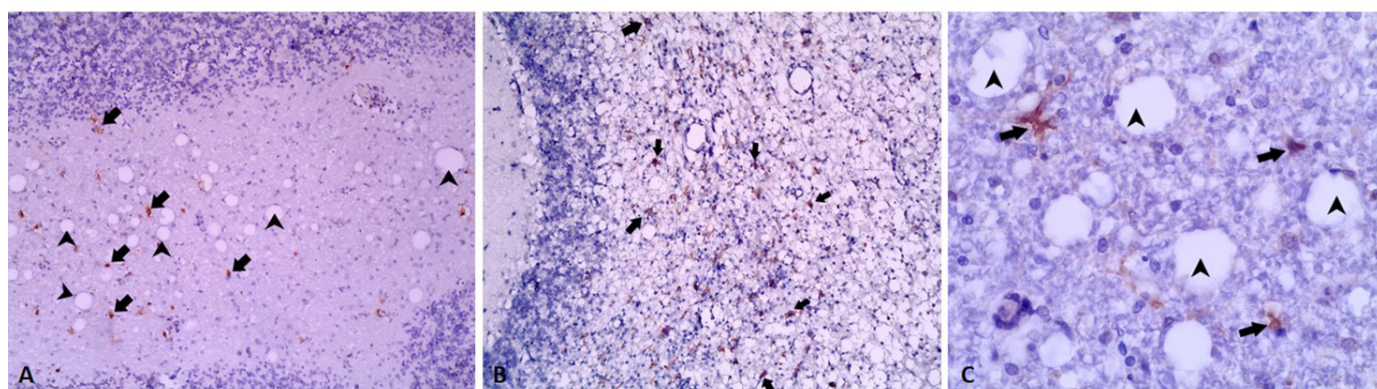


Figure 4 – Canine morbillivirus immunohistochemistry, viral protein in the demyelinated area at cerebellum of dogs. A-C: the presence of viral protein (arrows) in the demyelinated area (arrowheads) in different sites of the cerebellum (A-B:100x. C: 400x).

excessive generation of free radicals induces glutathione depletion in neurons and astrocytes. Impairing neuronal viability as glutathione depletion leaves these cells more susceptible to damage by oxidative stress (Abramov et al., 2010). The most vulnerable cells for oxidative injury are neurons and oligodendrocytes, while astrocytes and microglia show more resistance. These differences might be due to different intrinsic factors, such as the expression of antioxidant defense molecules, susceptibility for apoptosis induction, and differences in cellular metabolism (Lassmann & van Horsen, 2016). The lipid peroxidation occurs naturally in aerobic biologic systems, so, at low concentrations, 4-HNE is present in cells and tissue fluids under normal physiological conditions (Zhang & Forman, 2017). However, degradation of 4-HNE is slow in the brain. As a consequence, 4-HNE accumulates in greater amounts during oxidative stress and may lead to increased susceptibility to tissue damage (Zheng et al., 2014).

In this study, it was possible to observe axonal immunoreactivity to 4-HNE showing that not only OS can affect the perikaryon, but also other structures which are involved by myelin. Axonal damage represents a key event in the initial disease phase and during the progression of demyelinating leukoencephalitis induced by *Canine morbillivirus* (Lempp et al., 2014).

Choroid plexus expressed immunoreactivity to 4-HNE, showing that these cells also pass through oxidative stress that may be caused by virus infection. CDV antigens can be

detected in a variety of cell types in CNS, including choroid plexus, which has a receptor, nectin-4, which has a significant role in the virus spread in CNS (Pratakpiriya et al., 2017).

In conclusion, 4-HNE can be found in most of the cells in the brain of dogs naturally infected by *Canine morbillivirus*. Due to the presence of virus proteins found in demyelinated areas, detected by IHC anti-CDV, and the presence of 4-HNE immunoreactive cells in the same area, we conclude that the virus causes oxidative stress leading to lipid peroxidation, which participates in the tissue damage resulting in demyelinating process. This study provides a basis for further functional research into the role of oxidative stress in canine distemper.

Conflict of Interest

There is no conflict of interest between the authors.

Ethics Statement

Procedures were carried out in accordance with the Animal Use Ethics Committee of Federal University of Uberlândia, under the protocol number A007/18.

Acknowledgements

The first author thanks to Laboratório de Patologia Veterinária, Universidade de Brasília and Departamento de Medicina Veterinária Preventiva e Saúde Animal, Faculdade de Medicina Veterinária e Zootecnia, Universidade de São Paulo for technical support.

References

Abramov AY, Smulders-Srinivasan TK, Kirby DM, Acin-Perez R, Enriquez JA, Lightowers RN, Duchon MR, Turnbull DM. Mechanism of neurodegeneration of neurons with mitochondrial DNA mutations. *Brain*. 2010;133(3):797-807. <http://dx.doi.org/10.1093/brain/awq015>. PMID:20157008.

Attig F, Spitzbarth I, Kalkuhl A, Deschl U, Puff C, Baumgärtner W, Ulrich R. Reactive oxygen species are key mediators of demyelination in canine distemper leukoencephalitis but not in theiler's murine encephalomyelitis. *Int J Mol Sci*. 2019;20(13):3217. <http://dx.doi.org/10.3390/ijms20133217>. PMID:31262031.

- Duque-Valencia J, Sarute N, Olarte-Castillo XA, Ruíz-Sáenz J. Evolution and interspecies transmission of canine distemper virus: an outlook of the diverse evolutionary landscapes of a multi-host virus. *Viruses*. 2019;11(7):582. <http://dx.doi.org/10.3390/v11070582>. PMID:31247987.
- Esterbauer H, Schaur RJ, Zollner H. Chemistry and biochemistry of 4-hydroxynonenal, malonaldehyde and related aldehydes. *Free Radic Biol Med*. 1991;11(1):81-128. [http://dx.doi.org/10.1016/0891-5849\(91\)90192-6](http://dx.doi.org/10.1016/0891-5849(91)90192-6). PMID:1937131.
- Fischer AH, Jacobson KA, Rose J, Zeller R. Hematoxylin and eosin staining of tissue and cell sections. *Cold Spring Harb Protoc [Internet]*. 2008 [cited 2021, July 29];(5):4986. Available from: <http://cshprotocols.cshlp.org/content/2008/5/pdb.prot4986.short>.
- Furtado MM, Taniwaki SA, Barros IN, Brandão PE, Catão-Dias JL, Cavalcanti S, Cullen L, Filoni C, Jácomo ATA, Jorge RSP, Silva NS, Silveira L, Ferreira-Neto JS. Molecular detection of viral agents in free-ranging and captive neotropical felids in Brazil. *J Vet Diagn Invest*. 2017;29(5):660-8. <http://dx.doi.org/10.1177/1040638717720245>. PMID:28677421.
- Gandhi S, Abramov AY. Mechanism of oxidative stress in neurodegeneration. *Oxid Med Cell Longev*. 2012;2012: 428010. <http://dx.doi.org/10.1155/2012/428010>. PMID:22685618.
- Guichardant M, Bernoud-Hubac N, Chantegrel B, Deshayes C, Lagarde M. Aldehydes from n-6 fatty acid peroxidation. Effects on aminophospholipids. *Prostaglandins Leukot Essent Fatty Acids*. 2002;67(2-3):147-9. <http://dx.doi.org/10.1054/plef.2002.0412>. PMID:12324234.
- International Committee on Taxonomy of Viruses – ICTV. Master Species List ICTV 2018 v1 [Internet]. Washington, DC: ICTV; 2018 [cited 2021, July 29]. Available from: <https://talk.ictvonline.org/files/master-species-lists/m/msl/7992>.
- Klemens J, Ciurkiewicz M, Chludzinski E, Iseringhausen M, Klotz D, Pfankuche VM, Ulrich R, Herder V, Puff C, Baumgärtner W, Beineke A. Neurotoxic potential of reactive astrocytes in canine distemper demyelinating leukoencephalitis. *Sci Rep*. 2019;9(1): 11689. <http://dx.doi.org/10.1038/s41598-019-48146-9>. PMID:31406213.
- Lassmann H, van Horssen J. Oxidative stress and its impact on neurons and glia in multiple sclerosis lesions. *Biochim Biophys Acta*. 2016;1862(3):506-10. <http://dx.doi.org/10.1016/j.bbadis.2015.09.018>. PMID:26432481.
- Lempp C, Spitzbarth I, Puff C, Cana A, Kegler K, Techangamsuwan S, Baumgärtner W, Seehusen F. New aspects of the pathogenesis of canine distemper leukoencephalitis. *Viruses*. 2014;6(7):2571-601. <http://dx.doi.org/10.3390/v6072571>. PMID:24992230.
- Niki E. Lipid peroxidation: physiological levels and dual biological effects. *Free Radic Biol Med*. 2009;47(5):469-84. <http://dx.doi.org/10.1016/j.freeradbiomed.2009.05.032>. PMID:19500666.
- Pan YQ, Liu XY, Meng LP, Zhu GR, Xia YK, Chen JS, Takashi Y. Pathogenesis of demyelinating encephalopathy in dogs with spontaneous acute canine distemper. *J Integr Agric*. 2013;12(2):334-43. [http://dx.doi.org/10.1016/S2095-3119\(13\)60233-6](http://dx.doi.org/10.1016/S2095-3119(13)60233-6).
- Pratakpiriya W, Teh APP, Radtanakantikanon A, Pirarat N, Lan NT, Takeda M, Techangamsuwan S, Yamaguchi R. Expression of canine distemper virus receptor nectin-4 in the central nervous system of dogs. *Sci Rep*. 2017;7(1):349. <http://dx.doi.org/10.1038/s41598-017-00375-6>. PMID:28336928.
- Rendon-Marin S, Budaszewski RF, Canal CW, Ruiz-Saenz J. Tropism and molecular pathogenesis of canine distemper virus. *Virol J*. 2019;16(1):30. <http://dx.doi.org/10.1186/s12985-019-1136-6>. PMID:30845967.
- Spickett CM. The lipid peroxidation product 4-hydroxy-2-nonenal: advances in chemistry and analysis. *Redox Biol*. 2013;1(1):145-52. <http://dx.doi.org/10.1016/j.redox.2013.01.007>. PMID:24024147.
- Stein VM, Czub M, Schreiner N, Moore PF, Vandeveld M, Zurbriggen A, Tipold A. Microglial cell activation in demyelinating canine distemper lesions. *J Neuroimmunol*. 2004;153(1-2):122-31. <http://dx.doi.org/10.1016/j.jneuroim.2004.05.001>. PMID:15265670.
- Ulrich R, Puff C, Wewetzer K, Kalkuhl A, Deschl U, Baumgärtner W. Transcriptional changes in canine distemper virus-induced demyelinating leukoencephalitis favor a biphasic mode of demyelination. *PLoS One*. 2014;9(4):e95917. <http://dx.doi.org/10.1371/journal.pone.0095917>. PMID:24755553.
- Vandeveld M, Higgins RJ, Kristensen B, Kristensen F, Steck AJ, Kihm U. Demyelination in experimental canine distemper virus infection: Immunological, pathologic, and immunohistological studies. *Acta Neuropathol*. 1982;56(4):285-93. <http://dx.doi.org/10.1007/BF00691260>. PMID:7090737.

Vandeveld M, Zurbriggen A. Demyelination in canine distemper virus infection: a review. *Acta Neuropathol.* 2005;109(1):56-68. <http://dx.doi.org/10.1007/s00401-004-0958-4>. PMID:15645260.

Wang X, Michaelis EK. Selective neuronal vulnerability to oxidative stress in the brain. *Front Aging Neurosci.* 2010;2:12. <http://dx.doi.org/10.3389/fnagi.2010.00012>. PMID:20552050.

Zarkovic K, Jakovcevic A, Zarkovic N. Contribution of the HNE-immunohistochemistry to modern pathological concepts of major human diseases. *Free Radic Biol Med.* 2017;111:110-26. <http://dx.doi.org/10.1016/j.freeradbiomed.2016.12.009>. PMID:27993730.

Zhang H, Forman HJ. 4-hydroxynonenal-mediated signaling and aging. *Free Radic Biol Med.* 2017;111:219-25. <http://dx.doi.org/10.1016/j.freeradbiomed.2016.11.032>. PMID:27876535.

Zheng R, Dragomir AC, Mishin V, Richardson JR, Heck DE, Laskin DL, Laskin JD. Differential metabolism of 4-hydroxynonenal in liver, lung and brain of mice and rats. *Toxicol Appl Pharmacol.* 2014;279(1):43-52. <http://dx.doi.org/10.1016/j.taap.2014.04.026>. PMID:24832492.

Zhong H, Yin H. Role of lipid peroxidation derived 4-hydroxynonenal (4-HNE) in cancer: focusing on mitochondria. *Redox Biol.* 2015;4:193-9. <http://dx.doi.org/10.1016/j.redox.2014.12.011>. PMID:25598486.

Financial Support: This study was financed in part by the Coordenação de Aperfeiçoamento de Pessoal de Nível Superior - Brasil (CAPES) - Finance Code 001 and Fundação de Desenvolvimento Agropecuário (FUNDAP - UFU).