




ORIGINAL ARTICLE

Expression pattern of perilipins in human brain during aging and in Alzheimer's disease

Maria Conte^{1,2}  | Valentina Medici³ | Davide Malagoli⁴ | Antonio Chiariello¹ |
 Alice Cirrincione³ | Annalisa Davin³ | Maia Chikhladze^{3,5} | Francesco Vasuri⁶ |
 Giuseppe Legname⁷  | Isidre Ferrer^{8,9,10}  | Silvia Vanni¹¹ |
 Gabriella Marcon^{12,13} | Tino Emanuele Poloni³ | Antonio Guaita³ |
 Claudio Franceschi¹⁴ | Stefano Salvioli^{1,2}

¹Department of Experimental, Diagnostic and Specialty Medicine (DIMES), University of Bologna, Bologna, Italy

²Interdepartmental Centre "Alma Mater Research Institute on Global Challenges and Climate Change (Alma Climate)", University of Bologna, Bologna, Italy

³Department of Neurology and Neuropathology, Golgi-Cenci Foundation, Milan, Italy

⁴Department of Life Sciences, University of Modena and Reggio Emilia, Modena, Italy

⁵Department of Pharmacological and Biomolecular Sciences, Università degli Studi di Milano, Milan, Italy

⁶Pathology Unit, S. Orsola-Malpighi Bologna Authority Hospital, Bologna, Italy

⁷Laboratory of Prion Biology, Department of Neuroscience, Scuola Internazionale Superiore di Studi Avanzati (SISSA), Trieste, Italy

⁸Department of Pathology and Experimental Therapeutics, Institute of Neurosciences, University of Barcelona, Barcelona, Spain

⁹Bellvitge Biomedical Research Institute-IDIBELL, Department of Pathologic Anatomy, Bellvitge University Hospital, Barcelona, Spain

¹⁰Network Center for Biomedical Research in Neurodegenerative Diseases (CIBERNED), Institute Carlos III, Ministry of Health, L'Hospitatet del Llobregat, Barcelona, Spain

¹¹Osteoncology and Rare Tumors Center, IRCCS Istituto Romagnolo Per Lo Studio Dei Tumori (IRST) "Dino Amadori", Meldola, Italy

¹²DAME, University of Udine, Udine, Italy

¹³Department of Medical Surgical and Health Sciences, University of Trieste, Trieste, Italy

¹⁴Institute of Information Technologies, Mathematics and Mechanics, Lobachevsky University, Nizhny Novgorod, Russia

Correspondence

Maria Conte, Department of Experimental, Diagnostic and Specialty Medicine (DIMES), University of Bologna, Bologna, Italy.
Email: m.conte@unibo.it

Funding information

Ministry of Science and Higher Education at the Lobachevsky State University of Nizhny Novgorod, Grant/Award Number: 075-15-2019-871; Roberto and Cornelia Pallotti Legacy for Cancer Research

Abstract

Aims: Perilipins are conserved proteins that decorate intracellular lipid droplets and are essential for lipid metabolism. To date, there is limited knowledge on their expression in human brain or their involvement in brain aging and neurodegeneration. The aim of this study was to characterise the expression levels of perilipins (Plin1–Plin5) in different cerebral areas from subjects of different age, with or without signs of neurodegeneration.

Methods: We performed real-time RT-PCR, western blotting, immunohistochemistry and confocal microscopy analyses in autaptic brain samples of frontal and temporal cortex, cerebellum and hippocampus from subjects ranging from 33 to 104 years of age, with or without histological signs of neurodegeneration. To test the possible relationship between Plins and inflammation, correlation analysis with IL-6 expression was also performed.

[Correction added on 23 September 2021, after first online publication: Peer review history statement has been added.]

This is an open access article under the terms of the Creative Commons Attribution-NonCommercial License, which permits use, distribution and reproduction in any medium, provided the original work is properly cited and is not used for commercial purposes.

© 2021 The Authors. *Neuropathology and Applied Neurobiology* published by John Wiley & Sons Ltd on behalf of British Neuropathological Society.

Results: Plin2, Plin3 and Plin5, but not Plin1 and Plin4, are expressed in the considered brain areas with different intensities. Plin2 appears to be expressed more in grey matter, particularly in neurons in all the areas analysed, whereas Plin3 and Plin5 appear to be expressed more in white matter. Plin3 seems to be expressed more in astrocytes. Only Plin2 expression is higher in old subjects and patients with early tauopathy or Alzheimer's disease and is associated with IL-6 expression.

Conclusions: Perilipins are expressed in human brain but only Plin2 appears to be modulated with age and neurodegeneration and linked to an inflammatory state. We propose that the accumulation of lipid droplets decorated with Plin2 occurs during brain aging and that this accumulation may be an early marker and initial step of inflammation and neurodegeneration.

KEYWORDS

brain, human aging, inflammation, neurodegenerative diseases, perilipins

INTRODUCTION

Aging is considered the major risk factor for the development of neurodegenerative diseases, such as Alzheimer's disease (AD). Neurodegeneration is due to a progressive loss of neurons and connections, leading to atrophy of both grey and white matter, most prominently in the temporal and frontal lobes [1, 2]. However, although several age-associated neuronal changes have been clarified, many aspects of brain aging remain controversial and unclear. Recent evidence suggests that brain aging is characterised by chronic alterations of energy metabolism and in particular lipid metabolism [3]. The dysregulation of lipid metabolism in the brain leads to the accumulation of lipids including toxic ones, such as long-chain ceramides [4–6], and to the formation of lipid-laden cells (LLCs) [7]. This accumulation, together with the decline of omega-3 fatty acids [8], participates in the induction of age-related neuroinflammatory processes, closely associated with the onset of neurodegenerative disorders [9, 10]. Intracellular lipid storage occurs within organelles, called lipid droplets (LDs). During aging, the content and composition of LDs may vary, leading to an increase of ectopic lipid deposition in several nonadipose tissues (i.e., liver, skeletal muscle and pancreas) [11–13]. Though LDs were originally considered only as fat depots, recent evidence demonstrates that they are dynamic organelles involved in numerous cellular processes [14, 15]. Despite the fact that lipids are crucial components of the brain, so far, little is known about the function of LDs in this organ, especially in the context of neurodegenerative diseases [16].

LDs are characterised by a core of neutral lipids, containing cholesterol esters and triglycerides, and surrounded by a monolayer of phospholipids associated with several proteins involved in lipid metabolism. Among these proteins, the most abundant and well characterised are perilipins (Plins). Plins belong to a family of five evolutionary conserved proteins (called Plin1 to Plin5), known as the PAT protein family [13, 17, 18]. Plins are involved in different cellular processes, such as LD formation, trafficking and turnover. Each Plin displays a specific expression pattern; for example, Plin1 is expressed

Key points

- Plin2, Plin3 and Plin5, but not Plin1 and Plin4, are expressed in human brain with differences at the level of areas as well as white and grey matter and brain cell types.
- Plin2 appears to be expressed in neurons and the only one affected by age and neurodegenerative diseases.
- Plin2 seems to be associated with IL-6 expression, suggesting a possible connection between accumulation of Plin2-positive lipid droplets and neuroinflammation.

only in adipose tissue, Plin2 and Plin3 are ubiquitously expressed in nonadipose tissues, whereas Plin5 is particularly expressed in metabolic tissues, such as skeletal muscle and brown adipose tissue [13]. Moreover, because Plin2 is always associated to the surface of LDs, it is considered as a marker of LDs content [13, 19–21]. In the last few years, Plins received considerable attention because they are essential for the normal physiology of cells. Moreover, the differential expression of these proteins is associated with alteration in lipid metabolism, causing several metabolic disorders and age-related diseases [22, 23]. We have reported that high levels of Plin2, in both humans and mice, are associated with muscle atrophy and sarcopenia [24–26]. In addition, several lines of evidence from other laboratories indicate that high levels of Plin2 are associated with fatty liver disease, atherosclerosis, obesity, cardiovascular diseases and diabetes, whereas the downregulation or knockout of Plin2 prevents or mitigates these pathologies [13, 27–29]. Alteration of Plins has been reported also in several tumours, including liposarcomas, melanoma, renal cell carcinoma, pancreatic ductal adenocarcinoma and breast cancer [13].

To date, little is known about the expression of Plins in human brain and their possible changes during aging or in neurodegenerative diseases. In this study, we aimed to characterise the expression levels

of Plins in different cerebral areas (frontal and temporal cortex, cerebellum and hippocampus) from subjects of different age (from 33 to 104 years), with or without signs of neurodegeneration, such as early tauopathy (ET) or AD.

METHODS

Human brain samples

Fifty autopsy human brain samples from subjects in the age range 33–104 years, with or without (controls) signs of neurodegeneration, were used for this study. Most of the samples were provided by different brain banks: Abbiategrosso Brain Bank at Golgi Cenci Foundation (Milan, Italy), MRC Edinburgh Brain Bank, Institute of Neuropathology Brain Bank (HUB-ICO-IDIBELL Biobank, Barcelona, Spain). Moreover, 11 samples were collected in the framework of the European Project PROTEOMAGE (grant agreement: FP6-518230). All the samples were collected according to the guidelines of the local ethical committees. Table S1 reports information about all the samples, as also below described:

1. Abbiategrosso Brain Bank at Golgi Cenci Foundation. Eighteen samples were used: (i) one control subject without signs of neurodegeneration; (ii) five subjects with a neuropathological picture of low AD, including three without cognitive impairment, one with mild neurocognitive disorder (NCD) and one with major NCD; (iii) one subject with age-related TAU pathology and major NCD and (iv) 11 subjects with a neuropathological picture of high/intermediate AD and a clinical diagnosis of major NCD. The classification into 'low', 'intermediate' and 'high' AD was made according to the NIA-Alzheimer's Association guidelines for neuropathological assessment of AD, using the ABC score (a combination of: $A\beta$ plaques diffusion stage, Braak stage for TAUopathy and CERAD semiquantitative grading for neuritic plaques) [30]. Low AD pathology is defined by the presence of a Braak stages I–II (B1), in the presence of any amyloid stage, or even by higher Braak stages if the presence of amyloid and neuritic plaques is slight (A1, C1), whereas intermediate and high AD is defined by the concomitance of more severe pathology in both amyloid and Braak stages. From all these samples, the following brain areas were studied: frontal and temporal cortex, cerebellum and hippocampus. All donors underwent an extensive multidimensional assessment including clinical diagnosis, neuropsychological, biological and social evaluations, as previously described [31, 32]. The study protocol received approval from the Ethical Committee of Pavia University (Committee report 3/2009). All subjects joining the donation signed a specific consent form. In case a person was not deemed competent to sign, authorisation from the legal guardian or next-of-kin (NOK) was required. The research was performed under the supervision of the Federazione Alzheimer Italia.
2. MRC Edinburgh Brain Bank. Nine samples of frontal cortex from subjects without neurodegeneration, who died from pathologies

not affecting the brain and lacking any neurological sign (controls). The use of these samples was covered by ethical approval from the East of Scotland Research Ethics Service REC 1 (reference number 16/ES/0084). Informed consent for the research use of autopsy tissue was obtained from the relatives of the deceased whenever necessary.

3. Neuropathology Brain Bank (HUB-ICO-IDIBELL Biobank). Ten samples of frontal cortex from subjects with signs of ET, Braak stages I–II without βA deposition. Samples were obtained following the guidelines of Spanish legislation (Real Decreto 1716/2011) and the approval of the local ethics committee.
4. PROTEOMAGE. Eleven samples of frontal cortex from subjects of different age (33–103 years), died from pathologies not affecting the brain and lacking any neurological sign (controls). Among these controls, four were affected by hemiparesis; therefore, the samples were obtained from the unaffected hemisphere; two samples of frontal cortex were from centenarians (103 years old) affected by cognitive impairment and who died of old age. Given the difficulty to make a proper aetiological diagnosis of dementia during life, post-mortem neuropathological studies were performed. These samples were available in the biobank of the Immunology Lab at Bologna University (S. Salvioli) and were received from partners of the European Project PROTEOMAGE.

DFs culture and treatment

Primary dermal fibroblast (DF) cultures were obtained from biopsies of sun-protected areas (forearm or thigh) from five subjects without neurodegenerative disorders (controls: two young of 34 years, three old of 74 years), two AD patients (83 and 85 years) and three non-AD centenarians (100, 104 and 107 years). DFs from controls and two centenarians were available at the biobank of the Salvioli's laboratory, and those from AD patients and one centenarian came from the Abbiategrosso Golgi Cenci Foundation. In these latter subjects, the biopsy was performed at an average time of approximately 8 h post-mortem. DFs were cultured in DMEM supplemented with 10% heat-inactivated fetal calf serum (FCS), penicillin (100 units/ml), streptomycin (100 g/ml) and 2 mM L-glutamine (all from Sigma) and kept in an incubator at 5% CO₂ humidified atmosphere at 37°C. DFs from the sixth to 14th passage were used for the experiments. For the experiments, the cells were reseeded (125,000 cells/cm²) in FCS-supplemented medium in the presence or absence of 1 mM metformin (Sigma). Cells were collected after 48 h of treatment.

Tissue preparation, light microscopy and IHC

Neuropathological characterisation of samples was carried out on formalin fixed slices, embedded in paraffin and cut in 8- μ m-thick serial sections. The sections were stained with haematoxylin and eosin, cresyl violet, luxol fast blue and Gallyas to evaluate vascular, architectural and structural tissue abnormalities, myelin loss and neuritic

plaques. For immunohistochemical analysis, NeuN and GFAP were used to evaluate neuronal and glial compartments. AT8, 4G8, α -synuclein and TDP43 antibodies were used to assess all the main proteinopathies [32].

Selected sections were deparaffinised and pretreated with 3% H₂O₂ in PBS to neutralise endogenous peroxidase activity, unmasked using four 5-min cycles in citrate buffer, incubated with 5% normal goat serum for 30 min to mask non-specific adsorption sites and then incubated over night at room temperature with the primary antibodies (Table S2). On the day after, the sections were rinsed in PBS and incubated with secondary antibody (EnVision+ System-HRP Labelled Polymer) for 1 h at room temperature, and the antigen-antibody reaction was revealed using diaminobenzidine tetrahydrochloride (DAB+ Substrate Chromogen System, Dako) as chromogen. Control experiments (primary antibodies omitted) showed the absence of non-specific binding. The sections from all subjects were immunostained in a single batch in order to minimise variability and allow reliable comparison of the data obtained from the different cases.

Immunofluorescence and confocal microscopy

Selected paraffin sections were incubated overnight in a mixture of primary monoclonal and polyclonal antibodies (NeuN/Plins, GFAP/Plins, Olig2/Plins and TMEM119/Plins) and subsequently incubated in a mixture of the corresponding secondary antibodies (GAM cy2/GAR cy3 and DAR cy2/GAR cy3). NeuN was used as marker for neurons, GFAP for astrocytes, Olig2 for oligodendrocytes and TMEM119 for microglia.

All slides were examined with Nikon Eclipse Ni (Nikon) and images obtained with NIS Elements AR software (Nikon). These images were used to calculate the percentage of neurons and astrocytes expressing Plin2 and Plin3, respectively.

Then, the slides were examined with a Leica TCS-SP8 Laser Scanning Confocal Microscope (Leica Microsystems), equipped with blue COH (405 nm/25 mW) and white WWL (470 and 650 nm) lasers and managed by LASX Core Edition 3.3.0 software. Confocal high-resolution images were obtained in sequential scan mode, in order to exclude dye emission interference during image acquisition. For each dye, a specific panel of parameters was set before sequential image acquisition. Acquisition parameters were maintained for all the sessions in order to allow a fine comparison between signals from different slides. Images were processed with the open-source Fiji package [33].

RNA extractions and gene expression analysis

Total RNA was isolated from 50–100 mg of frozen (–80°C) frontal cortex samples. The tissue was homogenised with Stainless Steel Beads 5 mm in Tissue Lyser II (Qiagen), in TRIzol reagent (Invitrogen) following the manufacturer's instructions. RNA was extracted with PureLink RNA Mini Kit (Life Technologies), and on-column DNA

digestion was performed using PureLink DNase Set (Life Technologies). RNA was checked for concentration and purity on a NanoDrop 2000 spectrophotometer (Thermo Scientific), whereas RNA integrity was analysed using 2100 Bioanalyzer (Agilent Technologies). Samples with an RNA integrity number (RIN) ≥ 4 were included in the gene expression analysis.

Total RNA from DFs was isolated by using the AllPrep Universal Kit (Qiagen), according to the manufacturer's instructions.

cDNA was synthesised using iScript™ cDNA Synthesis Kit (Bio-Rad) according to the manufacturer's instructions. Real-time RT-PCR was performed with iTaq™ Universal SYBR Green Supermix (Bio-Rad) and Rotor gene Q 6000 system (Qiagen). Six housekeeping genes (18S rRNA, β Actin, glyceraldehyde-3-phosphate dehydrogenase [GAPDH], glucuronidase β , ribosomal protein large P0 and phosphoglycerate kinase 1 [PGK1]) were tested for their suitability as control genes. GAPDH and PGK1 were then chosen as reference genes, as they gave the more stable results, and all data were then normalised to these genes. The relative expression ratio was calculated using the $2^{-\Delta\Delta CT}$ method. Expression analysis of the following genes was undertaken: MAP2, Plin1, Plin2, Plin3, Plin4 and Plin5. All oligonucleotide pre-designed primers were from Bio-Rad (primer information are available at website www.bio-rad.com/PrimePCR).

Protein extraction and WB

Protein extracts were obtained from 30–100 mg of frozen (–80°C) samples of different areas (frontal and temporal cortex, cerebellum and hippocampus). Samples were lysed in lysis buffer consisting of urea 8 M, CHAPS 4%, DTT 65 mM, Tris 40 mM, phosphatase and protease inhibitors (Sigma). Total protein extract was quantified by Bradford's method and stored at –80°C until analysis. Twenty micrograms of the total protein was separated on a 12% SDS-polyacrilamide gel, transferred to a nitrocellulose membrane (Trans-Blot Transfer Medium, Bio-Rad) and immunoblotted with primary antibodies (Table S2); 1:3000 GAPDH antibody was used as a loading control. Densitometry analysis of bands was performed using ImageJ software.

Statistical analysis

All statistical tests used are reported in each figure legend. The comparison of different brain areas as far as Plins expression, as well as the comparison by age group, was performed by using the Kruskal-Wallis test, whereas the comparison between adult and old subjects was performed by using the Mann-Whitney test, because these data analysed did not follow a normal distribution. The Student's *t* test was used to compare control subjects versus ET patients and DFs untreated versus treated with metformin. The analysis of the data obtained from the comparison among AD patients (low, intermediate and high) and centenarians was performed by the one-way ANOVA. The Bonferroni correction was applied. The relationships between

Plins and IL-6 expression levels were calculated by the Spearman rank correlation test and regression analysis. Significance was accepted as $p < 0.05$. Data are expressed as mean \pm SE or mean \pm SD. All data were analysed using the SPSS 23.0 for Windows software.

RESULTS

Plin2, Plin3 and Plin5 proteins are expressed in brain areas

We characterised the protein expression of Plins by western blotting (WB) in different areas of the brain (cerebellum, C; temporal cortex, T; frontal cortex, F; hippocampus, H) from nine control subjects (age

range 71–95 years). We observed that only Plin2, Plin3 and Plin5 were expressed in the brain, whereas Plin1 and Plin4 were undetectable by WB in all the investigated areas. Figure 1A shows the results for three representative subjects. Moreover, Plin2 was expressed at significantly lower levels in the cerebellum with respect to other areas (Figure 1B), Plin3 followed a similar trend, but a significant difference in the expression level was found only between cerebellum and hippocampus (Figure 1C). Plin5 appeared equally expressed in all the considered areas (Figure 1D). To investigate the topographical distribution of Plin2, Plin3 and Plin5, an immunohistochemistry (IHC) analysis was performed. Plin2 immunoreactivity showed a diffuse staining of mild intensity (Figure 2A–D). All areas showed a similar Plin2 staining level; however, frontal and temporal cortex exhibited a slightly more intense staining of Plin2 with respect

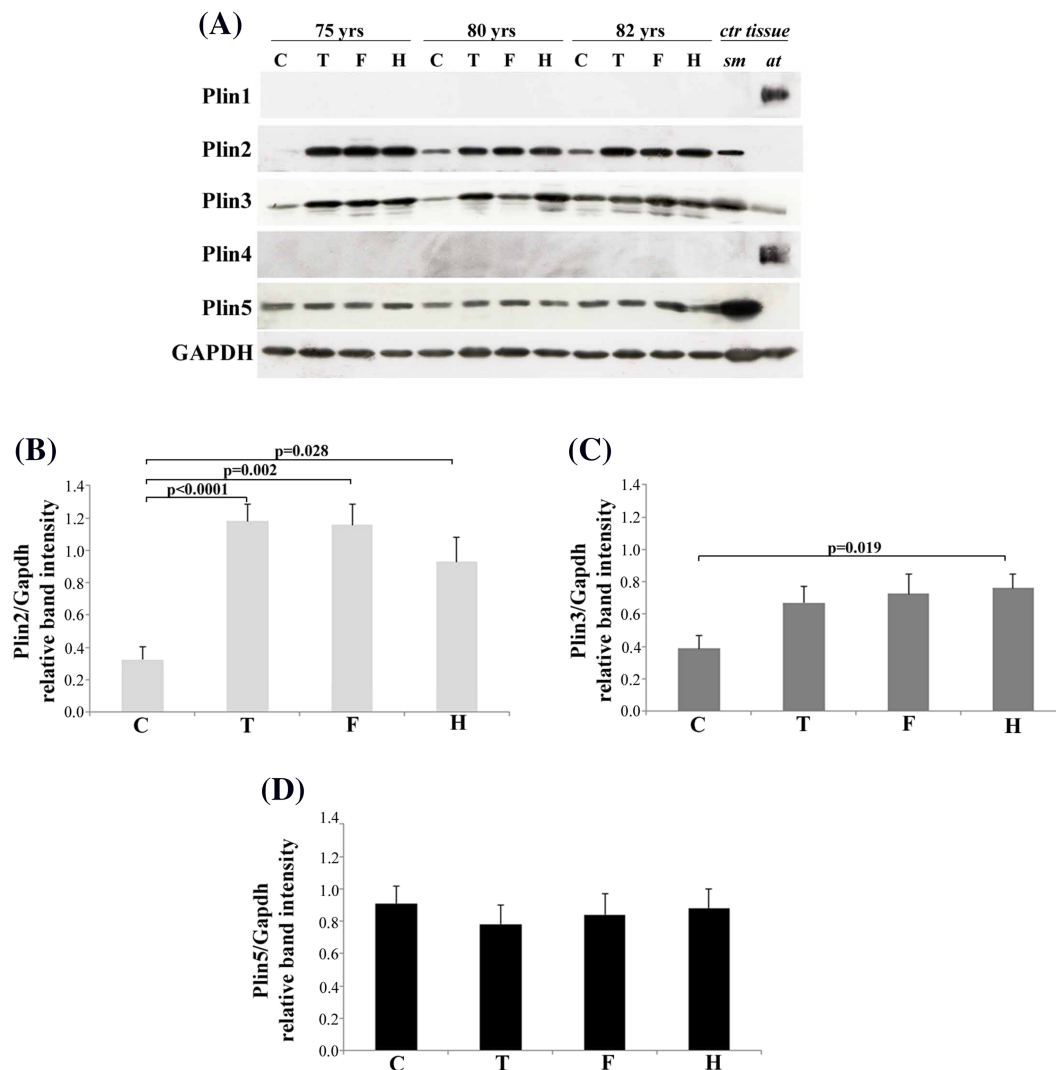


FIGURE 1 Western blotting (WB) analysis of Plins protein expression in different brain areas. (A) Representative immunoblotting image of Plin1, Plin2, Plin3, Plin4 and Plin5 in cerebellum (C), temporal cortex (T), frontal cortex (F) and hippocampus (H) from three representative old subjects (75, 80 and 82 years) without neurodegenerative diseases. (B–D) Relative protein expression levels of (B) Plin2, (C) Plin3 and (D) Plin5 in C, T, F and H areas from 10 old subjects without neurodegenerative diseases (control). The bars represent mean \pm SE. Kruskal–Wallis and Bonferroni tests were applied. WB quantification of Plins expression was performed using ImageJ software and normalised to GAPDH protein expression. Control (ctr) tissues, such as skeletal muscle (sm) and adipose tissue (ad), are used as internal controls

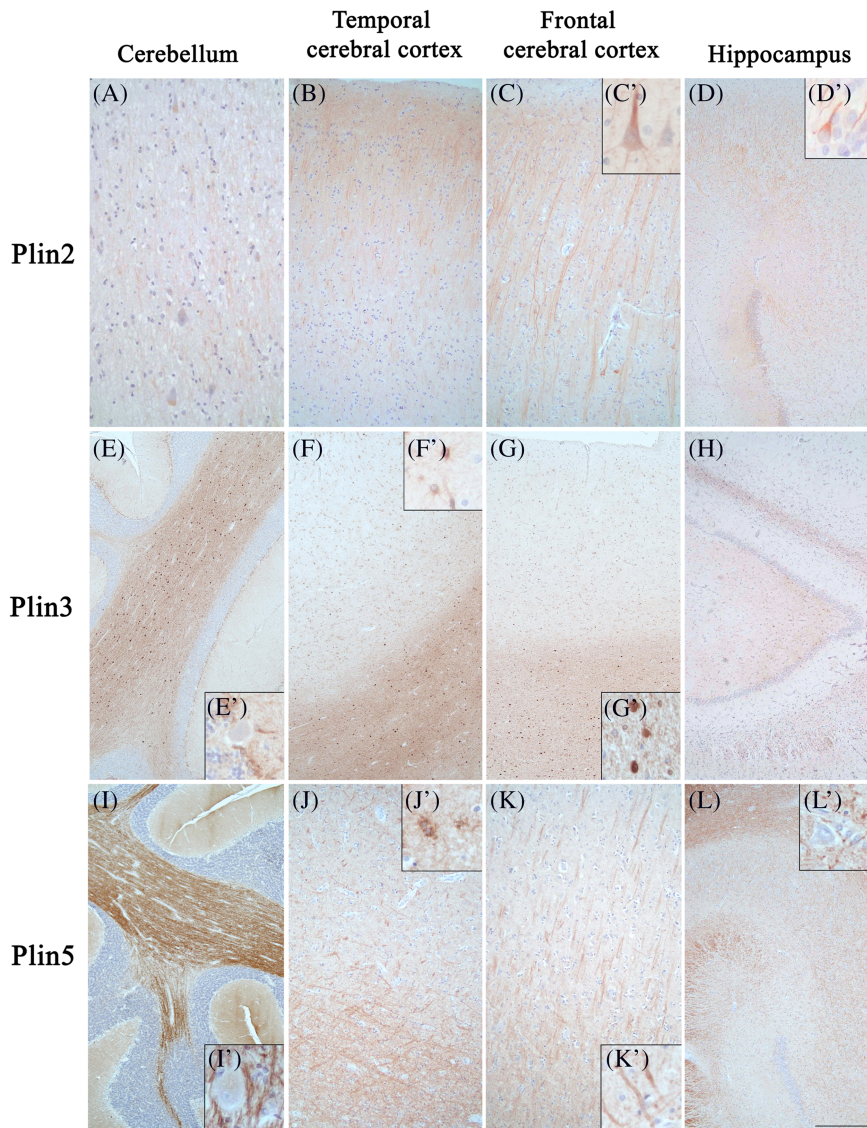


FIGURE 2 Immunohistochemical analysis of Plins in different brain areas. Localisation and distribution of (A–D') Plin2, (E–H) Plin3 and (I–L') Plin5 in sections from autptic human tissues of (A,E,E',I,I') cerebellum, (B,F,F',J,J') temporal cerebral cortex, (C,C',G,G',K,K') frontal cerebral cortex and (D,D',H,L,L') hippocampus. Plin2 immunoreactivity is evident (B,C) in the grey matter of cerebral cortex, (D) in the hippocampus and, to a lesser extent, (A) in the white matter of the cerebellum. Neuronal proximal fibres and some of the cytoplasm of neurons are clearly positive (C', D'). Note the intense Plin3 and Plin5 labelling, particularly evident in the white matter of the (E,I) cerebellum, (F, G, J, K) cerebral cortex and (H–L) hippocampus. Representative Plin3-positive neuropil and astrocytes around (E') Purkinje cells, in (F') grey and (G') white matter of cerebral cortex are shown at higher magnification. Strong Plin5 labelling (I,I',J,K,K',L,L') outlines axonal fibres in all areas and (J') marks some glial cells. Scale bars: (A,D',E',F',G',I',J',K',L') 58 μm ; (B,C,J,K) 198 μm ; (D–L) 460 μm ; (C') 50 μm

to the other areas (Figure 2, B and C vs A and D). It is notable that in the cortex, Plin2 immunostaining had a fascicular appearance, stronger in grey than in white matter (Figure 2B,C), particularly, in neuronal cytoplasm and in proximal neuronal fibres, both in the apical dendrites and in the axons (Figure 2C',D'). Plin3 and Plin5 showed intense expression in all the areas examined, with more evident staining in the glial white matter compartment (Figure 2E–L). The difference between grey and white matter immunostaining intensity was more evident for Plin3 than Plin5 (Figure 2, F vs J and G vs K). Moreover, Plin3 staining appeared more evident in astrocytes (Figure 2E'–G'), whereas Plin5 staining seemed to highlight the fibres in their axonal or myelin component (Figure 2I'–L') and also marked some glial cells (Figure 2J').

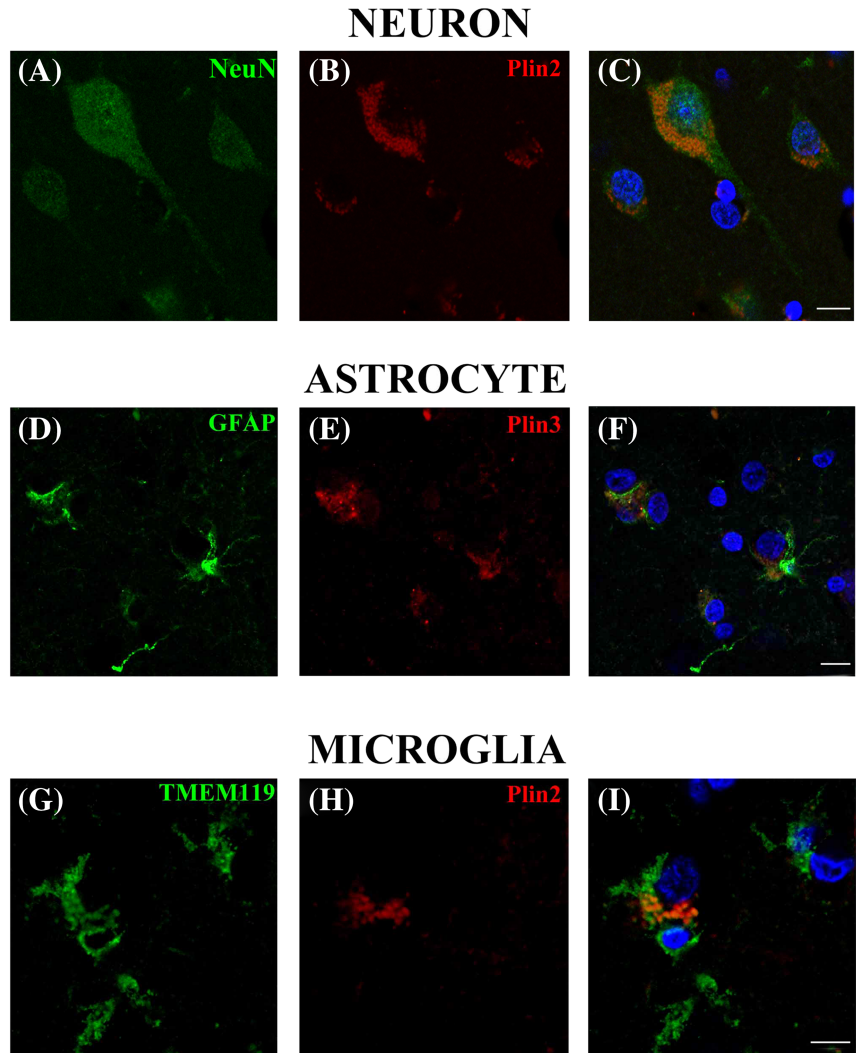
IHC analysis for Plin1 and Plin4 confirmed the almost total absence of these proteins, as observed with WB. Very weak expression was present only in some neurons of the cortical grey matter (Figure S1).

In order to confirm that in grey matter Plin2 is expressed prevalently in neurons and Plin3 in astrocytes, we performed a double

immunofluorescence labelling with antibodies specific for NeuN (neurons), GFAP (astrocytes), Plin2 and Plin3. Confocal microscopy analysis confirmed that Plin2 is expressed within NeuN+ cells (Figure 3A–C), whereas Plin3 is expressed within GFAP+ ones (Figure 3D–F). In contrast, Plin2 and Plin3 did not localise within GFAP+ and NeuN+ cells respectively (data not shown). The percentage of neurons positive for Plin2 was 66.5% (Figure S2A–D), whereas the percentage of astrocytes positive for Plin3 was 87.1% (Figure S2E–H), with apparently no difference between old and AD subjects (data not shown).

Because Plin3 was expressed primarily in white matter, we evaluated whether it was also expressed in oligodendrocytes. We tested the possible expression of Plin3 and Plin5 within Olig2+ cells, a marker for oligodendrocytes. Confocal microscopy indicated that Plin3 is not expressed in Olig2+ cells (Figure S3A–C), even though we cannot totally rule out that some Plin3+ oligodendrocytes do exist. In contrast, Olig2+ cells were positive for Plin5, suggesting that oligodendrocytes preferentially express Plin5 rather than Plin3 (Figure S3D–F).

FIGURE 3 Confocal microscopy analysis. Plin2 and Plin3 colocalisation with neuronal, astrocyte and microglia markers (NeuN, GFAP and TMEM119, respectively). (A–C) NeuN (green), Plin2 (red) and merge in neurons. (D–F) GFAP (green), Plin3 (red) and merge in astrocytes. (G–I) TMEM119 (green), Plin2 (red) and merge in microglia. Scale bars: (A–C) 10.5 μm ; (D–F) 15 μm ; (G–I) 10 μm



Finally, because it was recently reported that Plin2 is expressed in microglia of human and mouse brain [34], we checked the expression of Plin2 within cells positive for TMEM119, a marker of resident microglia [35]. We observed Plin2 expression in a few TMEM119-positive cells in the frontal cortex (Figure 3G–I).

Plin2 and Plin3 are expressed at high levels in old subjects

We then sought to determine whether the expression of Plins is modulated by age. WB analysis of Plins was conducted in samples from eight subjects of different age (from 33 to 82 years) without signs of neurodegeneration, subdivided in adult ($n = 3$) and old ($n = 5$) subjects. The results indicated that Plin2 was expressed more in old subjects in all the areas considered (Figure 4A–D), although it was not possible to determine whether the higher level of Plin2 expression observed with old age was due to an increased number of neurons expressing Plin2, an increased expression per neuron, or both. Also, Plin3 appeared to be expressed slightly more in the elderly; however,

the difference was never statistically significant (Figure 4A–D). Plin5 was expressed similarly in all subjects (Figure 4A–D). Furthermore, a partial investigation into exceptional longevity was possible due to the availability of frontal cortex from three centenarians. A comparison of Plin2, Plin3 and Plin5 protein expression with three adult and four old subjects was then performed. Samples from centenarians did not differ from those of old subjects. Also, in these cases, only Plin2, Plin3 and Plin5 were detectable, and Plin2 expression was similar to that of old subjects and higher with respect to that of adults. Plin3 and Plin5 were expressed to a similar extent in all the three age groups (Figure S4A–D). As expected, Plin1 and Plin4 were undetectable (data not shown).

Plin2 is expressed more in subjects with neurodegenerative diseases

Because age is the most important risk factor for neurodegeneration, in the light of the above-described results, we investigated the expression levels of Plins in samples from patients with signs of

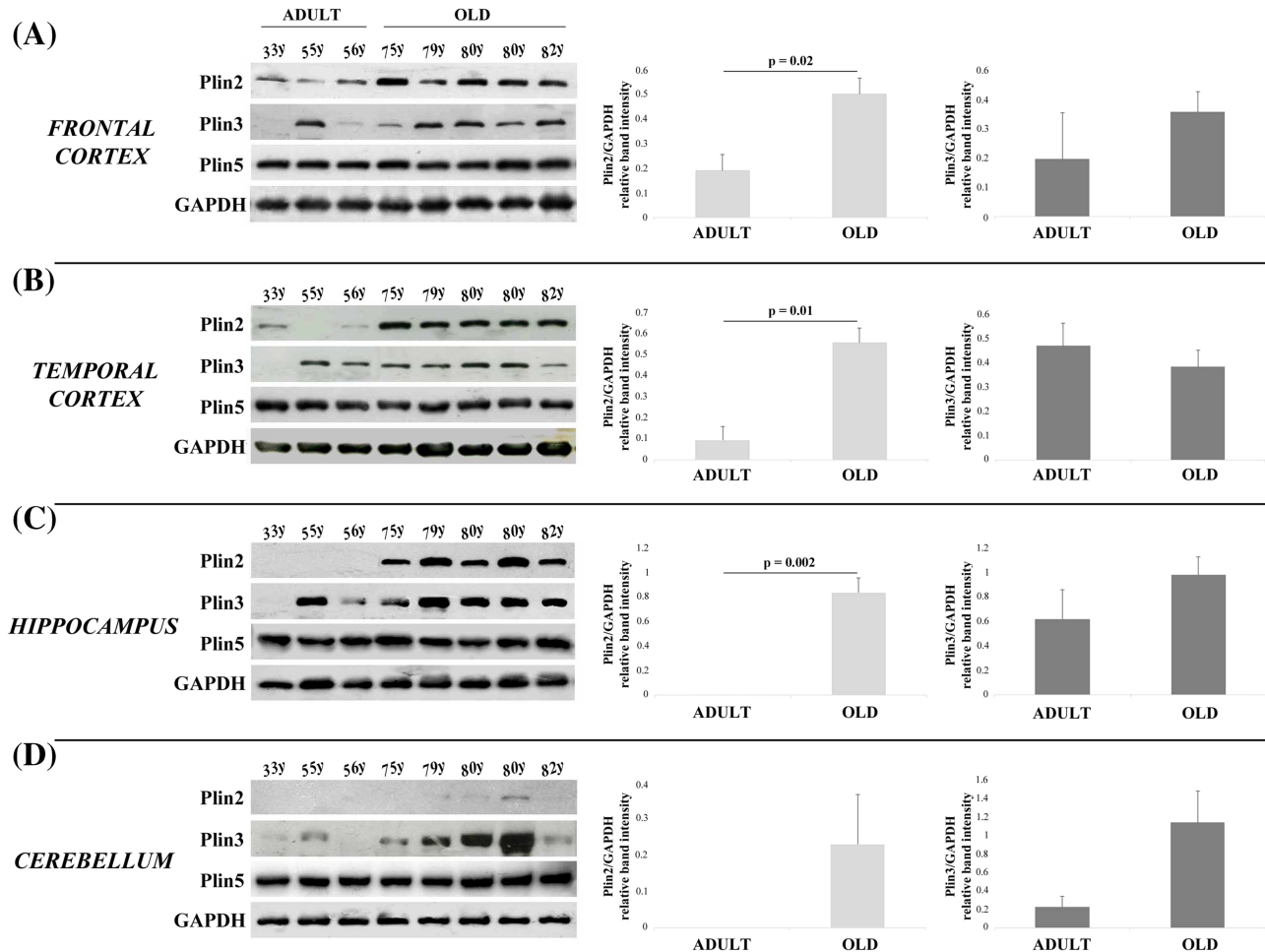


FIGURE 4 Western blotting (WB) analysis of Plins protein in different brain areas from control subjects of different age. (A–D) Representative immunoblotting image of Plin2, Plin3, Plin5 and relative protein expression of Plin2 and Plin3 in (A) frontal cortex, (B) temporal cortex, (C) hippocampus and (D) cerebellum. The bars represent mean \pm SE. Mann–Whitney test was applied. WB quantification of Plins expression performed using ImageJ software and normalised to GAPDH protein expression

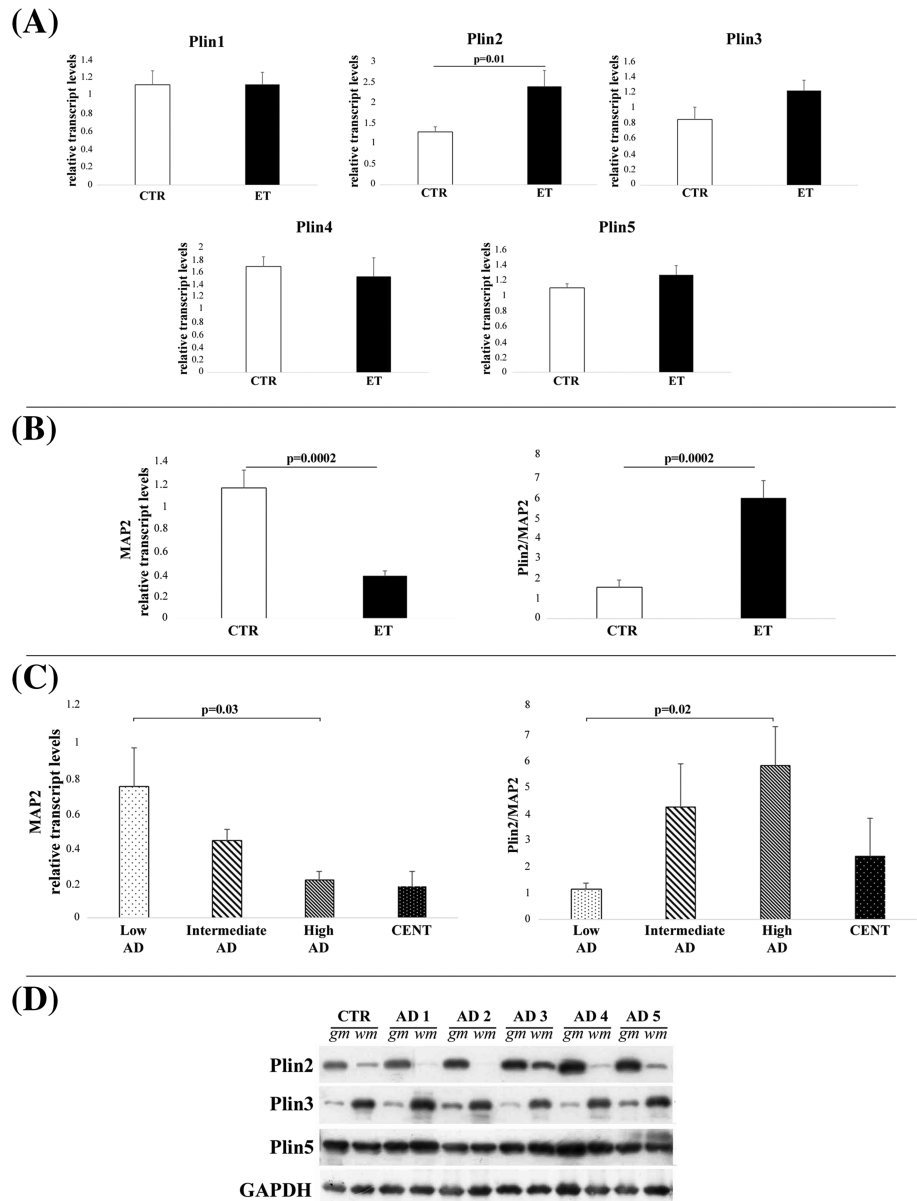
neurodegeneration. We first compared the transcript levels of Plins in samples of frontal cortex from 10 patients with ET to nine age-matched controls without neurodegenerative diseases, in order to identify possible different expression levels of Plins at the very early stages of the neuropathology. At variance with protein expression, the transcripts of Plin1 and Plin4 were detectable in these samples. Only the expression level of Plin2, but not that of all the other Plins, appeared higher in ET patients with respect to controls (Figure 5A). Because Plin2 was localised in neurons according to the IHC analysis, and because neurodegeneration is characterised by a decrease in the number of neurons, this result could appear paradoxical. In fact, in ET samples, the expression level of MAP2, a neuron-specific gene, was decreased with respect to controls, as expected (Figure 5B, left panel), and when Plin2 expression was normalised with respect to MAP2, the difference to controls was even more significant (Figure 5B, right panel). This result suggests that neurons from ET samples might be characterised by a very high level of Plin2 expression. To further support this hypothesis, we performed IHC of Plin2 in brain samples from ET patients (Braak stages I–II, without relevant amyloid load). Plin2

immunoreactivity showed a diffuse and intense staining of pyramidal neurons (Figure S5).

Real-time analysis was also performed in frontal cortex samples from patients with different severity of AD (low, intermediate and high, based on neuropathological diagnosis [30]) and from centenarians. As expected, the expression of MAP2 decreased with increasing severity of AD and with age (Figure 5C, left panel). We observed that the Plin2/MAP2 ratio is higher in patients with high AD with respect to patients with low and intermediate AD (Figure 5C, right panel). Notably, the Plin2/MAP2 ratio in centenarians was strikingly lower compared with high or intermediate AD patients and more similar to that of low AD patients, despite the low expression of MAP2. This suggests that, despite the decrease in number, the neurons of centenarians are different from those of AD patients in terms of Plin2 expression (and therefore lipid accumulation) and more similar to those of 70- to 80-year-old people with little neurodegeneration. This result agrees with WB analysis showing that centenarians have levels of Plin2 protein expression that are similar to those of old people (Figure S2).

FIGURE 5 Plins mRNA and protein expression analysis in early tauopathy (ET) or Alzheimer's disease (AD) patients. (A) Relative transcript levels of Plin1, Plin2, Plin3, Plin4 and Plin5 in frontal cortex samples from 10 patients with ET and nine age-matched controls.

(B) Relative transcript levels of MAP2 (left panel) and Plin2/MAP2 ratio (right panel) of the samples as in (A). (C) Relative transcript levels of MAP2 (left panel) and Plin2/MAP2 ratio (right panel) of patients with low, intermediate and high AD and centenarians. (D) Immunoblotting image of Plin2, Plin3 and Plin5 in grey (gm) and white (wm) matter from frontal cortex of AD patients as compared with one age-matched control. The bars represent mean \pm SE. Student's *t* and one-way ANOVA tests were applied



Because Plin2 appears to be expressed mainly in grey matter neurons, according to IHC, in order to be sure that the result from AD samples was not due to randomly different proportions of grey and white matter in the samples from which the RNA was extracted, we explored the protein expression of Plins in samples of grey and white matter of frontal cortex from AD patients. In agreement with IHC analyses, Plin2 was expressed more in grey matter, whereas Plin3 was expressed more in white matter (Figure 5D). Moreover, Plin2 expression was higher in grey matter samples of AD patients with respect to the control sample (Figure 5D), confirming the results from transcript analysis. No significant difference was found for Plin5 (Figure 5D), whereas, at variance with the transcript levels, Plin1 and Plin4 were undetectable in all subjects analysed (data not shown). This discrepancy between transcription and protein levels is not unusual for Plins, as already reported in other studies performed on different cell types,

such as adipocytes, suggesting the existence of a post-translational regulation mediated by the ubiquitin/proteasome pathway [36, 37].

Plin2 expression correlates with IL-6

Recent evidence indicates that Plin2 can be considered a marker not only of LDs but also of inflammation in the brain [16, 34, 38]. To explore this hypothesis, we analysed transcript levels of Plins and IL-6, a pro-inflammatory cytokine involved in neurodegenerative disorders such as AD [39]. Spearman correlation analysis (Table 1) and linear regression analysis (Figure 6A) performed in frontal cortex samples from nine control subjects, 10 ET patients, 15 AD patients and three centenarians, indicated that only Plin2 was positively and significantly correlated with IL-6, confirming that Plin2 is related to

inflammatory phenomena and suggesting that Plin2 may be involved in neurodegeneration.

In order to obtain insight into the possible causal relationship between Plin2 and IL-6, we took advantage of primary DF cultures that are now considered a reliable model system to study metabolic abnormalities related to neurodegenerative diseases [40, 41]. We treated DFs with metformin, a glucose-lowering drug able to modulate lipid metabolism and inflammatory response [42–44]. Treatment

with 1 mM metformin for 48 h induced no change in the expression of Plin2 in controls, a decrease in AD cases and an increase in centenarians (Figure 6B). Consistently, IL-6 expression followed the same trend of Plin2 (Figure 6C), suggesting that Plin2 and IL-6 levels are connected.

DISCUSSION

A number of studies have addressed the question of expression of Plins in the brain [18, 45]; however, in most cases, these studies focused either on Plins as LDs markers or on specific cell types or diseases. Moreover, there is a general lack of knowledge on the age-related variability in their expression. For example, a recent study reported that the majority of LDs in the brain are found in the microglia [34], whereas other studies showed the presence of LDs in a tiny number of cells (the above-mentioned LLCs), in meningeal, cortical and neurogenic brain regions [7]. However, considering that LDs are almost universal organelles and lipid accumulation has been demonstrated in both neurons and astrocytes in lesions [46], as well as in GFAP+ cells that are closely associated to the ependymal niche [47], it is likely that LDs are more widespread in the brain than previously

TABLE 1 Spearman correlation analysis between interleukin-6 (IL-6) and perilipin (Plin)1, Plin2, Plin3, Plin4 and Plin5

Correlation of Plins with IL-6	ρ	p
Plin1	0.025	n.s.
Plin2	0.456	0.005
Plin3	0.022	n.s.
Plin4	-0.057	n.s.
Plin5	-0.037	n.s.

Note: Significance level of p value is <0.05. n.s. = not significant; ρ = Spearman rank correlation coefficient, rho. Plin2 is the only protein significantly and positively correlated with IL-6 (shown in bold).

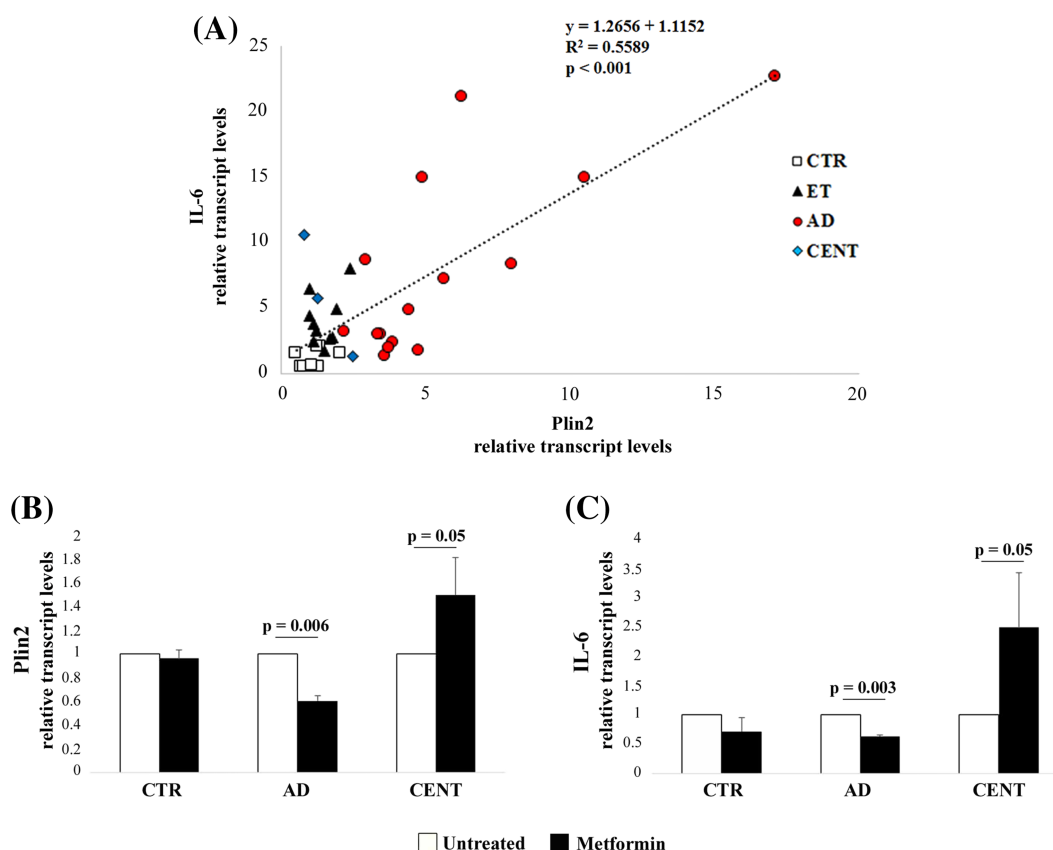


FIGURE 6 Plin2 and IL-6 analysis. (A) Regression analysis of relative transcript values of Plin2 and IL-6 in frontal cortex samples from nine control subjects (CTR), 10 early tauopathy (ET) patients, 15 Alzheimer’s disease (AD) patients and three centenarians (CENT). (B, C) Relative transcript levels of (B) Plin2 and (C) IL-6 in dermal fibroblast cultures from five CTR, two AD and three CENT, with or without 1 mM metformin for 48 h. Data are expressed as mean \pm SD. Student’s t test was applied

thought and possibly differ in regard to the expression of PAT family according to the specificities and needs of the cell type. In this study, we have checked the expression pattern of all the members of the PAT family in different areas and cell types of human brain, and we included in the study autoptic samples from subjects of different ages, with or without signs of neurodegeneration, in particular patients with ET or AD. We showed that only Plin2, Plin3 and Plin5 are expressed at the protein level and are expressed with variable intensity in different brain areas. In particular, Plin2 appears expressed more in grey matter and in neurons, in all the areas analysed (frontal and temporal cortex, hippocampus and cerebellum, though in the latter, the expression is weaker), whereas Plin3 and Plin5 appear expressed more in white matter. Moreover, Plin3 seems expressed more in astrocytes, whereas Plin5 appears to be expressed in many cell types, including oligodendrocytes. Interestingly, Plin2 is the only member of the PAT family to be modulated by age or neurodegeneration.

The presence of LLCs has been reported to increase with age [7], and more recently, Marschallinger et al. reported that microglia from old animals and humans display elevated numbers of LDs [34]. In our hands, samples from old people or from ET or AD patients showed increased expression of Plin2, but not of Plin5, whereas Plin3 showed a trend to increase as well, especially in frontal cortex and cerebellum, however, without reaching statistical significance. To date, Plin2 (together with Plin3) has been adopted only as a marker for the presence of LDs, but no one, to the best of our knowledge, has investigated Plin2 and other PAT family members in order to understand whether a possible shift in the expression level of Plins does occur with age or disease. Our results suggest that Plin2 may be correlated with advancing age and neurodegeneration. Of note, centenarians that represent examples of extreme longevity display Plin2 levels similar to those of 70- to 80-year-old people or patients with

low AD, indicating that the brain of these exceptional subjects are likely to be younger than their chronological age, at least as far as LDs accumulation, in agreement with epigenetic and proteomic data [48].

Interestingly, our data strongly suggest that Plin2 is also expressed more in patients with either ET or AD. In particular, the fact that Plin2 appears to be elevated in patients with low levels of neurodegeneration, such as ET, suggests that it could be involved in the early phases of the neurodegeneration. Actually, lipid accumulation has been already reported in neurodegeneration [16, 49–51]; however, it is possible that lipids that accumulate in Plin2-expressing LDs are more detrimental than others. This hypothesis should be tested by future studies. However, it is known that Plin2 is associated not only with LDs, and thus with intracellular accumulation of lipids, but also with inflammation (reviewed in Farmer et al. [16]). In particular, it has been demonstrated that the manipulation of Plin2 expression affects pro-inflammatory parameters. As an example, the overexpression of Plin2 in macrophages increases the mRNA levels and production of IL-6, TNF α and MCP-1, whereas Plin2 knock-down has the opposite effect [52]. Moreover, hepatic-specific knockout of Plin2 protected mice from high-fat diet induced steatosis and decreased the expression of cyclo-oxygenase 2, IL-6, TNF- α and IL-1 β [53]. In another study, Plin2 knockout inhibited an LPS-induced inflammatory response [54]. Therefore, the existence of a causal link between Plin2 accumulation and neuroinflammation is more than likely, and the data presented here may suggest that the same Plin2-IL-6 link exists at brain level and agrees with the hypothesis of the inflammatory origin of neurodegenerative diseases. Indeed, here, we reported that the expression of Plin2, but not other PAT family members, is associated in the brain with the expression of IL-6. To further prove the link between Plin2 and IL-6, we treated 10 DF lines from healthy controls, AD patients and centenarians with metformin, a biguanide widely

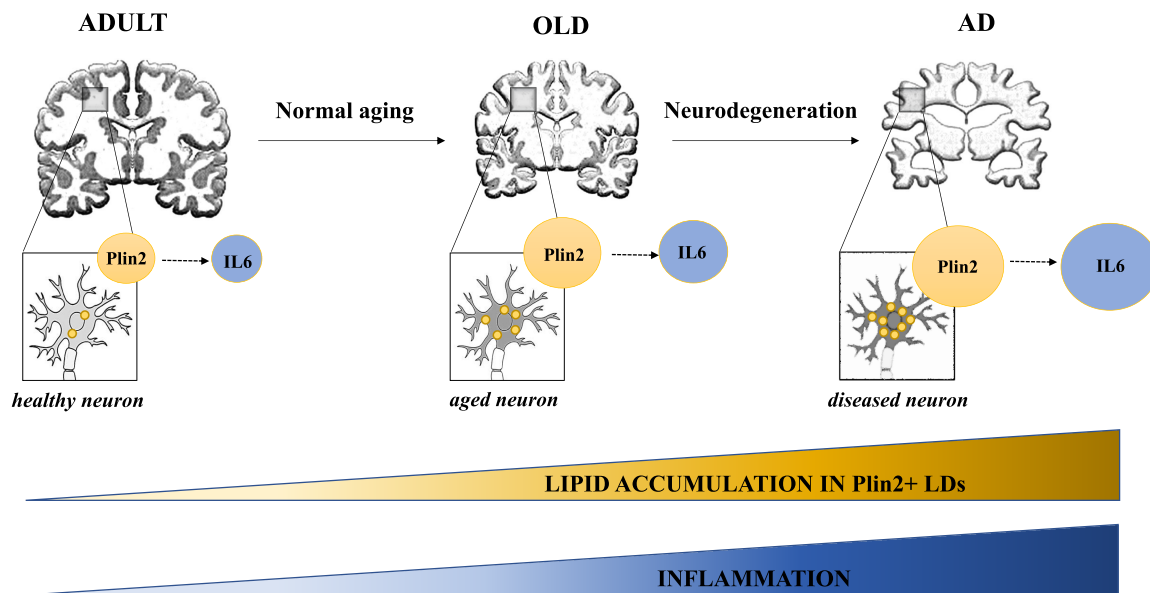


FIGURE 7 Schematic representation of the role of Plin2 in the brain considered as a continuum. We hypothesise that during aging and in neurodegenerative diseases such as Alzheimer's disease (AD), there is an accumulation of Plin2 (and consequently of Plin2-associated lipid droplets [LDs]) that may lead to a concomitant (possibly causal) increase in the expression of IL-6. See text for details

used as antidiabetic drug known to impact on lipid metabolism and inflammation [44, 55, 56]. We observed three distinct responses to metformin in terms of Plin2 transcript expression (no effect in healthy controls, decreased expression in AD patients and increased expression in centenarians), and interestingly, the expression of IL-6, in the same samples, always followed the same trend. As a whole, these data are compatible with the hypothesis that there is a causal link between Plin2 and inflammation. Further studies are needed to better clarify the precise mechanisms for the differential responses observed in DF lines, however, it has been reported that in different tissues, metformin can have opposite effects on the expression of Plin2 [57, 58].

Our data support, though indirectly, the idea that in the brain Plin2 plays a role in neuroinflammation and support the hypothesis that neuroinflammation is an early event in the pathogenesis of neurodegeneration [59, 60], where Plin2 may have a still unrecognised role. Further studies are needed to prove this hypothesis.

In the important study of Marschallinger et al. [34], microglial cells were reported to express both Plin2 and Plin3. However, these authors did not report on markers for cell types other than Iba1, TMEM119 or CD68, meaning that they limited their investigation to microglial cells only. We report that some TMEM119⁺ cells do express Plin2; however, our IHC analysis suggests that Plin2 and Plin3 are mostly expressed in neurons and astrocytes, respectively, but we cannot exclude that these Plins can be expressed in other cell types. Moreover, our analysis adds to the data by Marschallinger et al. [34], indicating that Plin2, but not other PAT family members, seems to accumulate with age and disease.

To summarise, our study indicates that Plins are widely expressed in human brain, with some differences in the distribution among different areas, and especially between white and grey matter. However, the most important finding is that Plin2 appears to be the only PAT family member to be modulated with age and neuroinflammation. Accordingly, we propose that lipid accumulation occurs physiologically in the aging brain within Plin2-decorated LDs, and this accumulation may be the initial inflammatory step toward neurodegeneration (Figure 7). Furthermore, Plin2 may be a connection between brain aging and inflammation. This hypothesis is also in agreement with the more general one of a continuum between aging and age-related diseases [61]. Some aspects remain unclear, including the precise role of Plins in the lipid metabolism of different cell types (in particular, Plin3 and Plin5 that result strongly expressed at the level of the glial compartment), and warrant further studies.

ACKNOWLEDGEMENTS

The authors gratefully acknowledge the ‘Centro Interdipartimentale Grandi Strumenti (C.I.G.S.)’ of the University of Modena and Reggio Emilia (Italy) for the confocal microscopy facilities and Dr Tatiana Gianni of the Department of Experimental, Diagnostic and Specialty Medicine, University of Bologna, for assistance in fluorescence microscopy. This paper is dedicated to the persons who allowed the execution of the study by donating their brain, and to their families. The study was partially supported by the Roberto and Cornelia Pallotti Legacy for Cancer Research to S.S. and Ministry of Science and

Higher Education at the Lobachevsky State University of Nizhny Novgorod Agreement No. 075-15-2019-871 to C.F.

CONFLICT OF INTEREST

The authors declare no conflicts.

AUTHOR CONTRIBUTIONS

M.C. was responsible for the design and conceptualisation of study, Bologna biobank management, conduction of the research, data generation and analysis, statistical analysis and writing of the manuscript. V.M., A.C., A.D. and Ma.Ch. were responsible for the Abbiategrosso biobank management, tissue preparation, IHC data generation and analysis. D.M. was responsible for the confocal microscopy analysis and data interpretation. A.C. was responsible for the real-time RT-PCR and WB data generation and analysis, primary dermal fibroblast management and experiment conduction. F.V. was responsible for the IHC data generation and analysis. G.L. and S.V. were responsible for the MRC Edinburgh Brain Bank and HUB-ICO-IDIBELL Biobank management and manuscript revision. I.S. was responsible for the HUB-ICO-IDIBELL Biobank management. G.M. was responsible for centenarian samples management, neuropathological diagnosis and manuscript revision. T.E.P. and A.G. were responsible for the Abbiategrosso biobank management, clinical and neuropathological diagnosis, manuscript revision for intellectual content and critical discussion. C.F. was responsible for the design and conceptualisation of study, manuscript revision for intellectual content and critical discussion. S.S. was responsible for the design and conceptualisation of study, Bologna biobank management, data analysis and writing of the manuscript.

ETHICS STATEMENT

All samples were collected according to the guidelines of the local ethical committees (see Section 2 for details).

PEER REVIEW

The peer review history for this article is available at <https://publons.com/publon/10.1111/nan.12756>.

DATA AVAILABILITY STATEMENT

The data that support the findings of this study are available from the corresponding author upon reasonable request.

ORCID

Maria Conte  <https://orcid.org/0000-0002-4621-9898>

Giuseppe Legname  <https://orcid.org/0000-0003-0716-4393>

Isidre Ferrer  <https://orcid.org/0000-0001-9888-8754>

REFERENCES

- Hafkemeijer A, Altmann-Schneider I, de Craen AJ, Slagboom PE, van der Grond J, Rombouts SA. Associations between age and gray matter volume in anatomical brain networks in middle-aged to older adults. *Aging Cell*. 2014;13(6):1068-1074.
- Farokhian F, Yang C, Beheshti I, Matsuda H, Wu S. Age-related gray and white matter changes in normal adult brains. *Aging Dis*. 2017; 8(6):899-909.

3. Mattson MP, Arumugam TV. Hallmarks of brain aging: adaptive and pathological modification by metabolic states. *Cell Metab.* 2018; 27(6):1176-1199.
4. Cutler RG, Kelly J, Storie K, et al. Involvement of oxidative stress-induced abnormalities in ceramide and cholesterol metabolism in brain aging and Alzheimer's disease. *Proc Natl Acad Sci.* 2004;101(7): 2070-2075.
5. Spassieva SD, Ji X, Liu Y, et al. Ectopic expression of ceramide synthase 2 in neurons suppresses neurodegeneration induced by ceramide synthase 1 deficiency. *Proc Natl Acad Sci.* 2016;113(21): 5928-5933.
6. Czubowicz K, Jęśko H, Wencel P, Lukiw WJ, Strosznajder RP. The role of ceramide and sphingosine-1-phosphate in Alzheimer's disease and other neurodegenerative disorders. *Mol Neurobiol.* 2019;56(8): 5436-5455.
7. Shimabukuro MK, Langhi LG, Cordeiro I, et al. Lipid-laden cells differentially distributed in the aging brain are functionally active and correspond to distinct phenotypes. *Sci Rep.* 2016;6(1):23795.
8. Chappus-McCendie H, Chevalier L, Roberge C, Plourde M. Omega-3 PUFA metabolism and brain modifications during aging. *Prog Neuropsychopharmacol Biol Psychiatry.* 2019;94:109662.
9. Hussain G, Anwar H, Rasul A, et al. Lipids as biomarkers of brain disorders. *Crit Rev Food Sci Nutr.* 2020;60(3):351-374.
10. Kao YC, Ho PC, Tu YK, Jou IM, Tsai KJ. Lipids and Alzheimer's disease. *Int J Mol Sci.* 2020;21(4):E1505.
11. Kraemer N, Farese RV Jr, Walther TC. Balancing the fat: lipid droplets and human disease. *EMBO Mol Med.* 2013;5(7):973-983.
12. Palikaras K, Mari M, Petanidou B, Pasparaki A, Filippidis G, Tavernarakis N. Ectopic fat deposition contributes to age-associated pathology in *Caenorhabditis elegans*. *J Lipid Res.* 2017;58(1):72-80.
13. Conte M, Franceschi C, Sandri M, Salvioli S. Perilipin 2 and age-related metabolic diseases: a new perspective. *Trends Endocrinol Metab.* 2016;27(12):893-903.
14. Olzmann JA, Carvalho P. Dynamics and functions of lipid droplets. *Nat Rev Mol Cell Biol.* 2019;20(3):137-155.
15. Onal G, Kutlu O, Gozuacik D, Dokmeci ES. Lipid droplets in health and disease. *Lipids Health Dis.* 2017;16(1):128.
16. Farmer BC, Walsh AE, Kluemper JC, Johnson LA. Lipid droplets in neurodegenerative disorders. *Front Neurosci.* 2020;14:742.
17. Bickel PE, Tansey JT, Welte MA. PAT proteins, an ancient family of lipid droplet proteins that regulate cellular lipid stores. *Biochim Biophys Acta.* 1791;2009:419-440.
18. Itabe H, Yamaguchi T, Nimura S, Sasabe N. Perilipins: a diversity of intracellular lipid droplet proteins. *Lipids Health Dis.* 2017; 16(1):83.
19. Kaushik S, Cuervo AM. Degradation of lipid droplet associated proteins by chaperone-mediated autophagy facilitates lipolysis. *Nat Cell Biol.* 2015;17(6):759-770.
20. Kaushik S, Cuervo AM. AMPK-dependent phosphorylation of lipid droplet protein PLIN2 triggers its degradation by CMA. *Autophagy.* 2016;12(2):432-438.
21. Xu S, Zou F, Diao Z, et al. Perilipin 2 and lipid droplets provide reciprocal stabilization. *Biophys Rep.* 2019;5(3):145-160.
22. Greenberg AS, Coleman RA, Kraemer FB, et al. The role of lipid droplets in metabolic disease in rodents and humans. *J Clin Invest.* 2011;121(6):2102-2110.
23. Zhang P, Meng L, Song L, et al. Roles of perilipins in diseases and cancers. *Curr Genomics.* 2018;19(4):247-257.
24. Conte M, Vasuri F, Trisolino G, et al. Increased Plin2 expression in human skeletal muscle is associated with sarcopenia and muscle weakness. *PLoS One.* 2013;8(8):e73709.
25. Conte M, Vasuri F, Bertaggia E, et al. Differential expression of perilipin 2 and 5 in human skeletal muscle during aging and their association with atrophy-related genes. *Biogerontology.* 2015;16(3): 329-340.
26. Conte M, Armani A, Conte G, et al. Muscle-specific Perilipin2 down-regulation affects lipid metabolism and induces myofiber hypertrophy. *J Cachexia Sarcopenia Muscle.* 2019;10(1):95-110.
27. Varela GM, Antwi DA, Dhir R, et al. Inhibition of ADRP prevents diet-induced insulin resistance. *Am J Physiol Gastrointest Liver Physiol.* 2008;295(3):G621-G628.
28. Ji J, Petropavlovskaja M, Khatchadourian A, et al. Type 2 diabetes is associated with suppression of autophagy and lipid accumulation in β -cells. *J Cell Mol Med.* 2019;23(4):2890-2900.
29. Sato S, Suzuki J, Hirose M, et al. Cardiac overexpression of perilipin 2 induces atrial steatosis, connexin 43 remodeling, and atrial fibrillation in aged mice. *Am J Physiol Endocrinol Metab.* 2019;317(6): E1193-E1204.
30. Montine TJ, Phelps CH, Beach TG, et al. National Institute on Aging-Alzheimer's Association guidelines for the neuropathologic assessment of Alzheimer's disease: a practical approach. *Acta Neuropathol.* 2012;123(1):1-11.
31. American Psychiatric Association. *Diagnostic and statistical manual of mental disorders (DSM-5®)* [Internet]. American Psychiatric Publishing; 2013. Available from <https://books.google.it/books?id=JivBAAAQBAJ>
32. Poloni TE, Medici V, Carlos AF, et al. Abbiatograsso Brain Bank Protocol for collecting, processing and characterizing aging brains. *J Vis Exp.* 2020;160.
33. Schindelin J, Arganda-Carreras I, Frise E, et al. Fiji: an open-source platform for biological-image analysis. *Nat Methods.* 2012;9(7):676-682.
34. Marschallinger J, Iram T, Zardeneta M, et al. Lipid-droplet-accumulating microglia represent a dysfunctional and proinflammatory state in the aging brain. *Nat Neurosci.* 2020;23:194-208.
35. Satoh J, Kino Y, Asahina N, et al. TMEM119 marks a subset of microglia in the human brain. *Neuropathology.* 2016;36(1):39-49.
36. Xu G, Sztalryd C, Londos C. Degradation of perilipin is mediated through ubiquitination-proteasome pathway. *Biochim Biophys Acta.* 2006;1761(1):83-90.
37. Takahashi Y, Shinoda A, Kamada H, et al. Perilipin2 plays a positive role in adipocytes during lipolysis by escaping proteasomal degradation. *Sci Rep.* 2016;6(1):20975.
38. Kwon YH, Kim J, Kim CS, et al. Hypothalamic lipid-laden astrocytes induce microglia migration and activation. *FEBS Lett.* 2017;591(12): 1742-1751.
39. Rothaug M, Becker-Pauly C, Rose-John S. The role of interleukin-6 signaling in nervous tissue. *Biochim Biophys Acta.* 1863;2016: 1218-1227.
40. Gasparini L, Racchi M, Binetti G, et al. Peripheral markers in testing pathophysiological hypotheses and diagnosing Alzheimer's disease. *FASEB j.* 1998;12(1):17-34.
41. Pérez MJ, Ponce DP, Osorio-Fuentealba C, Behrens MI, Quintanilla RA. Mitochondrial bioenergetics is altered in fibroblasts from patients with sporadic Alzheimer's disease. *Front Neurosci.* 2017;11:553.
42. Giugliano D, De Rosa N, Di Maro G, et al. Metformin improves glucose, lipid metabolism, and reduces blood pressure in hypertensive, obese women. *Diabetes Care.* 1993;16(10):1387-1390.
43. Wang N, Zhang J, Wu Y, Liu J, Liu L, Guo X. Metformin improves lipid metabolism disorders through reducing the expression of microsomal triglyceride transfer protein in OLETF rats. *Diabetes Res Clin Pract.* 2016;122:170-178.
44. Kim HS, Ren G, Kim T, et al. Metformin reduces saturated fatty acid-induced lipid accumulation and inflammatory response by restoration of autophagic flux in endothelial cells. *Sci Rep.* 2020;10(1):13523.
45. Teixeira V, Maciel P, Costa V. Leading the way in the nervous system: lipid droplets as new players in health and disease. *Biochim Biophys Acta Mol Cell Biol Lipids.* 1866;2021:158820.
46. Ioannou MS, Jackson J, Sheu SH, et al. Neuron-astrocyte metabolic coupling protects against activity-induced fatty acid toxicity. *Cell.* 2019;177:1522.e14-1535.e14.

47. Hamilton LK, Fernandes KJL. Neural stem cells and adult brain fatty acid metabolism: lessons from the 3xTg model of Alzheimer's disease. *Biol Cell*. 2018;110(1):6-25.
48. Horvath S, Pirazzini C, Bacalini MG, et al. Decreased epigenetic age of PBMCs from Italian semi-supercentenarians and their offspring. *Aging*. 2015;7(12):1159-1170.
49. Cole NB, Murphy DD, Grider T, Rueter S, Brasaemle D, Nussbaum RL. Lipid droplet binding and oligomerization properties of the Parkinson's disease protein alpha-synuclein. *J Biol Chem*. 2002;277(8):6344-6352.
50. Pennetta G, Welte MA. Emerging links between lipid droplets and motor neuron diseases. *Dev Cell*. 2018;45(4):427-432.
51. van der Kant R, Langness VF, Herrera CM, et al. Cholesterol metabolism is a druggable axis that independently regulates tau and amyloid- β in iPSC-derived Alzheimer's disease neurons. *Cell Stem Cell*. 2019;24:363.e9-375.e9.
52. Chen FL, Yang ZH, Wang XC, et al. Adipophilin affects the expression of TNF-alpha, MCP-1, and IL-6 in THP-1 macrophages. *Mol Cell Biochem*. 2010;337(1-2):193-199.
53. Najt CP, Senthivayagam S, Aljazi MB, et al. Liver-specific loss of Perilipin 2 alleviates diet-induced hepatic steatosis, inflammation, and fibrosis. *Am J Physiol Gastrointest Liver Physiol*. 2016;310(9):G726-G738.
54. Tan Y, Zhang H, Guo D, Wang J, Yuan X, Yuan Z. Adipophilin involved in lipopolysaccharide-induced inflammation in RAW264.7 cell via extracellular signal-regulated kinase 1/2-peroxisome proliferator-activated receptor gamma pathway. *DNA Cell Biol*. 2017;36:1159-1167.
55. Saisho Y. Metformin and inflammation: its potential beyond glucose-lowering effect. *Endocr Metab Immune Disord Drug Targets*. 2015;15(3):196-205.
56. Liu F, Wang C, Zhang L, et al. Metformin prevents hepatic steatosis by regulating the expression of adipose differentiation-related protein. *Int J Mol Med*. 2014;33(1):51-58.
57. Phillips SA, Choe CC, Ciaraldi TP, et al. Adipocyte differentiation-related protein in human skeletal muscle: relationship to insulin sensitivity. *Obes Res*. 2005;13(8):1321-1329.
58. Wang WY, Tan MS, Yu JT, Tan L. Role of pro-inflammatory cytokines released from microglia in Alzheimer's disease. *Ann Transl Med*. 2015;3:136.
59. Wu YY, Hsu JL, Wang HC, Wu SJ, Hong CJ, Cheng IH. Alterations of the neuroinflammatory markers IL-6 and TRAIL in Alzheimer's disease. *Dement Geriatr Cogn Dis Extra*. 2015;5(3):424-434.
60. Kinney JW, Bemiller SM, Murtishaw AS, Leisgang AM, Salazar AM, Lamb BT. Inflammation as a central mechanism in Alzheimer's disease. *Alzheimers Dement*. 2018;4(1):575-590.
61. Franceschi C, Garagnani P, Morsiani C, et al. The continuum of aging and age-related diseases: common mechanisms but different rates. *Front Med*. 2018;5:61.

SUPPORTING INFORMATION

Additional supporting information may be found online in the Supporting Information section at the end of this article.

How to cite this article: Conte M, Medici V, Malagoli D, et al. Expression pattern of perilipins in human brain during aging and in Alzheimer's disease. *Neuropathol Appl Neurobiol*. 2022; 48(1):e12756. <https://doi.org/10.1111/nan.12756>