

# VU Research Portal

## Evaluation of clinical tests for partial distal biceps tendon ruptures and tendinitis

Caekebeke, Pieter; Meglic, Uros; van den Bekerom, Michel P.J.; van Riet, Roger

### **published in**

Journal of Shoulder and Elbow Surgery  
2022

### **DOI (link to publisher)**

[10.1016/j.jse.2021.10.012](https://doi.org/10.1016/j.jse.2021.10.012)

### **document version**

Publisher's PDF, also known as Version of record

### **document license**

Article 25fa Dutch Copyright Act

### [Link to publication in VU Research Portal](#)

### **citation for published version (APA)**

Caekebeke, P., Meglic, U., van den Bekerom, M. P. J., & van Riet, R. (2022). Evaluation of clinical tests for partial distal biceps tendon ruptures and tendinitis. *Journal of Shoulder and Elbow Surgery*, 31(3), 532-536. <https://doi.org/10.1016/j.jse.2021.10.012>

### **General rights**

Copyright and moral rights for the publications made accessible in the public portal are retained by the authors and/or other copyright owners and it is a condition of accessing publications that users recognise and abide by the legal requirements associated with these rights.

- Users may download and print one copy of any publication from the public portal for the purpose of private study or research.
- You may not further distribute the material or use it for any profit-making activity or commercial gain
- You may freely distribute the URL identifying the publication in the public portal ?

### **Take down policy**

If you believe that this document breaches copyright please contact us providing details, and we will remove access to the work immediately and investigate your claim.

### **E-mail address:**

[vuresearchportal.ub@vu.nl](mailto:vuresearchportal.ub@vu.nl)



# Evaluation of clinical tests for partial distal biceps tendon ruptures and tendinitis

Pieter Caekebeke, MD<sup>a,\*</sup>, Uros Meglic, MD<sup>b</sup>,  
Michel P.J. van den Bekerom, MD, PhD<sup>c,d</sup>, Roger van Riet, MD, PhD<sup>e,f,g</sup>

<sup>a</sup>Department of Orthopaedic Surgery and Traumatology, Ziekenhuis Oost-Limburg, Genk, Belgium

<sup>b</sup>Department of Orthopaedic Surgery, University Medical Centre Ljubljana, Ljubljana, Slovenia

<sup>c</sup>Department of Orthopedic Surgery, OLVG, Amsterdam, the Netherlands

<sup>d</sup>Department of Human Movement Sciences, Amsterdam Movement Sciences, Vrije Universiteit Amsterdam, Amsterdam, the Netherlands

<sup>e</sup>Department of Orthopedic Surgery, AZ Monica, Antwerp, Belgium

<sup>f</sup>Department of Orthopedic Surgery, University Hospital Antwerp, Edegem, Belgium

<sup>g</sup>Orthopaedic Specialists, Harley Street Specialist Hospital, London, UK

**Background:** The clinical diagnosis of partial distal biceps tendon ruptures or tendinosis can be challenging. Three clinical tests have been described to aid in an accurate and timely diagnosis: biceps provocation test, tilt sign, and resisted hook test. However, not much is known about the sensitivity, specificity, and inter-rater reliability as the available evaluations are based on small groups or are case based. Furthermore, these tests have not been compared together in the same patient group.

**Methods:** Two dedicated elbow surgeons each included 20 consecutive patients in whom distal biceps tendon pathology was suspected. Patients with a complete distal biceps tendon tear were excluded. As a control, the same number of consecutive patients with various elbow pathologies other than distal biceps tendon problems was included. All 3 tests were performed both in control patients and in patients with suspected biceps tendon pathology. Magnetic resonance imaging (MRI) in the flexion-abduction-supination view and/or surgical exploration was performed in both groups. The findings of the clinical tests were determined before the results of MRI and other technical investigations were analyzed. The values of sensitivity, specificity, and accuracy were calculated.

**Results:** The combined sensitivity, specificity, and accuracy values for the biceps provocation test were 95%, 97%, and 96%, respectively. For the resisted hook test, the combined values were 78%, 76%, and 77%, respectively. The combined values for the tilt sign were 58%, 55%, and 56%, respectively. When the biceps provocation test and the resisted hook test were combined in a parallel testing setup, the sensitivity increased to 98% whereas the specificity was 73%. The sensitivity and specificity of the biceps provocation test and the tilt sign in a parallel testing setup were 97% and 53%, respectively. Finally, the sensitivity and specificity of the tilt sign and the resisted hook test in a parallel testing setup were 90% and 41%, respectively.

**Conclusions:** The biceps provocation test yielded higher accuracy than the resisted hook test and the tilt sign. When the biceps provocation test and the resisted hook test were combined, the sensitivity increased to 98%. We advise integration of these tests in daily

The ethical committee of Ziekenhuis Oost-Limburg approved this study (no. Z2021007). Institutional review board approval was obtained.

\*Reprint requests: Pieter Caekebeke, MD, Department of Orthopaedics Surgery and Traumatology, Ziekenhuis Oost-Limburg, Schieps Bos 6, 3600 Genk, Belgium.

E-mail address: [caekebeke.pieter@hotmail.com](mailto:caekebeke.pieter@hotmail.com) (P. Caekebeke).

practice to minimize delays in the diagnosis of partial distal biceps tendon ruptures, distal biceps tendon bursitis, or tendinosis. MRI in the flexion-abduction-supination view is still advised to distinguish between a partial biceps tendon rupture and tendinosis or bursitis at the distal biceps tendon insertion as this may influence further treatment.

**Level of evidence:** Level IV; Case-Control Design; Diagnostic Study

© 2021 Journal of Shoulder and Elbow Surgery Board of Trustees. All rights reserved.

**Keywords:** Test; elbow; distal; biceps; tendon; partial; diagnosis

Unlike the diagnosis of complete distal biceps tendon ruptures,<sup>2,6</sup> the clinical diagnosis of partial distal biceps tendon tears, tendinosis, or bicipital bursitis remains difficult. The findings of both the clinical examination and advanced imaging are less conclusive. Patients often complain of pain in the antecubital region, exacerbated with activity. Biceps strength is usually well maintained, and the results of resistance tests may be negative. Magnetic resonance imaging (MRI) is often used.<sup>3</sup> It is recommended to use the flexion-abduction-supination (FABS) view<sup>4,8</sup> to better detect distal biceps tendon pathology. Schenkels et al<sup>8</sup> reported sensitivity values of 76% for standard MRI and 84% for the FABS view.<sup>4</sup> The absence of specific and sensitive clinical tests for the aforementioned pathologies may lead to a delay in diagnosis—or the diagnosis may be missed altogether. In recent years, 3 different clinical tests, the biceps provocation test, the tilt sign, and the resisted hook test,<sup>1,7,9</sup> have been proposed to aid in an accurate and timely diagnosis. However, not much is known about the sensitivity, specificity, and inter-rater reliability as the available evidence is based on small groups or is only case based. Furthermore, these tests have not been compared together in the same patient group.

The purpose of this study was to review the sensitivity, specificity, and accuracy of 3 clinical tests for partial distal biceps tendon ruptures, tendinosis, or bicipital bursitis.

## Material and methods

### Clinical tests

Three clinical tests were included in this study. The biceps provocation test<sup>1</sup> and the tilt sign<sup>9</sup> were published in 2021 and 2018, respectively. The resisted hook test was first published in 2019 as an aid to examine biceps tendon integrity after biceps tendon repair.<sup>7</sup> It was published in 2020 as an aid to diagnose partial biceps tendon pathology.<sup>5</sup>

The biceps provocation test (Antwerp biceps test [ABT]), published in 2021, is a 2-part test (Fig. 1). The patient is standing with the elbow supported by the examiner and flexed to 70°. The examiner's hand is placed on the patient's forearm, with the examiner's other hand supporting the elbow, and the patient is asked to flex the elbow against resistance with the forearm supinated (ABT-S). Care is taken to avoid placement of the examiner's hands on the patient's hand or wrist as resisted wrist flexion or extension will elicit pain when other elbow pathologies are present

(Fig. 1, A). The forearm is then pronated, and the test is repeated (ABT-P) (Fig. 1, B). Pain is documented for both positions (ABT-S and ABT-P) using a visual analog scale from 0 to 10. The test result is positive when the patient reports an increase in pain with the ABT-P position when compared with the ABT-S position. Patients usually also indicate a decrease in strength due to pain inhibition.<sup>1</sup>

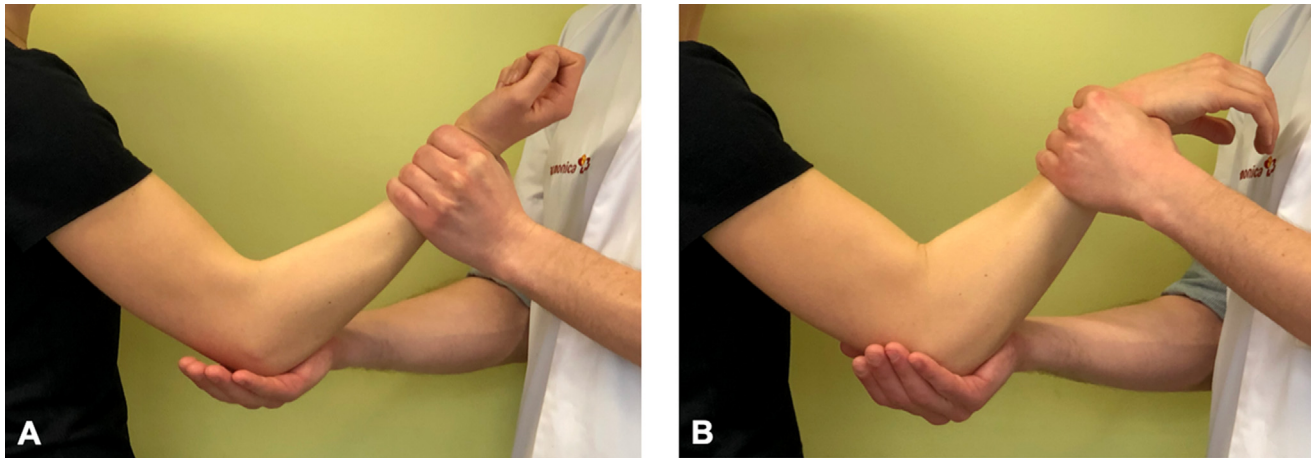
For the tilt sign, the patient's forearm is passively supinated and pronated with the elbow flexed to 90° while the examiner firmly palpates the dorsal forearm, overlying the radial tuberosity. The tuberosity presents itself beneath the examining fingers with full pronation of the forearm. A positive test result is indicated by tenderness over the radial (or lateral) aspect of the tuberosity (tilt sign) only in full forearm pronation and not in supination.<sup>9</sup>

The resisted hook test was first published in 2019 to examine biceps tendon integrity after biceps tendon repair<sup>7</sup>; in 2020, it was published as a test to diagnose partial biceps tendon ruptures.<sup>5</sup> The test is performed by positioning the shoulder in horizontal abduction with the elbow at 90° and the forearm supinated. The biceps tendon is "hooked" on the radial side of the tendon, by the examiner's index finger, and the patient is instructed to resist a pronation torque applied by the examiner. The test result is positive if this maneuver is painful.

### Evaluation of tests

All tests were performed by 2 dedicated elbow surgeons in 2 participating centers: Ziekenhuis Oost-Limburg, Genk, Belgium (center 1), and AZ Monica, Antwerp, Belgium (center 2). Each of the participating centers included all consecutive patients in whom distal biceps tendon pathology, such as a partial tear, tendinosis, or bicipital bursitis, was suspected. Patients with a complete distal biceps tendon tear were excluded. As a control, the same number of consecutive patients with various elbow pathologies other than distal biceps tendon problems was also included. All elbow pathologies were noted. All 3 tests were performed both in control patients and in patients with suspected biceps tendon pathology. FABS-view MRI and/or surgical exploration was performed in the group of patients with suspected biceps tendon pathology to confirm or rule out distal biceps tendon pathology. FABS-view MRI was performed in the control group. The findings of the clinical tests were determined before the results of MRI, surgery, or other technical investigations were analyzed.

The results were statistically analyzed using SPSS software (IBM, Armonk, NY, USA). Comparisons of the tests for each participating center were performed using the *t* test, and the significance level was set at .05. The values of sensitivity, specificity, and accuracy were calculated. In addition, sensitivity and specificity were calculated for the combination of 2 tests in a parallel testing setup.



**Figure 1** The Antwerp biceps test is a 2-part test. **(A)** The patient is standing, with the elbow supported by the examiner and flexed to 70°. The examiner's hand is placed on the patient's forearm, with the examiner's other hand supporting the elbow, and the patient is asked to flex the elbow against resistance with the forearm supinated. (© MoRe Foundation.) **(B)** The forearm is then pronated, and the test is repeated. Care is taken to avoid placement of the examiner's hands on the patient's hand or wrist as resisted wrist flexion or extension might elicit pain when other elbow pathologies are present. (© MoRe Foundation.)

## Results

Separate outcomes for each center are given in [Table I](#). All of the results presented in this section were calculated across both centers. The average age in the distal biceps tendon pathology group was 47 years (range, 35-67 years).

There were 37 male and 3 female patients. The dominant arm was involved in 19 patients. In the control group, the average age was 44 years (range, 22-72 years). There were 34 male and 6 female patients. The dominant arm was involved in 26 patients. There were no statistically significant differences between the biceps group and the

**Table I** Demographic characteristics and outcomes separated by participating center

	Center 1		Center 2	
	Biceps group (n = 20)	Control group (n = 20)	Biceps group (n = 20)	Control group (n = 20)
Mean age (range), yr	47 (35-67)	45 (22-72)	46 (35-61)	42 (22-63)
Male sex, n	17	20	20	14
MRI diagnosis, n				
Partial tear	9		5	
Tendinosis	11		15	
Lateral epicondylitis		11		12
Posterolateral instability				1
Synovitis		3		
PIN compression		1		6
Symptomatic plica		5		1
Biceps provocation test, %				
Sensitivity		100		95
Specificity		95		95
Accuracy		97.50		95
Tilt sign, %				
Sensitivity		55		35
Specificity		77		65
Accuracy		62.50		55
Resisted hook test, %				
Sensitivity		85		65
Specificity		95		65
Accuracy		90		65

MRI, magnetic resonance imaging; PIN, posterior interosseous nerve.

non-biceps group with respect to age, sex, and involvement of the dominant elbow ( $P = .7$ ,  $P = .2$ , and  $P = .1$ , respectively).

In the biceps group, 14 of 40 patients (35%) had a partial distal biceps tendon rupture that was confirmed on FABS-view MRI. In the remaining 26 patients (65%), FABS-view MRI showed tendinosis or bursitis without partial tearing.

In the control group, diagnoses were made by clinical examination and confirmed by FABS-view MRI. Specific attention was paid to rule out distal biceps tendon pathology on the images. Of 40 patients, 23 (57%) received a diagnosis of lateral epicondylitis. Posterior interosseous nerve compression was noted in 1 case (2.5%), a symptomatic radiohumeral plica was noted in 11 (28%), intra-articular elbow synovitis was diagnosed in 4 (10%), and posterolateral instability was diagnosed in 1 (2.5%).

The ABT results were positive in 39 patients with distal biceps tendon pathology and negative in 1. The results of the tilt sign were positive in 18 patients and negative in 22. The resisted hook test showed a positive result in 30 patients and a negative result in 10.

In the control group, 38 patients had negative ABT findings and 2 patients had positive ABT findings. The tilt sign showed a positive result in 13 patients and a negative result in 27. The results of the resisted hook test were negative in 32 patients and positive in 8.

The combined sensitivity, specificity, and accuracy values for the ABT were 95%, 97%, and 96%, respectively. For the resisted hook test, the combined sensitivity, specificity, and accuracy values were 78%, 76%, and 77%, respectively. The combined sensitivity, specificity, and accuracy values for the tilt sign were 58%, 55%, and 56%, respectively.

When the ABT and the resisted hook test were combined in a parallel testing setup, the sensitivity increased to 98% whereas the specificity was 73%. The sensitivity and specificity of the ABT and the tilt sign in a parallel testing setup were 97% and 53%, respectively. Finally, the sensitivity and specificity of the tilt sign and the resisted hook test in a parallel testing setup were 90% and 41%, respectively.

## Discussion

Clinical examination is usually sufficient to confidently diagnose complete distal biceps ruptures. Various clinical tests, such as the hook test, the biceps crease interval test, and the biceps squeeze test, yield very high sensitivity and specificity values (up to 100% sensitivity and specificity).<sup>1,2</sup>

Until recently, no clear clinical tests were available to diagnose partial distal biceps tendon ruptures, distal biceps

tendon bursitis, or tendinosis. As technical investigation is usually requested based on the patient's history and clinical suspicion, a significant delay in diagnosis or even a missed diagnosis of distal biceps tendon pathology regularly occurs.

Three different clinical tests have been described in the past 3 years: the biceps provocation test, the tilt sign, and the resisted hook test.<sup>1,7,9</sup> These may aid in a timely and accurate diagnosis of partial distal biceps ruptures, bicipital bursitis, or tendinosis. The sensitivity, specificity, and accuracy values for the ABT were 95%, 97%, and 96%, respectively. For the resisted hook test, these values were 78%, 76%, and 77%, respectively. For the tilt sign, these values were 58%, 55%, and 56%, respectively. In the original article, the results of the tilt sign were positive in all 3 patients included.<sup>9</sup> There was no control group, and sensitivity and specificity were not reported.

Both the biceps provocation test and the resisted hook test rely on impingement of the inflamed, thickened, or ruptured tissue between the tendon and the radius. This tissue is compressed onto the radius with pronation. Tensioning the tendon by flexion against resistance or additionally hooking the tendon will then cause pain. The tilt sign relies on the digital compression of inflamed, thickened, or ruptured tissue onto the radius in pronation. We believe that the inferior results of this test may be the result of failure to identify the correct location of the tuberosity in patients with biceps pathology. Furthermore, the overlying muscles will decrease the compressive effect onto the tuberosity, and compressing the overlying structures in patients with, for example, lateral epicondylitis or radial tunnel syndrome may result in a false-positive test result. Of note, false-positive results for the tilt sign occurred only in patients with lateral epicondylitis.

When the biceps provocation test and the resisted hook test were combined in a parallel test setup, the sensitivity increased to 98%. In a parallel test setup, if the result of either test is positive, then the patient is considered to have a positive finding. However, although this increases sensitivity, it lowers specificity, potentially leading to an increase in false-positive findings. In our case, the combined specificity value was 73%. When compared with MRI, both sensitivity and specificity are higher for the biceps provocation test and similar for the resisted hook test.<sup>8</sup> Although these tests may therefore be performed independently of MRI, we still suggest performing FABS-view MRI to improve specificity and to quantify the severity of the pathology, as well as the quality of the tendon, as this might alter further treatment.

There are some limitations to this study. First, the cohort is relatively small. Second, in the control group, the majority of patients had medial or lateral epicondylitis. A

concern might be that the examiner was biased. However, we performed the clinical examination starting with the 3 clinical tests and without taking the patients' history. Therefore, we believe such bias was minimized.

## Conclusion

The biceps provocation test yielded higher accuracy than the resisted hook test and the tilt sign. When the biceps provocation test and the resisted hook test were combined, the sensitivity increased to 98%. We advise integration of these tests in daily practice to minimize delays in the diagnosis of partial distal biceps tendon ruptures, distal biceps tendon bursitis, or tendinosis. FABS-view MRI is still advised to distinguish between a partial biceps tendon rupture and tendinosis or bursitis at the distal biceps tendon insertion as this may influence further treatment.

## Acknowledgments

We thank Raf van Riet for creating the illustrations included in this publication.

## Disclaimer

Roger van Riet is a designer with Acumed and Jake Design. All the other authors, their immediate families, and any research foundations with which they are affiliated have not received any financial payments or other

benefits from any commercial entity related to the subject of this article.

## References

1. Caekebeke P, Schenkels E, Bell SN, van Riet R. Distal biceps provocation test. *J Hand Surg Am* 2021;46:710.e1-e4. <https://doi.org/10.1016/j.jhsa.2020.12.012>
2. Devereaux MW, ElMaraghy AW. Improving the rapid and reliable diagnosis of complete distal biceps tendon rupture: a nuanced approach to the clinical examination. *Am J Sports Med* 2013;41:1998-2004. <https://doi.org/10.1177/0363546513493383>
3. Festa A, Mulieri PJ, Newman JS, Spitz DJ, Leslie BM. Effectiveness of magnetic resonance imaging in detecting partial and complete distal biceps tendon rupture. *J Hand Surg Am* 2010;35:77-83. <https://doi.org/10.1016/j.jhsa.2009.08.016>
4. Giuffre BM, Moss MJ. Optimal positioning for MRI of the distal biceps brachii tendon: flexed abducted supinated view. *AJR Am J Roentgenol* 2004;182:944-6. <https://doi.org/10.2214/ajr.182.4.1820944>
5. Harasymczuk M, Vaichinger A, Pallante GD, Fitzsimmons J, O'Driscoll SW. Algorithm for diagnosing complete and partial distal biceps tendon tears: hook test and resisted hook test. Presented at the First SECEC-ESSSE Virtual Congress. September 2020.
6. O'Driscoll SW, Goncalves LB, Dietz P. The hook test for distal biceps tendon avulsion. *Am J Sports Med* 2007;35:1865-9. <https://doi.org/10.1177/0363546507305016>
7. Pallante GD, O'Driscoll SW. Return of an intact hook test result: clinical assessment of biceps tendon integrity after surgical repair. *Orthop J Sports Med* 2019;7:2325967119827311. <https://doi.org/10.1177/2325967119827311>
8. Schenkels E, Caekebeke P, Swinnen L, Peeters J, van Riet R. Is the flexion-abduction-supination magnetic resonance imaging view more accurate than standard magnetic resonance imaging in detecting distal biceps pathology? *J Shoulder Elbow Surg* 2020;29:2654-60. <https://doi.org/10.1016/j.jse.2020.05.014>
9. Shim SS, Strauch RJ. A novel clinical test for partial tears of the distal biceps brachii tendon: the TILT sign. *Clin Anat* 2018;31:301-3. <https://doi.org/10.1002/ca.23038>