



ELSEVIER

Contents lists available at [ScienceDirect](https://www.sciencedirect.com)

Respiratory Medicine Case Reports

journal homepage: www.elsevier.com/locate/rmcr

Case Report

Pulmonary tuberculosis and COVID-19 coinfection: Hickam's Dictum revisited

Larry Ellee Nyanti^{a,b,*}, Zhun Han Wong^a, Benjamin Sachdev Manjit Singh^a, Andrew Kean Wei Chang^a, Ahmad Tirmizi Jobli^c, Hock Hin Chua^a^a Infectious Disease Unit, Medical Department, Sarawak General Hospital, Jalan Hospital, 93586, Kuching, Sarawak, Malaysia^b Faculty of Medicine and Health Sciences, Universiti Malaysia Sabah, Kota Kinabalu, Sabah, Malaysia^c Faculty of Medicine and Health Sciences, University Malaysia Sarawak, Kota Samarahan, Sarawak, Malaysia

ARTICLE INFO

Keywords:

COVID-19
Pulmonary tuberculosis
Coinfection
Endobronchial tuberculosis
Case series

ABSTRACT

COVID-19 and pulmonary tuberculosis (PTB) coinfection is associated with increased mortality and presents a unique diagnostic challenge to the clinician. We describe three cases of newly diagnosed PTB in COVID-19 patients treated at our centre and their clinical and radiological features. The challenges associated with diagnosis and management are also explored. Patient 1 was a case of smear positive, endobronchial tuberculosis incidentally diagnosed due to CT changes, and eventually made good recovery. Patient 2 was a case of COVID-19 who succumbed but was diagnosed posthumously due to a positive sputum culture for tuberculosis. Patient 3 showed radiographic features of PTB and was treated empirically for TB. In conclusion, COVID-19 and PTB coinfection should be suspected in the presence of constitutional symptoms, prior immunocompromised states, prolonged respiratory symptoms or fever, or unresolved radiological abnormalities, more so in regions where TB is endemic.

List of abbreviations

TB	tuberculosis
PTB	pulmonary tuberculosis
CT	computed tomography
WHO	World Health Organization
NPOP	nasopharyngeal and oropharyngeal
CTPA	computed tomography pulmonary angiogram
HRCT	high resolution computed tomography
GGO	ground glass opacities
ATT	anti-tuberculous therapy
IGRA	interferon-gamma release assay

* Corresponding author. Faculty of Medicine and Health Sciences, Universiti Malaysia Sabah, Kota Kinabalu, Sabah, Malaysia.

E-mail addresses: larrynyanti@ums.edu.my (L.E. Nyanti), zhunhan@hotmail.com (Z.H. Wong), benjaminsachdev@gmail.com (B. Sachdev Manjit Singh), andrchang@gmail.com (A.K.W. Chang), jatirmizi@unimas.my (A.T. Jobli), hchua2009@gmail.com (H.H. Chua).<https://doi.org/10.1016/j.rmcr.2022.101653>

Received 5 February 2022; Received in revised form 12 March 2022; Accepted 13 April 2022

Available online 21 April 2022

2213-0071/© 2022 The Authors. Published by Elsevier Ltd. This is an open access article under the CC BY-NC-ND license (<http://creativecommons.org/licenses/by-nc-nd/4.0/>).

1. Introduction

COVID-19 was declared a pandemic in 2020, whereas tuberculosis (TB) was declared a global health emergency by the World Health Organization (WHO) in 1993 [1]. Both diseases manifest as respiratory illnesses with varying severities and display similar symptoms [2], reflecting Hickam's dictum which states that multiple symptoms and signs may be due to more than one disease [3]. TB is endemic in the state of Sarawak, Malaysia, with a 2016 incidence of 104.23 per 100,000 population, far above the national average of 81.3 per 100,000 population [4]. Pulmonary TB (PTB) and COVID-19 coinfection has been well-reported [2,5–9] with meta-analysis showing increased risk of mortality [10]. We describe three cases of newly diagnosed PTB in COVID-19 patients treated at our tertiary centre, discuss their varied clinical and radiological presentations, and elucidate the challenges associated with diagnosis and management of PTB and COVID-19 coinfection. All three patients were infected with COVID-19 before the introduction of COVID vaccines.

1.1. Case presentation

1.1.1. Patient 1

A 61-year-old woman with a history of total abdominal hysterectomy and salpingectomy for cervical carcinoma initially visited the surgical clinic with complaints of abdominal bloating and loss of weight for a month, associated with a recent dry cough for one week. She denied shortness of breath, fever, haemoptysis, sore throat, anosmia or dysgeusia. Computed tomography (CT) of the abdomen and pelvis showed no intrabdominal abnormalities, however, ground glass opacities were observed at bilateral lower zones of the lung. Rapid nasopharyngeal and oropharyngeal (NPOP) antigen assay for COVID-19 was positive, and she was admitted to the isolation ward.

On admission, she was afebrile and normotensive, but was noted to be tachycardic (heart rate of 128 beats per minute), tachypnoeic (respiratory rate of 22 breaths per minute) and had an oxygen saturation of 89% under room air. Arterial blood gas taken under room air revealed type 1 respiratory failure (pH 7.46, PO₂ 67 mmHg, PCO₂ 30 mmHg, HCO₃ 28 mmol/L). Electrocardiogram showed atrial fibrillation with fast ventricular response, but no ischemic or myocarditis changes. Chest radiograph revealed bilateral nodular and airspace opacities (Fig. 1A).

Dexamethasone and lopinavir/ritonavir were administered as per local COVID-19 treatment guidelines at the time. She required invasive mechanical ventilation for three days. Endotracheal aspirates sampled for bacterial culture and respiratory virus PCR panel (QIAstat-Dx, QIAGEN, Maryland, United States) were negative. Post-extubation, she remained oxygen dependent and computed tomography pulmonary angiogram (CTPA) was performed on day 7 of admission. CTPA showed pulmonary embolism in the segmental branch of right descending pulmonary artery, generalized, diffuse peri-bronchovascular ground glass changes bilaterally, interlobular and intralobular septal thickening at bilateral upper lobes, focal consolidation at the lateral basal segment of the left lower lobe, and tree-in-bud nodules bilaterally (Fig. 2A). Sputum smear examination was positive for acid fast bacilli. Molecular testing for *M. TB* nucleic acids (Cepheid Xpert MTB/RIF, <https://www.cepheid.com>) revealed no rifampicin resistance. She was commenced on anti-coagulant and anti-tuberculous therapy (ATT) consisting of rifampicin, isoniazid, pyrazinamide, and ethambutol, and finally weaned off to room air on day 32 of admission. Follow-on high resolution computed tomography (HRCT) of the thorax at day 40 of admission showed resolution of ground glass changes and absence of septal thickening. However, there were increased diffuse centrilobular lung nodules with traction bronchiectasis at bilateral lower lobes, consistent with endobronchial TB (Fig. 2B). She was discharged well and completed a six-month course of ATT. Chest radiograph taken 3 months post-discharge showed resolving opacities (Fig. 1B).

1.1.2. Patient 2

A 63-year-old woman with underlying type 2 diabetes mellitus presented to a district clinic with loss of weight and loss of appetite for the last two months, two weeks of lethargy and poor oral intake, one week of fever and productive cough with whitish sputum, and rapidly worsening shortness of breath for the past two days. She was normotensive but tachycardic (pulse rate 115 beats per minute) and tachypnoeic (respiratory rate 28 breaths per minute) and had an oxygen saturation of 96% under room air. She was

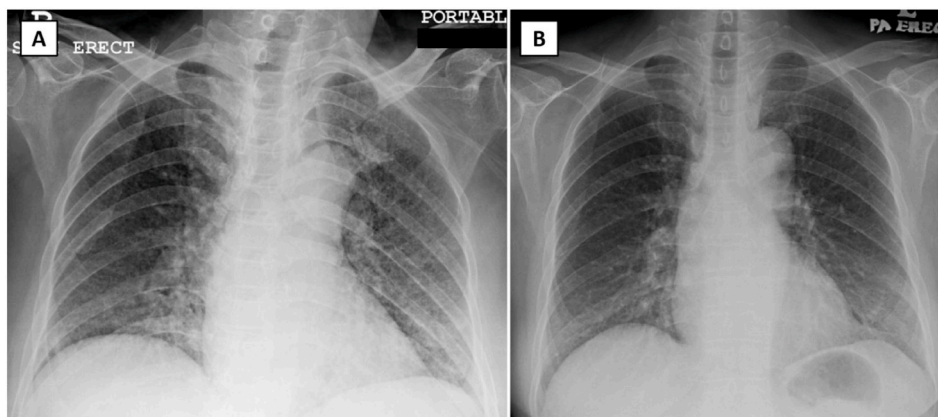


Fig. 1. Chest radiograph of patient 1 on admission demonstrates nodular and air space opacities bilaterally (Panel A). These opacities significantly resolve on day 12 of admission (Panel B). No cavity, enlarged hilar node, or pleural effusion is seen in both chest radiographs.