



# Normothermic frozen elephant trunk: our experience and literature review

Pietro Giorgio Malvindi<sup>1</sup>, Jacopo Alfonsi<sup>1</sup>, Paolo Berretta<sup>1</sup>, Mariano Cefarelli<sup>1</sup>, Emanuele Gatta<sup>2</sup>, Marco Di Eusanio<sup>1</sup>

<sup>1</sup>Cardiac Surgery Unit, Lancisi Cardiovascular Center, Polytechnic University of Marche, Ancona, Italy; <sup>2</sup>Vascular Surgery Department, Lancisi Cardiovascular Center, Ancona, Italy

**Contributions:** (I) Conception and design: All authors; (II) Administrative support: All authors; (III) Provision of study materials or patients: All authors; (IV) Collection and assembly of data: All authors; (V) Data analysis and interpretation: All authors; (VI) Manuscript writing: All authors; (VII) Final approval of manuscript: All authors.

**Correspondence to:** Pietro Giorgio Malvindi, Cardiac Surgery Department, Lancisi Cardiovascular Center, Ospedali Riuniti, Polytechnic University of Marche, Via Conca 71, Ancona 60129, Italy. Email: p.g.malvindi@univpm.it.

**Background and Objective:** The frozen elephant trunk (FET) technique has undoubtable advantages in treating complex and extensive disease of the aortic arch and the thoracic descending aorta. Despite several improvements in cardiopulmonary bypass conduction and surgical strategy, operative times and the institution of systemic circulatory arrest remain the main determinants of early mortality, cerebral/spinal cord injury and visceral organs dysfunction. We have conducted this review to highlight the recent technical advances in arch and FET surgery aiming at the reduction/avoidance of systemic circulatory arrest, and their impact on early outcomes.

**Methods:** A literature search (from origin to January 2022), limited to publications in English, was performed on online platforms and database (PubMed, Google, ResearchGate). After a further review of associated or similar papers, we found 4 experiences, described by 11 peer-reviewed published papers, which focused on minimising or avoiding systemic circulatory arrest during total arch replacement plus stenting of the descending thoracic aorta.

**Key Content and Findings:** Recent experiences reported the use of an antegrade endoaortic balloon, advanced and inflated into the stent graft, to provide an early systemic reperfusion soon after the deployment of the stented portion of the FET prosthesis and minimize the circulatory arrest time (down to a mean of 5 minutes), thus avoiding the need of moderate or deep hypothermia (mean systemic temperature 28–30 °C) while allowing a complete arch and FET repair. Our approach, based on off-pump retrograde vascular stent graft deployment in distal arch/descending thoracic aorta, and the use of a retrograde endoballoon, allows the repair of extensive aortic pathologies during uninterrupted normothermic cerebral and lower body perfusion.

**Conclusions:** The use of endoballoon occlusion has emerged in recent years as a safe and effective strategy to allow distal perfusion during FET repair. This technique minimizes or avoids the detrimental effects of hypothermia and systemic circulatory arrest and significantly reduces the operative times.

**Keywords:** Aorta; aortic arch; frozen elephant trunk (FET); circulatory arrest; hypothermia; cerebral perfusion

Submitted Feb 11, 2022. Accepted for publication May 17, 2022.

doi: 10.21037/cdt-22-73

View this article at: <https://dx.doi.org/10.21037/cdt-22-73>

## Introduction

The Elephant Trunk technique was introduced in 1983 by Borst *et al.* (1) to facilitate the repair of extensive pathology of the thoracic aorta. During the first surgical step via

median sternotomy the ascending aorta and the aortic arch are repaired and a free-floating extension of the arch vascular prosthesis, the “elephant trunk”, is left beyond the proximal descending aorta. This technique aims to

prevent difficult tissue dissection in the distal arch/proximal descending aorta area during the second surgical step and can provide a safe landing zone in case of endovascular completion. This approach has been shown to be safe but is burdened by the cumulative risk of two major surgical procedures and poses the hazard of potentially fatal aortic events during the interval time between the first and the second step (2).

The technological and technical evolution has allowed the possibility of a simultaneous treatment of the aortic arch and the descending aorta with the intraoperative implantation of a stent graft. Kato *et al.* presented in 1996 a series of 10 patients who received a custom-made stented prosthesis implanted at the distal arch anastomotic site for the treatment of descending thoracic aorta aneurysm and dissection (3). Karck *et al.* in 2003 described the frozen elephant trunk (FET) technique with the implantation of a purposely designed surgical stent graft (4).

Alongside the possibility of treating in a single step extensive aortic pathologies and lesions of the distal aortic arch and proximal descending aorta, FET repair is a valuable strategy in patients with acute aortic dissection especially in presence of complex primary tears, re-entry and aortic rupture at the distal arch or proximal descending (5) or in case of visceral malperfusion sustained by compression of the true lumen (6,7). At mid-term, this approach can also sustain a positive distal aortic remodelling (8) characterised by a higher rate of false lumen thrombosis (8,9) and a reduction in descending thoracic aorta dilatation (5,8,9).

Despite the growing experience at specialised centres with broader practice in aortic arch surgery, in-hospital mortality after FET is still non negligible (up to 17%) and postoperative course is often complicated by the occurrence of cerebral stroke (2.5–20%), spinal cord injury (2–21%) and renal dysfunction (up to 35%) (5,10–14). Operative times and institution of circulatory arrest remain the two main intraoperative negative determinants of early survival and are associated with postoperative brain/spinal cord injury and visceral organs complications (15–22).

Several adjustments in surgical techniques and cardiopulmonary bypass conduction have addressed these issues by reducing cardiopulmonary, cross-clamp and circulatory arrest times. Nevertheless, new approaches have been developed allowing arch surgery and FET repair minimising or completely avoiding systemic circulatory arrest. We present the following article in accordance with the Narrative Review reporting checklist (available at

<https://cdt.amegroups.com/article/view/10.21037/cdt-22-73/rc>).

## Methods

A literature search using online platform and database (PubMed, Google, ResearchGate) was performed for FET repair in mild hypothermia or normothermia and avoiding or minimising systemic circulatory arrest. We applied no data restrictions (from origin to January 2022) and we considered only English language publications. Due to the high heterogeneity of definition of these techniques, several searches were conducted using various combinations of the following terms: “frozen elephant trunk”, “elephant trunk”, “aortic arch”, “normothermia”, “hypothermia”, “endoballoon” (Table 1). Associated and similar papers were extensively reviewed. Ultimately, we were able to find four institutional experiences, described in 11 papers, which focused on minimising or avoiding systemic circulatory arrest during total arch replacement plus stenting of the descending thoracic aorta.

We discuss further experiences describing the progressive improvement in management of hypothermia and circulatory arrest and the transition towards the avoidance of systemic circulatory arrest.

## Key contents and findings

Reduction of cardiopulmonary bypass time can be achieved avoiding deep hypothermia and shortening cooling and rewarming phases. Different definitions of deep, moderate and mild hypothermia have been used according to cerebral physiology findings (23,24) (Tables 2,3). A systemic cooling at 14–20 °C allows 20–30 minutes of safe hypothermic circulatory arrest (HCA) duration. A longer safe period of circulatory arrest with lower neurological complications can be obtained at higher temperatures 22–26 °C with the adjunct of antegrade selective cerebral perfusion (27–31). Antegrade arterial return flow from right axillary/innominate artery, selective antegrade selective cerebral perfusion through innominate, left carotid and left subclavian arteries, and moderate HCA, provide satisfactory cerebral protection and spinal cord supply (23,27,32). Satisfactory results in terms of early survival, postoperative neurologic complications and organ function preservation, have been reported using antegrade cerebral perfusion and HCA at 30–31 °C (33,34). However, in these series most of the operations were hemiarch repairs with an average

**Table 1** The search strategy summary

Items	Specification
Date of search	18/01/2022
Databases and other sources of search	PubMed, Google, ResearchGate
Search terms used (alone or in various combinations)	“frozen elephant trunk”, “elephant trunk”, “aortic arch”, “normothermia”, “hypothermia”, “endoballoon”
Timeframe	Up to January 2022
Inclusion and exclusion criteria	Publications in English; due to the high heterogeneity of classification of “hypothermia” and definition of aortic surgery associated with stenting of the descending thoracic aorta, an extensive review of papers focusing on aortic surgery was carried out; no a priori exclusion criteria but the language was applied
Selection process	It was conducted independently by PGM, JA and MC. The final selection is the intersection and the implementation of the three searches

**Table 2** Classification of Hypothermia and calculated safe durations of hypothermic circulatory arrest (HCA) according to suppression of cerebral metabolism from McCullough *et al.* (25) and Luehr *et al.* (23)

Level of hypothermia	Temperature range, °C	Temperature, °C	Cerebral metabolic rate (% of baseline)	HCA safe duration (minutes)
Normothermia	36.0–37.0	37	100	5
Mild	33.0–35.9			
Moderate	28.0–32.9	30	56 [52–60]	9 [8–10]
Deep	21.0–27.9	25	37 [33–42]	14 [12–15]
Profound	<20.9	20	24 [21–29]	21 [17–24]
		15	16 [13–20]	31 [25–38]
		10	11 [8–14]	45 [36–62]

**Table 3** Classification of hypothermia according to neurophysiologic changes from Stecker *et al.* (26) and Yan *et al.* (24)

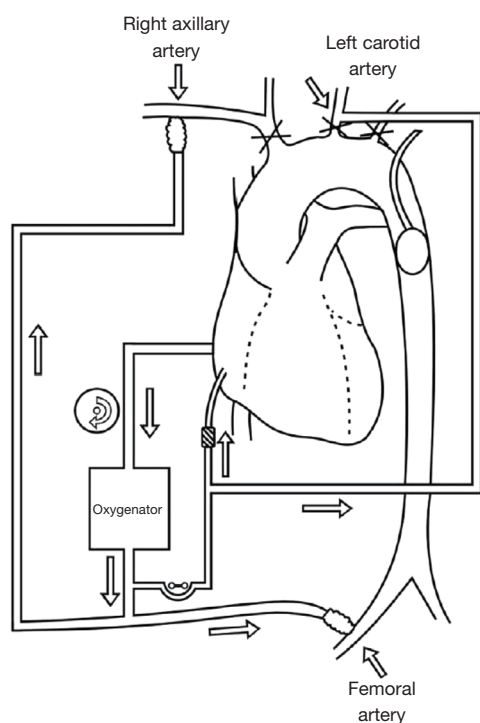
Level of hypothermia	Temperature range, °C
Mild	28.1–34.0
Moderate	20.1–28.0
Deep	14.1–20.0
Profound	<14

duration of isolated cerebral perfusion between 18 and 38 minutes. More complex procedures or redo operations with extensive treatment of the aortic arch and the descending thoracic aorta require longer systemic circulatory arrest periods thus increasing the risk of severe spinal cord injury and paraplegia if the time of arrest exceeds 50 minutes at mild hypothermia (35–37). Similarly,

visceral organs can suffer from prolonged arrest time at 28–30 °C, with kidneys tolerating up to 60 minutes of ischaemic time and liver up to 90 minutes before developing organ dysfunction and damage (37).

Proximalization of the distal aortic anastomosis in arch zone  $\leq 2$  is a valuable technical advantage of FET repair. It allows the construction of an easier and faster distal anastomosis in a more accessible area avoiding the handling of frail tissue at the distal arch and significantly shortening the circulatory arrest and cardiopulmonary bypass times (38).

The use of a 4-branched arch prosthesis can further reduce the circulatory arrest time. Once the distal side of the arch repair is accomplished, the vascular graft is clamped, and the systemic perfusion resumed from the fourth branch of the graft (39). The proximal aortic repair can be performed thereafter, and heart reperfusion regained before the anastomosis of the epi-aortic vessels.



**Figure 1** Right axillary and femoral artery perfusion with mild hypothermia for aortic arch replacement from Guo *et al.* (44).

### ***How to minimise circulatory arrest time: the antegrade balloon occlusion technique***

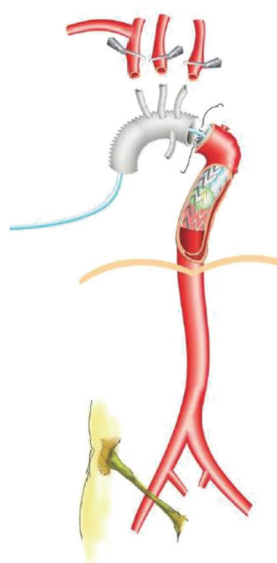
Despite these refinements, institution of HCA remains detrimental. Several experiences have tried to overcome the limitations and morbidities associated with conventional arch surgery introducing new approaches and techniques aiming the reduction or the avoidance of systemic circulatory arrest.

Matalanis *et al.* developed from 2005 the “branch-first” technique (40). The main aim of this approach is to avoid the circulatory arrest and maintain cerebral and systemic perfusion at an average temperature of 27 °C, range 22–28 °C. The first step of this method is the debranching and perfusion of the neck vessels, with intermittent interruption of the flow in each artery—in their experience, 14 (range, 10–18) minutes for innominate artery, 11 (range, 9–14) minutes for the left carotid artery, 18 (range, 13–23) minutes for the left subclavian artery—while avoiding any period of global cerebral circulatory arrest relying on intracranial and extracranial collaterals blood supply (41). The distal organ perfusion is maintained during the arch reconstruction through retrograde femoral artery perfusion

with cross-clamp of the proximal descending thoracic aorta or the use of an endo balloon after the deployment of the FET stent graft. With this technique they reported in 64 patients—mean age 65 years old, 49% acute aortic dissection, 11 cases of FET—satisfactory early outcomes: in-hospital mortality 3.1%, cerebral stroke 1.6% and a low occurrence of renal (6.2%) and respiratory (tracheostomy 4.7%) complications. Despite these outstanding results, in a recent paper focusing on their experience with the “branch-first” technique in patients undergoing arch repair and FET procedure from 2008 to 2019, the same group from Melbourne reported the systematic use of circulatory arrest at 25 °C (mean time: 44 minutes) during the deployment of the stent graft and the construction of the distal anastomosis (42).

Touati *et al.* described in 2007 their experience of normothermic arch replacement with the use of endoballoon occlusion of the descending thoracic aorta to allow distal organ perfusion (43). The perfusion set up provided: normothermic perfusion (between 36 and 37 °C) of the lower half of the body to obtain a femoral artery pressure  $\geq 55$  mmHg; normothermic cerebral perfusion through the cannulation of the innominate and left carotid arteries to obtain a right radial pressure of 70 mmHg; intermittent retrograde coronary sinus perfusion. The descending thoracic aorta was usually occluded with a Robicsek Pruitt aortic occlusion catheter after the opening of the aorta or with an inflated balloon of the Djumbodis system in case of stenting of the descending aorta. They reported no distal perfusion interruption during the transverse resection of the aorta and the placement of the endoballoon, manoeuvres that usually required about 5 minutes while maintaining a reduced retrograde flow at 1–1.5 L/min. Twenty-nine patients were treated with this method, 19 chronic aneurysms, 8 acute dissections and 3 chronic dissections. Extension of stenting with the Djumbodis system was performed in fifteen patients. In-hospital mortality was 6.8%, there was no perioperative neurological deficit, no renal and hepatic impairment was observed.

A similar technique (*Figure 1*) was used by Guo *et al.* (44) in 16 patients with acute type A aortic dissection who underwent aortic arch replacement between 2010 and 2012. At an average systemic temperature of 31 °C, after exploration of the aortic arch and preparation of the distal aortic stump, a membranous stent graft (MicroPort, Shanghai, China) was anchored to the inner wall of the descending thoracic aorta and occluded with a 16 French urethral catheter. Systemic perfusion through the femoral artery was resumed thereafter for a mean lower body



**Figure 2** Endo aortic balloon occlusion for total arch replacement and FET repair from Sun *et al.* (46). FET, frozen elephant trunk.

circulatory arrest time of  $20 \pm 13$  minutes. Early results were satisfactory with no 30-day mortality, there was one case of postoperative cerebral stroke and 2 patients required postoperative haemodialysis because of acute renal failure—one of these patients presented already with renal hypoperfusion because of renal artery dissection.

Mild systemic circulatory arrest for arch and FET repair using and endoballoon occlusion was described by Goto *et al.* (45) in 8 patients. Their method provided femoral and left subclavian artery cannulation for arterial return, selective antegrade cerebral perfusion and systemic cooling at  $30^\circ\text{C}$  of bladder temperature. After the transection of the aorta, the FET stent graft was deployed during a period of circulatory arrest of  $17 \pm 4$  minutes and was occluded thereafter with a Foley catheter balloon with an immediate resumption of the lower body perfusion from the femoral artery. Total operation time, cardiopulmonary bypass time and cardiac arrest time were significantly lower when compared with patients previously operated on moderate HCA. Mechanical ventilation time and postoperative hospital stay were significantly shorter in patients who had endoballoon FET occlusion. There was no hospital death in both groups, no complications were registered in the group who had reduced circulatory arrest time and FET repair in mild hypothermia. Despite the limited populations size, the authors suggested that endo-clamp with FET graft can safely shorten the circulatory arrest time, enhance the

neural protection and avoid coagulopathy and other adverse effects of deep HCA.

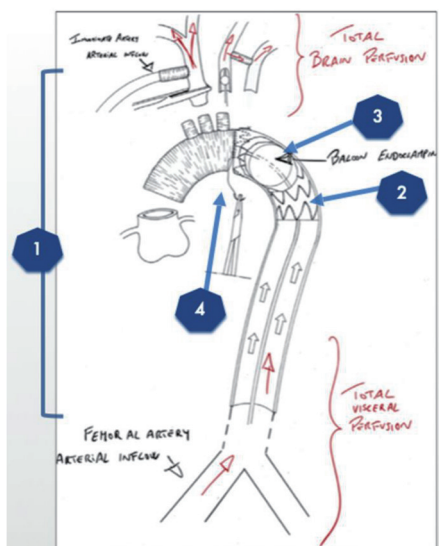
In 2019, Sun *et al.* (46) from Fuwai Hospital in Beijing described their surgical technique with an aortic balloon occlusion for total arch replacement with FET repair (Figure 2). The right axillary artery and the femoral artery are cannulated for cardiopulmonary bypass, and the right axillary artery is used for antegrade selective cerebral perfusion. Circulatory arrest is instituted at the nasopharyngeal temperature of  $28^\circ\text{C}$  and antegrade cerebral perfusion started and maintained at  $5\text{--}8\text{ mL/kg/min}$ . The aortic arch is transected between the left common carotid and left subclavian arteries. The stented graft is inserted into the descending aorta and an aortic balloon is deployed in the metal part of the FET prosthesis; reperfusion of the lower body starts again thereafter. In their initial experience the average HCA time was  $5.36 \pm 2.78$  min. The results of this technique have been widely reported with separate analyses (up to 134 patients treated with endo aortic balloon) for aortic dissection patients (47-49) and comparison with FET under moderate HCA and arch replacement + endovascular aortic repair (50,51).

The antegrade balloon occlusion technique seems a feasible way to shorten the circulatory arrest time and avoid deep cooling while providing neurological and visceral protection and reducing postoperative mechanical ventilation time (47,50). This data comes from single institutional practices and, apart from the experience of Fuwai Hospital (46-51), includes small populations of patients, therefore, no robust conclusions about the reproducibility of these techniques can be driven. Furthermore, due to the observational nature of these studies and the heterogeneity of the treated aortic pathologies, it is not possible to strongly and significantly objectify the expected advantages associated with the reduction of the operative times and the shortening of systemic circulatory arrest.

#### ***Normothermic FET with NO circulatory arrest. How we do it***

To improve surgical outcomes and extend open arch replacement with FET to elderly, comorbid and frail patients, we have proposed a new FET construction based on normothermia and completely avoiding systemic circulatory arrest (Figure 3). This approach involves:

- (I) Off-pump retrograde trans-femoral stent graft deployment;



**Figure 3** Our approach for normothermic arch + FET repair without circulatory arrest. 1: innominate and femoral artery cannulation; 2: trans-femoral off-pump stent graft deployment and subsequent cardiopulmonary bypass institution; 3: stent graft balloon endoclamp; 4: graft to stent graft anastomosis with cerebral, upper and lower body continuous perfusion. FET, frozen elephant trunk.

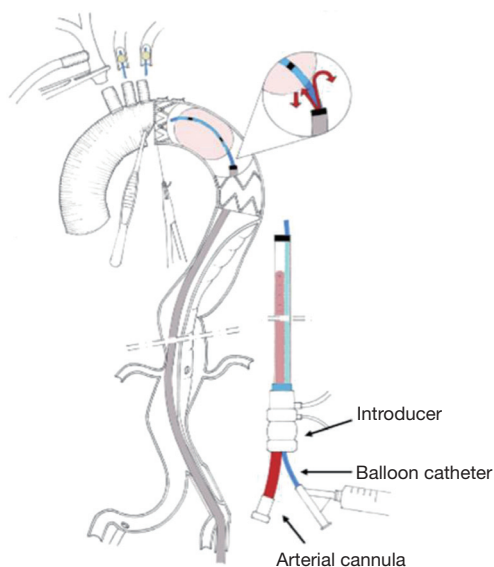
- (II) A combined femoral and innominate artery cannulation for cardiopulmonary bypass arterial return that allows continuous upper and lower body perfusion at 34–35 °C;
- (III) Antegrade selective cerebral perfusion with total brain and subclavian arteries perfusion; either with selective perfusion of innominate, left carotid and left subclavian arteries either with perfusion of innominate artery and left carotid artery after a left carotid to left subclavian bypass;
- (IV) Occlusion of the stent graft with a retrogradely inserted balloon;
- (V) Direct suture between the stent graft and the vascular graft.

Primarily this technique was employed in case of type Ia endoleak after TEVAR; afterwards the use of FET without HCA was extended to patients with chronic arch aneurysm (especially involving proximal descending thoracic aorta), with acute or chronic dissection, especially in high-risk and older patients (52–54).

### *Surgical procedure*

The operations were performed through a median sternotomy access. The arch vessels were extensively isolated and the proximal landing zone at the level of the origin of the subclavian artery was marked with multiple large clips. Following systemic heparinization, the innominate artery and the right femoral artery were cannulated for cardiopulmonary bypass arterial return. A vascular aortic stent graft without any free-flow area and supported by an extra-stiff guidewire, was deployed through the left femoral artery and advanced to the proximal landing zone. The stent graft size was chosen considering a 10–20% of oversizing of the distal landing zone in chronic aneurysm and a 0–10% of oversizing of the distal landing zone in acute dissection. Using a 11 French sheath, an endoballoon was then retrogradely advanced into the stent graft and was inflated under fluoroscopy to simulate and evaluated the aortic occlusion. The right atrium was cannulated with a two-stage cannula, a vent line was placed into the left ventricle through the right upper pulmonary vein and finally normothermic cardiopulmonary bypass was instituted. The left subclavian artery was ligated at its origin, anastomosed distally to an 8 mm graft and selectively perfused. The ascending aorta was clamped and cardioplegic arrest obtained with cardioplegia. The left carotid artery was ligated at the origin and distally cannulated and perfused for antegrade selective cerebral perfusion. The innominate artery was then clamped, and the aortic balloon inflated keeping the lower body perfused from the femoral artery. The crossclamp was then removed from the ascending aorta and the proximal aorta was resected from the sinotubular junction to the endoprosthesis. A 4-branched vascular graft was anastomosed to the distal aorta with bites internally taking the endograft and externally reinforced by a Teflon felt. Once the distal anastomosis was completed, the vascular Dacron graft was clamped, and the aortic balloon deflated. The proximal repair was then accomplished and the heart reperfused thereafter. With the heart beating, the three neck vessels were ultimately anastomosed to the three branches of the graft to complete the aortic reconstruction.

In patients with aortic dissection, an endo aortic balloon (Reliant balloon, Medtronic) and a 19 French arterial cannula were introduced in the same sheath and advanced retrogradely from the femoral artery. Once the balloon was



**Figure 4** In case of acute aortic dissection, after transfemoral graft deployment, the sheath is advanced into the stent graft and used to introduce the endoballoon and a cannula for arterial return. This configuration allows a continuous antegrade flow into the dissected thoraco-abdominal aorta. A disadvantage of this technique is the temporary occlusion of the internal iliac artery, which could impair the spinal cord blood supply. For this reason, the sheath is always removed soon after the distal arch anastomosis is complete and the antegrade systemic flow can be re-established through the 4th branch of the vascular prosthesis.

inflated, the arterial femoral line was opened and allowed uninterrupted antegrade perfusion of the distal dissected aorta from the descending thoracic aorta (52) (*Figure 4*).

Compared to the techniques reported and discussed in the previous paragraph using an antegradely delivered endoballoon (43-46), our approach:

- (I) Avoids completely circulatory arrest while providing a perfectly bloodless and manoeuvrable operative field as the balloon is retrogradely advanced into the stent graft for aortic clamping;
- (II) Enhances the safety of the procedure with the possibility of testing the endoballoon occlusion before opening the aortic arch;
- (III) Allows a normothermic cardiopulmonary bypass with continuous brain, spinal cord and visceral perfusion.

One of the major concerns in performing open arch surgery in mild hypothermia or normothermia, is the

dreadful event of an ineffective endoballoon occlusion causing a difficult exposure and inadequate distal perfusion. However, with our approach, the balloon occlusion is tested under fluoroscopy before the institution of cardiopulmonary bypass, and this is of utmost importance especially in case of important back bleeding from a pressurised false lumen during acute aortic dissection repair.

The retrograde insertion of the stent graft and the endoballoon can be prevented by the presence of significant disease of the iliac and femoral vessels. A severe atherosclerotic disease of the iliac and femoral axes could represent a limitation of our technique compared to the antegrade stent graft delivery.

Until today, at our Institution, 13 patients underwent aortic arch replacement using this technique: 7 patients for chronic arch aneurysm, 4 patients for type Ia endoleak and 2 patients for aortic dissection. We registered no cerebral stroke nor spinal cord injury. Two patients suffered postoperative acute renal injury. There was 1 in-hospital death for late pulmonary complications in a patient with history of severe COPD for whom an endovascular approach was deemed not feasible.

## Conclusions

Despite numerous refinements in cardiopulmonary bypass conduction and improvement in surgical techniques, HCA is strongly associated with early mortality and postoperative morbidity and remains the most important limitation of conventional arch surgery and FET repair. Minimising or avoiding circulatory arrest can shorten operative times and avoid the systemic effects associated with organ ischaemia and hypothermia. The use of endoballoon occlusion has emerged in recent years as a safe and effective strategy to allow distal perfusion during FET repair. In our experience, the multidisciplinary approach combining surgical and transcatheter techniques provides in selected patients a feasible and safe method for normothermic open arch and descending thoracic aorta surgery completely avoiding systemic circulatory arrest with uninterrupted systemic organ perfusion. Skills and proficiency in catheter-based techniques enhance the interventional armamentarium of the cardiovascular surgeon promoting the progress of the specialty and increasing patients' safety.

## Acknowledgments

*Funding:* None.

## Footnote

*Provenance and Peer Review:* This article was commissioned by the Guest Editors (Mohamad Bashir, Mohammed Idhrees and Edward P. Chen) for the series “Frozen Elephant Trunk” published in *Cardiovascular Diagnosis and Therapy*. The article has undergone external peer review.

*Reporting Checklist:* The authors have completed the Narrative Review reporting checklist. Available at <https://cdt.amegroups.com/article/view/10.21037/cdt-22-73/rc>

*Conflicts of Interest:* All authors have completed the ICMJE uniform disclosure form (available at <https://cdt.amegroups.com/article/view/10.21037/cdt-22-73/coif>). The series “Frozen Elephant Trunk” was commissioned by the editorial office without any funding or sponsorship. The authors have no other conflicts of interest to declare.

*Ethical Statement:* The authors are accountable for all aspects of the work in ensuring that questions related to the accuracy or integrity of any part of the work are appropriately investigated and resolved.

*Open Access Statement:* This is an Open Access article distributed in accordance with the Creative Commons Attribution-NonCommercial-NoDerivs 4.0 International License (CC BY-NC-ND 4.0), which permits the non-commercial replication and distribution of the article with the strict proviso that no changes or edits are made and the original work is properly cited (including links to both the formal publication through the relevant DOI and the license). See: <https://creativecommons.org/licenses/by-nc-nd/4.0/>.

## References

1. Borst HG, Walterbusch G, Schaps D. Extensive aortic replacement using ‘elephant trunk’ prosthesis. *Thorac Cardiovasc Surg* 1983;31:37-40.
2. Safi HJ, Miller CC 3rd, Estrera AL, et al. Staged repair of extensive aortic aneurysms: long-term experience with the elephant trunk technique. *Ann Surg* 2004;240:677-84; discussion 684-5.
3. Kato M, Ohnishi K, Kaneko M, et al. New graft-implanting method for thoracic aortic aneurysm or dissection with a stented graft. *Circulation* 1996;94:III188-93.
4. Karck M, Chavan A, Hagl C, et al. The frozen elephant trunk technique: a new treatment for thoracic aortic aneurysms. *J Thorac Cardiovasc Surg* 2003;125:1550-3.
5. Weiss G, Santer D, Dumfarth J, et al. Evaluation of the downstream aorta after frozen elephant trunk repair for aortic dissections in terms of diameter and false lumen status. *Eur J Cardiothorac Surg* 2016;49:118-24.
6. Shrestha M, Bachet J, Bavaria J, et al. Current status and recommendations for use of the frozen elephant trunk technique: a position paper by the Vascular Domain of EACTS. *Eur J Cardiothorac Surg* 2015;47:759-69.
7. Berretta P, Di Eusanio M. Descending endograft for DeBakey type 1 aortic dissection: pro. *Ann Cardiothorac Surg* 2016;5:222-6.
8. Dohle DS, Tsagakis K, Janosi RA, et al. Aortic remodelling in aortic dissection after frozen elephant trunk. *Eur J Cardiothorac Surg* 2016;49:111-7.
9. Di Bartolomeo R, Pantaleo A, Berretta P, et al. Frozen elephant trunk surgery in acute aortic dissection. *J Thorac Cardiovasc Surg* 2015;149:S105-9.
10. Katayama A, Uchida N, Katayama K, et al. The frozen elephant trunk technique for acute type A aortic dissection: results from 15 years of experience. *Eur J Cardiothorac Surg* 2015;47:355-60.
11. Shrestha M, Kaufeld T, Beckmann E, et al. Total aortic arch replacement with a novel 4-branched frozen elephant trunk prosthesis: Single-center results of the first 100 patients. *J Thorac Cardiovasc Surg* 2016;152:148-159.e1.
12. Preventza O, Liao JL, Olive JK, et al. Neurologic complications after the frozen elephant trunk procedure: A meta-analysis of more than 3000 patients. *J Thorac Cardiovasc Surg* 2020;160:20-33.e4.
13. Di Eusanio M, Castrovinci S, Tian DH, et al. Antegrade stenting of the descending thoracic aorta during DeBakey type 1 acute aortic dissection repair. *Eur J Cardiothorac Surg* 2014;45:967-75.
14. Leone A, Beckmann E, Martens A, et al. Total aortic arch replacement with frozen elephant trunk technique: Results from two European institutes [published correction appears in *J Thorac Cardiovasc Surg*. 2020 Jun;159(6):2571]. *J Thorac Cardiovasc Surg* 2020;159:1201-11.
15. Nakamura K, Onitsuka T, Yano M, et al. Risk factor analysis for ascending aorta and aortic arch repair using selective cerebral perfusion with open technique: role of open-stent graft placement. *J Cardiovasc Surg (Torino)* 2006;47:659-65.
16. Khaladj N, Shrestha M, Meck S, et al. Hypothermic circulatory arrest with selective antegrade cerebral perfusion in ascending aortic and aortic arch surgery: a risk factor analysis for adverse outcome in 501 patients. *J*



- Thorac Cardiovasc Surg 2008;135:908-14.
17. Di Eusanio M, Berretta P, Cefarelli M, et al. Total Arch Replacement Versus More Conservative Management in Type A Acute Aortic Dissection. *Ann Thorac Surg* 2015;100:88-94.
  18. Mousavizadeh M, Daliri M, Aljadayel HA, et al. Hypothermic circulatory arrest time affects neurological outcomes of frozen elephant trunk for acute type A aortic dissection: A systematic review and meta-analysis. *J Card Surg* 2021;36:3337-51.
  19. Czerny M, Krähenbühl E, Reineke D, et al. Mortality and neurologic injury after surgical repair with hypothermic circulatory arrest in acute and chronic proximal thoracic aortic pathology: effect of age on outcome [published correction appears in *Circulation*. 2014 Feb 25;129(8):e357]. *Circulation* 2011;124:1407-13.
  20. Svensson LG, Crawford ES, Hess KR, et al. Deep hypothermia with circulatory arrest. Determinants of stroke and early mortality in 656 patients. *J Thorac Cardiovasc Surg* 1993;106:19-28; discussion 28-31.
  21. Cao L, Guo X, Jia Y, et al. Effect of Deep Hypothermic Circulatory Arrest Versus Moderate Hypothermic Circulatory Arrest in Aortic Arch Surgery on Postoperative Renal Function: A Systematic Review and Meta-Analysis. *J Am Heart Assoc* 2020;9:e017939.
  22. Tian DH, Wan B, Di Eusanio M, et al. A systematic review and meta-analysis on the safety and efficacy of the frozen elephant trunk technique in aortic arch surgery. *Ann Cardiothorac Surg* 2013;2:581-91.
  23. Luehr M, Bachet J, Mohr FW, et al. Modern temperature management in aortic arch surgery: the dilemma of moderate hypothermia. *Eur J Cardiothorac Surg* 2014;45:27-39.
  24. Yan TD, Bannon PG, Bavaria J, et al. Consensus on hypothermia in aortic arch surgery. *Ann Cardiothorac Surg* 2013;2:163-8.
  25. McCullough JN, Zhang N, Reich DL, et al. Cerebral metabolic suppression during hypothermic circulatory arrest in humans. *Ann Thorac Surg* 1999;67:1895-9; discussion 1919-21.
  26. Stecker MM, Cheung AT, Pochettino A, et al. Deep hypothermic circulatory arrest: I. Effects of cooling on electroencephalogram and evoked potentials. *Ann Thorac Surg* 2001;71:14-21.
  27. Misfeld M, Leontyev S, Borger MA, et al. What is the best strategy for brain protection in patients undergoing aortic arch surgery? A single center experience of 636 patients. *Ann Thorac Surg* 2012;93:1502-8.
  28. Guilmet D, Roux PM, Bachet J, et al. A new technique of cerebral protection. Surgery of the aortic arch. *Presse Med* 1986;15:1096-8.
  29. Kazui T, Washiyama N, Muhammad BA, et al. Improved results of atherosclerotic arch aneurysm operations with a refined technique. *J Thorac Cardiovasc Surg* 2001;121:491-9.
  30. Di Eusanio M, Wesselink RM, Morshuis WJ, et al. Deep hypothermic circulatory arrest and antegrade selective cerebral perfusion during ascending aorta-hemiarch replacement: a retrospective comparative study. *J Thorac Cardiovasc Surg* 2003;125:849-54.
  31. Cefarelli M, Murana G, Surace GG, et al. Elective Aortic Arch Repair: Factors Influencing Neurologic Outcome in 791 Patients. *Ann Thorac Surg* 2017;104:2016-23.
  32. Etz CD, Kari FA, Mueller CS, et al. The collateral network concept: a reassessment of the anatomy of spinal cord perfusion. *J Thorac Cardiovasc Surg* 2011;141:1020-8.
  33. Zierer A, Detho F, Dzemali O, et al. Antegrade cerebral perfusion with mild hypothermia for aortic arch replacement: single-center experience in 245 consecutive patients. *Ann Thorac Surg* 2011;91:1868-73.
  34. Urbanski PP, Lenos A, Bougioukakis P, et al. Mild-to-moderate hypothermia in aortic arch surgery using circulatory arrest: a change of paradigm? *Eur J Cardiothorac Surg* 2012;41:185-91.
  35. Etz CD, Luehr M, Kari FA, et al. Selective cerebral perfusion at 28 degrees C--is the spinal cord safe? *Eur J Cardiothorac Surg* 2009;36:946-55.
  36. Kamiya H, Hagl C, Kropivnitskaya I, et al. The safety of moderate hypothermic lower body circulatory arrest with selective cerebral perfusion: a propensity score analysis. *J Thorac Cardiovasc Surg* 2007;133:501-9.
  37. Griep RB, Di Luozzo G. Hypothermia for aortic surgery. *J Thorac Cardiovasc Surg* 2013;145:S56-8.
  38. Tsagakis K, Osswald A, Weymann A, et al. The frozen elephant trunk technique: impact of proximalization and the four-sites perfusion technique. *Eur J Cardiothorac Surg* 2021;61:195-203.
  39. Di Eusanio M, Schepens MA, Morshuis WJ, et al. Separate grafts or en bloc anastomosis for arch vessels reimplantation to the aortic arch. *Ann Thorac Surg* 2004;77:2021-8.
  40. Matalanis G, Perera NK, Galvin SD. Aortic arch replacement without circulatory arrest or deep hypothermia: the "branch-first" technique. *J Thorac Cardiovasc Surg* 2015;149:S76-82.
  41. Matalanis G, Shi WY. An Australian experience with aortic

- arch replacement: a novel approach without circulatory arrest or deep hypothermia. *Heart Lung Circ* 2011;20:163-9.
42. Kim M, Matalanis G. Aortic arch replacement using the branch-first and frozen elephant trunk techniques. *Ann Cardiothorac Surg* 2020;9:259-61.
  43. Touati GD, Marticho P, Farag M, et al. Totally normothermic aortic arch replacement without circulatory arrest. *Eur J Cardiothorac Surg* 2007;32:263-8; discussion 268.
  44. Guo J, Wang Y, Zhu J, et al. Right axillary and femoral artery perfusion with mild hypothermia for aortic arch replacement. *J Cardiothorac Surg* 2014;9:94.
  45. Goto Y, Hosoba S, Fukumoto Y, et al. Mild Systemic Hypothermic Circulatory Arrest Using a Frozen Elephant Trunk Graft with Endo-Balloon Occlusion for Total Arch Replacement. *Heart Surg Forum* 2020;23:E673-6.
  46. Sun X, Guo H, Liu Y, et al. The aortic balloon occlusion technique in total arch replacement with frozen elephant trunk. *Eur J Cardiothorac Surg* 2019;55:1219-21.
  47. Li Y, Guo H, Wang L, et al. Application of Aortic Balloon Occlusion in Total Aortic Arch Replacement with Frozen Elephant Trunk on Clinical Endpoints for Aortic Dissection Patients. *Ann Thorac Cardiovasc Surg* 2020;26:332-41.
  48. Li Y, Guo H, Shi Y, et al. Early outcome of aortic balloon occlusion during total aortic arch replacement with the frozen elephant trunk technique for aortic dissection. *Interact Cardiovasc Thorac Surg* 2020;30:91-8.
  49. Liu Y, Shi Y, Guo H, et al. Aortic balloon occlusion technique versus moderate hypothermic circulatory arrest with antegrade cerebral perfusion in total arch replacement and frozen elephant trunk for acute type A aortic dissection [published online ahead of print, 2019 Oct 4]. *J Thorac Cardiovasc Surg* 2019;S0022-5223(19)31850-1.
  50. Liang S, Liu Y, Zhang B, et al. Early-to-midterm outcomes of aortic balloon occlusion technique versus hybrid procedure for aortic arch diseases. *Eur J Cardiothorac Surg* 2021;60:1447-54.
  51. Liang S, Liu Y, Zhang B, et al. A Comparison of Frozen Elephant Trunk, Aortic Balloon Occlusion, and Hybrid Repair for Total Arch Replacement. *Semin Thorac Cardiovasc Surg* 2021;33:667-75.
  52. Di Eusanio M, Gatta E. Frozen Elephant Trunk Without Circulatory Arrest in Acute Aortic Dissection. *Ann Thorac Surg* 2021;112:e143-5.
  53. Di Eusanio M, Cefarelli M, Alfonsi J, et al. Arch Surgery for Type Ia Endoleak: How to Remain Normothermic and Avoid Circulatory Arrest. *Ann Thorac Surg* 2020;110:e139-41.
  54. Di Eusanio M, Cefarelli M, Alfonsi J, et al. Normothermic frozen elephant trunk surgery without circulatory arrest: how we do it in Ancona. *Ann Cardiothorac Surg* 2020;9:244-5.

**Cite this article as:** Malvindi PG, Alfonsi J, Berretta P, Cefarelli M, Gatta E, Di Eusanio M. Normothermic frozen elephant trunk: our experience and literature review. *Cardiovasc Diagn Ther* 2022;12(3):262-271. doi: 10.21037/cdt-22-73