

SUCCESSFUL NON-OPERATIVE TREATMENT IN MICROCYSTIC LYMPHATIC MALFORMATION OF THE TONGUE: A CASE REPORT

Nuri Fitriasaki*, Irna Sufiawati**

* Oral Medicine Residency Program, Faculty of Dentistry, Padjadjaran University, Dr. Hasan Sadikin General Hospital, Bandung

** Department of Oral Medicine, Faculty of Dentistry, Padjadjaran University, Dr. Hasan Sadikin General Hospital, Bandung

Correspondence: nuri.fitriasaki@gmail.com

Keywords:

Microcystic lymphatic malformation;
Ultrasonography;
Corticosteroid; Antibiotics

ABSTRACT

Background: Microcystic lymphatic malformation (MLM) is an abnormal congenital growth of lymphatic vessels. It may occur in any part of the human body, with 75 % cases found in the head and neck, including in oral cavity. This case report aimed to describe a case of MLM in a child who was successfully treated non-operatively with antibiotics and corticosteroid.

Case Report: A 4-year-old child came to Oral Medicine Clinic of Dr. Hasan Sadikin General Hospital, Bandung, with a chief complaint lesions of the tongue since a year ago, accompanied by bleeding in the affected areas but not pain. Patient gave history of recurrent episodes of the symptoms since 7 months old.

Result : Ultrasonography was performed and diagnosis of microcystic lymphatic malformation was established. Systemic oral corticosteroid, antibiotics, and multivitamins were given and the lesions showed significant improvement after 2-weeks treatment.

Conclusion: Therapy of MLM with antibiotics and systemic oral corticosteroid significantly improved patient's condition, and ultrasonography may be used as a diagnostic modality in MLM diagnosis.

INTRODUCTION

Vascular anomalies are congenital defects of capillary, arterial, venous, or lymphatic vessels, occurring in 5 % of the population.¹ Classification of vascular anomalies includes histological, biological, and clinical consideration, and comprises two main groups, i.e. vascular tumors and malformations.^{1,2} Vascular anomalies have heterogenous pathological processes and multiple severity levels, and as such it is difficult to establish a gold standard treatment for the condition.³

Vascular malformations are caused by improper vascular morphogenesis and happened in 0.5 % population. It can be hemodynamically divided into low-flow lesions, e.g. capillary, venous

and lymphatic malformations (LM), and high-flow lesions, e.g. arteriovenous malformation and arteriovenous fistulas.^{1,4} Approximately 75 % vascular malformations occur in the head and neck, which includes oral cavity, followed by oropharyngeal and parapharyngeal areas. Intraorally, they are often found on the tongue, lips, buccal mucosae, and the the base and palate of the mouth.^{5,6} LM is a rare congenital defect which involves malformation of lymphatic vessels and classified into two types: the macrocystic lymphatic malformation with size 2 cm or more and clear borders, and microcystic lymphatic malformation (MLM) with size less than 2 cm and vague or diffuse borders. The MLM type is often found in oral cavity,

throat, tongue, and sub-mandibular and parotid glands, and may cause macroglossia and breathing or eating difficulties.^{5,7} Most LM cases were diagnosed after delivery, with 90 % before the patient was 2 years of age.^{5,6,8}

Diagnosis and treatment of LM is usually complex and difficult.^{1,3,4,9} Many suggestions have been made for LM malformation management, but its medication is still a challenge.^{5,8} The main goal of LM management is the functional and aesthetic restoration and preservation of the affected area.^{6,7} This case report presents the diagnosis and non-operative treatment of MLM in a child.

CASE REPORT

A 4-year-old child came to Oral Medicine Clinic of Dr. Hasan Sadikin General Hospital, Bandung, with a chief complaint of lesion of the tongue since a year ago, accompanied by bleeding in the affected areas but not pain. Patient gave history of recurrent episodes of the symptoms since 7 months old.

Intraoral examination showed non-scrapable multiple white and dark reddish vesicles, which covered two-thirds of dorsal surface and some parts of ventral surface of the tongue (Figure 1).

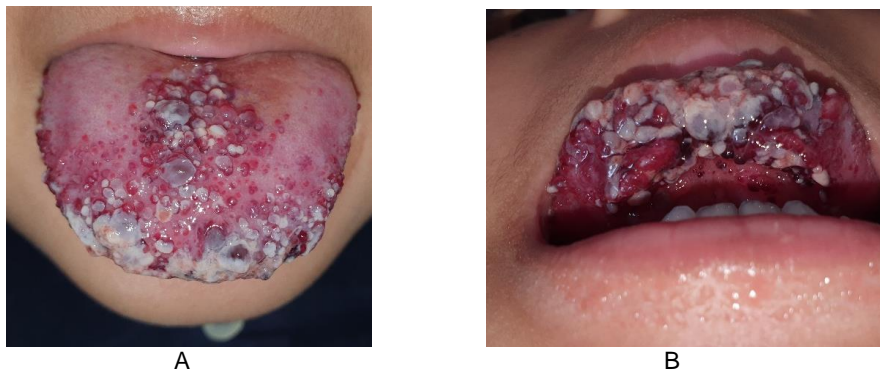

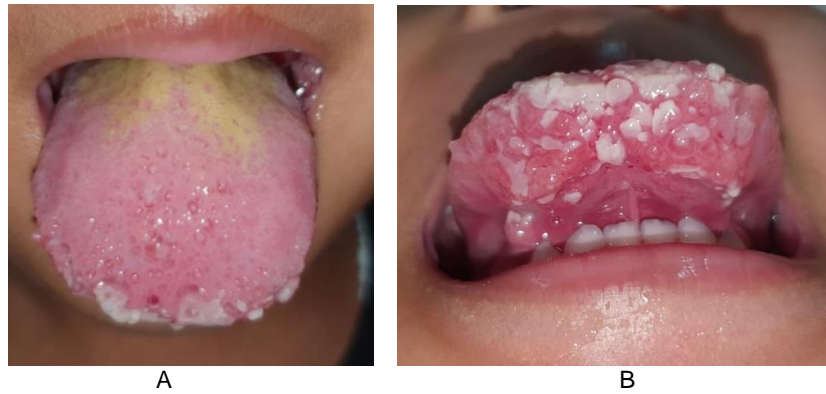Figure 1. Clinical presentation in first visit (A) Dorsal surface of the tongue, (B) Ventral surface of the tongue; multiple white, clear liquid and dark reddish vesicles, covering two-thirds of dorsal surface and some parts of ventral surface of the tongue.

After anamnesis and intraoral examination, the patient was diagnosed with MLM of the tongue, and differential diagnosis of hemangioma of the tongue. The patient was treated with pharmacological administration of antibiotics, corticosteroid, and vitamins.

Non-pharmacological treatment delivered was education of oral health, which includes how to clean the teeth with finely bristled toothbrush, and how to clean the tongue with povidone iodine on

sterile gauze gently rubbed on the tongue from posterior to anterior part, at least twice a day. The patient was advised to conduct ultrasonography and visit the clinic again in two weeks.

Two weeks later, the complaint improved. The patient reported no pain and no difficulty chewing, speaking, or breathing. Intraoral examination showed significant reduction in white and dark reddish vesicles compared to the condition in first visit (Figure 2).



Gambar 2. Clinical presentation in second visit (A) Dorsal surface of the tongue, (B) Ventral surface of the tongue; significant improvement in both areas affected

Diagnostic examination, namely ultrasonography, supported the MLM diagnosis, thus eliminating the hemangioma differential

(Figure 3). The patient showed significant improvement throughout two weeks of therapy.

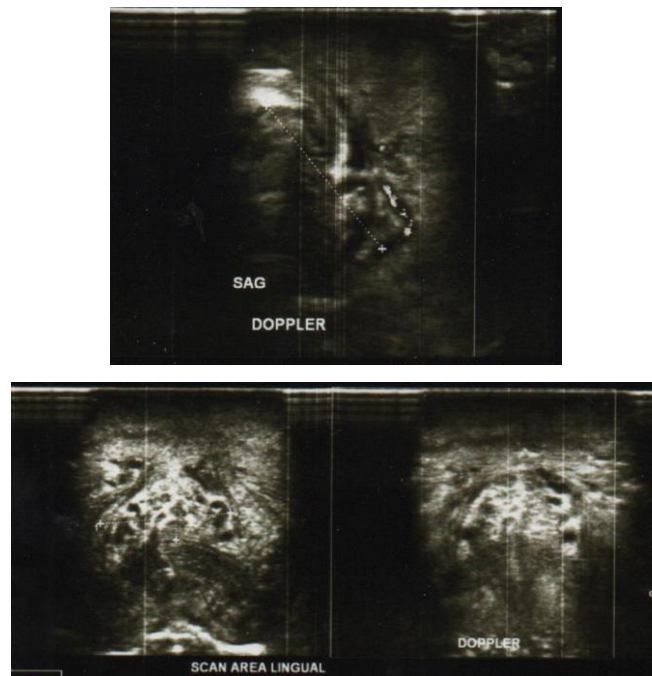


Figure 3. Ultrasonogram showed isoechoic inhomogeneous lesions with hypoechoic lesions within, lobulated, relatively clear borders, irregular, 1.9x0,96 cm in size and 2.12 cm in depth. Color Doppler did not show intralesional vascularization.

Non-pharmacologic management includes communication, information, and education regarding MLM, specifically its potential of

recurrence and possible operative treatment, and reminder to maintain oral health. The parent of the patient chose observing his condition.

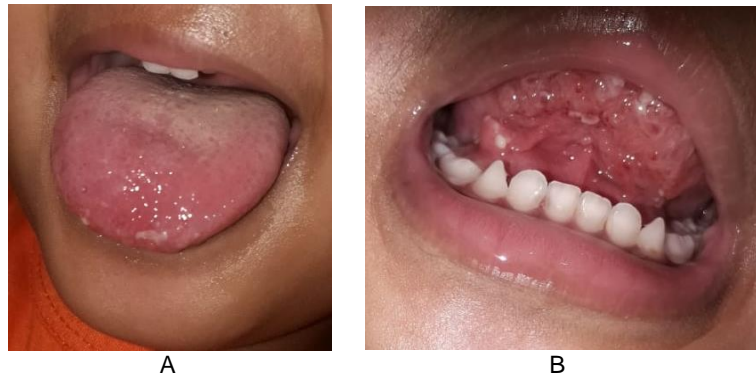

Figure 4. Clinical presentation during observation showed further improvement, with only very few white vesicles on the dorsal and ventral surface of the tongue.

DISCUSSION

Mulliken and Glowacki (1982) classified vascular anomalies according to their biological lesions, and this classification was adopted by the International Society for the Study of Vascular Anomalies (ISSVA) in 1996. This biological classification has further been revised in 2015 following a growing understanding in the field.¹ Vascular anomalies, i.e. tumors and malformations, became classified based on their clinical presentation and cellular characteristics, and with this classification at least 90 % of the diagnoses can be established from anamnesis and physical examination.^{1,10,11}

Anamnesis and physical examination results which usually indicate LM of the tongue include history of recurrence of lesions.¹² LM of the tongue tends to be microcystic, coarse, diffuse, and occur in anterior two-thirds of dorsal surface of the tongue.¹² LM can present in multiple vesicles either containing clear liquid or hemorrhagic with diffuse borders, and these vesicles may thicken or swell.^{5,9,13} These vesicles may rupture either spontaneously or after infection or trauma.¹² These clinical findings were also found in the present case.

Ultrasonography is the first-line imaging modality in LM diagnostic test, especially in children, as sedation is not necessary.⁴ Ultrasonography usually shows multiloculated cystic lesions, bound by septae with variable

thickness, although in some cases it shows irregular or calcified appearance. Doppler imaging will show no blood flow in the lesions.⁸ While ultrasonography may not be as informative as magnetic resonance imaging, it can deliver diagnostic confirmation, show the existence of intralesional bleeding, and distinguish between macrocystic and microcystic lesions.¹⁰ In the present case, the result showed MLM lesions with 1.94x0.96 cm size, and color Doppler imaging did not show intralesional vascularization, which also support the diagnosis of MLM.

Therapy for MLM is complex, considering the high recurrence rate (50 -66 %).^{7,9} The impact of this recurrence alongside negative functional and aesthetic effects of MLM cannot be ignored, especially in microcystic lesions where the lesions may expand without clear borders.¹⁴ That being said, MLM is non-malignant and intervention is not always mandatory, e.g. in minor and asymptomatic lesions where just observation is feasible. Intervention is preferred for LM with painful or significant lesions, and where LM threatens vital structures.¹⁰

Conservative observation management is better saved for asymptomatic patients before definitive therapy is delivered. With the watchful waiting attitude, antibiotic administration will follow the appearance of a first symptom when there is a

rapid progression in the lesion size, or swelling from suspected infection.¹²

Intralesional bleeding happens in up to 35 % MLM cases. It caused bluish discoloration, pain, or swelling.^{8,10} Because MLM the risk of infection, good oral hygiene must be maintained.¹⁰ In this patient, bleeding often happened but there is no pain, and as such we treat the patients with antibiotics and education on oral hygiene, including how to brush teeth and tongue with proper technique at least twice a day after breakfast and before sleep.

Although antibiotics must be given to prevent the occurrence or the spread of an infection, in the case of acute swelling in MLM, corticosteroids may be prescribed to reduce edema.¹² Steroids has been used to treat vascular malformation, with various results.¹⁵

Short-time combination of antibiotics and systemic corticosteroids usually results in improvement of symptoms, with reduction in swelling and inflammation. As such, this mode of therapy is presently used in all patients with cases of LM before definitive therapy. For this patient we also administer oral corticosteroid. Systemic corticosteroid for MLM helps lessen lymphoid hypertrophy, stabilize blood vessels to reduce bleeding and liquid osmosis into surrounding tissues.¹² Other than that, criteria for therapy must bring into consideration the patient's age, size and type of the lesion, functional symptoms (respiration, swallowing, bleeding, phonation), and therapeutic goals (definitive, sequential, palliative).¹⁴ In the present case, the patient did not report difficulties in eating, speaking, or breathing alongside the appearance of the lesions. Most MLM cases in children did not need urgent treatment during diagnosis. Treatment must be individually tailored, and decisions on treatment must again be based on MLM characteristics, patient's age, and also the

patient's and their parent's desire. Some parents decide to wait until the child grows for some time before they decide to continue with operative intervention or not.^{10,16} In the present case, the parent decided to watch, which entails observation and non-operative medication until the desired improvement is achieved.

CONCLUSION

Non-operative treatment of MLM using antibiotics and corticosteroid shows significant improvement of the patient's condition, and ultrasonography may be used as one of the diagnostic modalities for MLM.

REFERENCES

1. Greene A. Operative Management of Vascular Anomalies. *Operative Management of Vascular Anomalies*. Rio de Janeiro: Thieme; 2017. 3–109 p.
2. Richter GT, Friedman AB. Hemangiomas and Vascular Malformations: Current Theory and Management. *Int J Pediatr*. 2012;2012:1–10.
3. Freixo C, Ferreira V, Martins J, Almeida R, Caldeira D, Rosa M, et al. Efficacy and safety of sirolimus in the treatment of vascular anomalies: A systematic review. *J Vasc Surg*. 2020;71(1):318–27.
4. White CL, Olivieri B, Restrepo R, McKeon B, Pinar Karakas S, Lee EY. Low-flow vascular malformation pitfalls: From clinical examination to practical imaging evaluation - Part 1, lymphatic malformation mimickers. *Am J Roentgenol*. 2016;206(5):940–51.
5. Eltohami YI, Alim NE, Abuaffan AH. Microcystic Lymphatic Malformation: A Case Report. *Dentistry*. 2017;07(03):2–3.
6. Cheng LH, Lee JC, Kao CH, Shi ZP, Lin YS. Lymphangiomatous macroglossia associated with extensive cervicomediastinal cystic hygromas. *J Chinese Med Assoc*. 2013;76(11):653–6.
7. Khanum N, Smitha, Kanwar S. Microcystic Lymphatic Malformation: A Case Report. *Dentistry*. 2017;07(03):67–70.
8. Ma J, Biao R, Lou F, Lin K, Gao YQ, Wang ML, et al. Diagnosis and surgical treatment of cervical macrocystic lymphatic malformations in infants. *Exp Ther Med*. 2017;14(2):1293–8.
9. Garcia-Montero P, Del Boz J, Sanchez-Martinez M, Santos IME, Baselga E. Microcystic lymphatic malformation

- successfully treated with topical rapamycin. *Pediatrics*. 2017;139(5).
10. Greene AK, Perlyn CA, Alomari AI. Management of lymphatic malformations. *Clin Plast Surg*. 2011;38(1):75–82.
 11. M JF, Soni HM, Pimpalwar S. Medical management of vascular anomalies. *Semin Cutan Med Surg*. 2016;35(3):177–81.
 12. Wiegand S, Eivazi B, Zimmermann AP. Microcystic Lymphatic Malformations of the Tongue. *Arch Otolaryngol Head Neck Surg*. 2011;135(10):976–83.
 13. Kulungowski AM, Patel M. Lymphatic malformations. *Natl Organ Rare Disord*. 2020;29(5):1–10.
 14. Lerat J, Mounayer C, Scomparin A, Orsel S, Bessede JP, Aubry K. Head and neck lymphatic malformation and treatment: Clinical study of 23 cases. *Eur Ann Otorhinolaryngol Head Neck Dis*. 2016;133(6):393–6.
 15. Ricci KW. Advances in the medical management of vascular anomalies. *Semin Intervent Radiol*. 2017;34(7):239–49.
 16. Wiegand S, Wichmann G, Dletz A. Treatment of Lymphatic Malformations with the mTOR Inhibitor Sirolimus: A Systematic Review. *Lymphat Res Biol*. 2018;16(4):330–9.