

Original Article

Effect of vitamin C and quercetin treatment on the liver histopathologic profile in congenital lead exposed male rat pups

Narjes Beheshti¹, Farzaneh Ganji^{1*}, Hamid Sepehri²

1. Department of Biology, Faculty of Sciences, Golestan University, Gorgan, Iran

2. Department of Physiology, Faculty of Medicine, Golestan University of Medical Sciences, Gorgan, Iran

Abstract

Introduction: Lead is one of the most important environmental pollutants due to its vast use in various industries. Lead accumulation in different organs, especially the brain, liver and kidneys can cause serious health problems. Lead exposure is more dangerous during fetal period and childhood.

Materials and Methods: Timed pregnant female rats divided into 6 groups. Group 1 served as control group and received tap water, group 2 received 500 mg/liter lead acetate in the drinking water from 5th day of gestation up to 25th day post-partum, group 3 received the same dose of lead acetate along with daily IP injection of 40mg/kg quercetin, Group 4 received the same dose of lead acetate along with 2g/liter vitamin C, groups 5 and 6 received vitamin C and quercetin respectively like groups 2 and 3 but without lead acetate. On the 25th day postpartum, 6 male pups in each group were deeply anesthetized by chloroform; livers were removed and processed for Hematoxyline- Eosin staining. The microscopic slides were photographed and liver tissue morphological characteristics were evaluated.

Results: Lead exposure caused extensive histopathologic changes in liver tissue including hepatocyte degradation, cell nucleus bifurcation and inflammation around hepatic veins. Quercetin and vitamin C treatment could prevent these pathologic changes to a considerable extent.

Conclusion: Vitamin C in drinking water and quercetin via IP injection could protect the liver tissue against lead hepatotoxic effects.

Keywords:

lead exposure;
liver;
quercetin;
vitamin C;

Received:

10 Jun 2014

Accepted:

2 Sep 2014

*Correspondence to:

F. Ganji

Tel./fax:

01732220084

Email:

fganji2@yahoo.com

Introduction

Lead, a non-physiological heavy metal, was one of the first metals used by man. Its wide application was begun since over 8000 years ago (Järup, 2003). With

the onset of the Industrial Revolution in Europe, the unique properties of lead made this heavy metal a good choice in various industries including printing, paint industry, producing all kinds of batteries, making glazes and ceramic tiles as well as making the bullets and ammunition, but the main use of lead in the form

of tetraethyl lead, which is used as an antiknock agent in leaded gasoline, was began in 1920s (Lessler, 1988). Along with this wide use of lead, its harmful effects gradually appeared. Lead poisoning is one of the first known occupational diseases and a detailed report on gastrointestinal complications of lead entitled "Diseases caused by lead," has been published in 1848 (Azizi and Azizi, 2010). There are many reports in the scientific literature about adverse effects of lead exposure on almost every organ in vertebrates' body. Thus, adding lead to gasoline in developed countries have been stopped since 1970s (Meyer *et al.*, 2008). However, it is used extensively in battery manufacture, solders, pigments (specially for outdoor paints which require greater resilience to weather) radiation shielding, lead shot for firearms and rubber and plastic manufacturing and there was no suitable replacement for lead until now, and so this metal is still released into the air and soil (Bradberry and Vale, 2003). Because lead is stable in nature and there is no way to clean up soil and water contaminated with lead, environmental pollution by lead has remained as an important unsolved health problem resulting in chronic exposure in the general population and lead contamination is still a public health problem in many countries due to domestic exposure through contaminated water and soil (Sabath and Robles-Osorio, 2012). Lead exposure in the general population occurs primarily through ingestion (about 10-15% absorbed) and inhalation (up to 80% absorbed) (Grandjean, 1993). Gastrointestinal absorption of lead is greatest in infancy; infants can absorb about 50% of lead ingested from food, water or dust while adults absorb only 10-15 percent of ingested lead (Markowitz, 2000). The absorbed lead is conjugated in the liver and passed to the kidneys, where part of it is excreted in the urine and the rest of absorbed lead accumulates in various body organs, affecting many biological functions at the molecular, cellular and intercellular levels. These altered biological functions result in morphological changes that can remain even after blood lead levels have fallen (Flora *et al.*, 2006; Jarrar, 2003; Sidhu and Nehru, 2003). The liver is a sensitive target organ for lead exposure and children are more sensitive to lead adverse effects on various

organs (Hernandez-Avila *et al.*, 2002).

Since it is impossible to eliminate lead from the environment, a large number of studies in recent years have been devoted to find ways to ameliorate the toxic effects of lead. The biochemical and molecular mechanisms of lead toxicity are poorly understood, but emerging data suggest that some of the effects of lead may be attributed to production of reactive oxygen species (ROS) and causing oxidative stress in the living organs (Flora, 2009; Patra *et al.*, 2011). Evidences suggest significant protective effects of antioxidant nutrients such as vitamin C, flavonoids, carotenoids, selenium, vitamin-E, and so forth. Vitamin C is a major antioxidant that scavenges the aqueous ROS by very rapid electron transfer and inhibits lipid peroxidation (Patra *et al.*, 2011).

Quercetin, one of the most abundant flavonoids in human diet, is a strong oxygen radical scavenger and good metal chelator (Patra *et al.*, 2011). In the light of the recent findings it seems reasonable to expect that administration of vitamin C and quercetin might contribute to reduce liver damage after lead exposure. Thus, the purpose of our study was to ascertain whether treatment with vitamin C and quercetin exerts any beneficial effect on liver histopathology after congenital lead exposure.

Materials and methods

Timed pregnant Wistar rats (Pasteur's Institute, Tehran, Iran) were housed individually in plastic cages with free access to food and water. The animal room was maintained at constant 22–24 °C temperature under a 12-h light/12-h dark cycle. The study was performed according to the guidelines for laboratory animal use and care set forth by the research council at Golestan University of Medical Sciences (Gorgan–Iran). The rats were divided into six groups of 8 animals in each on day 5 of gestation:

1. Control group: received deionized water as drinking water.
2. Lead acetate treatment: received a solution of 500 mg/L of lead acetate (Merck) as drinking water.
3. Lead acetate+vitamin C treatment: received a solution of 500 mg /L lead acetate plus vitamin

Table 1. Semi quantitative evaluation of histopathologic changes in 6 experimental groups. Group 1; Control, Group 2; Lead acetate treatment, Group 3; Lead acetate + vitamin C treatment, Group 4; Lead acetate + quercetin treatment, Group 5; Vitamin C treatment, Group 6; Quercetin treatment

	Group 1	Group 2	Group 3	Group 4	Group 5	Group 6
Inflammation	-	+++	+	+	-	-
Large Nuclei	+	+++	++	+	+	+
Binucleated Hepatocytes	+	+++	+	++	+	+
Kupffer Cells Hyperplasia	-	++	+	+	-	-

C (2 g/L) as drinking water

4. Lead acetate+quercetin: received a solution of 500 mg/L lead acetate plus daily intraperitoneal (ip) injection of 40 mg/kg quercetin dissolved in dimethyl sulfoxide (DMSO).
5. Vitamin C treatment: received a solution of vitamin C (2gr/L) as drinking water.
6. Quercetin treatment: received daily ip injections of 40mg/kg of quercetin dissolved in DMSO.

Lead acetate containing solutions were prepared by dissolving the salt in distilled water and were replaced daily to minimize precipitation.

Treatments were started from the 5th day of pregnancy until postnatal day (PND) 25. At birth 8 pups were left with each dam and on PND 25, six male pups in each experimental group were used for histological evaluation.

The pups were deeply anesthetized with chloroform, for each animal the chest was opened. Then liver was excised, washed with normal saline, divided into 0.7×0.7×0.7 cm tissue blocks and transferred to 10% formaldehyde solution for 72 hour. After fixation, tissue blocks were dehydrated in ascending alcohol grades, cleared in xylene and embedded in paraffin. Paraffin embedded blocks were cut into 5-6µm tissue sections using a rotary microtome. For every 5 serial sections one section was transferred on the microscopic slides and the slides were stained with Hematoxyline and Eosin. For semi quantitative evaluations, for each experimental group five microscopic slides having four tissue sections on them were selected. Under the 40x power of microscope, for each slide 10 different view field were photographed using a DP71 digital camera mounted on a BX51 Olympus microscope. The histopathologic

changes observed in photomicrographs were scored as mentioned below:

Without any change (-), histopathologic changes in less than 20% of view fields (+), histopathological changes in 20-60% of view fields (++), histopathological changes in more than 60% of view fields (+++) (Benli *et al.*, 2008).

Results

The histological profiles of liver in six experimental groups are shown in figures 1 and 2. The results of semi-quantitative evaluation are shown in table 1. Congenital lead exposure induced mild to severe chronic mononuclear inflammatory exudate comprising mainly lymphocytes infiltrated in the perivenous areas (Figure 2, A and B). In lead acetate treated group the hyperplasia of sinusoidal Kupffer cells was seen (Table 1 and Figure 1,B) and occasional autolytic changes were observed in the hepatocytes' cytoplasm which are hallmarks of necrosis (Figure 2 B). Nuclei with a diameter larger than 12 µm were considered as large nuclei. In lead treated group hepatocyte nuclei were larger compared to normals and binucleated hepatocytes were more prominent in this experimental group (Figure 1B). Co-administration of lead acetate and vitamin C or quercetin has ameliorated these morphological changes. In tissue sections of lead plus vitamin C and lead plus quercetin groups the histopathologic profile of liver showed a near normal appearance (Figure 1, C and D). Vitamin C alone or quercetin alone treatment has no impact on the morphological characteristics of the liver compared to control group. In our evaluations, the protective

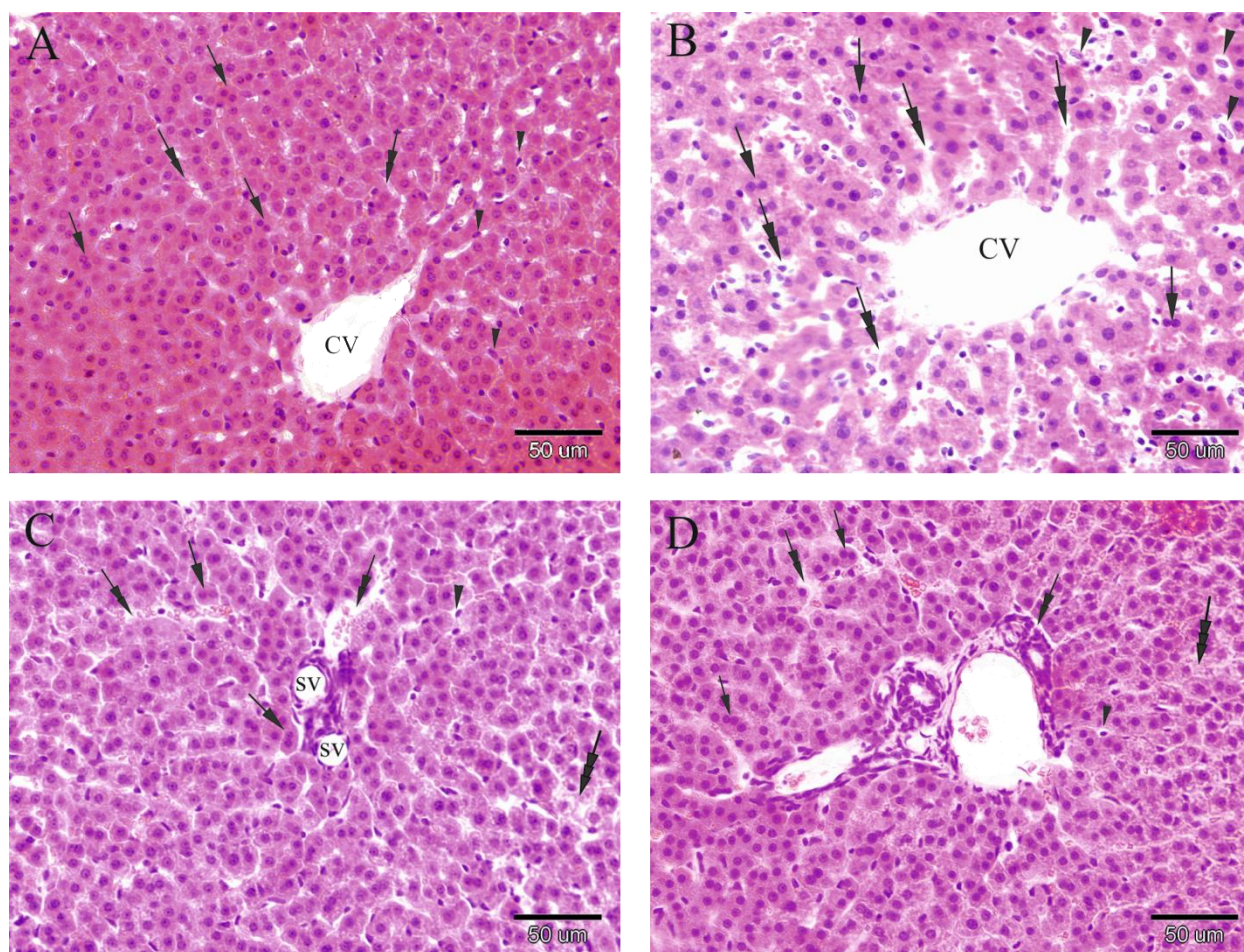


Fig 1: Photomicrographs showing liver sections in A; control group with a normal appearance and few binucleated hepatocyte (arrows), Kupffer cells (arrow heads) and normal sinusoids (double headed arrows) B; lead acetate treated group with Kupffer cells hyperplasia, congested sinusoids and autolytic cytoplasm (three headed arrow) C; Lead acetate plus vitamin C and D; lead acetate plus quercetin. Hepatocytes and sinusoidal spaces show a near normal appearance. CV; central vein, SV; small vein

effects of vitamin C and quercetin against lead hepatotoxicity showed similar characteristics.

Discussion

The histopathological examination of the liver of lead acetate treated rat pups showed remarkable inflammation and necrosis as well as having a high number of binucleated hepatocytes versus control animals. These histopathological changes due to lead exposure are in agreement with those of Jarrar (Jarrar and Taib, 2012) and Del Monte (2005). When vitamin C and quercetin were given to lead treated animals, the liver showed a near normal appearance. Oxidative stress is one of the most explained

mechanisms for lead hepatotoxicity (Flora, 2009; Jarrar and Taib, 2012). It is reported that lead exposure can induce the production of reactive oxygen species (ROS) in the lungs, blood vessels endothelium, testis, liver and brain tissue (Hsu and Guo, 2002). Johar et al. in a chronic lead exposure model have observed neutrophilic infiltrations in portal space. The lead adverse effects on hepatic enzymes and proteins or its interaction with antioxidant defense mechanisms can cause these infiltrations to occur (Johar et al., 2004). In the recent years, adding natural antioxidants and vitamins to the diet for prevention of the hazards of carcinogens and heavy metal exposure has been investigated (Dawson et al., 1999; Echeverry et al., 2010;

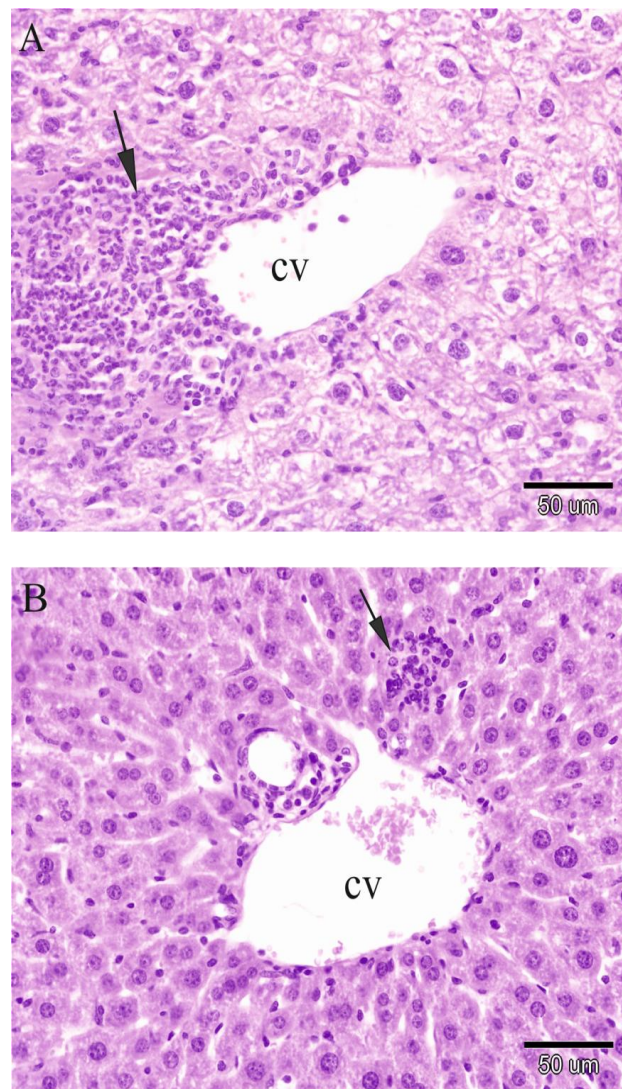


Fig 2: Photomicrographs showing liver tissue in lead acetate treated group, A and lead acetate plus quercetin, B. Lead exposure caused severe mononuclear infiltration (arrow) around central vein (CV). Hepatocyte cytoplasm showed necrotic changes. Co-administration of lead acetate and quercetin protects the tissue against lead hepatotoxicity. Mononuclear infiltrations and hepatocyte necrosis are not as severe as the lead exposure group.

Neuhaus ML and ML, 2004). These natural nutrients showed beneficial effects against lead toxic effects in living organs (Schneider *et al.*, 2001; Sharma and Pandey, 2010). Vitamin C, Vitamin E, some flavonoids like quercetin and purarine can protect the cells from oxidative damage of free radicals formed under lead exposure, they also can chelate the lead ions (Flora, 2009; Flora *et al.*, 2007). Vitamin C is a well-known free radical scavenger and it has been shown that this antioxidant agent can prevent the lead induced lipid peroxidation in the rat brain and liver (Patra *et al.*, 2011). Using a 500mg/liter vitamin C solution as drinking water has reduced the ROS production to 40% in the rat (Hsu

and Guo, 2002). Vitamin C content of rat liver in a lead exposure model like our model showed a 26% decrease (Jurczuk *et al.*, 2006). Unlike human, rat liver synthesizes the animal's need for vitamin C and maybe the depletion of hepatic vitamin C for fighting free radicals increases the need for this vitamin beyond the liver's potency for vitamin C synthesis and so, the exogenous vitamin C may reverse the adverse effect of lead on the liver. On the other hand, vitamin C besides its antioxidant effects reduces the intestinal absorption of lead. This molecule reduces ferrous iron to its ferric form and ferric ions compete with lead in absorption through divalent metal transporter 1 (DMT1) (Suzuki and Yoshida, 1979).

Moreover, vitamin C has prevented lead ions from entering into mammalian cells in tissue cultures; the mechanism of this prevention is unclear (Fischer *et al.*, 1998).

Quercetin, another potent antioxidant is one of the several naturally-occurring dietary flavonol compounds with a broad range of biological functions (Neuhouser ML and ML, 2004). This molecule has shown potent anti ROS and chelating properties in several studies. In our study quercetin like vitamin C protects the liver tissue against lead induced hepatotoxicity (Harwood *et al.*, 2007).

Co-administration of vitamin C and quercetin with lead acetate in a congenital lead exposure model could improve the liver histopathological profile. Because of potent antioxidant activity of these molecules, lead may induce its hepatotoxic effects mainly through oxidative stress. Light microscope studies were unable to show any difference between vitamin C and quercetin in protecting the liver tissue against congenital lead exposure. It seems having a vitamin C and quercetin rich diet through pregnancy and lactation periods and infancy can reduce the hepatotoxic effects of lead in lead contaminated areas.

Acknowledgments

This research was supported by a fund from the Golestan University. The authors wish to thank the Department of Physiology, Golestan University of Medical Sciences for providing the facilities for animal treatments.

Conflict of interest

The authors declare that they have no conflict of interest.

References

- Azizi MH, Azizi F. Lead poisoning in the world and Iran. *Int. J. Occup. Environ. Med.* 2010; 1: 81–87.
- Benli ACK, Köksal G, Ozkul A. Sublethal ammonia exposure of Nile tilapia (*Oreochromis niloticus* L.): effects on gill, liver and kidney histology. *Chemosphere* 2008; 72: 1355–1358.
- Bradberry S, Vale A. *Lead. Medicine* (Baltimore) 2003; 31: 56–57.
- Dawson EB, Evans DR, Harris WA, Teter MC, McGanity WJ. The effect of ascorbic acid supplementation on the blood lead levels of smokers. *J. Am. Coll. Nutr.* 1999; 18: 166–170.
- Del Monte. Swelling of hepatocytes injured by oxidative stress suggests pathological changes related to macromolecular crowding. *Med. Hypotheses* 2005; 64: 818–825.
- Echeverry C, Arredondo F, Abin-Carriquiry JA, Midiwo JO, Ochieng C, Kerubo L, et al. Pretreatment with natural flavones and neuronal cell survival after oxidative stress: a structure-activity relationship study. *J. Agric. Food Chem.* 2010; 58: 2111–2115.
- Fischer AB, Hess C, Neubauer T, Eikmann T. Testing of chelating agents and vitamins against lead toxicity using mammalian cell cultures. *The Analyst* 1998; 123: 55–58.
- Flora SJ. Structural, chemical and biological aspects of antioxidants for strategies against metal and metalloids exposure. *Oxid Med Cell Longev* 2009; 2: 191–206.
- Flora SJS, Flora G, Saxena G. Chapter 4 - Environmental occurrence, health effects and management of lead poisoning [Internet]. In: José S. Casas, José Sordo, editor(s). *Lead*. Amsterdam: Elsevier Science B.V.; 2006. p. 158–228. [cited 2013 Jul 11] Available from: <http://www.sciencedirect.com/science/article/pii/B978044452945950004X>
- Flora SJS, Saxena G, Mehta A. Reversal of Lead-Induced Neuronal Apoptosis by Chelation Treatment in Rats: Role of Reactive Oxygen Species and Intracellular Ca²⁺. *J. Pharmacol. Exp. Ther.* 2007; 322: 108–116.
- Grandjean P. International perspectives of lead exposure and lead toxicity. *Neurotoxicology* 1993; 14: 9–14.
- Harwood M, Danielewska-Nikiel B, Borzelleca JF, Flamm GW, Williams GM, Lines TC. A critical review of the data related to the safety of quercetin and lack of evidence of in vivo toxicity, including lack of genotoxic/carcinogenic properties. *Food Chem. Toxicol. Int. J. Publ. Br. Ind. Biol. Res. Assoc.* 2007; 45: 2179–2205.
- Hernandez-Avila M, Peterson KE, Gonzalez-Cossio T, Sanin LH, Aro A, Schnaas L, et al. Effect of maternal bone lead on length and head circumference of newborns and 1-month-old infants. *Arch. Environ. Health* 2002; 57: 482–488.
- Hsu P-C, Guo YL. Antioxidant nutrients and lead toxicity. *Toxicology* 2002; 180: 33–44.
- Jarrar BM. Histological and histochemical alterations in the kidney induced by lead. *Ann. Saudi Med.* 2003; 23: 10–15.
- Jarrar BM, Taib NT. Histological and histochemical alterations in the liver induced by lead chronic toxicity. *Saudi J. Biol. Sci.* 2012; 19: 203–210.
- Järup L. Hazards of heavy metal contamination. *Br. Med. Bull.* 2003; 68: 167–182.
- Johar D, Roth JC, Bay GH, Walker JN, Krocak TJ, Los M. Inflammatory response, reactive oxygen species, programmed (necrotic-like and apoptotic) cell death and cancer. *Rocz. Akad. Med. W Białymst.* 1995 2004; 49: 31–39.

- Jurczuk M, Moniuszko-Jakoniuk J, Brzóska MM. Involvement of some low-molecular thiols in the peroxidative mechanisms of lead and ethanol action on rat liver and kidney. *Toxicology* 2006; 219: 11–21.
- Lessler MA. Lead and Lead Poisoning from Antiquity to Modern Times [Internet]. 1988[cited 2013 Sep 4] Available from: <http://hdl.handle.net/1811/23252>
- Markowitz M. Lead poisoning. *Pediatr. Rev. Am. Acad. Pediatr.* 2000; 21: 327–335.
- Meyer PA, Brown MJ, Falk H. Global approach to reducing lead exposure and poisoning. *Mutat. Res.* 2008; 659: 166–175.
- Neuhouser ML, ML N. Dietary flavonoids and cancer risk: evidence from human population studies. *Nutr Cancer* 2004; 50: 1–7.
- Patra RC, Rautray AK, Swarup D. Oxidative stress in lead and cadmium toxicity and its amelioration. *Vet. Med. Int.* 2011; 2011: 457327.
- Sabath E, Robles-Osorio ML. Renal health and the environment: heavy metal nephrotoxicity. *Nefrol. Publ. Of. Soc. Esp. Nefrol.* 2012; 32: 279–286.
- Schneider JS, Lee MH, Anderson DW, Zuck L, Lidsky TI. Enriched environment during development is protective against lead-induced neurotoxicity. *Brain Res.* 2001; 896: 48–55.
- Sharma V, Pandey D. Protective Role of *Tinospora cordifolia* against Lead-induced Hepatotoxicity. *Toxicol. Int.* 2010; 17: 12–17.
- Sidhu P, Nehru B. Relationship between lead-induced biochemical and behavioral changes with trace element concentrations in rat brain. *Biol. Trace Elem. Res.* 2003; 92: 245–256.
- Suzuki T, Yoshida A. Effectiveness of dietary iron and ascorbic acid in the prevention and cure of moderately long-term lead toxicity in rats. *J. Nutr.* 1979; 109: 1974–1978.