

# Teratogenic effects of gabapentin on the skeletal system of Balb/C mice fetuses

Mohammad Afshar, MSc, PhD, Mohammad M. Hassanzadeh-Taberi, MSc, PhD, Seyed-Adel Moallem, PharmD, PhD, Azadeh Tamizi, MD, Mohammad J. Golalipour, MSc, PhD.

## ABSTRACT

**الاهداف:** قمنا بتقييم آثار تلقي عقار جابابنتين (GBP) على أجنة الفئران الحوامل .

**الطريقة:** تم إجراء الدراسة بجامعة برجانده للعلوم الطبية خلال عام 2008. تم تقسيم عدد 30 فأرة حامل نوع Balb/c عشوائياً الى ثلاث مجموعات: مجموعتين وهما مجموعتنا التجريبية وتلقنا مقدار 25 ملجم (للمجموعة الأولى) ومقدار 50 ملجم (للمجموعة الثانية) من عقار جابابنتين (GBP) عبر الصفاق خلال الخمسة عشر يوماً الأولى من الحمل. وتلقنا مجموعة واحدة وهي مجموعة التحكم المحلول الملحي العادي. تم القيام بالمراقبة الخارجية لمدة 18 يوماً للأجنة والصبغة المزدوجة للهيكل العظمي .

**النتائج:** ظهر على مجموعتي التجربة اضطرابات مشابهة والتي يمكن تصنيفها كالتالي: 1) انخفاض في وزن جسم الجنين وزيادة في الارتشاف، 2) تشوه مجهري، 3) تشوهات هيكلية عظمية. كان وزن الجسم والارتشاف لدى مجموعتي التجربة أقل بشكل ملحوظ وأعلى مقارنة مع مجموعة التحكم على التوالي. شملت التشوهات المجهريّة على برانية الدماغ، عيوب الأطراف، قصر الفك و تشوه العمود الفقري والأجنة مع تأخر النمو. اشتملت التشوهات العظمية على تأخر التعظم، الجنف، تشوه القحف ونقص التنسج الفكي .

**خاتمة:** كشفت هذه الدراسة أن عقار (GBP) قد يثير تشوهات شديدة مسبقة وغير مذكورة إذا تم استعماله باستمراراً خلال مراحل غرس أو زرع البيضة، التكون العصبي و تكون الأعضاء من الحمل. لذلك من المقترح أخذ الحذر الشديد خلال استعمال عقار (GBP) أثناء المراحل المبكرة من الحمل حتى يتم القيام بالمزيد من الدراسات لتفهم هذه الآثار بشكل أفضل .

**Objectives:** To evaluate the effects of gabapentin (GBP) administration on mice fetuses.

**Methods:** This study was carried out in Birjand University of Medical Sciences during 2008. Thirty Balb/c pregnant mice were divided randomly into 3 groups: 2 experimental groups that received 25 mg/kg (I) and 50 mg/kg (II) of GBP intraperitoneally for the first 15 days of pregnancy, and a control group

that received normal saline. External observations of day 18 fetuses and skeleton double staining were performed.

**Results:** Both experimental groups showed similar disorders that can be categorized as the following: 1) decrease of fetal body weight and increase of fetal resorption, 2) macroscopic malformations, and 3) skeletal malformations. Fetal body weights were significantly lower, and fetus resorptions were significantly higher in both treated groups compared to the control group. Macroscopic malformations included exencephaly, limbs defects, brachygnathia, vertebral column deformity, and fetuses with severe retarded growth. Skeletal malformations included delayed ossification, scoliosis, calvaria deformity, and mandibular hypoplasia.

**Conclusion:** This study revealed that GBP can induce previously unreported severe malformations if it is used continuously during the implantation, neurulation, and organogenesis stages of pregnancy. Therefore, it is suggested that great caution should be exercised in using GBP during the early stages of pregnancy until further studies are performed to better understand these effects.

*Neurosciences 2009; Vol. 14 (3): 239-244*

*From the Department of Anatomy (Afshar, Hassanzadeh-Taberi, Tamizi), Birjand University of Medical Sciences, Birjand, the Department of Pharmacodynamics and Toxicology (Moallem), School of Pharmacy, Pharmaceutical Research Center, Medical Toxicology Research Center, Mashhad University of Medical Sciences, Mashhad, and the Department of Anatomy (Golalipour), Gorgan University of Medical Sciences, Gorgan, Iran.*

*Received 20th November 2008. Accepted 18th March 2009.*

*Address correspondence and reprint request to: Dr. Mohammad M. H. Taberi, Department of Anatomy, Birjand University of Medical Sciences, Birjand, Islamic Republic of Iran. Tel. +98 (915) 3617955. Fax. +98 (561) 4440447. E-mail: mmhtabery35@yahoo.com*

Epilepsy is the second leading cause of CNS morbidity after cerebrovascular accidents,<sup>1</sup> and approximately 1% percent of adults, and 5% of children are affected worldwide, and nearly all have to take antiepileptic drugs (AEDs).<sup>2</sup> The use of AEDs in

pregnancy may have potential effects on embryogenesis, neurological development, growth, and subsequent pediatric progress.<sup>2</sup> Gabapentin (GBP), with the trade name Neurontin, is a new anticonvulsant drug that was introduced by Park Davis Company in 1993 and approved by the US Food and Drug Administration for epilepsy.<sup>3</sup> This AED is indicated for adjunctive use in individuals older than 12 years for the treatment of partial seizures, with or without becoming secondarily generalized.<sup>4,5</sup> In addition to its use in the therapy of epilepsy, this drug is administered for relief of neuropathic pain and prophylaxis of migraine.<sup>4-8</sup> Lack of appreciable metabolism, no drug interaction, rapid glomerular filtration rate, and good tolerance of this drug are reasons for its extensive usage.<sup>9</sup> Low molecular weight (171D) and no binding to the plasma proteins are the probable causes of passing across the placental membrane.<sup>10</sup> Ohman et al<sup>11</sup> studied the pharmacokinetics of GBP during delivery, lactation, and in the neonatal period, and reported an active transplacental transport of GBP, with accumulation in the fetus as an important consequence. However, despite expanding data on the usage of GBP, there is little information on its teratogenic effects. The first studies did not report any significant teratogenic effects of this drug on rodents.<sup>12,13</sup> Some studies on rodents have shown that oral consumption of this drug (1000-3000 mg/Kg per day) causes delayed ossification of several bones in the skull, vertebral column, upper, and lower limbs during the organogenesis period.<sup>13</sup> Another report has shown that consumption of GBP during pregnancy can cause hydronephrosis and hydroureter in rat fetuses.<sup>3,13</sup> One case of a more severe malformation, holoprosencephaly, following consumption of GBP, and carbamazepine in humans has been reported.<sup>14</sup> In a previous study,<sup>15</sup> we reported that intraperitoneal injection of GBP (1400-1800 mg/day) in pregnant Balb/C mice lead to severe malformations, such as neural tube defects (NTD), and limb deformities during gastrulation and neurulation (G1-G10). Montouris' study<sup>16</sup> on human fetuses showed that GBP exposure during pregnancy was not associated with an increased risk for adverse maternal and fetal events, and Crawford<sup>17</sup> suggested that the 2 newer AEDs (GBP and Lamotrigine) appear to be less harmful to the fetuses when compared to the rest. Therefore, in this study, the teratogenic effects of GBA administration at 2 doses during implantation, neurulation, and the organogenesis stages of pregnancy have been evaluated. Accordingly, the objectives of the present study were: 1) evaluate GBP-induced murine fetotoxicity at different dose levels (25-50 mg/kg), on fetal body weight, and fetal resorption; 2) describe the gross malformations that occur after GBP administration with the above dosage levels; and 3) assess the teratogenic effects of

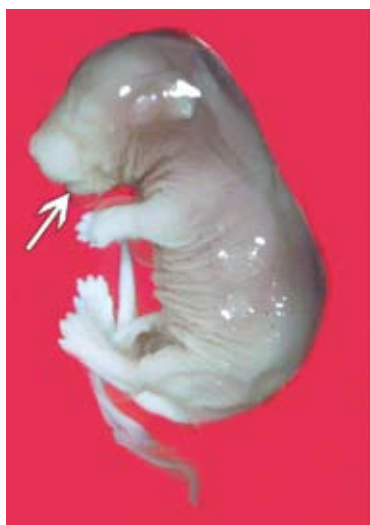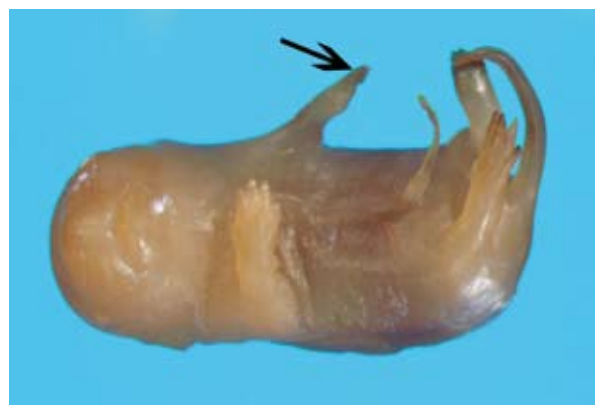
GBP on the skeletal system using Alizarin red S-Alcian blue double staining.

**Methods.** This study was carried out in Birjand University of Medical Sciences during 2008. Virgin female Balb/c mice, weighing 28-30 gram (8-9 weeks old) were used in this experimental study. The animals were maintained in a climate-controlled room under a 12-hour alternating light/dark cycle (9.00-21.00 h light), 20.1-21.2°C temperatures, and 50-55.5% relative humidity. Dry food pellets and water were provided ad libitum. After 2 weeks of acclimation to the diet and the environment, 2 females were caged with a male of the same strain overnight. The presence of vaginal plug the following morning confirmed that mating had taken place and was designated as Gestation Day 0 (GD0). Maternal weights were measured throughout the experiment. The approval for this study was gained from the Birjand University of Medical Sciences Animal Care and Ethics Committee. Thirty pregnant mice were randomly divided into 3 groups: 2 experimental groups that received 25 mg/kg (I) and 50 mg/kg (II) of GBP intraperitoneally for the first 15 days of pregnancy, and one control group that received normal saline on the same days. These doses of GBP were the routine doses used for the treatment of patients in a clinical setting. The GBP powder was obtained from 100 mg capsules (Pharma Science, Montreal, Canada). Dilution was carried out by normal saline. Injection dosages for mice were calculated according to previous studies.<sup>15,16</sup> Cesarean section was performed under deep anesthesia on GD18. Embryos were collected carefully from the uteri and external observation was carried out by a stereo research microscope (SZX, Olympus, Tokyo, Japan). Fetuses were assessed as either alive or dead and exteriorized uterine horns were inspected for fetal resorption. Then, each fetus was weighed by a sensitive electronic balance. All live fetuses were measured and examined externally for gross malformations or deviations from normal growth. Fetuses with skeletal malformations were chosen for double staining. They were kept in 95% ethanol for 3 days and then double stained by Alizarin red S-Alcian blue according to a slightly modified McLeod<sup>18</sup> and Kimmel & Trammel technique<sup>19</sup> for skeletal malformations. Malformations were detected, and photography performed.

Each fetus was weighed, and data were reported as mean  $\pm$  SD. Tukey test was carried out after ANOVA among the control groups and each treated group. With regards to the frequency of absorbed fetuses, external malformation differences between the control groups and each treated group was tested with the  $\chi^2$  test. The unit of frequency analysis was fetuses. All analysis carried out with SPSS software (version 11.5). Differences were considered significant at  $p < 0.05$ .

**Table 1** - Cesarean section parameters and external malformations in Balb/c mice fetuses treated with gabapentin at doses of 25 & 50 mg/kg (control group received normal saline).

Parameters	Treated groups		Control group (normal saline)
	25 mg/kg gabapentin	50 mg/kg gabapentin	
Litters (n)	10	10	10
Total number of fetuses (n)	124	118	131
Live fetuses, n (%)	115 (93), $p=0.67$	103 (87), $p=0.45$	131 (100)
Absorbed fetuses, n (%)	9 (7), $p=0.00$	15 (13), $p=0.00$	0
Fetal weight, Mean $\pm$ SD (gM)	0.98 $\pm$ 0.06, $p=0.00$	0.91 $\pm$ 0.05, $p=0.00$	1.17 $\pm$ 0.03
Fetuses examined (n)	115	103	131
Brachygnathia, n (%)	12 (10), $p=0.00$	15 (14), $p=0.00$	0
Limbs deformities, n (%)	11 (9), $p=0.00$	14 (13), $p=0.00$	0
Vertebral deformity, n (%)	5 (4), $p=0.01$	10 (9), $p=0.00$	0
Exencephaly, n (%)	3 (2), $p=0.06$	4 (4), $p=0.02$	0
Severe malformation, n (%)	2 (2), $p=0.13$	3 (3), $p=0.49$	0

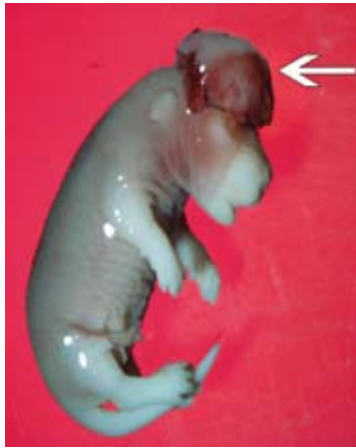**Figure 1** - A fetus with hypognathia (white arrow) from experimental group II, treated with 50 mg/kg/day gabapentin.**Figure 2** - A fetus with limb deformities from experimental group II, treated with 50 mg/kg/day gabapentin.

**Results.** The frequency of total number of fetuses, live fetuses, their weights, and resorbed fetuses, in experimental groups I and II, and the control group is summarized in Table 1. No significant differences were observed in mean number of live fetuses among the different studied groups. Significant dose-dependent fetal resorption was observed, and a dose-dependent weight reduction of treated fetuses was also observed (Table 1). Brachygnathia, deformities in vertebral column and limbs, exencephaly, and also fetuses with severe malformations were observed in experimental groups I and II (Table 1). Brachygnathia was the most prominent malformation in both treated groups. Our result showed that approximately 10% of fetuses in

group I and 14% of fetuses in group II had a significantly smaller mandible. In these fetuses, the snout was narrow and pointed due to the small mandible (Figure 1). Limb anomalies were the second prevalent deformity that was observed among the fetuses of the experimental groups. These deformities included malrotation and delayed development in upper and lower limbs that appeared as micromelia (Figure 2). Nine percent of fetuses in group I, and 13% in group II had limbs deformities. The third prevalent anomaly was vertebral column deformity, which was determined as deviations in normal curvatures. Our results showed that 4% of fetuses in group I, and 9% in group II had this malformation (Table 1). A number of fetuses in experimental groups I (2%) and

**Table 2** - Skeletal malformations in Balb/c mice fetuses treated with gabapentin at doses of 25 & 50 mg/kg (control group received normal saline).

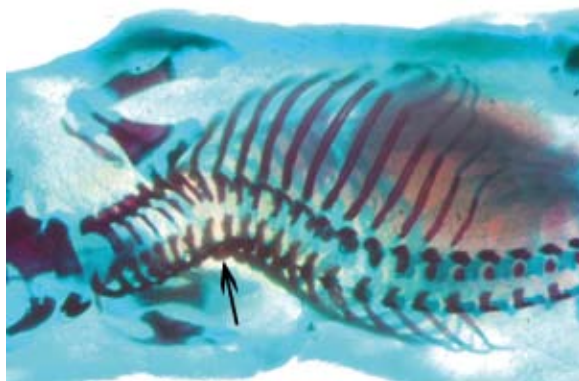Parameters	Treated groups		Control group (normal saline)
	25 mg/kg gabapentin	50 mg/kg gabapentin	
Litters (n)	10	10	10
Fetuses examined (n)	115	103	131
Mandibular hypoplasia, n (%)	12 (10), $p=0.00$	15 (14), $p=0.00$	0
Vertebral column deformity, n (%)	5 (3), $p=0.01$	10 (9.7), $p=0.00$	0
Calvaria deformities, n (%)	15 (13), $p=0.00$	20 (19), $p=0.00$	0
Delayed ossification, n (%)	20 (17), $p=0.00$	27 (26), $p=0.00$	0



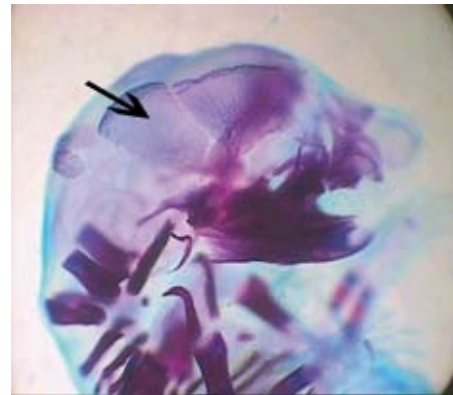
**Figure 3** - A fetus with exencephaly (white arrow) from experimental group II, treated with 50 mg/kg/day gabapentin.



**Figure 4** - A fetus skeleton with mandibular hypoplasia (black arrow) from experimental group II, treated with 50 mg/kg/day gabapentin, which has been stained with Alizarin red S-Alcian blue.



**Figure 5** - A fetus skeleton with scoliosis from experimental group II, treated with 50 mg/kg/day gabapentin, which has been stained with Alizarin red S-Alcian blue.



**Figure 6** - A fetus skeleton with calvaria deformities from experimental group II, treated with 50 mg/kg/day gabapentin.

II (4%) showed exencephaly, and this was significant in group II. In these fetuses, the bones of calvaria did not develop and the brain was exposed and was in contact with the amniotic fluid (Figure 3). Severe malformations were observed in the trunks of fetuses in experimental group I (2%) and group 2 (3%). It was hardly possible to determine different parts of these trunks, and the

trunk was very small and pale. A difference of this malformation was statistically significant only between experimental group II and the control group (Table 1). Mandibular hypoplasia, malformations of vertebrae, and bones of calvaria, and delayed ossification were skeletal anomalies observed following Alizarin red S and Alcian blue double staining (Table 2). Significant mandibular



hypoplasia was observed in both treated groups (Figure 4). Significant vertebrae malformations including deformities in normal route of vertebral column such as scoliosis were observed in both treated groups (Figure 5). As shown in Figure 6, significant defects of calvaria were more obvious in frontal and parietal bones, which appeared as overlapping and defects in formation of these bones (13% in group I, and 19% in group II). Significant delayed ossification was obvious in metacarpus and metatarsals bones. Primary ossification centers in these bones and phalanges did not appear. Density of compact bones of forearm and leg decreased and calvaria also showed delayed ossification.

**Discussion.** This investigation showed that injection of GBP at doses of 25 mg/kg and 50 mg/kg doses comparable to doses in patients using GBP, during the implantation, neurulation, and organogenesis stages can cause reduction of fetus weight, increasing fetus resorption, brachygnathia, vertebral column deformity, limbs anomalies, exencephaly, severe trunk malformations, mandibular hypoplasia, malformations of calvaria, and delayed ossification. These findings are in contradiction to the observations by Petrere and Anderson.<sup>12</sup> They studied the teratogenic effects of GBP in mice with different doses of 500 up to 3,000 mg/kg on gestational days 6-15 and concluded that GBP exposure during pregnancy was not associated with an increased risk for adverse maternal and fetal events. This contradiction might be related to the different mice strains that were used in their study.

In this study, a significant increase in resorbed fetuses was observed in the experimental groups as compared with the fetuses in the control group. Similar findings have been reported by Afshar and Gosalipour,<sup>15</sup> after injection of GBP intraperitoneally in doses of 1400 mg/day and 1800 mg/day during GD1 to GD 10 in pregnant mice. Prakash et al<sup>20</sup> injected GBP in doses of 1800 mg/day and 3600 mg/day intraperitoneally in mid GD (7-12) and late GD (13- 17), and also reported similar results. Also, the mean weight of fetuses in the treated groups was significantly less than the control group, similar to the findings of Afshar and Gosalipour.<sup>15</sup> Furthermore, in Prakash et al's study,<sup>20</sup> which in addition to weight, assessed the length of the fetuses, reported that crown-rump decreased significantly in the treated groups receiving GBP in mid and late GDs in comparison with the corresponding control group. In their study, small bodies in the experimental groups were observed.<sup>20</sup> The Neurontin Registry study<sup>16</sup> that was performed on 39 pregnant women who were taking GBP showed that gabapentin exposure does not carry an increased risk of malformation, fetal loss, low birth weight babies, or maternal complications. Brachygnathia was the most

prevalent observed anomaly in fetuses of experimental groups I and II. This finding was also similar to Prakash et al's study.<sup>20</sup> In our study, bone double staining showed that brachygnathia was due to mandibular hypoplasia (Table 2). Another observed macroscopic malformation in the treated groups was limb defects that appeared as abnormal growth and malrotation limbs. Such anomalies have been reported by Prakash et al,<sup>20</sup> and Afshar and Gosalipour.<sup>15</sup> Therefore, the present study confirms that relative GBP exposure can produce limbs anomalies. Deformities in vertebrae were another anomaly that appeared as abnormal curvatures along the vertebral column like scoliosis. Deviation in the vertebral column has been reported in a previous study.<sup>12</sup> In Prakash et al's study, shortening of the neck has been reported.<sup>20</sup> Severe trunk malformations were the other observed anomaly. Very small bodies, albino, and abundant malformations in different parts of the trunk were characteristics of these malformed fetuses. This malformation has not been reported in previous studies of other AED's. However, despite the low frequency of this anomaly, this is a significant observation that needs to be further investigated. The latest gross malformation observed was exencephaly, and was found in both treated groups, only the difference between experimental group II and the control group was significant.

Anomalies of calvaria were the most common skeletal anomalies observed in this study. Defects of the calvaria were more obvious in the frontal and parietal bones, and appeared as overlapping defects in the formation of these bones. This finding has not been reported in previous studies. In macroscopic studies of the fetal skeleton, delayed ossification was observed and appeared predominantly in the metacarpus and metatarsal bones. Long bones in the forearm and leg also showed a decrease in the density of compact bone tissue. Primary ossification centers did not appear in these bones and phalanges. The calvaria also showed delayed ossification. In a study, in which GBP has been administered orally in doses of 1000-3000 mg/day during the organogenesis period, delayed ossification was observed in calvaria, vertebrae, humerus, and forearm bones, similar to our findings.<sup>10</sup>

The exact mechanism or mechanisms of the teratogenic effects of GBP are not yet clear, and need further investigation. However, alterations in GABA neurotransmitter concentration may be an important factor in probable teratogenic mechanisms.<sup>21</sup> As GBP has structural similarities with GABA, (in fact, it is an analog of GABA), hence, it is possible that GBP's teratogenic effects, especially producing NTD, may be related to changes in GABA concentration or influence on GABA metabolism.

In conclusion, our study was limited by the animal model and the 2 doses of GBP used. According to our findings, GBP may have potential teratogenic effects similar to other AEDs, however with less intensity than other drugs. Therefore, it is suggested that great caution be used when prescribing this drug during the early stages of pregnancy. Furthermore, more detailed studies, by different routes of administration and more emphasis on mechanistic studies need to be performed.

**Acknowledgment.** *This article is part of findings related to a joint project between Gorgan and Birjand Universities of Medical Sciences (code 282). Hence, the authors thank both Universities for the financial support. Special thanks to Miss Lotfi for assistance in the animal house and Mr. Khorashadzadeh for photographing.*

## References

- Porter RJ, Meldrum BS. Antiseizure Drugs. In: Katzung BG, editor. Basic & Clinical Pharmacology. 10th ed. Norwalk (CN): Appleton and Lange; 2007. p. 374-394.
- Lowe SA. Drugs in pregnancy. Anticonvulsants and drugs for neurological disease. *Best Pract Res Clin Obstet Gynaecol* 2001; 15: 863-876.
- Gabapentin as add-on therapy in refractory partial epilepsy: a double-blind, placebo-controlled, parallel-group study. The US Gabapentin Study Group No. 5. *Neurology* 1993; 43: 2292-2298.
- Bergey GK, Morris HH, Rosenfeld W, Blume WT, Penovich PE, Morrell MJ, et al. Gabapentin monotherapy: I. An 8-day, double-blind, dose-controlled, multicenter study in hospitalized patients with refractory complex partial or secondarily generalized seizures. *Neurology* 1997; 49: 739-745.
- Beydun A, Fischer J, Labar DR; Gabapentin monotherapy II. A 26 week, double-blind, dose-controlled multicenter study of conversion from polytherapy in outpatients with refractory complex partial or secondarily generalized seizures. *Neurology* 1997; 49: 746-752.
- Backonja M, Beydoun A, Edwards KR, Schwartz SL, Fonseca V, Hes M, et al. Gabapentin for the symptomatic treatment of painful neuropathy in patients with diabetes mellitus: a randomized controlled trial. *JAMA* 1998; 280: 1831-1836.
- Rowbotham M, Harden N, Stacey B, Bernstein P, Magnus-Miller L. Gabapentin for the treatment of postherpetic neuralgia: a randomized controlled trial. *JAMA* 1998; 280: 1837-1842.
- Spira PJ, Beran RG. Australian gabapentin chronic daily headache group. Gabapentin in the prophylaxis of chronic daily headache: a randomized placebo-controlled study. *Neurology* 2003; 61: 1753-1759.
- Tatum WO 4th, Galvez R, Benbadis S, Carrazana E. New antiepileptic drugs: into the new millennium. *Arch Fam Med* 2000; 9: 1135-1141.
- Briggs GG, Freeman RK, Yaffi SJ. Drug in pregnancy and lactation: a reference guide to total and neonatal risk. 8th ed. Philadelphia (PA): Lippincott Williams & Wilkins; 2008. p. 802-803.
- Ohman I, Vitols S, Tomson T. Pharmacokinetics of gabapentin during delivery, in the neonatal period, and lactation: does a fetal accumulation occur during pregnancy? *Epilepsia* 2005; 46: 1621-1624.
- Petrere JA, Anderson JA. Developmental toxicity studies in mice, rats and rabbits with the anticonvulsant gabapentin. *Fundam Appl Toxicol* 1994; 23: 585-589.
- Neurontin product monograph [Internet]. New York: Pfizer; C2008 [cited 2008 Oct 20]. Available from: [http://media.pfizer.com/files/products/uspi\\_neurontin.pdf](http://media.pfizer.com/files/products/uspi_neurontin.pdf).
- Rosa F. Holoprosencephaly and antiepileptic exposures. *Teratology* 1995; 51: 230.
- Afshar M, Ghalipour MJ. Teratogenic effects of gabapentin on neural tube and development in mice. *Neurosciences* 2008; 13: 321-323.
- Montouris G. Gabapentin exposure in human pregnancy: results from the Gabapentin Pregnancy Registry. *Epilepsy Behav* 2003; 4: 310-317.
- Crawford P. Best practice guidelines for the management of women with epilepsy. *Epilepsia* 2005; 46 Suppl 9: 117-124. Review.
- McLeod MJ. Differential staining of cartilage and bone in whole mouse fetuses by alcian blue and alizarin red S. *Teratology* 1980; 22: 299-301.
- Kimmel CA, Trammell C. A rapid procedure for routine double staining of cartilage and bone in fetal and adult animals. *Stain Technol* 1981; 56: 271-273.
- Prakash, Prabhu LV, Rai R, Pai MM, Yadav SK, Madhyastha S, et al. Teratogenic effects of the anticonvulsant gabapentin in mice. *Singapore Med J* 2008; 49: 49-53.
- Briner W. The effect of GABA receptor ligands in experimental spina bifida occulta. *BMC Pharmacol* 2001; 1: 2.

## NEW PEER REVIEWERS

Join our team of expert peer reviewers for the Neurosciences Journal by sending an enquiry and summarized CV to [info@smj.org.sa](mailto:info@smj.org.sa). Note that NSJ reviewers, whose reviews are returned on time and are judged satisfactory by the Editors, may receive 1 CME credit per review, with a maximum of 5 credits per year, from the Saudi Council for Health Specialties.