

# Outcomes of Human Leukocyte Antigen–Matched Allogeneic Cultivated Limbal Epithelial Transplantation in Aniridia-Associated Keratopathy—A Single-Center Retrospective Analysis

Joséphine Behaegel, MD, PhD,\*† Marie-José Tassignon, MD, PhD,\*† Neil Lagali, PhD,‡  
Alejandra Consejo, PhD,§ Carina Koppen, MD, PhD,\*† and Sorcha Ní Dhubhghaill, MD, PhD\*†

**Purpose:** To assess the efficacy and safety of human leukocyte antigen–matched allogeneic cultivated limbal epithelial stem cell grafts in the treatment of aniridia-associated keratopathy (AAK).

**Methods:** Six eyes of 6 patients with severe AAK received an allogeneic stem cell graft between January 2010 and March 2017. Anatomical and functional results were assessed at 6 months, 1 year, 2 years, and the final follow-up visit available. Safety analysis was performed by considering all perioperative and postoperative adverse events and additional surgeries required during the follow-up period.

**Results:** The mean follow-up was 53.6 months (range 24–104 months). In most patients (80%), there was an early improvement of the keratopathy postoperatively, which slowly regressed during longer follow-up. At the final follow-up, 4 of the eyes were graded as failure and 1 eye was graded as partial success. Grading the sixth eye was not possible because of an adverse event. None of the patients maintained a total anatomical success in the long-term. Only 1 patient maintained a modest improvement in best-corrected visual

acuity from hand motion to counting fingers. Four serious adverse events were recorded in 2 patients.

**Conclusions:** Severe AAK remains a challenging condition to manage. Transplantation of allogeneic ex vivo cultivated limbal stem cells may provide a temporary improvement in ocular surface stability, but anatomical and functional results are poor in the long-term. The eyes are prone to adverse events, and any surgical treatment should take this into consideration.

**Key Words:** congenital aniridia, aniridia-associated keratopathy, limbal stem cell deficiency, cultivated limbal epithelial cell transplantation, HLA matching, allo-CLET

(*Cornea* 2022;41:69–77)

Congenital aniridia is a pan-ocular disorder caused by developmental disturbances in different eye structures including the iris, cornea, anterior chamber, lens, retina, and optic nerve.<sup>1–3</sup> The *PAX6* gene is the major gene responsible for ocular development, and mutations in this gene cause this developmental anomaly.<sup>4,5</sup> Although patients with aniridia usually have limited visual acuity from birth, they are susceptible to further visual deterioration during their lifetime due to aniridia-associated keratopathy (AAK).<sup>6</sup> This keratopathy is characterized by peripheral and progressive conjunctivalization of the corneal surface and may eventually lead to severe corneal scarring with chronic irritations and recurrent erosions.<sup>7,8</sup> As such, it is one of the most painful manifestations of congenital aniridia. The precise pathophysiology of AAK is not completely understood but is believed to result from a progressive breakdown of the limbal stem cell niche, leading to limbal stem cell deficiency (LSCD).<sup>9,10</sup> In vivo confocal microscopy studies have demonstrated a correlation between the morphology of the limbal niche structures and the stage of AAK. In early stages, the limbus may have intact niches with functioning stem cells. However, over time, the niche structures gradually degrade and are no longer present in severe AAK.<sup>9</sup>

An increasing prevalence and severity of keratopathy is observed with age, consistent with the progressive nature of the pathology, but clinical manifestations of AAK and the rate of progression vary across individuals.<sup>6,11</sup> Treatment of AAK is also challenging, and the strategies depend on the degree of

Received for publication November 28, 2020; revision received February 8, 2021; accepted February 13, 2021. Published online ahead of print April 22, 2021.

From the \*Ophthalmology, Visual Optics and Visual Rehabilitation, Faculty of Medicine and Health Sciences, University of Antwerp, Antwerp, Belgium; †Department of Ophthalmology, Antwerp University Hospital, Edegem, Belgium; ‡Division of Ophthalmology, Department of Biomedical and Clinical Sciences, Faculty of Medicine, Linköping University, Linköping, Sweden; and §Department of Applied Physics, University of Zaragoza, Zaragoza, Spain.

Supported by the European Union Horizon2020 project ARREST BLINDNESS (grant agreement number 667400); by the European Union Cooperation in Science and Technology (COST) program, through the COST Action CA-18116, ANIRIDIA-NET; and by the “Agentschap voor Innovatie door Wetenschap en Technologie—Toegepast Biomedisch onderzoek” (IWT-TBM, project number: 130270).

The authors have no conflicts of interest to disclose.

Correspondence: Joséphine Behaegel, MD, PhD, Department of Ophthalmology, Antwerp University Hospital, Wilrijkstraat 10 2650, Edegem 2650, Belgium (e-mail: josephinebehaegel@gmail.com).

Copyright © 2021 The Author(s). Published by Wolters Kluwer Health, Inc. This is an open access article distributed under the terms of the Creative Commons Attribution-Non Commercial-No Derivatives License 4.0 (CCBY-NC-ND), where it is permissible to download and share the work provided it is properly cited. The work cannot be changed in any way or used commercially without permission from the journal.

keratopathy. Patients with mild AAK can benefit from supportive ocular treatment including optimal lubrication or autologous serum drops to improve ocular surface quality.<sup>12</sup> Surgical treatments are reserved for severe keratopathy with significant visual impairment.<sup>13</sup> Because AAK is characterized by a dysfunctional limbus, penetrating keratoplasty (PK) alone has a poor prognosis in these eyes, and without properly functioning stem cells, these grafts will always fail in the long-term.<sup>3</sup>

Limbal stem cell grafts aim to restore the limbal function and reconstruct the ocular surface, with the goal of subsequent corneal graft survival. Because of the bilaterality of AAK, the grafts are sourced from allogeneic cadaveric or living-related donors. Grafts can be categorized as direct or cultivated limbal stem cell transplants, and both options require systemic immunosuppression.<sup>14–16</sup> Allogeneic cultivated limbal epithelial transplantation (allo-CLET) is a newer option to address AAK, requiring only a small donor biopsy. Based on the evidence that donor cells are no longer present on the corneal surface beyond 9 months,<sup>17</sup> many authors reduce dose and duration of systemic immunosuppression compared with direct allogeneic tissue grafts. Most direct tissue grafts seem to provide only a temporary improvement in AAK, despite immunosuppressive treatment.<sup>18,19</sup> Matching human leukocyte antigen (HLA) in donor tissue destined for allo-CLET with host antigens has been proposed because it could improve graft survival in vascularized corneas, but its benefit in limbal stem cell grafting is unclear, and the number of studies reporting HLA-matched stem cell grafts in AAK are limited.<sup>20</sup>

In this study, we aimed to report the outcomes of an allogeneic HLA-matched allo-CLET protocol for treatment of severe AAK, by analyzing the anatomical and functional outcomes and by specifically reporting the adverse events that occurred in this group of aniridia patients who received treatment, with a view to avoiding these issues in the future therapeutic attempts.

## MATERIALS AND METHODS

### Study Design and Subjects

This is a retrospective study based on data provided in 2 consecutive prospective clinical trials conducted between 2008 to 2012 and 2015 to 2019, respectively. Both trials were approved by the Antwerp University Hospital Ethical Committee and followed the tenets of the Declaration of Helsinki. Written informed consent for all procedures described in this study was obtained from all participants.

The inclusion criteria for this study were as follows: (1) presence of bilateral congenital AAK grade 3 or 4 preoperatively; the grade of keratopathy was assessed after slit lamp examination using the grading scale of Lagali et al<sup>21</sup>; (2) patients who underwent allogeneic HLA-matched ex vivo CLET, with HLA match of at least 50% on loci HLA-A, HLA-B, and HLA-DR; and (3) patients with a postoperative follow-up of at least 24 months after allo-CLET.

### Treatment Protocol

The culture methods, transplantation techniques, and postoperative management have been described previously.<sup>22</sup> Briefly, a superficial limbal tissue biopsy was harvested from the limbus of a living relative's eye. In cases without an appropriate living-related donor, the limbal tissue was harvested from the donor eye of a multiorgan donor, after HLA matching. The donor cells were cultured on a denuded human amniotic membrane using a standardized xenogeneic-free protocol. After a culture period of 14 days, the graft was transplanted onto the recipient's eye. A secondary amniotic membrane was then placed on top of the graft and sutured to the conjunctiva, serving as a temporary patch.<sup>22</sup> Postoperatively, all patients were prescribed 0.3% ofloxacin drops 4 times per day, 0.1% dexamethasone drops 8 times per day, 20% autologous serum drops 16 times per day, continued for 1 month and then gradually tapered. All drops were preservative free. Patients without contraindications to systemic immunosuppression were placed under oral cyclosporine A 3-mg·kg<sup>-1</sup>·d<sup>-1</sup>, commenced 1 week before transplantation and continued for 2 months thereafter, then tapered down to 25 to 50 mg/d and maintained at this dosage for a period of 1 year.

### Data Collection and Outcome Measures

The data retrieved from the medical records included age and sex of the patient, degree of AAK, best-corrected visual acuity (BCVA), intraocular pressure (IOP), corneal vascularization, corneal haze, epithelial integrity, related and unrelated complications, and follow-up duration. BCVA was recorded using the Snellen eye chart. For the purpose of this analysis, all visual acuity data were converted to logMAR equivalents. Visual acuities of counting fingers (CFs) at 1 m were converted to logMAR 2.00, hand motion (HM) at 1 m to logMAR 2.30, perception of light to logMAR 2.75, and no perception of light to logMAR 3.00.<sup>23,24</sup>

The status of the ocular surface was documented by ocular slit lamp photographs. The effect of treatment over time was evaluated using our previously reported Vascularization, Haze and Integrity (VaHI) clinical image grading scale.<sup>25</sup> The VaHI is available in an open-access platform for assessing clinical photographs of the corneal surface in patients with LSCD; it also enables evaluation of clinical images over time and reduces assessment bias.<sup>25</sup> Using this tool, which has shown a high intergrader reliability,<sup>25</sup> 4 corneal specialists rated the clinical parameters as corneal neovascularization and haze, ranging from 0 (no haze and/or no vascularization) to 39 (severe haze and/or vascularization). Integrity could not be assessed using the tool because photographs under cobalt blue light were not included in the protocol of the previous trial. Therefore, clinical charts were reviewed to assess the clinical findings after fluorescein instillation (documentation on presence/absence of epithelial defects or epithelial staining).

Total anatomical success was defined as an intact corneal epithelium without central 8-mm superficial neovascularization, as assessed using the VaHI clinical image grading tool.<sup>25</sup> Partial anatomical success was defined as a relapsed corneal superficial neovascularization, not as extensive as at the time of admission, without central 4-mm

neovascularization and an intact epithelial layer. Anatomical failure was defined as recurrent significant epithelial defects or superficial corneal neovascularization encroaching on the central 4 mm of the cornea.

We considered an adverse event any unexpected and unintended experience, sign, symptom, or disease that occurred during surgical procedure or during the postoperative follow-up course. All adverse events either reported spontaneously by the subject or observed by the investigating clinician were recorded. Each adverse event was assessed to its seriousness and its causality (whether or not considered related to the transplanted graft). An adverse event was termed related if it was assessed that the event was a response to the cultivated allograft. Adverse events that occurred secondary to epithelial instability were considered as related to the allo-CLET. An adverse event was classified as serious when it led to the need for major surgical intervention, permanent or significant vision loss, in-patient hospitalization, or systemic infection due to pathogen transmission.

### Statistical Analysis

Intraclass reliability was evaluated with the intraclass correlation coefficient (ICC). A 1-way repeated measures analysis of variance (ANOVA) test was used to evaluate the effect of time on BCVA.

The Pearson  $\chi^2$  test was applied to evaluate the independence of anatomical results from time. In addition, Cramér V ( $\phi_c$ ) was used to assess the level of association between the variables anatomical output and time. Cramér V is a measure of association between 2 nominal variables, based on the Pearson  $\chi^2$  statistic;  $\phi_c$  can reach a value from 0 (no association) to 1 (complete association).

To assess whether haze and vascularization were correlated, the Pearson coefficient of correlation ( $r$ ) was calculated. Because of the small sample size, no statistical test could be performed to evaluate the effect of time on vascularization and haze. Instead, the individual results were plotted graphically.

## RESULTS

Between 2010 and 2017, 6 patients with bilateral congenital aniridia received allogeneic HLA-matched cultivated limbal stem cell transplantation for the treatment of severe keratopathy. None of the patients had bilateral treatment. Patient demographics are listed in Table 1. The mean age at time of transplantation was 38.2 years (range 21–77 years; SD 21.7). Patient 6 was lost to follow-up 3 months postoperatively. The length of follow-up of the remaining patients ranged from 24 to 104 months, with a mean follow-up of 53.6 months (SD 38.4).

### Clinical Outcomes

Patient 6 could not be included for clinical outcome assessment because he was lost to follow-up in the early postoperative phase after a serious adverse event. In 4 of the 5 remaining cases, an anatomical improvement was noted

during the initial follow-up period. At 6 months, 3 of the 5 patients were graded as a total success, 1 as a partial success and 1 as a failure. By the 2-year follow-up visit, 3 grafts had failed, 1 was graded as partial success, and 1 patient was graded as a total success (Fig. 1). This latter patient had received a PK 1 year post-allo-CLET, which remained stable during the first postoperative year. However, during the further follow-up course, a gradual increase in haze was noted. The graft eventually decompensated because of a combination of both endothelial failure and graft rejection. The patient required a second PK, 3 years after his previous PK. This latter graft showed a relative rapid increase of haze and vascularization, resulting in a failure. His postoperative course is illustrated in Figure 2. All post-operative outcome data are presented in Table 1.

The results indicate a trend to poor anatomical outcome over time, as illustrated in Figure 3. However, the null hypothesis (anatomical outcome and time are dependent of one another) was rejected [ $\chi^2 = 6.4$  (df = 6, N = 20);  $P = 0.38$ ]. Association between anatomical outcome and time was found to be moderate ( $\phi_c = 0.40$ ).

### Functional Outcomes

Two patients experienced a modest increase in BCVA from HM to CF during the first postoperative year. By the 2-year visit, only 1 patient retained this visual gain. The BCVA of the remaining patients was similar ( $n = 2$ ) or worse ( $n = 2$ ) compared with baseline findings. Of note, patient 1 experienced an increase in BCVA from HM to 0.2, after 2 subsequent penetrating keratoplasties. However, these outcomes were not sustained, and the visual improvement declined again to pretreatment levels 2 years after his final PK. No statistically significant difference was found in visual acuity with time in the total group (1-way repeated measures ANOVA,  $P = 0.59$ ). The BCVA of patient 6 dropped from perception of light preoperatively to no perception of light at his 3 months postoperative visit. Because longer follow-up data were not available, this patient could not be included in the ANOVA analysis.

### Grading of Vascularization and Haze From Clinical Photography

The 4 graders showed an excellent agreement when evaluating vascularization (ICC = 0.90; 95% confidence interval, 0.88–0.99) and an acceptable agreement when evaluating haze (ICC = 0.70; 95% confidence interval, 0.28–0.87). The graded eyes had a highly variable baseline (pre-allo-CLET) value in vascularization and haze. In 4 of the 5 patients, there was a gradual increase in vascularization over time (Fig. 4). Haze measurements tended to fluctuate less, apart from patient 4 where a clear decrease in haze was noted initially post-CLET, followed by a steady increase (Fig. 4).

Without considering time as a variable and pooling all available images ( $n = 20$ ), the correlation between vascularization and haze was significant ( $r = 0.74$ ,  $P < 0.001$ ). The correlation was significant considering only preoperative images ( $n = 5$ ,  $r = 0.95$ ,  $P = 0.006$ ). Similarly, considering

**TABLE 1.** Overview of the Demographic Data and Postoperative Results of the Enrolled Patients

Patient No.	Age	Sex	Donor Relation	Grade of AAK	Eye	Surgeries Pre-Allo-CLET	Follow-up, mo	Visual Acuity					Anatomical Result				Surgeries Post Allo-CLET
								Pre-Allo-CLET	6 mo Post-Allo-CLET	12 mo Post-Allo-CLET	24 mo Post-Allo-CLET	Final Follow-up Visit	6 mo Post-Allo-CLET	12 mo Post-Allo-CLET	24 mo Post-Allo-CLET	Final Follow-up Visit	
1	27	M	Father	4	OS	PK (x2), direct LSCT, phaco + IOL	104	0.05	CF	0.05	0.05	CF	Total	Total	Total	Failure	PK (x2), glaucoma drainage device, tube grafting (x3)
2	31	M	Mother	3	OD	Phaco+IOL, trabeculectomy, glaucoma drainage device	86	CF	CF	CF	CF	CF	Total	Failure	Failure	Failure	/
3	21	F	Sister	4	OS	Phaco + IOL, Baerveldt implant	30	HM	HM	HM	HM	PL	Failure	Failure	Failure	Failure	/
4	50	F	MOD	4	OD	Direct LSCT, corneal scraping	24	HM	CF	CF	HM	/*	Total	Partial	Failure	Failure	AMT
5	77	F	Cousin	4	OD	ECCE	24	HM	CF	CF	CF	/*	Partial	Partial	Partial	Partial	/
6	23	M	Father	4	OD	PK	3	PL	NPL†	/	/	/	/	/	/	/	/

\*No further follow-up visits 24 months after allogeneic cultivated limbal epithelial stem cell transplantation.

†Visual acuity at 3 months.

AMT, amnion membrane transplantation; ECCE, extracapsular cataract extraction; LSCT, limbal stem cell transplantation; MOD, multiorgan donor; NPL, no perception of light; phaco + IOL, phacoemulsification + intraocular lens implantation; PL, perception of light.

only the postoperative images ( $n = 15$ ), the correlation between vascularization and haze was significant ( $r = 0.68$ ,  $P = 0.002$ ).

## Safety Results

Five of the 6 eyes presented with 1 or more adverse events during the course of the follow-up study. In total, 15 related and 15 nonrelated adverse events were recorded during the entire follow-up course. Four adverse events were graded as serious. Three patients required unscheduled surgery for treatment of an adverse event. All adverse events are listed in Table 2.

Adverse events related to epithelial instability included corneal epithelial defects, corneal ulcer, and descemetocoele and included 50% of the total events. Retinal detachment, extreme perioperative corneal thinning, corneal ulcer, and descemetocoele were graded as serious adverse events. Epithelial breakdown in a failed graft was the most commonly reported adverse event, occurring over 11 visits in 3 different eyes (patients 1, 2, and 4). In 3 patients, the IOP increased after allo-CLET, requiring treatment (patients 1, 2, and 5). Of these, patient 1 required glaucoma surgery by means of a Baerveldt implant. This latter procedure was complicated by repeated tube exposures, requiring 3 different patch grafts.

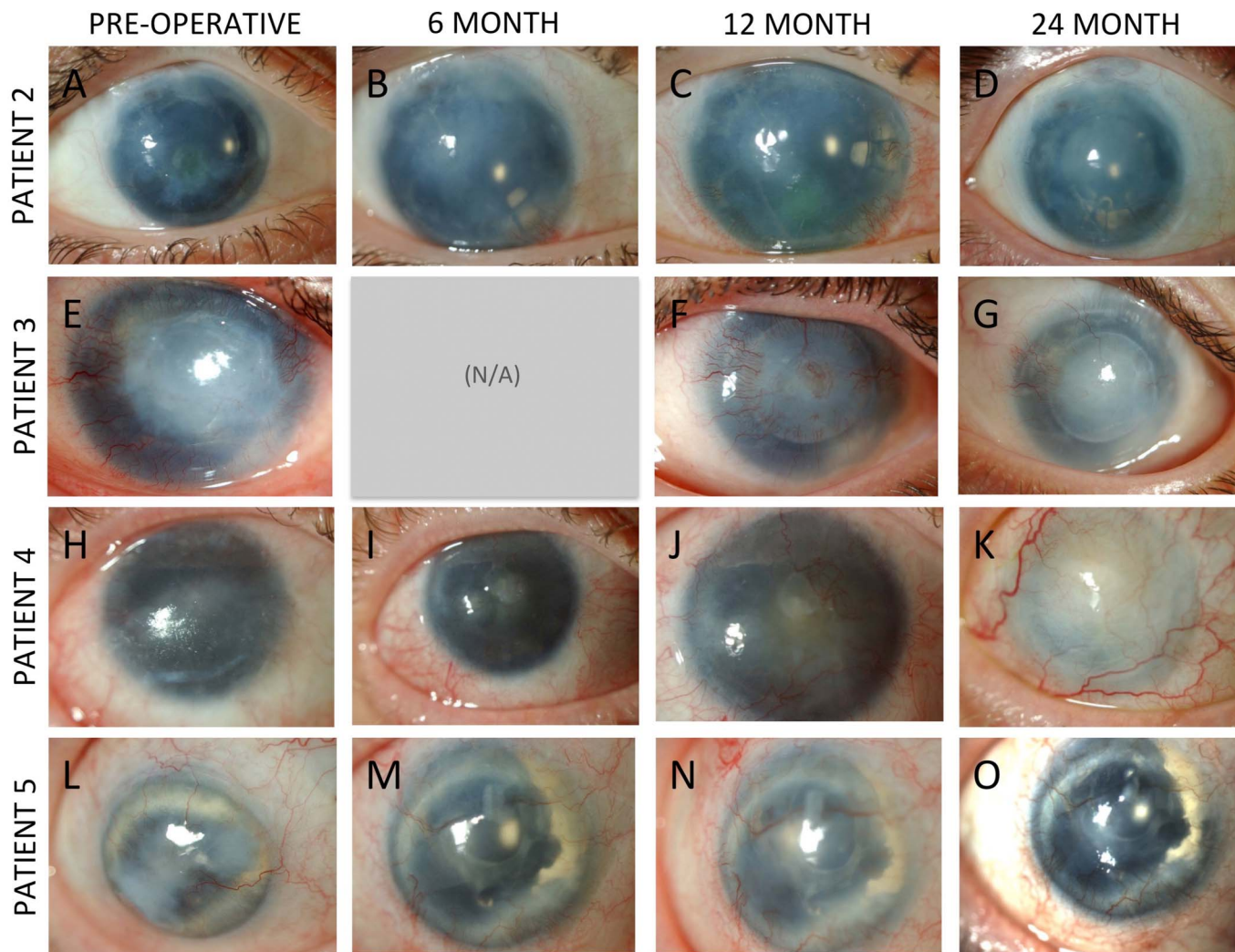
Two patients (patients 4 and 6) experienced a total of 4 serious adverse events. In the latter patient, an intraoperative high IOP and severe corneal thinning was noted after removal of the pannus tissue. The surgeon elected for a combined PK, glaucoma drainage device and allo-CLET procedure, to salvage the eye. The postoperative course was complicated by a retinal detachment 2 weeks postoperatively. An attempt to reattach the retina was unsuccessful. Unfortunately, the patient experienced severe depressive symptoms related to this event and was ultimately lost to follow-up. Patient 4 presented with a large bacterial corneal ulcer 16 months after a successful allo-CLET. The ulcer led to a descemetocoele

formation, and the patient also developed a choroidal effusion a few days after the onset of the descemetocoele, although a perforation could not be identified. Amniotic membrane transplantation was performed to save the globe. Eventually, the cornea conjunctivalized and remained stable thereafter, but functional and anatomical results were very poor.

## DISCUSSION

In this study, we report issues related to the safety and efficacy of HLA-matched allo-CLETs used to treat severe congenital AAK. In most patients, improvement of the keratopathy was observed early in the postoperative period, followed by a gradual recurrence of LSCD signs over time. We observed a reduction in corneal neovascularization early postoperatively but not in corneal haze. In most patients, the clinical improvement did not last longer than 2 years. Only 1 patient was graded as a total success at his 2-year follow-up visit. He was the only patient who had received a PK after the limbal graft. His PK slowly revascularized during the further postoperative follow-up course. It is, however, worth mentioning that this patient had 2 failed PK grafts before the allo-CLET, which is an independent risk factor for graft failure.<sup>26</sup> In 2 of the 5 patients, there was worsening of the keratopathy at the final follow-up, compared with the baseline findings. Both were preceded by the occurrence of adverse events. Most patients experienced a modest improvement in BCVA after allo-CLET, which may be attributable to the superficial keratectomy and early success after CLET grafting; however, over time, the corneal clarity and vision progressively deteriorated along with the appearance of signs of recurrent LSCD, with only 1 patient maintaining a visual gain at the 2-year follow-up.

Our results show an overall higher failure rate with a poorer visual improvement compared with outcomes of direct limbal stem cell grafting, including keratolimbal (KLAL) allografts and living-related conjunctival limbal (lr-CLAL)



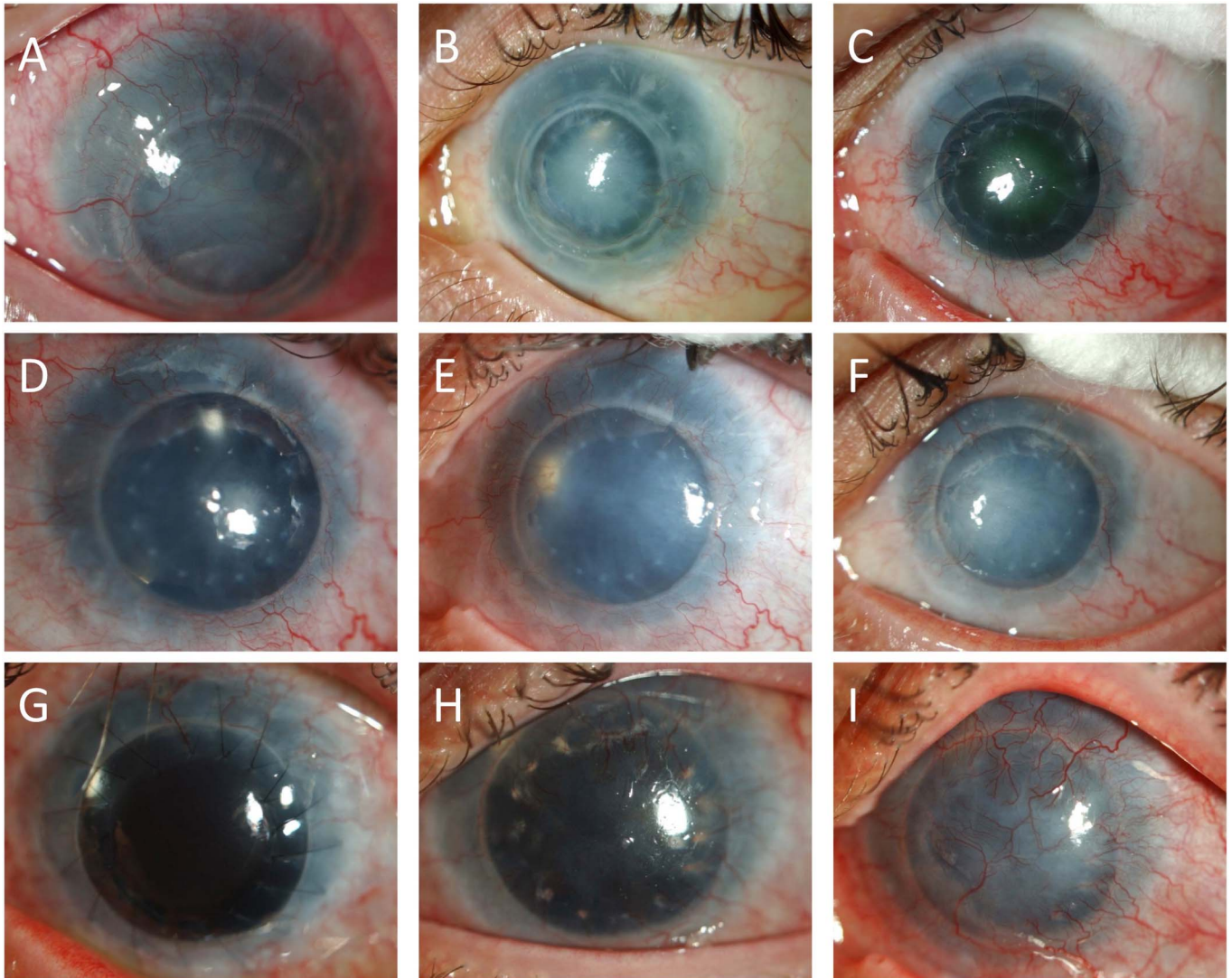
**FIGURE 1.** Anterior segment photographs of 4 patients with grade 3 (patient 2) and grade 4 (patient 3–5) AAK who underwent transplantation. Photographs preoperatively (A, E, H, L), at the 6-month follow-up representing total (B, I) and partial (M) success; at 12 months representing partial success (J, N) and failure (C, F); and at 24 months representing partial success (O) and failure (D, G, K). NA, not available. (The full color version of this figure is available at [www.corneajrnl.com](http://www.corneajrnl.com).)

allografts. A study by Yazdanpanah et al<sup>27</sup> reported that, at a mean follow-up of almost 100 months, 73.7% of 19 patients with AAK grades 2 to 4 had an improved or stable visual acuity after KLAL or Ir-CLAL (including repeat stem cell grafting where necessary) allograft transplantation, whereas 42.3% of the initial stem cell grafts failed or rejected. In that series, 10.5% of cases had grade 2 AAK and the BCVA was better or equal to 0.05 preoperatively in 52.6% of the eyes. In our series, all cases were graded AAK stage 3 to 4, and in 80% of the patients, the BCVA was below 0.05 preoperatively. The less favorable preoperative status of our case series could explain the poorer postoperative results. Treating earlier disease could possibly lead to improved outcomes, although the data we present in this study would discourage us from using this intervention because it stands at an earlier stage. Moreover, the burden of surgery and immunosuppression should be avoided in earlier keratopathy stages with a centrally transparent cornea.

The largest series on limbal allografting in aniridia was recently reported by Cheung et al<sup>28</sup> and included a total of 154 limbal allografts in aniridia. Of these, 124 eyes received a KLAL allograft and 27 eyes were treated with an Ir-CLAL allograft. They reported a stable anatomical long-term outcome in 65.9% of the KLAL group and 81.5% in the Ir-CLAL group. None of the patients in the Ir-CLAL group failed, compared with 15.9% in the KLAL group. Details of the grade of keratopathy (extent of corneal haze and vascularization) and the follow-up time for the aniridia subgroup, however, were not reported. Different to our protocol, they used a stronger and longer systemic immunosuppression regimen. Oral prednisolone was tapered over 1 to 3 months, and both mycophenolate mofetil and tacrolimus were prescribed longer term, whereas the systemic suppressive regimen in our patients consisted of cyclosporine A for a 1-year period only.

Our results were most comparable with the data reported by Shortt et al,<sup>29</sup> who evaluated 3-year outcomes





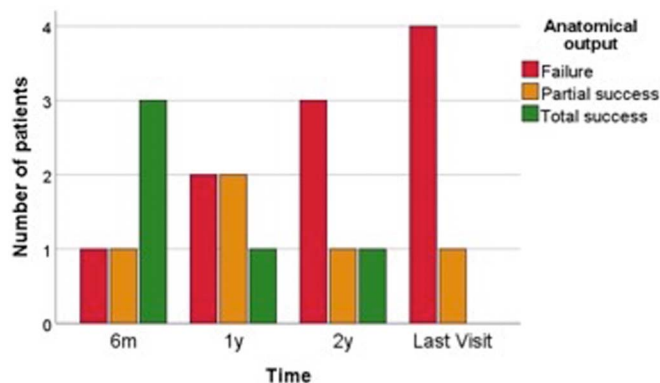
**FIGURE 2.** Anterior segment images of patient 1, representing his postoperative outcomes over an 8-year period in his left eye: preoperative photograph. Note the circular scar delineating the border of previous PK (A); results after allo-CLET at 6 months (B); at 19 months (6 months after PK) (C); at 3 years (D); at 4 years (E); at 5 years (F); at 6 years (2 months after a second PK) (G), at 7 years (H); at 8 years (I). Note the gradual increase of haze/vascularization after the first PK (D–F) and the failure of the second PK (H–I). (The full color version of this figure is available at [www.corneajnl.com](http://www.corneajnl.com).)

after allo-CLET in 10 eyes with aniridia-related LSCD. A temporary improvement in clinical signs was reported up to 12 months after surgery, with a progressive deterioration thereafter. Contrary to our findings, however, they reported a higher visual gain with a persistent visual benefit at 36 months in 30% of their patients.

Discrepancies in short-term outcomes between allo-CLET and direct allogeneic limbal grafts may be because of different baseline visual acuity and severity of AAK before surgical intervention and different immunosuppressive treatment regimens and mutation-dependent differences in AAK aggressivity.<sup>21</sup> The success rates of direct stem cell grafts depend on the use of long-term systemic immunosuppression,<sup>15</sup> and therefore, long-term and heavier regimens of immunosuppressive agents are administered. In allo-CLET,

the use of lifelong immunosuppressive agents is not considered beneficial because donor cells are no longer present beyond 9 months.<sup>17</sup> Although this evidence also seems to obviate the need for immunotyping in allo-CLET, we believe that, similar to all other forms of allogeneic transplantation, HLA matching must play a role in reducing rejection. The Cincinnati Protocol reported by Cheung et al<sup>30</sup> describes a preoperative screening algorithm before considering KLAL or lr-CLAL, which when combined with triple immunosuppression can lead to improved ocular surface stability rates.

We also observed a high number of adverse events in this case series. Breakdown of epithelial integrity was the most frequently observed adverse event, illustrating the poor integration of the grafts in these patients. Four serious events occurred in 2 of the 6 transplanted patients, requiring



**FIGURE 3.** Bar chart indicating the number of the 5 patients that had their anatomical outcome graded as total success, partial success, or failure in each time point evaluated. (The full color version of this figure is available at [www.corneajrnl.com](http://www.corneajrnl.com).)

unscheduled surgery. In only 1 of the transplanted eyes, no complications occurred during the entire observation period. However, this eye showed an early graft failure with a quick revascularization postoperatively. Although clinical results were poor, the eye remained stable until the final follow-up visit. Compared with autologous CLET where the number of reported complications is low,<sup>31</sup> the seriousness and frequency of the adverse events in allogeneic cases can be high, particularly in eyes with AAK.

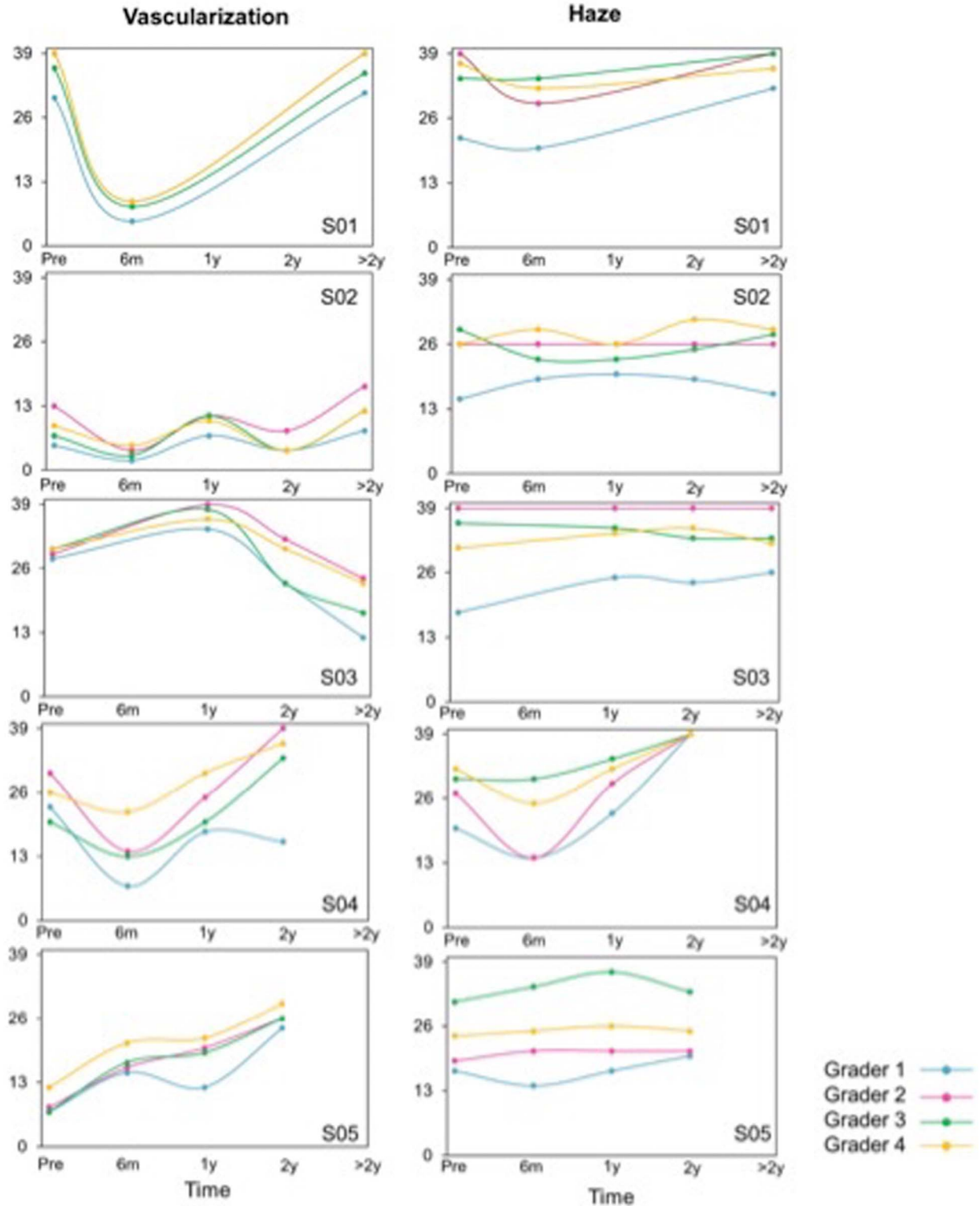
We hypothesize different reasons for our observed poor results in this study. First, AAK is more than LSCD alone. Lagali et al<sup>32</sup> suggested that corneas of aniridia patients are in an immune activated state, even at a very young age, which may be associated with limbal stem cell niche breakdown. Neither this altered immune activated state nor the niche degradation is addressed by CLET grafting alone, and both could be related to early graft failure. Compared with CLET, direct limbal stem cell grafting might provide additional support by providing a larger amount of niche structures, but it would not address the immune status. It has also been shown that a severe corneal nerve deficit exists in aniridia, present in the central and limbal regions.<sup>9,21,32</sup> Not only does the epithelial integrity and stability depend on neurotrophic factors, but the stem cell niche also derives trophic support from corneal nerves.<sup>33,34</sup> In addition, the presence of meibomian gland dysfunction and a reduced tear production, commonly observed in aniridia,<sup>35</sup> may exacerbate the severity of the AAK and impede healing and integration of the cells after transplantation. Furthermore, visual improvement is limited by the preexisting comorbidities such as foveal hypoplasia and glaucoma. Moreover, any type of intraocular surgery carries a risk for complications and a progression of the keratopathy in patients with congenital aniridia. Although stem cell grafting is offered to improve the ocular surface, it could potentially provoke further keratopathy in the long-term. In this case series, all patients had received one or more types of ocular surgery before their CLET, thus increasing their risk for progression of keratopathy and contributing to chronic inflammation of the ocular surface. Other reasons for

the poor results include the presence of comorbidities such as glaucoma requiring medical or surgical therapy, and subsequently compromising ocular surface health, and nystagmus that causes constant friction on the vulnerable graft layer. Finally, a gradual loss of the transplanted cells over time and/or rejection of the allogeneic transplanted cells are also a likely reason for early failure, leading us to consider and question the systemic immunosuppressive therapy given in this study. The maintenance of a stable epithelium observed in the study group of Cheung et al<sup>28</sup> might be related to the strong immunosuppressive treatment regimen used. Cyclosporine A as used in this study for a period of 1 year does not seem sufficient to stave off rejection, and the use of a triple agent regimen could possibly be an approach to extend the survival of allo-CLET grafts.

This study had several limitations, including the size of the study population, the retrospective study design, and the differences in follow-up time among the patients. Because of the rarity of the pathology and the paucity of the centers offering allo-CLET and HLA matching, however, it is unlikely that future studies will include large series or randomized designs. Although clinical diagnosis of LSCD and graft failure was evident, a further drawback of the study was the lack of confirmatory diagnostic tests for LSCD such as *in vivo* confocal microscopy and impression cytology.

Severe AAK remains a challenging condition to manage. Cultivated stem cell grafting provides only a temporary or minimal improvement and is often complicated by occurrence of (serious) adverse events. A viable surgical alternative to limbal stem cell grafting includes the Boston keratoprosthesis, which has been reported to give good results in the short-term. However, functional success rates decline over time, and occurrence of severe postoperative complications are not uncommon.<sup>36</sup> Any consideration of surgery must be evaluated very carefully in aniridia patients. To date, it is still difficult to find therapeutic strategies that lead to long-term clinical benefits. Development of new and improved treatment strategies will require a better understanding of the underlying pathophysiology and ideally avoid the need for ocular surgery. But, even with surgery, strategies aimed at supporting the transplanted cells (eg, addressing nerve deficits, treating ocular surface inflammation, or reducing proangiogenic factors) could potentially lead to improved outcomes by ensuring the best chance for the graft to survive. The use of a stronger immunosuppressive regimen is likely critical to optimize outcomes in these patients. In addition, the use of autologous serum and amnion membrane transplantation may improve ocular surface health and offer support to the transplanted cells.<sup>12,37</sup> Antivascular endothelial growth factor and nerve growth factor could be interesting in the future,<sup>38,39</sup> by functioning in a more targeted way. Moreover, efforts in therapies targeting the molecular and genetic basis of the disease might provide a more sustainable treatment for these patients in the future.

Finally, we should also point out the patient perspectives during management of severe AAK. Clinical outcomes such as improvement in BCVA from HM to CF or reduced vascularization do not capture the impact of the surgery on the patient's quality of life. The absolute amount of benefit



**FIGURE 4.** Vascularization and haze scores evaluated in time with the VaHI grading tool for 5 patients (S01–S05) by 4 independent graders. (The full color version of this figure is available at [www.corneajrnl.com](http://www.corneajrnl.com).)

after extensive treatment is small, and we could, therefore, question whether surgery is warranted at all in these patients with advanced AAK. The overall poor results in AAK might

also question the ethics of recruiting a living-related donor for HLA-matched allo-CLET. Both donor and recipient should be fully informed about the risks, benefits, and prognosis



**TABLE 2.** Related and Unrelated Adverse Events After the HLA-Matched Allo-CLET Procedures

Adverse Event	No. of Events (in No. of Subjects)
Assessed as related to CLET	
Corneal epithelial defect	11 (3)
Corneal ulcer*	1 (1)
Descemetocele*	1 (1)
Extreme corneal thinning perioperative*	1 (1)
Assessed as unrelated to CLET	
Elevated IOP	
Requiring topical treatment	4 (2)
Requiring glaucoma surgery	1 (1)
Stromal oedema	2 (2)
Adenoviral conjunctivitis	1 (1)
Conjunctival hemorrhage	1 (1)
Exposure of Baerveldt tube	4 (1)
Choroidal effusion	1 (1)
Retinal detachment*	1 (1)

\*Events that were graded as serious.

during the consent process, and expectations need to be reviewed before surgery.<sup>40</sup> The use of patient reported outcome measures should be increasingly evaluated in the future trials to assess whether any temporary benefit in AAK matches expectations.

## REFERENCES

- Nelson LB, Spaeth GL, Nowinski TS, et al. Aniridia. A review. *Surv Ophthalmol.* 1984;28:621–642.
- McCulley T, Mayer K, Dahr SS, et al. Aniridia and optic nerve hypoplasia. *Eye (Lond).* 2005;19:762–764.
- Mayer KL, Nordlund ML, Shwartz GS, et al. Keratopathy in congenital aniridia. *Ocul Surf.* 2003;1:74–79.
- Graw J. Genetic aspects of embryonic eye development in vertebrates. *Dev Genet.* 1996;197:181–197.
- Landsend ES, Utheim ØA, Pedersen HR, et al. The genetics of congenital aniridia—a guide for the ophthalmologist. *Surv Ophthalmol.* 2017;63:105–113.
- Eden U, Riise R, Tornqvist K. Corneal involvement in congenital aniridia. *Cornea.* 2010;29:1096–1102.
- Nishida K, Kinoshita S, Ohashi Y, et al. Ocular surface abnormalities in aniridia. *Am J Ophthalmol.* 1995;120:368–375.
- Ihnatko R, Eden U, Fagerholm P, et al. Congenital aniridia and the ocular surface. *Ocul Surf.* 2016;14:196–206.
- Lagali N, Eden U, Utheim TP, et al. In vivo morphology of the limbal palisades of vogt correlates with progressive stem cell deficiency in aniridia-related keratopathy. *Invest Ophthalmol Vis Sci.* 2013;54:5333–5342.
- Eden U, Fagerholm P, Danyali R, et al. Pathologic epithelial and anterior corneal nerve morphology in early-stage congenital aniridic keratopathy. *Ophthalmology.* 2012;119:1803–1810.
- Ramaesh K, Ramaesh T, Dutton GN, et al. Evolving concepts on the pathogenic mechanisms of aniridia related keratopathy. *Int J Biochem Cell Biol.* 2005;37:547–557.
- López-García J, Rivas L, García-Lozano I, et al. Autologous serum eyedrops in the treatment of aniridic keratopathy. *Ophthalmology.* 2008;115:262–267.
- Seitz B, Käsmann-Kellner B, Viestenz A. Stage-related therapy of congenital aniridia [in German]. *Ophthalmologie.* 2014;111:1164–1171.
- Espana E, Di Pascuale M, Grueterich M, et al. Keratolimbic allograft in corneal reconstruction. *Eye (Lond).* 2004;18:406–417.
- Holland EJ, Djalilian AR, Schwartz GS. Management of aniridic keratopathy with keratolimbic allograft: a limbal stem cell transplantation technique. *Ophthalmology.* 2003;110:125–130.
- Eslani M, Haq Z, Movahedan A, et al. Late acute rejection after allograft limbal stem cell transplantation: evidence for long-term donor survival. *Cornea.* 2017;36:26–31.
- Daya SM, Watson A, Sharpe JR, et al. Outcomes and DNA analysis of ex vivo expanded stem cell allograft for ocular surface reconstruction. *Ophthalmology.* 2005;112:470–477.
- Solomon A, Ellies P, Anderson DF, et al. Long-term outcome of keratolimbic allograft with or without penetrating keratoplasty for total limbal stem. *Ophthalmology.* 2002;109:1159–1166.
- de la Paz MF, Alvarez de Toledo J, Barraquer RI, et al. Long-term visual prognosis of corneal and ocular surface surgery in patients with congenital aniridia. *Acta Ophthalmol.* 2008;86:735–740.
- Behaegel J, Dhuhghaill SN, Koppen C, et al. Safety of cultivated limbal epithelial stem cell transplantation for human corneal regeneration. *Stem Cells Int.* 2017;2017:6978253.
- Lagali N, Wowra B, Fries FN, et al. PAX6 mutational status determines aniridia-associated keratopathy phenotype. *Ophthalmology.* 2019;127:273–275.
- Zakaria N, Koppen C, Van Tendeloo V, et al. Standardized limbal epithelial stem cell graft generation and transplantation. *Tissue Eng Part C Methods.* 2010;16:921–927.
- Schulze-Bonsel K, Feltgen N, Burau H, et al. Visual acuities “hand motion” and “counting fingers” can be quantified with the Freiburg Visual Acuity Test. *Invest Ophthalmol Vis Sci.* 2006;47:1236–1240.
- Lange C, Feltgen N, Junker B, et al. Resolving the clinical acuity categories “hand motion” and “counting fingers” using the Freiburg Visual Acuity Test (FrACT). *Graefes Arch Clin Exp Ophthalmol.* 2009;247:137–142.
- Behaegel J, Consejo A, Wouters K, et al. Development and validation of an open-source grading tool for outcome assessment in limbal stem cell. *Cornea.* 2020;39:787–792.
- Barraquer RI, Pareja-Aricò L, Gómez-Benlloch A, et al. Risk factors for graft failure after penetrating keratoplasty. *Medicine (Baltimore).* 2019;98:e15274.
- Yazdanpanah G, Bohm KJ, Hassan OM, et al. Management of congenital aniridia-associated keratopathy: long-term outcomes from a tertiary referral center. *Am J Ophthalmol.* 2019;210:8–18.
- Cheung AY, Eslani M, Kurji KH, et al. Long-term outcomes of living-related conjunctival limbal allograft compared with keratolimbic allograft in patients with limbal stem cell deficiency. *Cornea.* 2020;39:980–985.
- Shortt AJ, Bunce C, Levis HJ, et al. Three-year outcomes of cultured limbal epithelial allografts in aniridia and Stevens-Johnson syndrome evaluated using the Clinical Outcome Assessment in Surgical Trials assessment tool. *Stem Cells Transl Med.* 2014;3:265–275.
- Cheung AY, Sarnicola E, Kurji KH, et al. Cincinnati protocol for preoperative screening and donor selection for ocular surface stem cell transplantation. *Cornea.* 2018;37:1192–1197.
- Le Q, Chauhan T, Yung M, et al. Outcomes of limbal stem cell transplant: a meta-analysis. *JAMA Ophthalmol.* 2020;138:660–670.
- Lagali N, Wowra B, Norbert F, et al. Early phenotypic features of aniridia-associated keratopathy and association with PAX6 coding mutations. *Ocul Surf.* 2020;18:130–140.
- Ueno H, Ferrari G, Hattori T, et al. Dependence of corneal stem/progenitor cells on ocular surface innervation. *Cornea.* 2012;53:867–872.
- Kolli S, Ghareeb AE, Kurzawa-Akanbi M, et al. The role of nerve growth factor in maintaining and the limbal stem cell phenotype. *Stem Cells.* 2019;37:139–149.
- Landsend EC, Pedersen HR, Utheim ØA, et al. Meibomian gland dysfunction and keratopathy are associated with dry eye disease in aniridia. *Br J Ophthalmol.* 2018;139:119–124.
- Shah KJ, Cheung AY, Holland EJ. Intermediate-term and long-term outcomes with the Boston type 1 keratoprosthesis in aniridia. *Cornea.* 2018;37:11–14.
- López-García J, Rivas L, García-Lozano I. Moderate limbal deficiency in patients with congenital aniridia treated with amniotic membrane transplantation. *Arch Soc Esp Ophthalmol.* 2005;80:517–523.
- Lapid-Gortzak R, Santana NTY, Nieuwendaal C, et al. Topical bevacizumab treatment in aniridia. *Int Ophthalmol.* 2018;38:1741–1746.
- Gong N, Pleyer U, Vogt K, et al. Local overexpression of nerve growth factor in rat corneal transplants improves allograft survival. *Invest Ophthalmol Vis Sci.* 2007;48:1043–1052.
- Behaegel J, Dhuhghaill SN, Draper H. Ethical issues in living-related corneal tissue transplantation. *J Med Ethics.* 2019;45:430–434.