

[CASE REPORT]

Ecuzumab for Severe Thrombotic Microangiopathy Secondary to Surgical Invasive Stress and Bleeding

Yoko Fujita¹, Maho Terashita¹, Masahiko Yazawa¹, Yukitaka Yamasaki², Tomonori Imamura³,
Junichiro Kibayashi⁴, Toshihiro Sawai⁵, Yoshihiko Hidaka^{6,7}, Katsuki Ohtani^{7,8},
Norimitsu Inoue^{6,7} and Yugo Shibagaki¹

Abstract:

Atypical hemolytic uremic syndrome (aHUS) is an extremely rare condition caused by an excessive activation of the complement pathway based on genetic or acquired dysfunctions in complement regulation, leading to thrombotic microangiopathy (TMA). A complement-amplifying condition (CAC) can trigger aHUS occurrence along with complement abnormality. We herein report a case of severe TMA after laparoscopic myomectomy in a healthy woman. This case was eventually diagnosed as complement-mediated TMA secondary to surgical invasive stress as a CAC, with no definitive diagnosis of aHUS despite a genetic test. The patient fully recovered after several ecuzumab administrations.

Key words: atypical hemolytic uremic syndrome, aHUS, complement amplifying condition, thrombotic microangiopathy, TMA, ecuzumab

(Intern Med 59: 93-99, 2020)

(DOI: 10.2169/internalmedicine.3315-19)

Introduction

Atypical hemolytic uremic syndrome (aHUS) is extremely rare with an estimated incidence of only 1-2 cases per million and is a life-threatening form of thrombotic microangiopathy (TMA) (1-3). It used to be classified as TMA, except for thrombotic thrombocytopenic purpura (TTP) and hemolytic uremic syndrome (HUS), until its pathophysiology became clear. Now, an excessive activation of the complement pathway secondary to innate or acquired dysfunction in complement regulation has been demonstrated to play a pivotal role in aHUS. Furthermore, aHUS is known to be activated by several conditions, including complement-amplifying condition (CAC) along with intrinsic complement abnormality. CAC includes infection, pregnancy, malignant hypertension, surgery, and allergic reactions (4-6).

Therefore, the terminal complement inhibitor ecuzumab is the principal treatment choice for aHUS (7) and similar conditions related to complement activation that cause TMA.

We herein report a case of life-threatening TMA after laparoscopic myomectomy and bleeding from the surgical site in a healthy woman that was eventually diagnosed as complement-mediated TMA secondary to surgical invasive stress as a CAC, with no definitive diagnosis of aHUS despite a genetic test. Following treatment with ecuzumab, the patient fully recovered from a dialysis-dependent acute kidney injury and was discharged from the intensive-care unit (ICU) with no further need for intubation/mechanical ventilation. We also discuss the implications of genetic testing, withdrawal of ecuzumab administration, and the future perspective of this patient in terms of care.

¹Division of Nephrology and Hypertension, Department of Internal Medicine, St. Marianna University School of Medicine, Japan, ²Department of Infectious Disease, St. Marianna University School of Medicine, Japan, ³Department of Emergency and Critical Care Medicine, Tokyo Metropolitan Police Hospital, Japan, ⁴Department of Obstetrics and Gynecology, Yokohama General Hospital, Japan, ⁵Department of Pediatrics, Shiga University of Medical Science, Japan, ⁶Department of Molecular Genetics, Wakayama Medical University, Japan, ⁷The Japanese Association for Complement Research, Japan and ⁸Department of Food and Health Sciences, Rakuno Gakuen University, Japan

Received for publication May 9, 2019; Accepted for publication July 30, 2019

Correspondence to Dr. Masahiko Yazawa, masahikoyazawa@gmail.com

Case Report

A 30-year-old woman was admitted to the gynecological department of a different hospital to undergo elective surgery for myoma. She did not have symptoms such as diarrhea or purpura nor a personal/family medical history of illness or allergies, nor was she using any medication, although she was a current smoker. She underwent laparoscopic myomectomy with no intraoperative complications. However, she noted a lower abdominal swelling the night after the surgery; therefore, intra-abdominal bleeding was suspected.

Contrast-enhanced computed tomography (CT) was performed, and bleeding from the surgical site was identified. Re-operation for hemostasis was promptly initiated, and approximately 1.9 L of bleeding in the retro-peritoneal space was found. Fortunately, she did not enter hypovolemic shock or a life-threatening condition. However, even after re-operation, her hemoglobin (Hb) level decreased from 12.8 g/dL to 8.4 g/dL, and oliguria and hypoxia followed. She was urgently moved to the ICU for continuous treatment of this emergent condition.

From the day after her surgery, the Hb level steadily decreased to 6.2 g/dL, the platelet count decreased from 300,000/ μ L to 53,000/ μ L, and the D-dimer level notably increased. At that time, her former physician suspected disseminated intravascular coagulation (DIC) secondary to bleeding as the diagnosis for the hematologic abnormality and started transfusions of red blood cells (RBCs), platelets, and fresh-frozen plasma (FFP). However, the transfusion-dependent anemia and thrombocytopenia did not resolve despite the lack of further bleeding. Furthermore, total bilirubin and lactate dehydrogenase (LDH) increased to 2.3 mg/dL and 4,719 U/L, respectively, and the serum creatinine (sCr) level sharply increased to 7.15 mg/dL concomitantly with oliguria. On post-operative day (POD) 5, the patient was intubated and supported by mechanical ventilation due to respiratory failure suspected to have been provoked by a volume overload secondary to oliguria. The physician therefore decided to initiate continuous renal replacement therapy (CRRT). Finally, the patient was diagnosed with thrombotic microangiopathy (TMA) based on laboratory findings, including a low haptoglobin value and the appearance of fragmented RBCs, an extremely low platelet count, and severe renal dysfunction.

On POD 8, the transfusion-dependent hemolytic anemia and thrombocytopenia persisted, and the urine volume was still insufficient. While plasma exchange (PE) was performed for possible TTP, eculizumab was sequentially administered for possible aHUS. The LDH level notably decreased after PE and further decreased after the first administration of eculizumab, and the kidney function and urine volume recovered enough that the intermittent hemodialysis could be stopped. The Hb and platelet levels also increased. Her laboratory results were normal for a disintegrin-like and

metalloproteinase with thrombospondin type 1 motifs 13 (ADAMTS13) inhibitor, negative for Shiga-toxin-producing *Escherichia coli* (STEC) infection in stool culture, and negative for anti-*Escherichia coli* O157 lipopolysaccharide (LPS) antibodies. Based on these findings, the possibility of TTP and STEC-HUS was excluded. Antinuclear antibody tests, blood culture results, direct coombs test, and anti-platelet antibodies were all negative. She had no history of pregnancy nor organ/bone marrow transplantation and no history of drug usage that may have led to TTP before TMA occurred, all of which ruled out a secondary cause of TMA, leading to a clinical diagnosis of aHUS.

Although a genetic test was not performed, the physician decided to continue the administration of eculizumab for the clinical diagnosis of aHUS. Due to newly onset high blood pressure, the patient started taking amlodipine. Because of the continuous fever, vaccination for meningococcus was postponed, and amoxicillin was administered prophylactically. She was transferred to our hospital to determine whether or not eculizumab should be continued and to discover the cause of the fever. The clinical course and laboratory data are shown in Figure, Table 1, and Table 2.

TMA had almost disappeared at the time of the transfer, and the sCr level had decreased to 3.77 mg/dL without any uremic symptoms. We performed examinations to determine the cause of the fever, such as endocarditis, viral infection, abscess formation, collagen disease, and malignancy, through performing blood tests, cultures, and diagnostic imaging. However, thrombosis was found at the right femoral vein just before the inferior vena cava where a dialysis catheter had been placed approximately two weeks earlier. We therefore hypothesized that the fever had been caused by thrombosis or eculizumab, and eventually the fever gradually alleviated without treatment.

Furthermore, we also investigated un-tested causes of acute kidney injury, such as anti-neutrophil cytoplasmic antibodies (ANCA)-associated glomerulonephritis and anti-glomerular basement membrane (GBM) glomerulonephritis. Myeloperoxidase-ANCA (MPO-ANCA), proteinase-3-ANCA (PR3-ANCA), and GBM antibody were all negative. During the investigation, we did not discover new findings that would exclude or further support the aHUS diagnosis. Since we ultimately planned the long-term administration of eculizumab, we promptly vaccinated the patient for *Meningococcus* and administered intravenous ceftriaxone until one week after the vaccination. On POD 33, the sCr, Hb, and platelet levels reached the baseline levels, and fragmented RBCs completely disappeared, while LDH and T-Bil returned to normal. After administering eculizumab 4 times (900 mg weekly), she was discharged on POD 43 with a plan to continue eculizumab administration as an outpatient. We administered 1,200 mg of eculizumab biweekly, and she went back to her daily life under close observation. However, she was admitted with *Salmonella* bacteremia on POD 252. Fortunately, she was able to fully recover without a recurrence of TMA by the administration of levofloxacin.

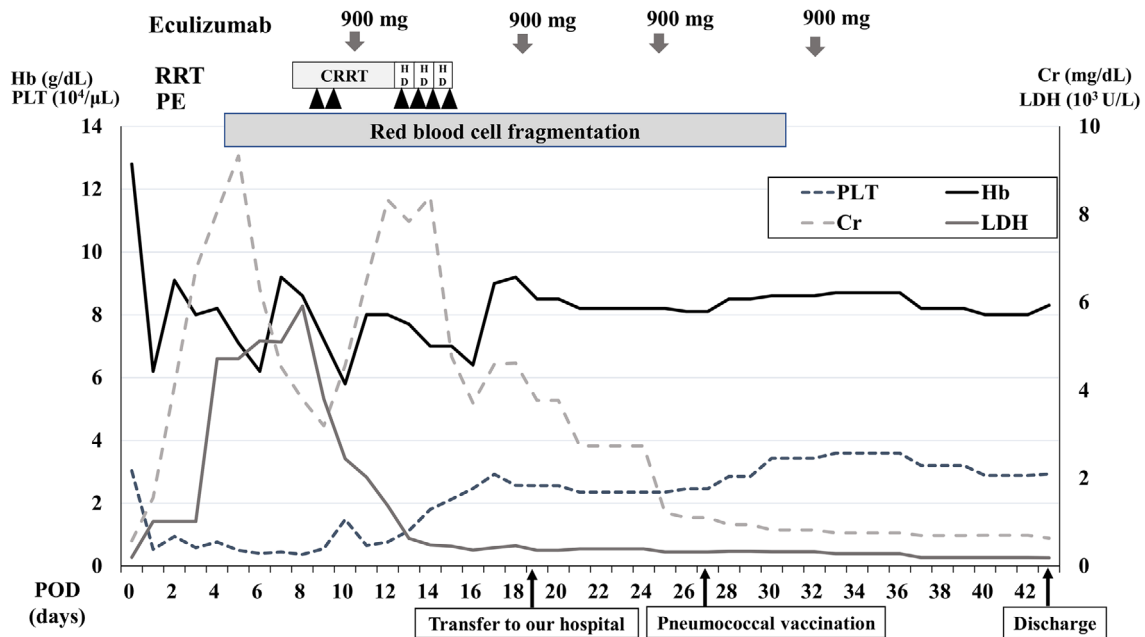


Figure. Clinical course of the present case. RRT: renal replacement therapy, PE: plasma exchange, CRRT: continuous renal replacement therapy, HD: hemodialysis, POD: post-operative day, Cr: creatinine, LDH: lactate dehydrogenase, PLT: platelet, Hb: hemoglobin

Eventually, we performed a genetic test, which revealed minor variations in complement factor H (CFH) (Y1058H, V1060L) and C3 (H16Q). The former variations are known to cause aHUS in western countries; however, this result did not lead to a definitive diagnosis because these variations have a relatively high prevalence in Japan (approximately 2.7% in V1060L). The H16Q variation was not identified as a cause of aHUS. This case was therefore eventually clinically diagnosed as complement-mediated TMA secondary to surgical invasive stress as a CAC, without a definitive genetic diagnosis of aHUS.

We discontinued eculizumab on POD 245, counting 17 administrations from the beginning of the treatment, because the genetic test was unlikely to provide a definitive diagnosis of aHUS and *Salmonella* bacteremia occurred during eculizumab treatment. Furthermore, the patient expressed the desire to quit eculizumab as she was concerned it could become financial, physical, and mental burdens. We monitored her for any signs of recurrence using a urine dipstick test once a day as well as monthly or bimonthly clinic visits with blood and urine examinations for hemolytic anemia. The patient was followed up for more than 200 days after discontinuing eculizumab treatment, and TMA never recurred.

Discussion

We herein report a case of immediate post-surgical TMA in an otherwise healthy woman who was eventually diagnosed with aHUS. She completely recovered following comprehensive interventions, including eculizumab therapy. Genetically, no mutations attributable to aHUS were found, and

the patient was clinically diagnosed with aHUS. This case had several implications regarding the cause, onset, genetic diagnosis, possible infectious side effects of eculizumab, and decision for eculizumab discontinuation.

In 2009, Noris et al. distinguished aHUS from HUS, which occurs due to the non-Shiga toxin in 10% of cases (1). Essentially, aHUS was defined as complement-mediated TMA based on abnormal complement activation developed by an abnormal complement regulatory factor by producing C5, which induces inflammation and formation of the membrane attack complex (MAC). Eculizumab inhibits C5 production and differentiation of C5, resulting in a reduced MAC production (7). Interestingly, not everyone with an abnormal complement regulatory factor presents with aHUS (8). The definite abnormal complement regulatory factor can be detected only in 50% of patients with a clinical diagnosis of aHUS (8). In addition, aHUS can be triggered by CACs, such as surgery, infection, pregnancy, and auto-immune diseases (4-6), along with intrinsic complement abnormalities. To our knowledge, there are no data concerning the type of surgery or amount of invasive surgical stress that are associated with CAC.

Two cases have been reported describing a sudden onset of severe TMA soon after heart transplantation (9) and laparoscopic myomectomy (in a Japanese journal) relating to surgery as a CAC. Both of them used aHUS as the diagnosis terminology despite the lack of complementary genetic testing. However, in the clinical setting, results from a genetic test often arrive after a long time, and the early use of eculizumab could save the patient's life in the case of complement-mediated TMA. In fact, various clinical diagnostic algorithms for TMA have been proposed, and many

Table 1. Clinical Course before Operation and throughout Hospitalization.

	Before operation	Day of occurrence of TMA (POD 0)	Day of transfer (POD 19)	Day of discharge (POD 43)
Vital signs				
Body temperature (°C)	N/A	N/A	38.6	36.8
Body weight (kg)	N/A	N/A	47.5	40.6
Blood pressure (mmHg)	N/A	N/A	132/83	105/66
Laboratory data				
White blood cells (count/ μ L)	7,600	15,100	21,400	5,700
Neutrophils (%)	64.4	94.0	91.5	77.5
Eosinophils (%)	1.3	0.0	0.0	0.5
Hemoglobin (g/dL)	12.8	6.2	8.5	8.3
Platelet count (count/ μ L)	303,000	53,000	256,000	293,000
Total bilirubin (mg/dL)	0.4	3.1	0.7	0.5
Indirect-bilirubin (mg/dL)	N/A	2.5	0.6	0.5
AST (IU/L)	22	44	15	20
ALT (IU/L)	17	15	15	35
LDH (U/L)	198	1,013	358	184
Total protein (g/dL)	7.5	5.6	5.7	7.0
Albumin (g/dL)	4.7	3.5	3.0	4.4
BUN (mg/dL)	21	32	38.1	14.6
Creatinine (mg/dL)	0.57	2.27	3.77	0.62
eGFR (mL/min/1.73m ²)	99.9	22.0	12.6	91.1
PT-INR	0.91	1.61	1.25	1.08
APTT (sec)	27.7	50.4	34.1	35.1
D-dimer (μ g/mL)	N/A	184.3	N/A	N/A
Urinary protein (g/g Cr)	N/A	0.42**	0.74	0.21
Proteinuria by dipstick test	–	2+*	+	–
Hematuria by dipstick test [#]	1+	3+*	2+ (non-glomerular hematuria)	–

*Data from POD1, **data from POD3

#We could not distinguish between glomerular hematuria and non-glomerular hematuria

AST: aspartate aminotransferase, ALT: alanine aminotransferase, LDH: *lactate dehydrogenase*, BUN: blood urea nitrogen, eGFR: estimated glomerular filtration, Na: serum sodium, Cl: serum chloride, K: potassium, PT: prothrombin time-international normalized ratio, APTT: activated partial thromboplastin time, FENa: fractional excretion of Na, N/A: not available

permit eculizumab administration for possible aHUS in the very early stage if plasma exchange is not effective and TTP and HUS have been excluded (10, 11). Based on these algorithms, our treatment and diagnostic strategy seemed appropriate, and ultimately the patients' lives were saved without the occurrence of disabilities.

We performed a genetic test and an analysis of complement-related protein two months after the first eculizumab administration to determine the definite diagnosis and ensure continuous eculizumab administration. The results showed CFH variations (Y1058H, V1060L), which are relatively common variants in Japanese patients (approximately 2.7% in V1060L) (12), and a C3 variation (H16Q), which has not been established as a definite cause of aHUS. These were therefore concluded to be non-functional polymorphisms, and a definite genetic diagnosis of aHUS was not established in the present case. Although multiple rounds of eculizumab were administered, the general status of the patient was good, the laboratory results were normal, the serum complement level (CH50) was still at a measurable level (Table 3), and a relatively high level of complement

sC5b-9 complex (MicroVue SC5b-9 Plus Enzyme Immunoassay; Quidel, San Diego, USA) (13) was revealed by an analysis of the complement-related proteins (Table 3). This might suggest that there is still an activated terminal complement complex (TCC), despite eculizumab administration, capable of blocking the complement pathway. In addition, several clinical decisions, regardless of a lack of evidence of gene abnormalities, supported our diagnosis as follows: 1) C3, C4, and CH50 were already below the cut-off levels before plasma exchange and administration of eculizumab (Table 2); 2) we completely excluded other causes of TMA, as typified by TTP and STEC-HUS; and 3) eculizumab effectively decreased disease activity. We therefore finally diagnosed the patient clinically with complement-mediated TMA due to the invasive stress induced by surgery and bleeding as a CAC.

The known side effects of eculizumab include meningococcal infection, for which a warning has been issued by the U.S. Food and Drug Administration (FDA) and the Japanese Ministry of Health, Labor and Welfare. *Meningococcus* is a capsule-forming bacterium that is immunologically elimi-

Table 2. TMA Associated Laboratory Results.

Differential diagnosis for other diseases	Before plasma exchange (From POD 3 to 8)	After transfer (POD 19 and thereafter)
For TTP/STEC-HUS		
ADAMS13 activity (reference range: 0.75–1.5)	0.83	N/A
ADAMS13 antibody	Negative	N/A
Anti- <i>Escherichia coli</i> O157 LPS antibody	Negative	Negative
Stool culture	Shiga toxins: negative	N/A
For collagen disease		
C3 (mg/dL) (standard value: 65–135)	59	75
C4 (mg/dL) (standard value: 13–35)	8	27
CH50: Complement levels (U/mL) (standard value: 30–50)	<7	<10*
Anti-nuclear antibody (standard value: 0–40)	<40	80
Speckled pattern		
Anti-RNP antibody	N/A	Negative
Anti-Sm antibody	N/A	Negative
Anti-Scl-70 antibody	N/A	Negative
For hemolytic anemia		
Direct coombs test	Negative	N/A
Indirect coombs test	Negative	N/A
For infectious Disease		
Blood culture	Negative (once)	Negative (twice)
Urine culture	Negative	Negative
Sputum culture	Negative	Negative
CMV antigen (C10/C11)	N/A	Negative
VZV IgG (EIA) (standard value: 0-2)	N/A	16.7 (+)
VZV IgM (EIA) (standard value: –)	N/A	Negative
Bordetella pertussis DNA	N/A	Negative
HIV antibody	N/A	Negative

ADAMTS13: a disintegrin-like and metalloproteinase with thrombospondin type 1 motifs 13, LPS: lipopolysaccharide, ANA: antinuclear antibody, CMV: cytomegalovirus, VZV: varicella-zoster virus, EIA: enzyme immunoassay, DNA: deoxyribonucleic acid, HIV: human immunodeficiency virus, N/A: not available. *After administration of eculizumab

nated by MAC. Therefore, under the administration of eculizumab, meningococcal infection can cause lethal sepsis or meningitis (14). Of note, *Streptococcus pneumoniae* and *Haemophilus influenzae* type b form capsules and can also result in sepsis. However, these two bacteria have less severe effects if the patient is being treated with eculizumab, as it has been suggested that the bacteria are neutralized by C3 opsonization, which is located upstream of C5 in the complement pathway (15). In the present case, after the 17th eculizumab administration (POD 252), non-typhoidal *Salmonella* bacteremia occurred. Fortunately, it was promptly cured with antibiotics. Some nontyphoidal *Salmonella* form capsules; therefore, attention should be paid to *Salmonella* and meningococcus infections when eculizumab is being administered (16). However, in our case, we identified the O-4 antigen, which implied that these bacteria do not form cap-

sules. Because we were unable to identify the strain, the direct relationship between the *Salmonella* bacteremia and eculizumab was not confirmed in this context. Furthermore, this case underscores the importance of considering all bacterial infections, not just infection with *Meningococcus*.

Although a genetic test was unlikely to provide a definitive diagnosis of aHUS, we carefully stated this patient had a low risk of TMA recurrence. We finally discontinued eculizumab after 17 administrations on POD 245. TMA did not recur for more than 200 days. Because we did not completely eliminate the possibility of TMA recurrence, we informed the patient and her family about the symptoms and the need for access to an emergency hospital. In addition, we asked her to perform a self-test with a urine dipstick daily in order to detect any signs of reoccurrence as soon as possible. As the patient expressed a desire to become preg-

Table 3. Complement Related Protein Analysis Results.

	Serum sample	Plasma sample
sC5b-9 (ng/mL)	1,503.7	369.9
standard value*	148.0 - 1,243.6	37.0 - 260.6
Ba (ng/mL)	1,503.3	503.8
standard value*	419.6 - 1,714.0	275.6 - 685.2
CFH (µg/mL)	386.3	350.0
standard value*	285.9 - 710.7	229.8 - 714.6
CFH-IgG (AU/mL)	1,798.1	1,438.0
standard value*	393.9 - 1,069.0	393.9 - 1,183.0
CFI (µg/mL)	37.3	102.9
standard value*	28.8 - 55.6	72.0 - 139.2
C5a (ng/mL)	10.94	6.80
standard value*	0.50 - 32.33	0.20 - 15.62
C3 (mg/dL)	90.7	79.7
standard value*	60.4 - 143.2	61.3 - 131.7
C4 (mg/dL)	26.2	23.3
standard value*	9.1 - 35.9	8.7 - 33.1
CH50 (U/mL)	9.9	9.9
standard value*	31.7 - 50.5	31.2 - 43.2

CFH: complement factor H, CFI: complement factor I sC5b-9; It shows the amount of terminal complement complex (TCC, MAC). Theoretically, administration of anti-C5 antibody would significantly inhibit sC5b-9 production. Plasma sample would rather be accurate than serum sample since sC5b-9 can be gradually formed in the serum samples.

Ba; It shows the activated status of the alternative complement pathway or amplifying pathway. Theoretically, administration of anti-C5 antibody would not inhibit Ba production. Plasma sample would rather be accurate than serum sample since Factor B can be gradually formed in the serum samples.

CFH; It prompts cleavage of C3b and acts as a complement regulatory factor. It shows the amount of protein in CFH which is one of the causal proteins of aHUS.

CFH-IgG; It shows the amount of autoantibody (anti-CFH antibody) which could inhibit the function of CFH. It is one of the causal factors of aHUS.

CFI; It inhibits complement activation by cleaving C3 and C4b coincident with the existence of cofactor.

C5a; It is produced at the terminal complement pathway. It mediates neutrophils and macrophages to release histamine, and functions to increase the permeability of blood vessels and chemotaxis of white blood cells. Plasma sample would rather be accurate than serum sample since C5a can be gradually formed in the serum samples.

*Each standard value was calculated by The Japanese Association for Complement Research based on the results from $\pm 2SD$ (standard deviation) among the Japanese healthy population (n=24)

C3, C4, sC5b-9, CFH-IgG were obtained with quality control and quality assurance by the International Complement Society

nant in the future, sharing medical information is extremely important for building a system supporting the prompt use of eculizumab, as pregnancy would likely constitute a CAC or carry a high risk of aHUS recurrence (17, 18). Furthermore, the patient and her health care providers will need to pay close attention to her risk of TMA and CAC for the rest of her life.

In conclusion, we encountered a case of life-threatening TMA that appeared to be strongly associated with

complement-mediated TMA, similar to aHUS, and was completely resolved by eculizumab. In such a life-threatening situation, it is advised to establish aHUS as a cause of TMA soon after the occurrence of CAC and administer eculizumab treatment in order to save the patient's life.

The authors state that they have no Conflict of Interest (COI).

Acknowledgement

The authors thank Dr. Jesús María García Fernández and Santiago Rodríguez de Córdoba (Department of Cellular and Molecular Medicine, Center for Biological Research, Madrid, Spain) for providing advice regarding the interpretation of gene variants.

This complement examination was performed by The Japanese Association for Complement Research which was financially supported by Alexion GK and CSL Behring K. K. as company sponsored research.

References

- Noris M, Remuzzi G. Atypical hemolytic-uremic syndrome. *N Engl J Med* **361**: 1676-1687, 2009.
- George JN, Nester CM. Syndromes of thrombotic microangiopathy. *N Engl J Med* **371**: 654-666, 2014.
- Noris M, Caprioli J, Bresin E, et al. Relative role of genetic complement abnormalities in sporadic and familial aHUS and their impact on clinical phenotype. *Clin J Am Soc Nephrol* **5**: 1844-1859, 2010.
- Asif A, Nayer A, Haas CS. Atypical hemolytic uremic syndrome in the setting of complement-amplifying conditions: case reports and a review of the evidence for treatment with eculizumab. *J Nephrol* **30**: 347-362, 2017.
- Riedl M, Fakhouri F, Le Quintrec M, et al. Spectrum of complement-mediated thrombotic microangiopathies: pathogenetic insights identifying novel treatment approaches. *Semin Thromb Hemost* **40**: 444-464, 2014.
- Berger BE. The alternative pathway of complement and the evolving clinical-pathophysiological spectrum of atypical hemolytic uremic syndrome. *Am J Med Sci* **352**: 177-190, 2016.
- Legendre CM, Licht C, Muus P, et al. Terminal complement inhibitor eculizumab in atypical hemolytic-uremic syndrome. *N Engl J Med* **368**: 2169-2181, 2013.
- Nester CM, Thomas CP. Atypical hemolytic uremic syndrome: what is it, how is it diagnosed, and how is it treated? *Hematology American Society of Hematology Education Program* **2012**: 617-625, 2012.
- Kransdorf EP, Kittleson MM, Kobashigawa JA. Atypical hemolytic-uremic syndrome immediately after heart transplantation. *J Heart Lung Transplant* **33**: 664-665, 2014.
- Azoulay E, Knoebl P, Garnacho-Montero J, et al. Expert statements on the standard of care in critically ill adult patients with atypical hemolytic uremic syndrome. *Chest* **152**: 424-434, 2017.
- Afshar-Kharghan V. Atypical hemolytic uremic syndrome. *Hematology American Society of Hematology Education Program* **2016**: 217-225, 2016.
- Matsumoto T, Fan X, Ishikawa E, et al. Analysis of patients with atypical hemolytic uremic syndrome treated at the Mie University Hospital: concentration of C3 p.I1157T mutation. *Int J Hematol* **100**: 437-442, 2014.
- Rinder CS, Rinder HM, Smith BR, et al. Blockade of C5a and C5b-9 generation inhibits leukocyte and platelet activation during extracorporeal circulation. *J Clin Invest* **96**: 1564-1572, 1995.
- Heesterbeek DAC, Angelier ML, Harrison RA, Rooijakkers SHM. Complement and bacterial infections: from molecular mechanisms

- to therapeutic applications. *J Innate Immun* **10**: 455-464, 2018.
- 15.** Winthrop KL, Mariette X, Silva JT, et al. ESCMID Study Group for Infections in Compromised Hosts (ESGICH) Consensus Document on the safety of targeted and biological therapies: an infectious diseases perspective (Soluble immune effector molecules [II]: agents targeting interleukins, immunoglobulins and complement factors). *Clin Microbiol Infect* **24** (Suppl 2): S21-S40, 2018.
- 16.** Marshall JM, Gunn JS. The O-antigen capsule of *Salmonella enterica* serovar typhimurium facilitates serum resistance and surface expression of *FliC*. *Infect Immun* **83**: 3946-3959, 2015.
- 17.** Huerta A, Arjona E, Portoles J, et al. A retrospective study of pregnancy-associated atypical hemolytic uremic syndrome. *Kidney Int* **93**: 450-459, 2018.
- 18.** Macia M, de Alvaro Moreno F, Dutt T, et al. Current evidence on the discontinuation of eculizumab in patients with atypical haemolytic uraemic syndrome. *Clin Kidney J* **10**: 310-319, 2017.

The Internal Medicine is an Open Access journal distributed under the Creative Commons Attribution-NonCommercial-NoDerivatives 4.0 International License. To view the details of this license, please visit (<https://creativecommons.org/licenses/by-nc-nd/4.0/>).