



UNIVERSITÀ DI PARMA

ARCHIVIO DELLA RICERCA

University of Parma Research Repository

First-trimester fetal neurosonography: technique and diagnostic potential

This is the peer reviewed version of the following article:

Original

First-trimester fetal neurosonography: technique and diagnostic potential / Volpe, N; Dall'Asta, A; Di Pasquo, E; Frusca, T; Ghi, T. - In: ULTRASOUND IN OBSTETRICS & GYNECOLOGY. - ISSN 0960-7692. - 57:2(2021), pp. 204-214. [10.1002/uog.23149]

Availability:

This version is available at: 11381/2881605 since: 2020-10-29T16:49:01Z

Publisher:

John Wiley and Sons Ltd

Published

DOI:10.1002/uog.23149

Terms of use:

openAccess

Anyone can freely access the full text of works made available as "Open Access". Works made available

Publisher copyright

(Article begins on next page)



ISUOG

Virtual World Congress
ON ULTRASOUND IN OBSTETRICS
AND GYNECOLOGY

16-18 OCTOBER 2020

3 DAY EVENT

5 streams — **170+** expert talks — **1200+** abstracts

Register to access a high tech virtual space
enabling you to learn and interact with

200+ world leading experts

and global community

● Watch Live OR **▶ On Demand**

Earn CME/CPD points
for attending

Benefit from reduced
registration fees

[Explore scientific program & register here](#)



First-trimester fetal neurosonography: technique and diagnostic potential

N. Volpe¹, A. Dall'Asta¹, E. Di Pasquo¹, T. Frusca¹, T. Ghi¹

¹Department of Medicine and Surgery, Unit of Surgical Sciences, Obstetrics and Gynecology, University of Parma, Parma, Italy

Correspondence:

Prof. Tullio Ghi

Department of Medicine and Surgery, Unit of Surgical Sciences, Obstetrics and Gynecology,
University of Parma, Italy

E-mail: tullioghi@yahoo.com

Running head: Fetal neurosonogram in the first trimester.

Keywords: multiplanar imaging, fetal neurosonogram, brain development, sonoembriology

This article has been accepted for publication and undergone full peer review but has not been through the copyediting, typesetting, pagination and proofreading process which may lead to differences between this version and the Version of Record. Please cite this article as doi: 10.1002/uog.23149

Contribution

What are the novel findings of this work?

With the inclusion of the non-axial planes, a multiplanar neurosonography may be carried out at the end of the first trimester in accordance to the methodology recommended for the midtrimester expert assessment of the fetal brain.

What are the clinical implications of this work?

Expert neurosonography with 2D and 3D US at 1st trimester combined with a deep knowledge of the fetal anatomy and sonoembryology allow to detect the early findings of several brain abnormalities, which are commonly diagnosed later in gestation and whose early diagnosis can be clinically advantageous for the couple. A standardized protocol for first trimester neurosonography including the systematic evaluation of specific markers for structural abnormalities is expected to anticipate the detection of brain anomalies at 11-13 weeks.

Abstract

Most of the brain abnormalities are present in fact also at first trimester but only a few of these are detected at such early stage. According to the current recommendations for the first trimester ultrasound, the fetal head structures that should be visualized are limited to the cranial bones, the midline falx and the choroid-plexus-filled ventricles. Using this basic approach almost all cases of acrania, alobar holoprosencephaly and cephalocele are usually detected, however the majority of the other abnormalities of the fetal central nervous system remain undiagnosed until midtrimester. Such anomalies are potentially detectable if the sonographic study is extended to additional anatomic details which are not currently included in the existing guidelines. The aim of this review article is to describe how to assess the normal fetal brain at first trimester expert multiplanar neurosonography and to demonstrate the early sonographic findings which characterize some major fetal brain abnormalities.

Introduction

Fetal brain abnormalities are among the most common congenital malformations, with a reported prevalence in Europe of about 1 per 1000 babies¹. According to the brain district involved and the type of abnormality, the prognosis is mostly severe, with a substantial impact on both the neurodevelopmental and the cognitive outcome. Prenatal ultrasound sensitivity for central nervous system (CNS) congenital malformations ranges between 68% and 92%^{2,3}, but a comprehensive evaluation and diagnosis of the defect is usually difficult at the standard examination. CNS fetal defects are usually suspected at the screening ultrasound evaluation, although an expert multiplanar examination is required for an accurate diagnosis and classification of each brain anomaly. The multiplanar fetal neurosonogram is usually performed at around 20 weeks' gestation or later, and its methodology has been described by the International Society of Ultrasound in Obstetrics and Gynecology (ISUOG)⁴.

Most of the brain abnormalities are present in fact also at 1st trimester but only a few of these are detected at such early stage^{5,6,7,8,9,10,11,12,13,14}. Following the current ISUOG recommendations for the 1st trimester ultrasound, the fetal head structures that should be visualized are limited to the cranial bones, the midline falx and the choroid-plexus-filled ventricles. Using this basic approach almost all cases of acrania, alobar holoprosencephaly and cephalocele are usually detected^{6,7,8,10,13} while the majority of the other brain abnormalities remain undiagnosed until midtrimester. Low detection rates of brain abnormalities at first trimester could be related to the small size of the fetal brain structures

and also to the fact that for some a later appearance in pregnancy is acknowledged. Moreover, it should also be noted how at first trimester some brain abnormalities do not alter the sonographic aspect of those basic intracranial structures whose examination is suggested at this stage. Most of these anomalies are potentially detectable only if the sonographic study is extended to additional anatomic details which are not currently requested by 1st trimester guidelines. Indeed, only a deep knowledge of the normal sonographic appearance of the fetal brain at 1st trimester allows to recognize the early anatomic modifications which anticipate the typical appearance of major cerebral abnormalities at second trimester, when their sonographic findings are more widely characterized. In some brain malformations such as severe ventriculomegaly, callosal agenesis, cranial posterior fossa anomalies (CPF) and Chiari II anomaly, the sonographic appearance is considerably different at 12 weeks compared with the 2nd trimester and they can be suspected at 1st trimester only if new ultrasonographic landmarks are assessed by an expert eye.

In the most recent years, high-resolution ultrasound machines are giving the opportunity to evaluate the subtle details of fetal anatomy at earlier gestational age and to improve our understanding of the normal and abnormal sonoembryological development of the fetal brain. Studies on the development of the fetal brain during the first weeks of pregnancy have characterized and labelled the developing brain structures using H-thymidine signal¹⁵ on the anatomic specimens. Thanks to these studies a good correlation between high-resolution sonographic images and anatomic findings may be achieved.

The aim of this review article is two-fold: to describe how to assess the normal fetal brain at 1st trimester expert multiplanar sonography and to illustrate the early sonographic findings which characterize some major fetal brain abnormalities.

Accepted Article

Normal Anatomy of the fetal brain in the first trimester

Axial Views

Approaching the 11+0-13+6 weeks fetal brain by axial views, it is possible to evaluate its sonographic appearance on two different anatomical planes: a plane just above the third ventricle and thalami (Figure 1 – supra-thalamic section) and a plane at the level of the thalami (Figure 2 – trans-thalamic section). These two planes are obtained when the ultrasound beam is oriented perpendicularly to the midline echo.

The supra-thalamic view represents the most common scanning plane obtained at first trimester, and allows the evaluation of the interhemispheric fissure (midline echo), the lateral ventricles, containing their choroid plexuses, the rudimentary cortex and the surrounding calvarium.

At this early stage, the calvarium shape, integrity and calcification can be assessed, as the absence of intact cranial bones surrounding the brain can be a sign of acrania or other neural tube defects^{16,17}. The midline echo should be seen as a straight uninterrupted hyperechoic line, dividing the brain in two equal symmetric parts. An interruption of the midline echo should be noted, as it could be suggestive of lobar holoprosencephaly. On both sides of the cerebral midline the two lateral ventricles, almost entirely occupied by their choroid plexus, are visible. The two choroid plexuses are expected to be symmetrical in terms of size, shape and position, with an overall appearance that resembles a butterfly¹⁸. The

rudimentary surrounding cortex seems not to show any fissure or gyri at this stage, with the exception of the mild lateral recess representing the future Sylvian Fissure (Figure 1).

Sweeping more caudally the transducer, the trans-thalamic view is obtained as a slightly oblique head section including the third ventricle, the thalami and the aqueduct of Sylvius (from front to back, Figure 2). On this view only the anterior third of the midline echo is visible, being interrupted posteriorly by the third ventricle. This latter structure appears as a thin anechoic space, between the two thalami. At prenatal US these appear as two separated, symmetrical anechoic ovoid structures, and posterior to them, on the midline, it is possible to visualize the Sylvian aqueduct as an anechoic square-shaped cavity, lined by the anechoic tectum on either side.

Sagittal Views

Since the earlier publications on the clinical usefulness of nuchal translucency in the first trimester screening for fetal chromosomal abnormalities more than 20 years ago^{19,20}, the acquisition of the midsagittal view of the fetal head at 1st trimester has become widely used.

This is actually the only scanning plane where the nuchal translucency thickness can be properly measured, following strict methodological criteria in order to maintain high accuracy, reproducibility and repeatability of the measurement. In order to obtain the midsagittal view of the fetal head at 11 to 13 weeks the ultrasound beam should be aligned to the midsagittal suture at the level of the anterior fontanelle^{4,21}. On this scanning plane, independently of the measurement of the nuchal translucency, a thorough sonographic assessment of the midline cerebral structures can be performed. The diencephalon can be

Accepted Article

visible as a hypoechoic round-shaped structure, followed caudally by the brainstem (BS), which includes the mesencephalon, the pons and the medulla (Figure 3). The BS has a typical “S” shape due to the mesencephalic and pontine flexures. Behind the BS, within the cranial posterior fossa (CPF) it is possible to visualize the 4th ventricle (4thV also named as “intracranial translucency”) and the cisterna magna (CM), forming three parallel anechoic spaces between the sphenoid bone and the occipital one (BS, 4thV and CM)²² (Figure 3). Under normal circumstances the ratio between the BS thickness and its distance to the occipital bone is 0.5-1.0^{23,24}. Above the diencephalon, it is also possible to distinguish the fornix as a thin hyperechoic line, whose cranial extremity is slightly thickened and forms the anterior commissure (Figure 3).

When approaching the fetal head on the midsagittal plane posteriorly through the posterior fontanelle a comprehensive view of the posterior cerebral structures can be obtained. On this view plane the subtle anatomic details of the developing brainstem and posterior fossa can be demonstrated^{15,25,26,27}. The aqueduct of Sylvius and the 4thV can be then visualized as anechoic spaces behind the BS, separated by the isthmus at the level of the mesencephalic flexure (Figure 4). At this stage the aqueduct is larger than in the second trimester, with a size that is similar to that of the 4thV and an elongated shape, and is roofed by the tectum. The 4thV sits behind the BS, mainly within its pontine flexure. The roof of the 4thV is a medullary velum divided in two parts by the choroid plexus of the ventricle, protruding in the middle. Above the plexus, the velum is defined as anterior membranous area (AMA), which is in continuity with the cerebellar vermis at its upper extremity. Below

the choroid plexus, the velum is defined as posterior membranous area (PMA), protruding into the CM as a finger shaped structure, the Blake's pouch.

The sonographic demonstration of some of these structures, their development and measurement have been recently reported^{27,28}.

Coronal Views

Aligning the ultrasound beam perpendicularly to the sagittal suture, a parallel sweep of the probe from the forehead to the occiput allows to obtain in sequence the coronal planes of the fetal brain, namely the frontal, the trans-caudate, the trans-thalamic and the occipital ones (Figure 5).

The frontal view, passing through the frontal horns of the developing lateral ventricles, allows to display the anterior part of the corresponding choroid plexuses on either side of the interhemispheric fissure (Figure 6). Just below the brain, on this plane it is possible to visualize the fetal orbits with the lenses.

On the trans-caudate view the lateral ventricles with their choroid plexuses on either side of the interhemispheric fissure, the ganglionic eminences at the basis of the lateral ventricles and the basal ganglia (including the caudate) below them can be seen. In between the basal ganglia it is possible to visualize the third ventricle(Figure 7).

On the trans-thalamic view the thalami, appearing as round-shaped symmetric structures with low echogenicity are shown. The two lateral ventricles are also visible on this plane.

Between the thalami it is possible to visualize the caudal portion of the third ventricle (Figure 8).

Finally, on the occipital view the posterior horns of the lateral ventricles are depicted together with the aqueduct just below them, on the midline, and the two rudimentary cerebellar hemispheres on either side. The aqueduct appears surrounded by the tectum from above, and by the isthmus from below. It is possible to distinguish two occipital coronal planes, a more anterior one passing through the pons and medulla (Figure 9), and a more posterior one including the 4th ventricle and the medulla below it (Figure 10).

Vascular anatomy at 11-13 weeks

Thanks to the use of new high-sensitive Doppler technologies the visualization of the main fetal cerebral vessels is also feasible at 11-13 weeks^{29,30}. On the sagittal views (Figure 11) it is possible to display the pericallosal arteries with their branches, and the internal carotid artery below it. Few venous structures are also visible, such as the superior sagittal sinus underneath the calvarium, the straight sinus at the level of the cerebellar tentorium, continuing into the vein of Galen anteriorly, and joining the straight sinus into the torcular herophili, posteriorly. When moving to axial views, Doppler imaging allows also to visualize the Willis circle, including anterior, middle and posterior cerebral arteries (Figure 12).

Potentially detectable anomalies at first trimester expert neurosonography

CNS abnormalities involving the structures included in a basic ultrasound examination are often identified at early stages. For acrania, encephalocele and alobar holoprosencephaly a high detection rate has been already reported at the basic ultrasound examination^{6,7,12,16,17,18}. However, an expert evaluation may allow the early description of other major CNS anomalies such as ventriculomegaly, open spina bifida, Dandy-Walker malformation and agenesis of the corpus callosum.

Ventriculomegaly

While the conventional definition of ventriculomegaly in the second trimester refers to a measurement of the atrial diameter equal or greater than 10 mm, the diagnosis of this condition at first trimester is not based on the ventricles width. At the end of the first trimester, when the fluid content of the lateral ventricle is increased, a relative reduction of the choroid plexus size rather than an enlargement of the ventricle will be noted^{31,32} (Figure 13). It has been shown that an increased ratio between the choroid plexus and ventricle areas may anticipate the diagnosis of ventriculomegaly at second trimester US, according to its traditional definition^{31,32}. More specifically, at 11-13 weeks ratios < 5th percentile (pc) between the area (5thpc 0.48-0.36), the length (5thpc 0.66-0.56) and the width (5thpc 0.60-0.54) of these two structures have been reported to predict the diagnosis of ventriculomegaly at midtrimester in 94% and 82% of the cases, respectively³¹. Therefore, although the number of available studies is still limited, it is possible to establish a tentative diagnosis of cerebral ventriculomegaly at first trimester based on the ratios described. According to others the

qualitative observation of hypoplastic choroid plexuses, too small to reach the roof of the ventricles, independently from any quantitative measurement, should raise the suspicion of early onset ventriculomegaly³³ (Figure 13).

Open Spina Bifida (OSB)

An abnormal appearance of the cranial posterior fossa (CPF) at midtrimester has been shown to be associated with open spina bifida in the vast majority of cases. Recent studies have demonstrated that the early cranial indirect findings of spina bifida can be noted on the midsagittal view in the first trimester, when the direct visualization of the spinal defect may be challenging. Actually, among fetuses affected by Chiari II malformation a reduced width of the cisterna magna (CM) can be demonstrated. On the frontal midsagittal view instead of the three symmetrical and parallel black spaces described above (the BS, the 4th V or intracranial translucency and the CM, Figure 3) the prevalence of the BS combined with a thinning of the 4thV and CM, or the absence of a separation between these two latter structures have been described to be fair predictors of OSB^{22,34,23,35}. It has been figured out that due to the caudal displacement of the BS and of the 4thV, the CM is collapsed and is not sonographically visible in the majority of these cases (Figure 14).

Some recent studies have proposed to quantify the ratio among the size of the three CPF structures visible on the midsagittal view, in order to demonstrate objectively the Chiari II malformation and to anticipate the presence of OSB. It has been proven that an increased ratio between the BS and the 4thV/CM complex (BS to Occipital Bone complex, BSOB - Figure 3) is a reliable and reproducible sonographic marker of OSB. More in details, a

BS/BSOB ratio >95th centile between 11 and 13+6 weeks has been found to predict almost all cases of OSB^{23,24,36}, performing better than the qualitative assessment or the measurement of every single structure of the CPF including the BS, BSOB and intracranial translucency.

On axial view also, the presence of abnormal brain findings in fetuses with open spina bifida has been reported at 11-13 weeks of gestation. Due to the leakage of fluid through the foramen magnum, in case of Chiari II anomaly, the amount of fluid in the lower part of the ventricular system is reduced and this sonographic aspect has been described as the “dry brain”³⁷ (Figure 15), with the 3rd ventricle and Sylvian aqueduct barely visible. Moreover, the backwards displacement of the midbrain and aqueduct, which are pushed closer to the occipital bone, has been labelled as “crash sign” (Figure 15). This sonographic sign has been found to herald the presence of OSB in the vast majority of cases and seems to reflect the early shape changes of the brainstem in fetuses with Chiari 2 anomaly^{38,39}. Other authors have proposed to quantify on the axial plane the proximity of the aqueduct to the occipital bone reporting a significant shortening of the distance between these two structures in case of OSB⁴⁰.

Very recently, a multicentre case series has compared the accuracy of all sonographic markers of OSB described on both midsagittal and axial views of the fetal brain at first trimester²⁴. The study has shown that the most accurate predictor of OSB is the BS/BSOB ratio, with an area under the receiver operating characteristics curve of 0.997, and no cases of intact spine with a ratio above 1.

Since the cranial posterior fossa structures can be visualized exactly on the same scanning plane in which the NT is properly measured, the routine evaluation of the posterior fossa seems feasible without any additional effort when performing the routine screening for chromosomal abnormalities at 1st trimester. This extended examination has been demonstrated to improve the early detection of open spina bifida^{6,23,24,36}. In, a recent study including a wide population it has been shown that the detection rate of OSB improved from 15% to about 60% after implementing the routine evaluation of the CPF structures in the anatomic protocol for first trimester ultrasound⁶.

Dandy Walker Malformation (DWM)

Historically the sonographic diagnosis of posterior fossa anomalies and the accurate differentiation between the classic DWM and more common and benign Blake's pouch cyst (BPC) have been considered feasible only after 20 weeks. In the last decade the 1st trimester detection of posterior fossa malformations by expert fetal brain scanning has been independently reported by several research groups^{26,35,41,42,43,28,44,45,46}. On the frontal midsagittal plane in fetuses with DWM or BPC an increased amount of fluid in the 4th ventricle and in the CM with the fusion of these two latter structures has been reported at 11-13 weeks^{35,41,45,46}. Due to the wide communication between the 4th ventricle and the CM others have suggested that in fetuses with cystic anomalies of the posterior fossa only two black parallel spaces instead of three are qualitatively visible on the midsagittal plane^{35,42,47}. A reduced BS/BSOB ratio has been proposed as an early objective marker of posterior fossa

anomaly. A BS/BSOB measurement below the 5th centile at 1st trimester has been shown to anticipate the sonographic appearance of DWM or BPC at mid-gestation in a large proportion of cases, and to witness a posterior fossa anomaly rather than OSB when only two black parallel spaces are visible on the midsagittal plane^{35,41,47} (Figure 16)

The upward displacement of the tentorium cerebelli in respect of its normal insertion on the occipital clivus is among the major criteria to differentiate DWM from BPC in fetuses with abnormal communication between the fourth ventricle and the cisterna magna. Although the antenatal visualization of the position of the tentorium cerebelli is technically challenging especially at 1st trimester, the torcular herophili (TH) which lies at the intersection between the tentorium and the falx cerebri may be sonographically depicted by means of high sensitive Doppler imaging (Figure 11). On this basis the antenatal demonstration of the TH at Doppler imaging has been proposed as a proxy of the insertion of the tentorium on the fetal skull. Some recent studies have suggested that thanks to the visualization of the TH at 1st trimester fetal neuronography the differential diagnosis between the DWM and BPC may be feasible³⁰. On the frontal midsagittal view of the brain in fetuses with abnormal communication between the fourth ventricle and the cisterna magna Volpe et al. have shown that a very small angle between the brainstem and the tentorium (with the straight sinus appearing almost parallel to the BS) may anticipate the appearance of DWM already in the first trimester³⁰.

A research work from our group has shown that the sonographic demonstration of the TH in the second trimester is feasible and may assist in the differential diagnosis between BPC and DWM allows to differentiate fetuses with BPC from those with DWM⁴⁸.

In fetuses with suspected posterior fossa anomalies a detailed sonographic study of the developing cerebellar vermis is feasible on the midsagittal plane only from the posterior fontanel. On this scanning plane the vermis can be visualized and measured⁴⁴. Moreover, additional quantitative and qualitative parameters have been recently proposed, such as the angle formed by the vermis and the pons (ponto-vermian angle) and the appearance of the Sylvian aqueduct. It has been suggested that among fetuses with posterior fossa anomalies the ponto-vermian angle is larger than 100°, being much increased in DWM and, to a lesser extent, in BPC²⁸. Furthermore, at 1st trimester the Sylvian aqueduct might look smaller or larger than normal in case of DWM, or BPC, respectively²⁸.

Agensis of the corpus callosum

On the midsagittal plane of the fetal head, the corpus callosum becomes sonographically detectable after 16-18 weeks^{49,50}. At first trimester it is therefore not possible to suspect a callosal agenesis based on the lack of its direct visualization at grey scale ultrasound. However, some Authors have proposed to look at this stage for some of the indirect signs of callosal absence, which may be visible also at 11 to 13 weeks. In 80% of fetuses with agenesis of corpus callosum diagnosed later in gestation Lachmann et al. demonstrated an increased ratio between the diencephalon diameter (from midbrain to falx, including 3rd ventricle and thalami) and the falx diameter⁵¹ (Figure 17). This sonographic marker seems

to reflect at early gestation the upward displacement and the dilatation of the 3rd ventricle, which is commonly noted at midtrimester in fetuses with absent corpus callosum.

Some independent groups have used 2D and 3D Power Doppler ultrasound to evaluate the presence and the course of the pericallosal arteries at 1st trimester. It has been demonstrated that the visualization of a normal artery is associated to the later appearance of normal corpus callosum in all cases, whereas callosal agenesis was diagnosed at midtrimester when the artery had not been demonstrated at 1st trimester. In accordance with this data the sonographic visualization of the pericallosal artery has been suggested as an indirect but reliable sign to rule out callosal agenesis at first trimester neurosonography^{29,52,53}.

Conclusions

In conclusion, on the the axial planes a “basic” examination of the fetal brain may be performed in accordance with current ISUOG guidelines for 1st trimester ultrasound. Using this approach only the most severe or lethal brain abnormalities can be sonographically picked up at 11 to 13 weeks. With the inclusion of the non-axial planes a multiplanar neurosonography may be carried out at the end of the first trimester, following the methodology recommended for dedicated fetal brain scanning at midtrimester. Expert neurosonography with 2D and 3D US at 1st trimester combined with a deep knowledge of fetal anatomy and sonoembryology allows to detect the early findings of several brain abnormalities, which are commonly diagnosed later in gestation and whose early diagnosis can be clinically advantageous for the couple. This detailed examination of the CNS can be

offered to the couples at high risk for fetal anomalies based on the family history or on the presence of abnormal findings at the basic ultrasound examination. A standardized protocol for first trimester neurosonography including the systematic evaluation of specific markers for structural abnormalities (such as the BS/BSOB measurement) is expected to anticipate the detection of most severe brain anomalies at 11-13 weeks.

Disclosure of interest

The Authors state no financial disclosures nor conflict of interest related to the content of this work.

Funding

There was no funding source for this study.

Acknowledgments

The Authors acknowledge the contribution of Dr Paolo Volpe whose commitment and research activity on the expert assessment of the fetal anatomy in the first trimester has inspired the design of this work.

The anatomic specimens shown in Figures 2, 4, 7, 8, 9 and 10 have been reproduced with permission from the Bayer's and Altman's Atlas of Human Central Nervous System Development, Volume 4 - The human brain during the late first trimester. CRC Press, 2006.

References

1. Morris JK, Wellesley DG, Barisic I, Addor MC, Bergman JEH, Braz P, Cavero-Carbonell C, Draper ES, Gatt M, Haeusler M, Klungsoyr K, Kurinczuk JJ, Lelong N, Luyt K, Lynch C, O'Mahony MT, Mokoroa O, Nelen V, Neville AJ, Pierini A, Randrianaivo H, Rankin J, Rissmann A, Rouget F, Schaub B, Tucker DF, Verellen-Dumoulin C, Wiesel A, Zymak-Zakutnia N, Lanzoni M, Garne E. Epidemiology of congenital cerebral anomalies in Europe: A multicentre, population-based EUROCAT study. *Arch Dis Child*. 2019;104(12):1181-1187.
2. Anderson N, Boswell O, Duff G. Prenatal sonography for the detection of fetal anomalies: Results of a prospective study and comparison with prior series. *Am J Roentgenol*. 1995;165(4):943-50.
3. Bernaschek G, Stuempflen I, Deutinger J. The value of sonographic diagnosis of fetal malformations: Different results between indication-based and screening-based investigations. *Prenat Diagn*. 1994;14(9):807-12.
4. Salomon LJ, Alfirevic Z, Bilardo CM, Chalouhi GE, Ghi T, Kagan KO, Lau TK, Papageorghiou AT, Raine-Fenning NJ, Stirnemann J, Suresh S, Tabor A, Timor-Tritsch IE, Toi A, Yeo G. ISUOG Practice Guidelines: performance of first-trimester fetal ultrasound scan. *Ultrasound Obstet Gynecol* 2013; 41: 102–113
5. Syngelaki A, Chelemen T, Dagklis T, Allan L, Nicolaides KH. Challenges in the diagnosis of fetal non-chromosomal abnormalities at 11-13 weeks. *Prenat Diagn*. 2011;31(1):90-

6. Syngelaki A, Hammami A, Bower S, Zidere V, Akolekar R, Nicolaides KH. Diagnosis of fetal non-chromosomal abnormalities on routine ultrasound examination at 11–13 weeks' gestation. *Ultrasound Obstet Gynecol.* 2019;54(4):468–76
7. Rossi AC, Prefumo F. Accuracy of ultrasonography at 11-14 weeks of gestation for detection of fetal structural anomalies: A systematic review. *Obstet Gynecol.* 2013;122(6):1160–7
8. Rayburn WF, Jolley JA, Simpson LL. Advances in ultrasound imaging for congenital malformations during early gestation. *Birth Defects Res Part A - Clin Mol Teratol.* 2015;103(4):260–8
9. Iliescu D, Tudorache S, Comanescu A, Antsaklis P, Cotarcea S, Novac L, Cernea N, Antsaklis A. Improved detection rate of structural abnormalities in the first trimester using an extended examination protocol. *Ultrasound Obstet Gynecol.* 2013;42(3):300–9
10. Grande M, Arigita M, Borobio V, Jimenez JM, Fernandez S, Borrell A. First-trimester detection of structural abnormalities and the role of aneuploidy markers. *Ultrasound Obstet Gynecol.* 2012;39(2):157–63
11. Bardi F, Smith E, Kuilman M, Snijders RJM, Bilardo CM. Early Detection of Structural Anomalies in a Primary Care Setting in the Netherlands. *Fetal Diagn Ther.* 2019;46(1):12–9

- Accepted Article
12. Karim JN, Roberts NW, Salomon LJ, Papageorghiou AT. Systematic review of first-trimester ultrasound screening for detection of fetal structural anomalies and factors that affect screening performance. *Ultrasound Obstet Gynecol.* 2017;50(4):429–41
 13. Vayna AM, Veduta A, Duta S, Panaitescu AM, Stoica S, Buinoiu N, Nedelea F, Peltecu G.. Diagnosis of fetal structural anomalies at 11 to 14weeks. *J Ultrasound Med.* 2018;37(8):2063-2073
 14. Kenkhuis MJA, Bakker M, Bardi F, Fontanella F, Bakker MK, Fleurke-Rozema JH, Bilardo CM. Effectiveness of 12–13-week scan for early diagnosis of fetal congenital anomalies in the cell-free DNA era. *Ultrasound Obstet Gynecol.* 2018;51(4):463-469.
 15. Bayer S and Altman J, 2006. *The Human Brain During The Late First Trimester.* Boca Raton: CRC Press.
 16. Sepulveda W, Wong AE, Andreeva E, Odegova N, Martinez-Ten P, Meagher S. Sonographic spectrum of first-trimester fetal cephalocele: Review of 35 cases. *Ultrasound Obstet Gynecol.* 2015;46(1):29–33
 17. Cheng CC, Lee FK, Lin HW, Shih JC, Tsai MS. Diagnosis of fetal acrania during the first trimester nuchal translucency screening for Down syndrome. *Int J Gynecol Obstet.* 2003;80(2):139–44
 18. Sepulveda W, Wong AE. First trimester screening for holoprosencephaly with choroid plexus morphology (“butterfly” sign) and biparietal diameter. *Prenat Diagn.*

2013;33(13):1233-7.

19. Nicolaides KH, Azar G, Byrne D, Mansur C, Marks K. Fetal nuchal translucency: Ultrasound screening for chromosomal defects in first trimester of pregnancy. *Br Med J.* 1992;304(6831):867-9.
20. Nicolaides KH, Brizot ML, Snijders RJM. Fetal nuchal translucency: ultrasound screening for fetal trisomy in the first trimester of pregnancy. *ACOG Curr J Rev.* 1995;8(2):42
21. Nicolaides KH, Heath V, Cicero S. Increased fetal nuchal translucency at 11-14 weeks. *Prenat Diagn.* 2002;22(4):308–15
22. Chaoui R, Benoit B, Mitkowska-Wozniak H, Heling KS, Nicolaides KH. Assessment of intracranial translucency (IT) in the detection of spina bifida at the 11-13-week scan. *Ultrasound Obstet Gynecol.* 2009;34(3):249–52
23. Lachmann R, Chaoui R, Moratalla J, Picciarelli G, Nicolaides KH. Posterior brain in fetuses with open spina bifida at 11 to 13 weeks. *Prenat Diagn.* 2011;31(1):103-6.
24. Wertaschnigg D, Ramkrishna J, Ganesan S, Tse C, Scheier M, Volpe N, Ghi T, Meagher S, Rolnik DL. Cranial sonographic markers of fetal open spina bifida at 11 to 13 weeks of gestation. *Prenat Diagn.* 2020;40(3):365-372.
25. Robinson AJ. Inferior vermian hypoplasia - Preconception, misconception. *Ultrasound Obstet Gynecol.* 2014;43(2):123–36

26. Robinson AJ, Goldstein R. The cisterna magna septa: Vestigial remnants of Blake's pouch and a potential new marker for normal development of the rhombencephalon. *J Ultrasound Med.* 2007;26(1):83–95
27. Altmann R, Scharnreitner I, Scheier T, Mayer R, Arzt W, Scheier M. Sonoembryology of the fetal posterior fossa at 11 + 3 to 13 + 6 gestational weeks on three-dimensional transvaginal ultrasound. *Prenat Diagn.* 2016;36(8):731–7
28. Paladini D, Donarini G, Parodi S, Volpe G, Sglavo G, Fulcheri E. Hindbrain morphometry and choroid plexus position in differential diagnosis of posterior fossa cystic malformations. *Ultrasound Obstet Gynecol.* 2019;54(2):207–14
29. Conturso R, Contro E, Bellussi F, Youssef A, Pacella G, Martelli F, Rizzo N, Pilu G, Ghi T. Demonstration of the pericallosal artery at 11-13 weeks of gestation using 3D ultrasound. *Fetal Diagn Ther.* 2015;37(4):305–9
30. Volpe P, Persico N, Fanelli T, De Robertis V, D'Alessandro J, Boito S, Pilu G, Votino C. Prospective detection and differential diagnosis of cystic posterior fossa anomalies by assessing posterior brain at 11–14 weeks. *Am J Obstet Gynecol MFM* [Internet]. 2019;1(2):173–81. Available from: <https://doi.org/10.1016/j.ajogmf.2019.06.004>
31. Manegold-Brauer G, Oseledchyk A, Floeck A, Berg C, Gembruch U, Geipel A. Approach to the sonographic evaluation of fetal ventriculomegaly at 11 to 14 weeks gestation. *BMC Pregnancy Childbirth* [Internet]. 2016;16(1):1–8. Available from: <http://dx.doi.org/10.1186/s12884-016-0797-z>

32. Loureiro T, Ushakov F, Maiz N, Montenegro N, Nicolaides KH. Lateral ventricles in fetuses with aneuploidies at 11-13 weeks' gestation. *Ultrasound Obstet Gynecol.* 2012;40(3):282–7
33. Ushakov F, Chitty LS. P30.03: Ventriculomegaly at 11–14 weeks: diagnostic criteria and outcome. 2016;48(September):2016
34. Chaoui R, Nicolaides KH. From nuchal translucency to intracranial translucency: Towards the early detection of spina bifida. *Ultrasound Obstet Gynecol.* 2010;35(2):133–8
35. Martinez-Ten P, Illescas T, Adiego B, Estevez M, Bermejo C, Wong AE, Sepulveda W. Non-visualization of choroid plexus of fourth ventricle as first-trimester predictor of posterior fossa anomalies and chromosomal defects. *Ultrasound Obstet Gynecol.* 2018;51(2):199–207
36. Chaoui R, Benoit B, Heling KS, Kagan KO, Pietzsch V, Sarut Lopez A, Tekesin I, Karl K. Prospective detection of open spina bifida at 11-13 weeks by assessing intracranial translucency and posterior brain. *Ultrasound Obstet Gynecol.* 2011;38(6):722-6
37. Loureiro T, Ushakov F, Montenegro N, Gielchinsky Y, Nicolaides KH. Cerebral ventricular system in fetuses with open spina bifida at 11-13 weeks' gestation. *Ultrasound Obstet Gynecol.* 2012;39(6):620–4
38. Ushakov F, Sacco A, Andreeva E, Tudorache S, Everett T, David AL, Pandya PP. Crash

sign: new first-trimester sonographic marker of spina bifida. *Ultrasound Obstet Gynecol.* 2019;54(6):740-745.

39. Chaoui R, Nicolaidis KH. Detecting open spina bifida at the 11-13-week scan by assessing intracranial translucency and the posterior brain region: Mid-sagittal or axial plane? *Ultrasound Obstet Gynecol.* 2011;38(6):609–12
40. Finn M, Sutton D, Atkinson S, Ransome K, Sujenthiran P, Ditcham V, Wakefield P, Meagher S. The aqueduct of Sylvius: A sonographic landmark for neural tube defects in the first trimester. *Ultrasound Obstet Gynecol.* 2011;38(6):640–5
41. Lachmann R, Sinkovskaya E, Abuhamad A. Posterior brain in fetuses with Dandy-Walker malformation with complete agenesis of the cerebellar vermis at 11-13weeks: A pilot study. *Prenat Diagn.* 2012;32(8):765–9
42. Volpe P, Contro E, Fanelli T, Muto B, Pilu G, Gentile M. Appearance of fetal posterior fossa at 11-14 weeks in fetuses with Dandy-Walker malformation or chromosomal anomalies. *Ultrasound Obstet Gynecol.* 2016;47(6):720–5
43. Iuculano A, Zoppi MA, Ibba RM, Monni G. A Case of Enlarged Intracranial Translucency in a Fetus with Blake's Pouch Cyst. *Case Rep Obstet Gynecol.* 2014;2014:1–3
44. Altmann R, Schertler C, Scharnreitner I, Arzt W, Dertinger S, Scheier M. Diagnosis of Fetal Posterior Fossa Malformations in High-Risk Pregnancies at 12-14 Gestational Weeks by Transvaginal Ultrasound Examination. *Fetal Diagn Ther.* 2020;47(3):182–7

45. Lafouge A, Gorincour G, Desbriere R, Quarello E. Prenatal diagnosis of Blake's pouch cyst following first-trimester observation of enlarged intracranial translucency. *Ultrasound in Obstetrics and Gynecology*. 2012;40(4):479-80.
46. Garcia-Posada R, Eixarch E, Sanz M, Puerto B, Figueras F, Borrell A. Cisterna magna width at 11-13 weeks in the detection of posterior fossa anomalies. *Ultrasound Obstet Gynecol*. 2013;41(5):515–20
47. Volpe P, Muto B, Passamonti U, Rembouskos G, De Robertis V, Campobasso G, Tempesta A, Volpe G, Fanelli T. Abnormal sonographic appearance of posterior brain at 11-14weeks and fetal outcome. *Prenat Diagn*. 2015;35(7):717-23.
48. Dall'Asta A, Grisolia G, Volpe N, Schera GBL, Sorrentino F, Frusca T. Prenatal visualization of the torcular herophili by means of a Doppler technology highly sensitive for low velocity flow in the expert assessment of the posterior fossa: a prospective study. *Br J Obstet Gynaecol*. 2020; published online ahead of print. doi:10.1111/1471-0528.16392
49. Malinger G, Zakut H. The corpus callosum: Normal fetal development as shown by transvaginal sonography. *Am J Roentgenol*. 1993;161(5):1041-3.
50. Achiron R, Achiron A. Development of the human fetal corpus callosum: A high-resolution, cross-sectional sonographic study. *Ultrasound Obstet Gynecol*. 2001;18(4):343–7

51. Lachmann R, Sodre D, Barmpas M, Akolekar R, Nicolaides KH. Midbrain and falx in fetuses with absent corpus callosum at 11-13 weeks. *Fetal Diagn Ther.* 2013;33(1):41–6
52. Pati M, Cani C, Bertucci E, Re C, Latella S, D'Amico R, Mazza V. Early visualization and measurement of the pericallosal artery: An indirect sign of corpus callosum development. *J Ultrasound Med.* 2012;31(2):231-7.
53. Díaz-Guerrero L, Giugni-Chalbaud G, Sosa-Olavarría A. Assessment of pericallosal arteries by color Doppler ultrasonography at 11-14 weeks: An early marker of fetal corpus callosum development in normal fetuses and agenesis in cases with chromosomal anomalies. *Fetal Diagn Ther.* 2013;34(2):85–9

Figure legends

Figure 1. Supra-thalamic section: (P) choroid plexus; (LV) lateral ventricle; (IHF) interhemispheric fissure; (SyF) future Sylvian fissure; (FrL) frontal lobe cortex; (Ocl) occipital lobe cortex.

Figure 2. A) Trans-thalamic section at ultrasound; B) Anatomic specimen corresponding to the trans-thalamic section. (P) choroid plexus; (LV) lateral ventricle; (IHF) interhemispheric fissure; (SyF) future Sylvian fissure; (T) thalamus; (3) 3rd ventricle; (Aq) Sylvian aqueduct; (Tec) tectum.

Figure 3. Mid-sagittal view, frontal ultrasound approach. A) Detailed anatomy of the cranial posterior fossa. B) Measurements of the posterior fossa structures, and detailed anatomy of the visible midline structures. (D) diencephalon; (M) mesencephalon; (P) pons; (Md) medulla; (4) 4th ventricle; (CM) Cisterna Magna; (BS) brain stem; (BSOB) brain stem to occipital bone space; (Fx) fornix; (AC) anterior commissure.

Figure 4. Midsagittal view, posterior ultrasound approach. A) Detailed anatomy of the cranial posterior fossa and Aqueduct. B) Anatomic specimen corresponding to the midsagittalsection. (Aq) aqueduct of Sylvius; (M) mesencephalon; (P) pons; (Md) medulla; (4) 4th ventricle; (CM) Cisterna Magna; (Tec) tectum; (AMA) anterior membranous area; (PMA) posterior membranous area; (Px) plexus of the 4th ventricle; (V) cerebellar vermis; (BP) Blake's pouch.

Figure 5. Coronal views of the fetal brain: (tF) frontal, (tC) trans-caudate, (tT) trans-thalamic,

(tO) occipital.

Figure 6. Frontal coronal view. (P) choroid plexus; (LV) lateral ventricle; (IHF) interhemispheric fissure; (O+L) eye orbit and lens; (FB) frontal bone.

Figure 7. Trans-caudate coronal view: A) detailed ultrasound anatomy and B) corresponding anatomic specimen. (P) choroid plexus of the lateral ventricle; (IHF) interhemispheric fissure; (3) 3rd ventricle; (G) ganglionic eminence; (B) basal ganglia.

Figure 8. Trans-thalamic coronal view: A) detailed ultrasound anatomy and B) corresponding anatomic specimen. (P) choroid plexus; (LV) lateral ventricle; (IHF) interhemispheric fissure; (3) 3rd ventricle; (T) thalamus.

Figure 9. Occipital coronal view 1, anterior to the 4th ventricle: A) detailed ultrasound anatomy and B) corresponding anatomic specimen. (LV) lateral ventricle; (A) aqueduct of Sylvius; (Te) tectum; (BS) brain stem (pons and medulla); (C) future cerebellar hemisphere.

Figure 10. Occipital coronal view 2, at the level of the 4th ventricle: A) detailed ultrasound anatomy and B) corresponding anatomic specimen. (LV) lateral ventricle; (A) aqueduct of Sylvius; (Te) tectum; (Is) isthmus; (BS) brain stem (pons and medulla); (4) 4th ventricle (C) future cerebellar hemisphere (P) rhomboencephalic (4th ventricle) choroid plexus.

Figure 11. Sagittal views of the fetal brain using high-sensitive Doppler (MV flow). (P) pericallosal artery; (C) internal carotid artery; (B) basilar artery; (V) vertebral artery; (St) straight sinus; (Su) superior sagittal sinus; (TH) torcular Herophili; (G) vein of Galen.

Figure 12. Axial view of the fetal brain showing the circle of Willis by high-sensitive Doppler (MV flow). (A) anterior cerebral artery; (M) middle cerebral artery; (P) posterior cerebral artery; (pc) posterior communicating artery.

Figure 13. Ventriculomegaly in the first trimester. A) On the axial supra-thalamic plane the ratios between the lengths and areas of the choroid plexus (p) and the lateral ventricle (v) are reduced. B) On the coronal trans-thalamic view both choroid plexuses do not reach the roof of the corresponding lateral ventricle.

Figure 14. Appearance of the Chiari II malformation on the midsagittal view in the first trimester. The brain stem (BS) is thicker than usual and posteriorly displaced, compressing the 4th ventricle (4) with consequent collapse of the cisterna magna.

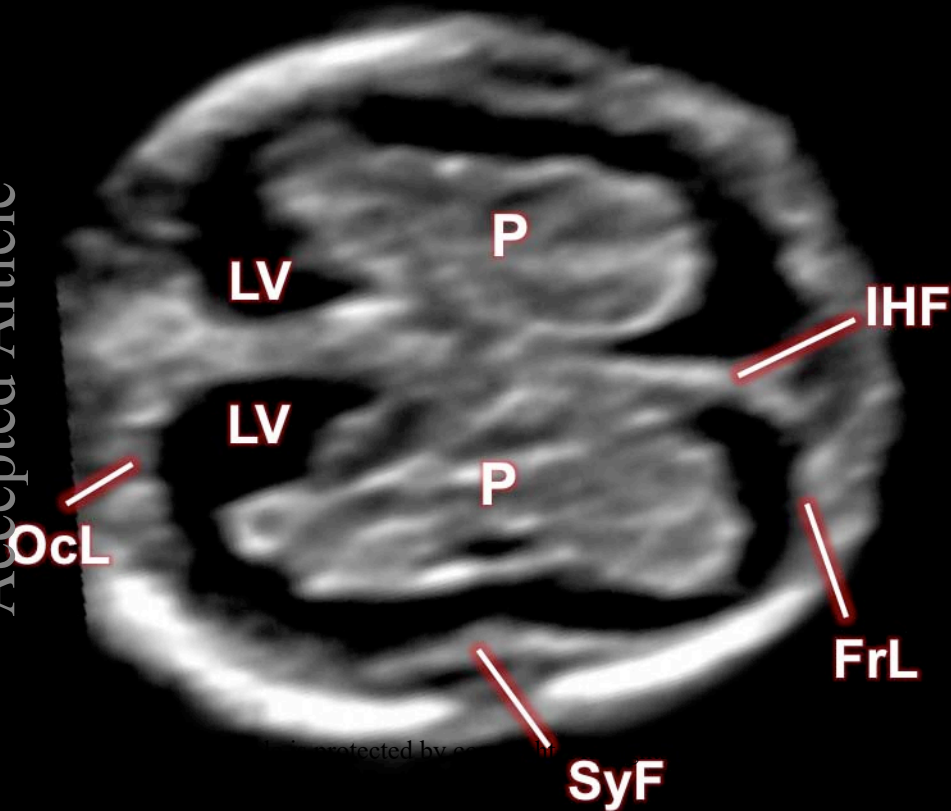
Figure 15. Appearance of the Chiari II malformation on the axial trans-thalamic view in the first trimester. The 3rd ventricle and the aqueduct of Sylvius (arrow) are barely visible (“dry brain”), and the midbrain is displaced backwards with the aqueduct pushed close to the occipital bone (“crash sign”).

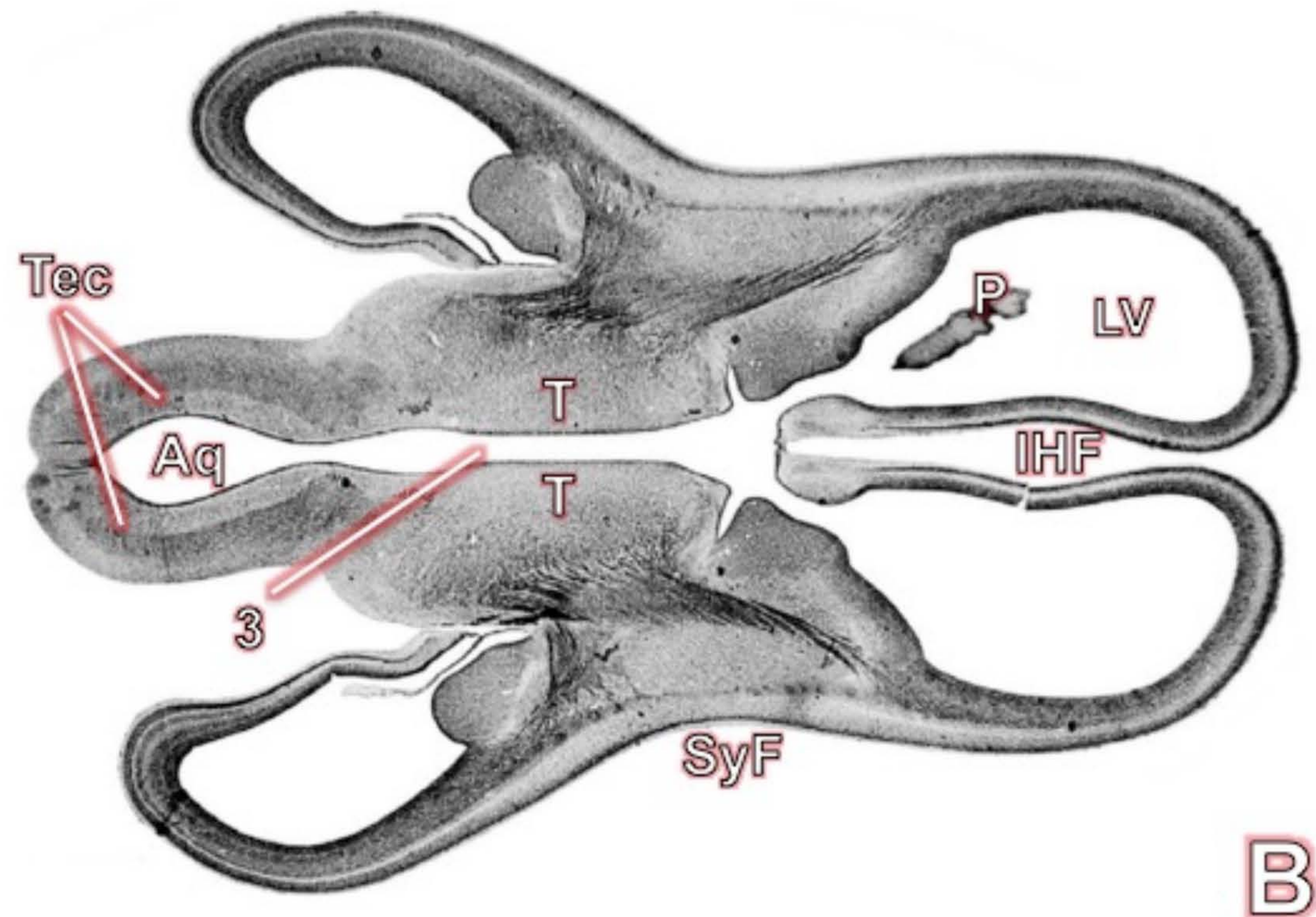
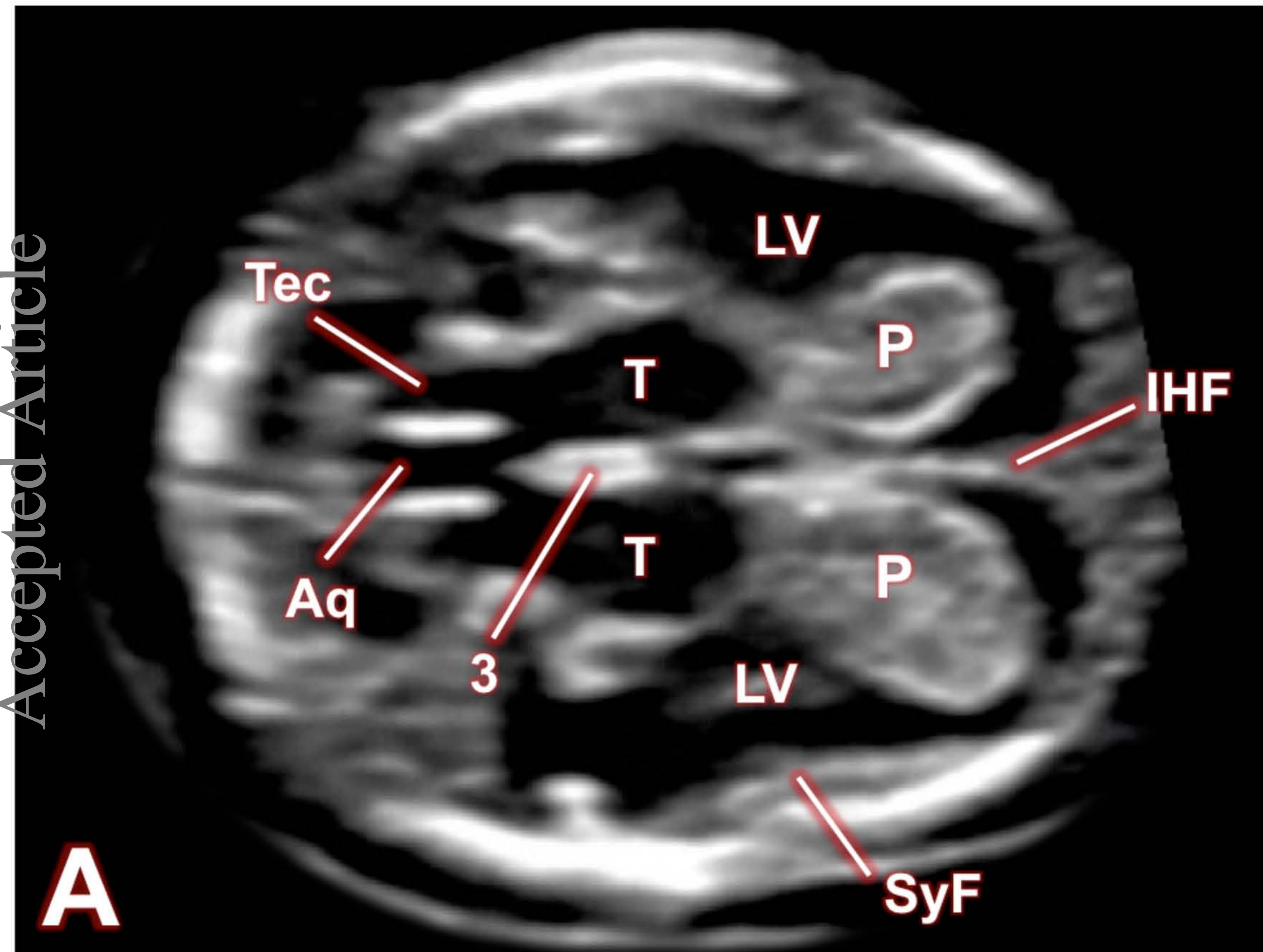
Figure 16. Appearance of a cystic anomaly of the posterior fossa in the first trimester: A) on the midsagittal view the ratio between the brain stem (BS) and the BS-to-occipital-bone distance (BSOB) is reduced, and B) on the occipital coronal view the 4th ventricle (4v) appears enlarged, with prominence also of the aqueduct of Sylvius (A) and the Blake’s pouch (BP). C) the ponto-vermian angle is increased when focusing on the pons (P) and vermis (V). (Te) tectum, (Is) isthmus, (C) future cerebellar hemisphere; (Px) plexus of the 4th

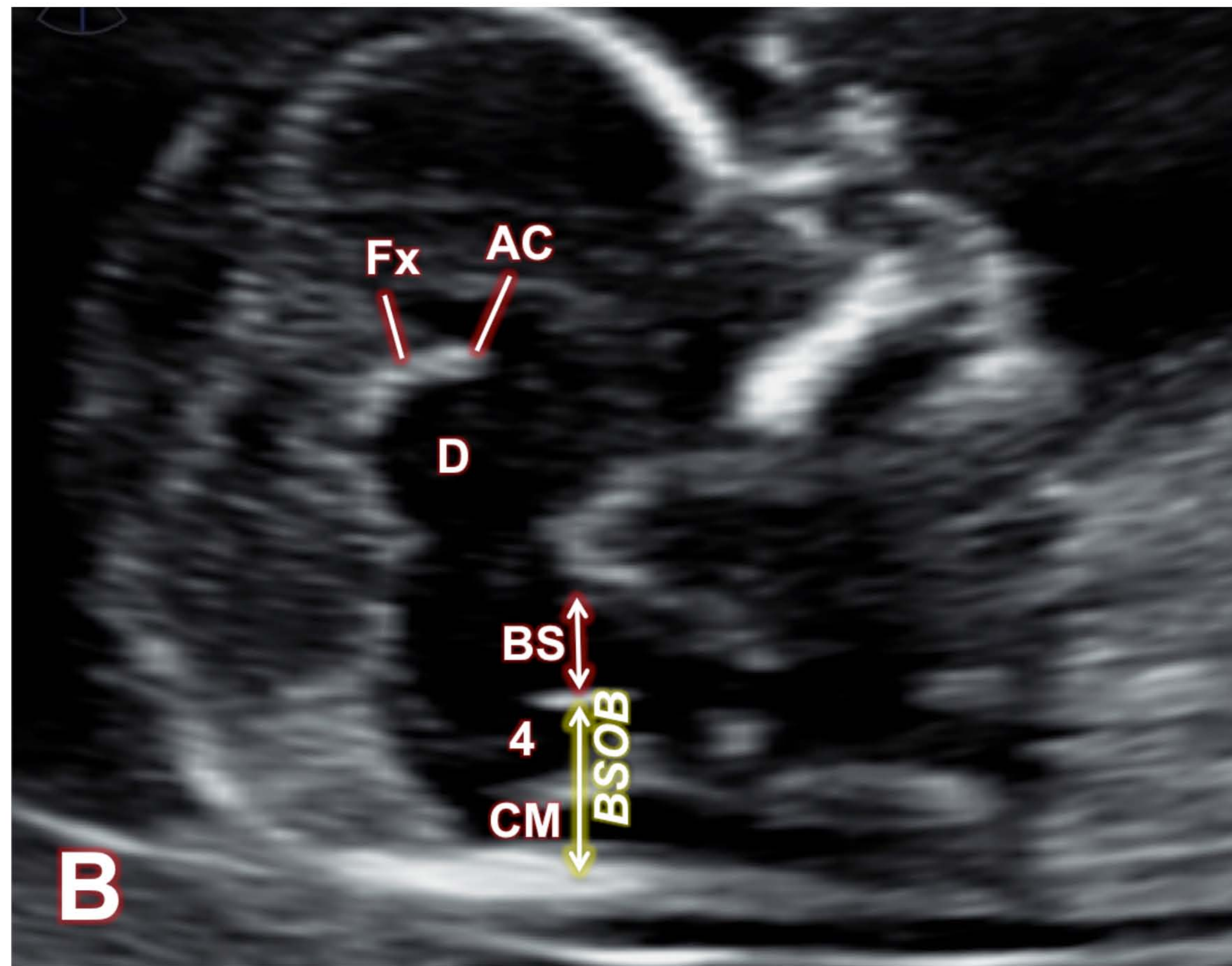
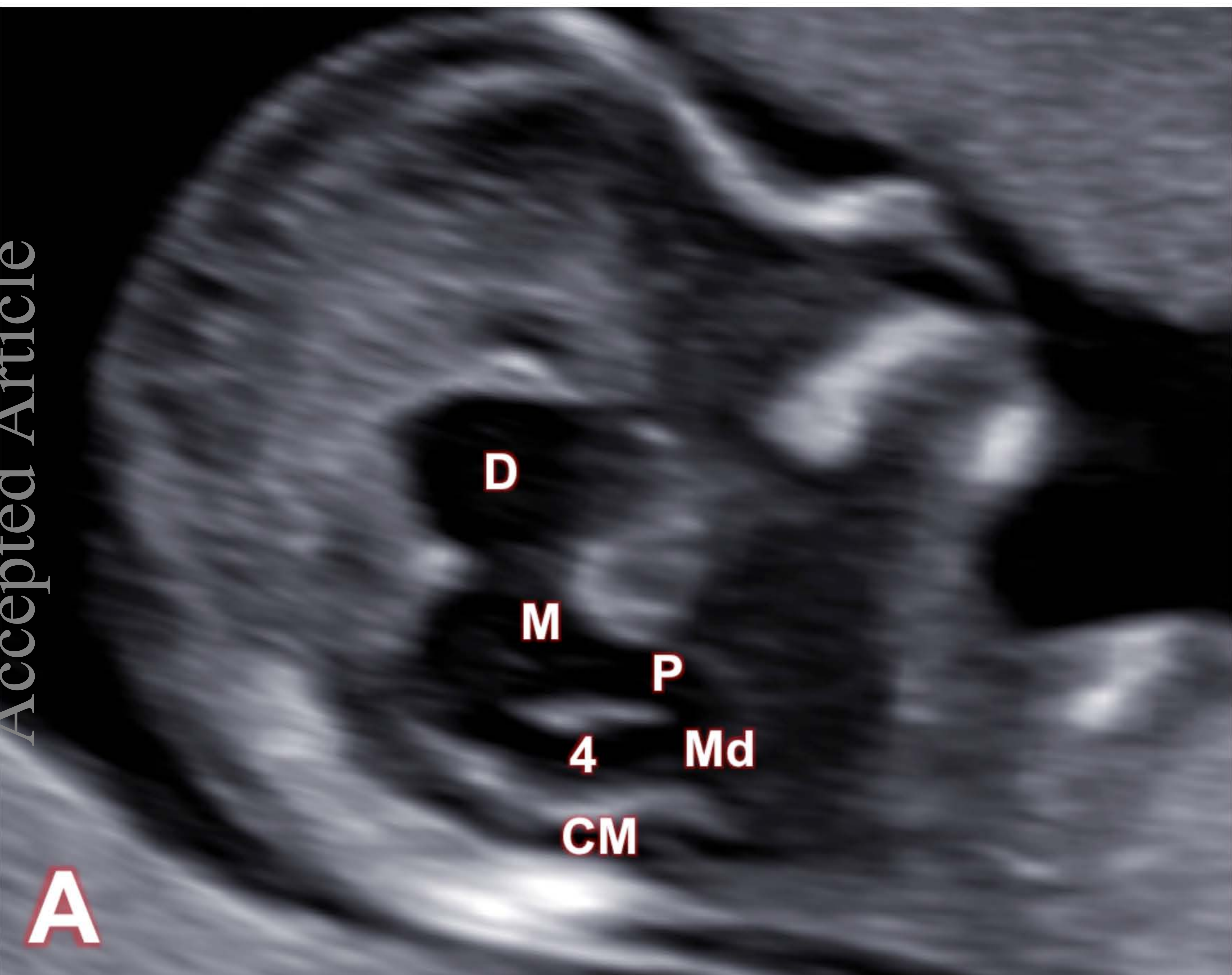ventricle.

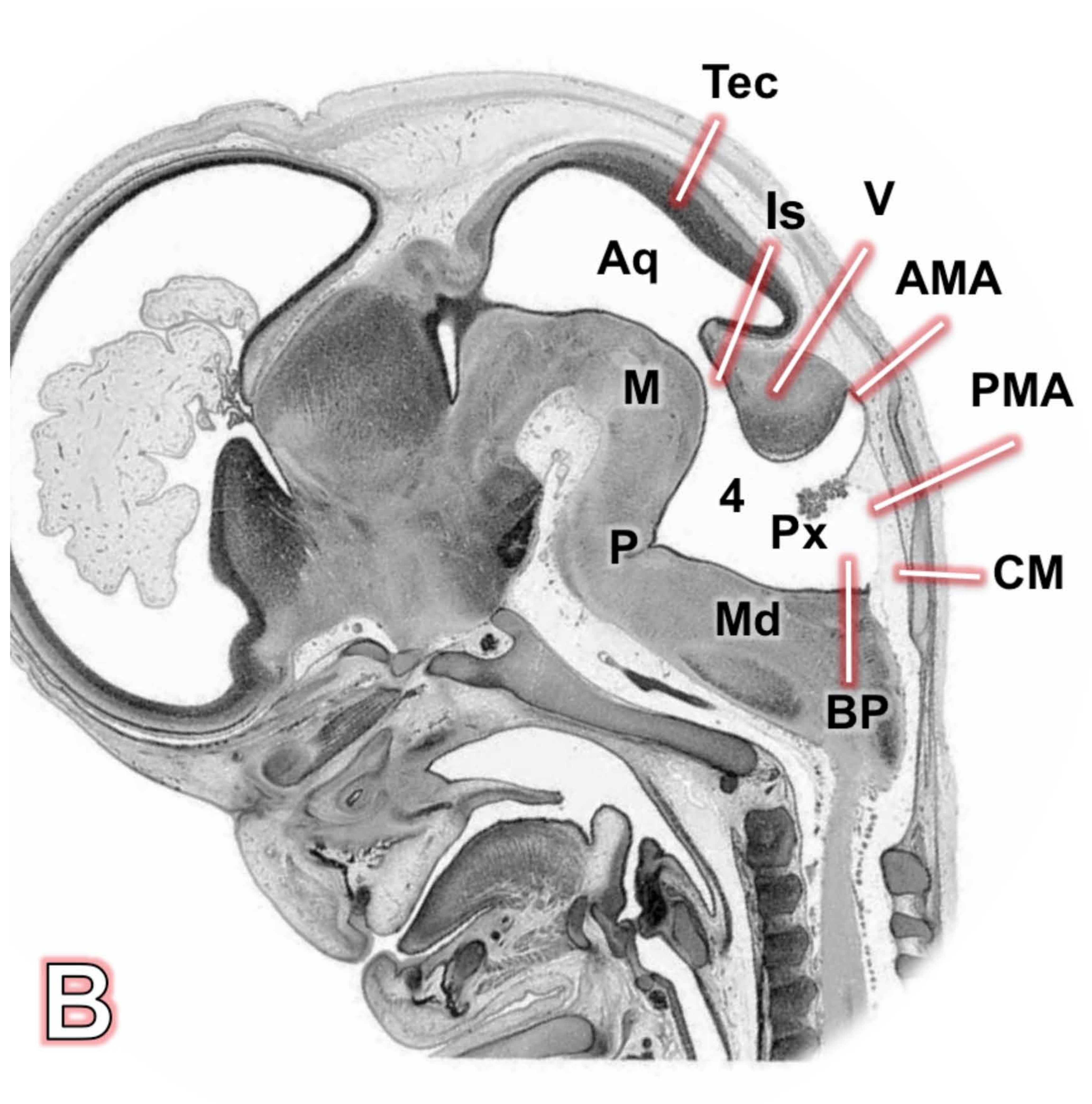
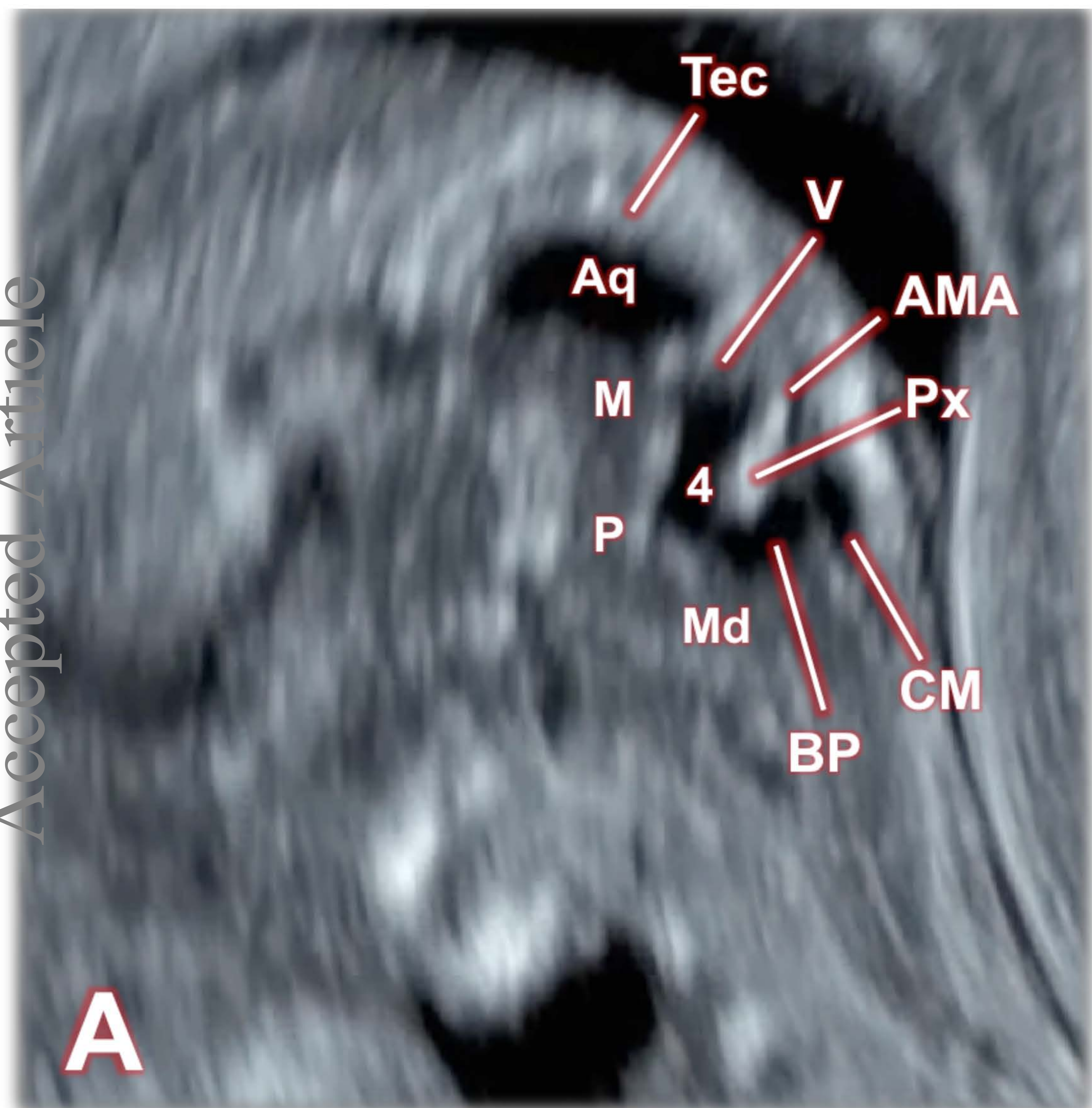
Figure 17. A case of agenesis of corpus callosum in the first trimester, showing on the midsagittal view an increased ratio between the diencephalon (D) and falx (F) diameters.

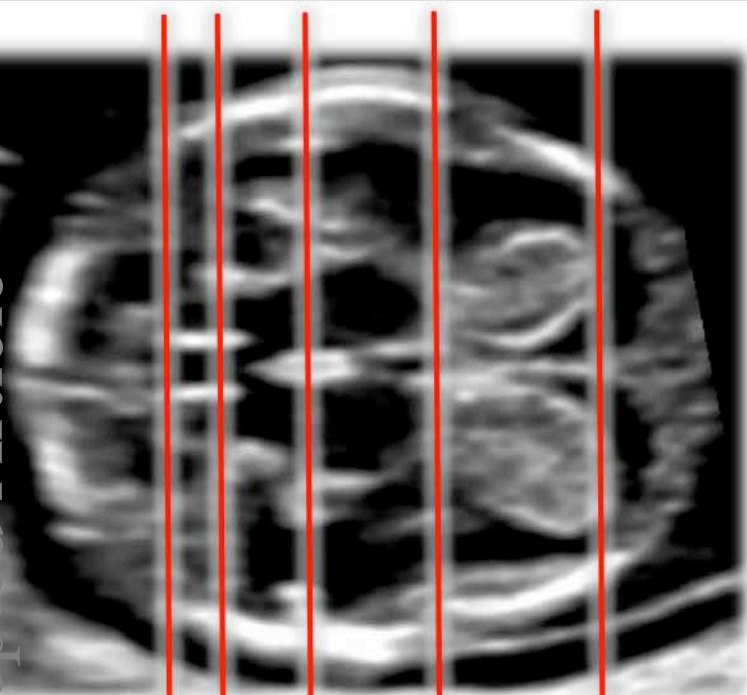
Accepted Article



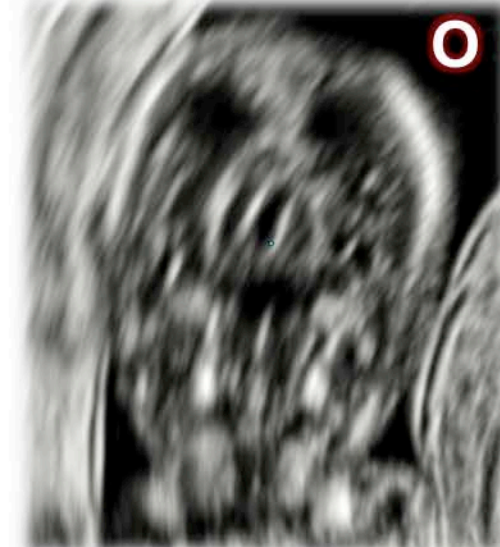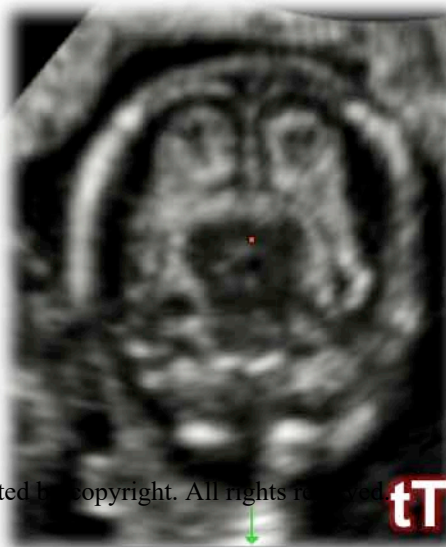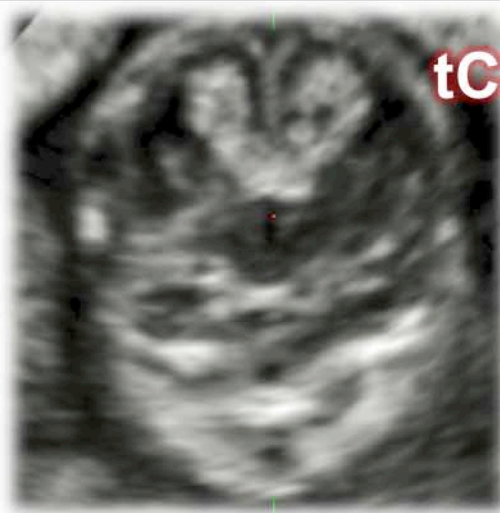


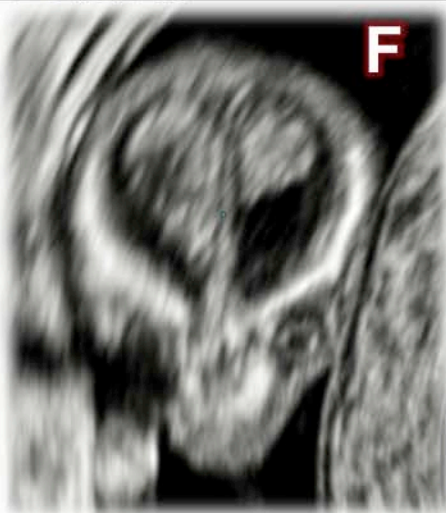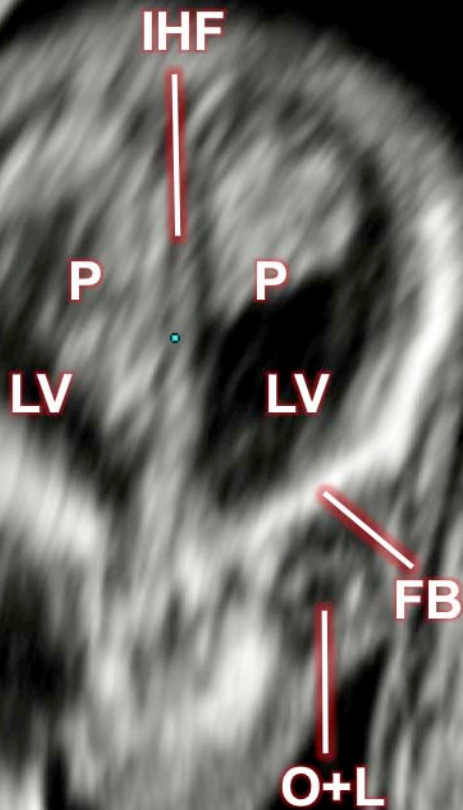


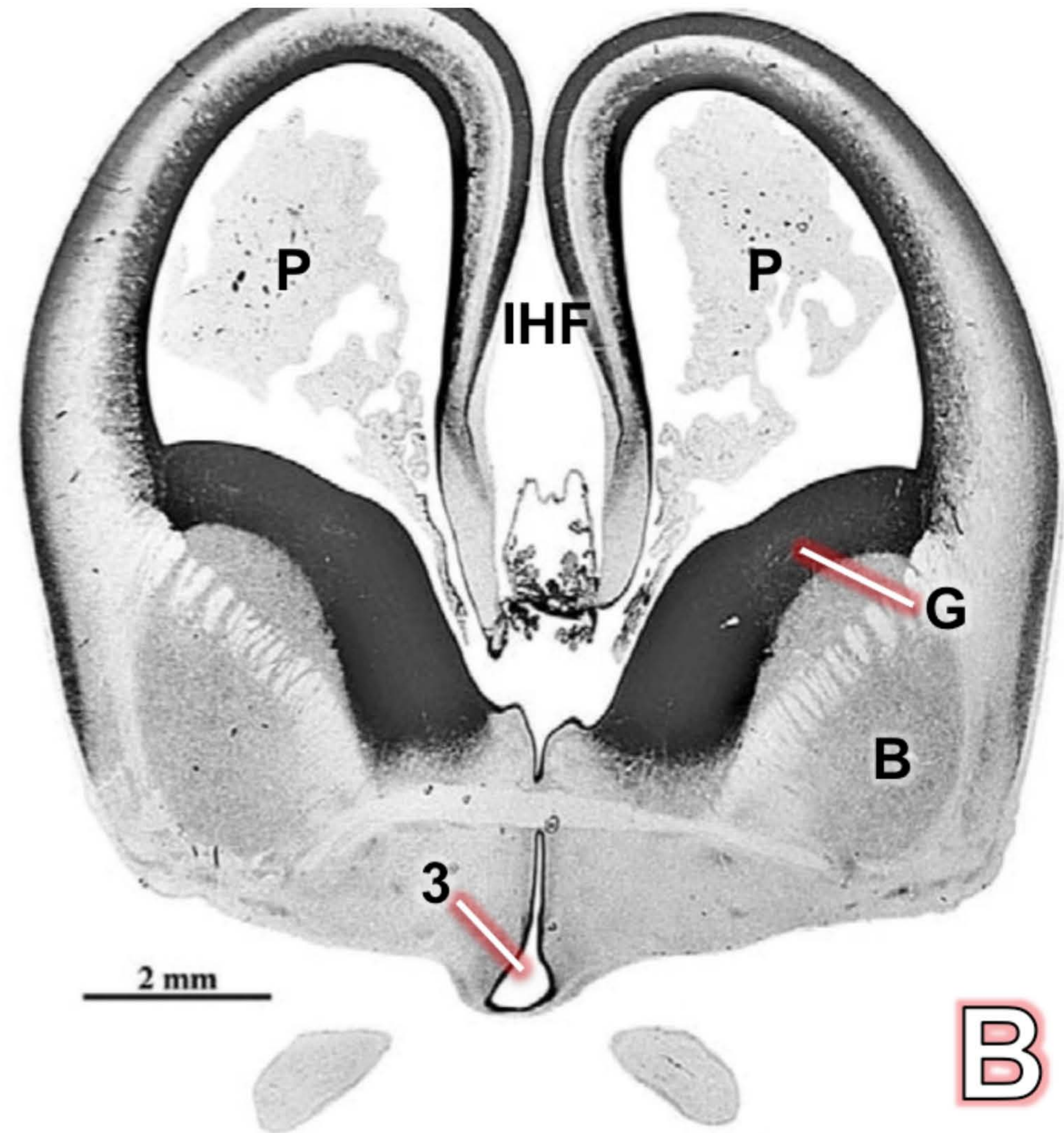
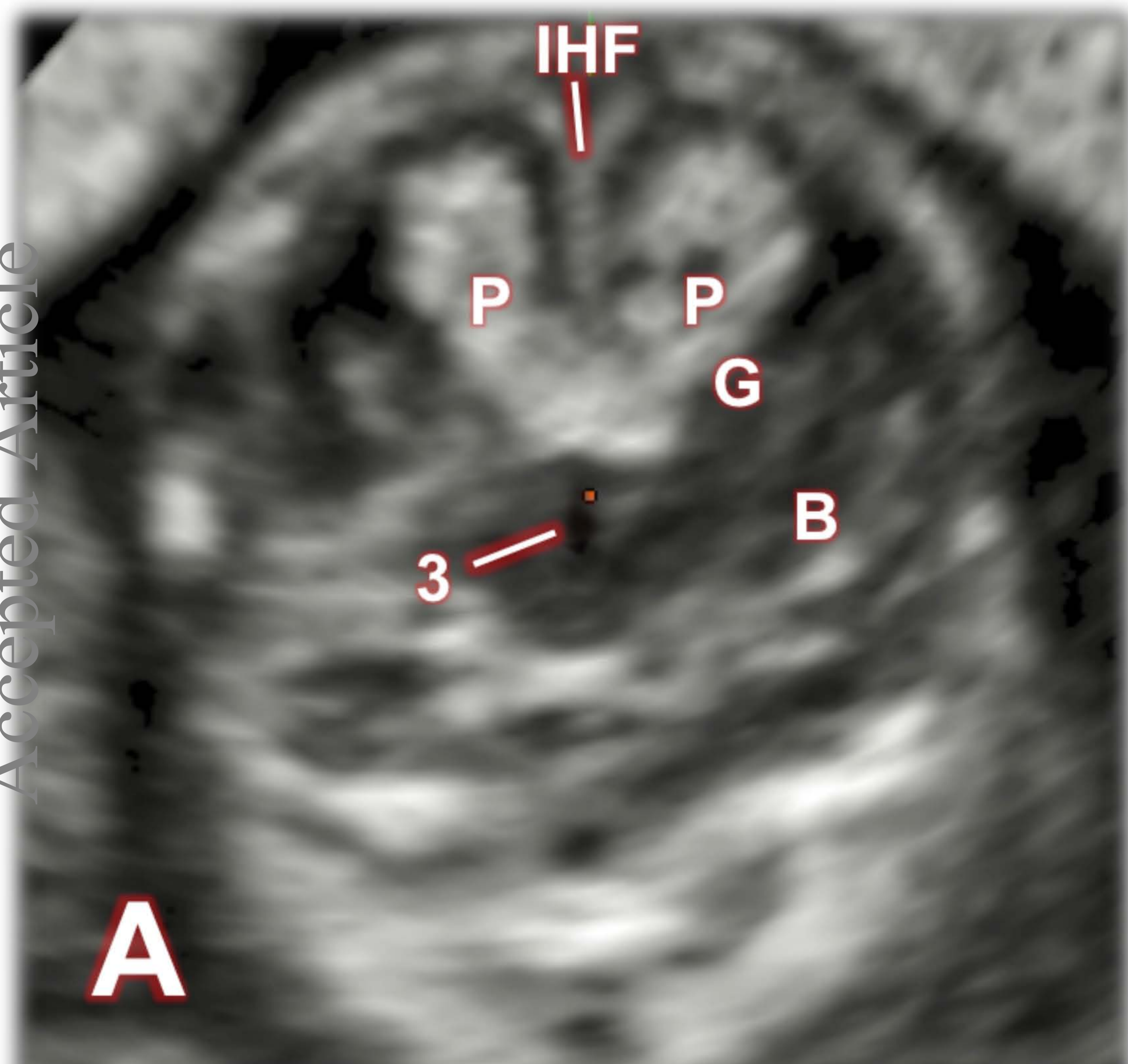


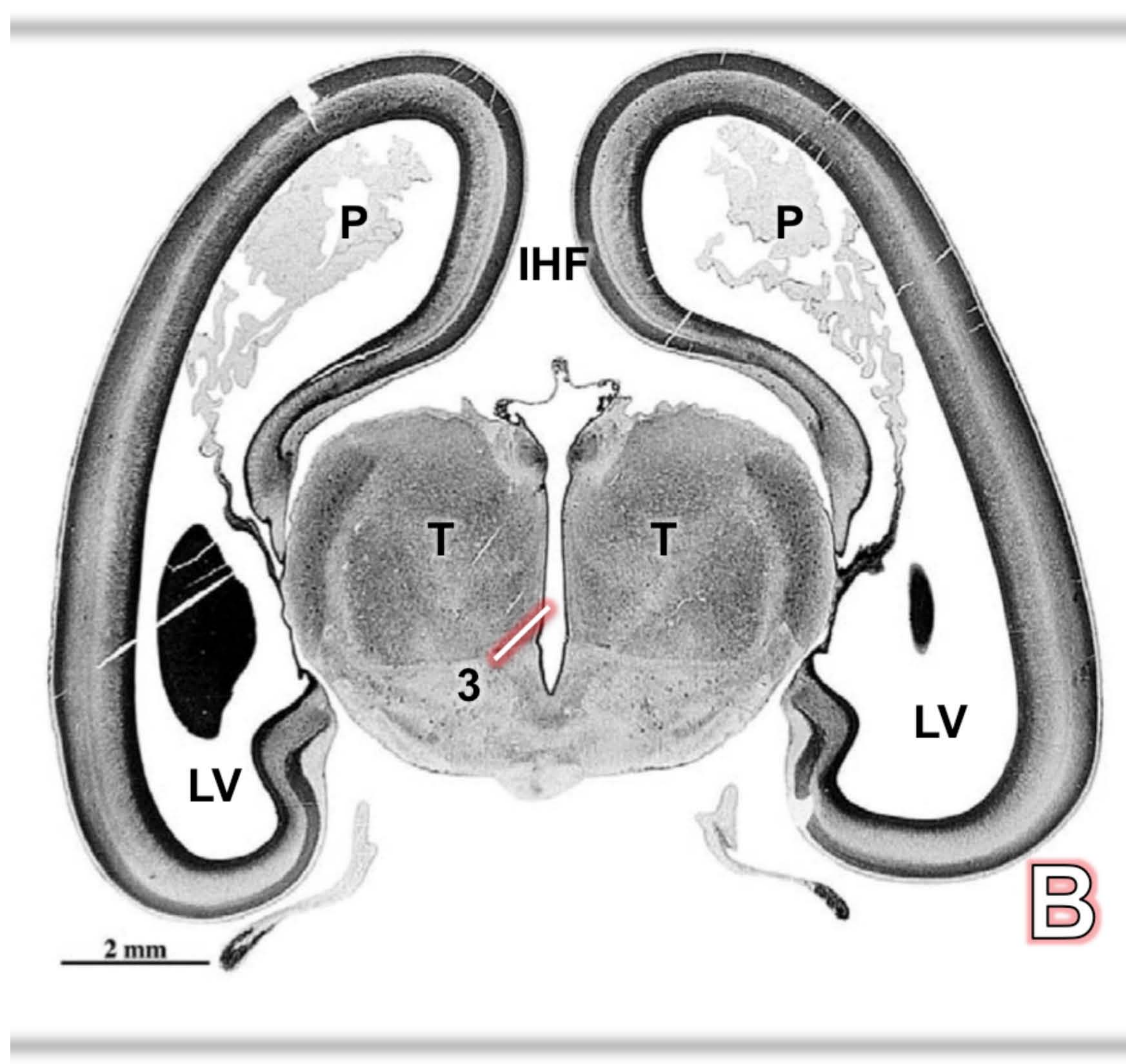
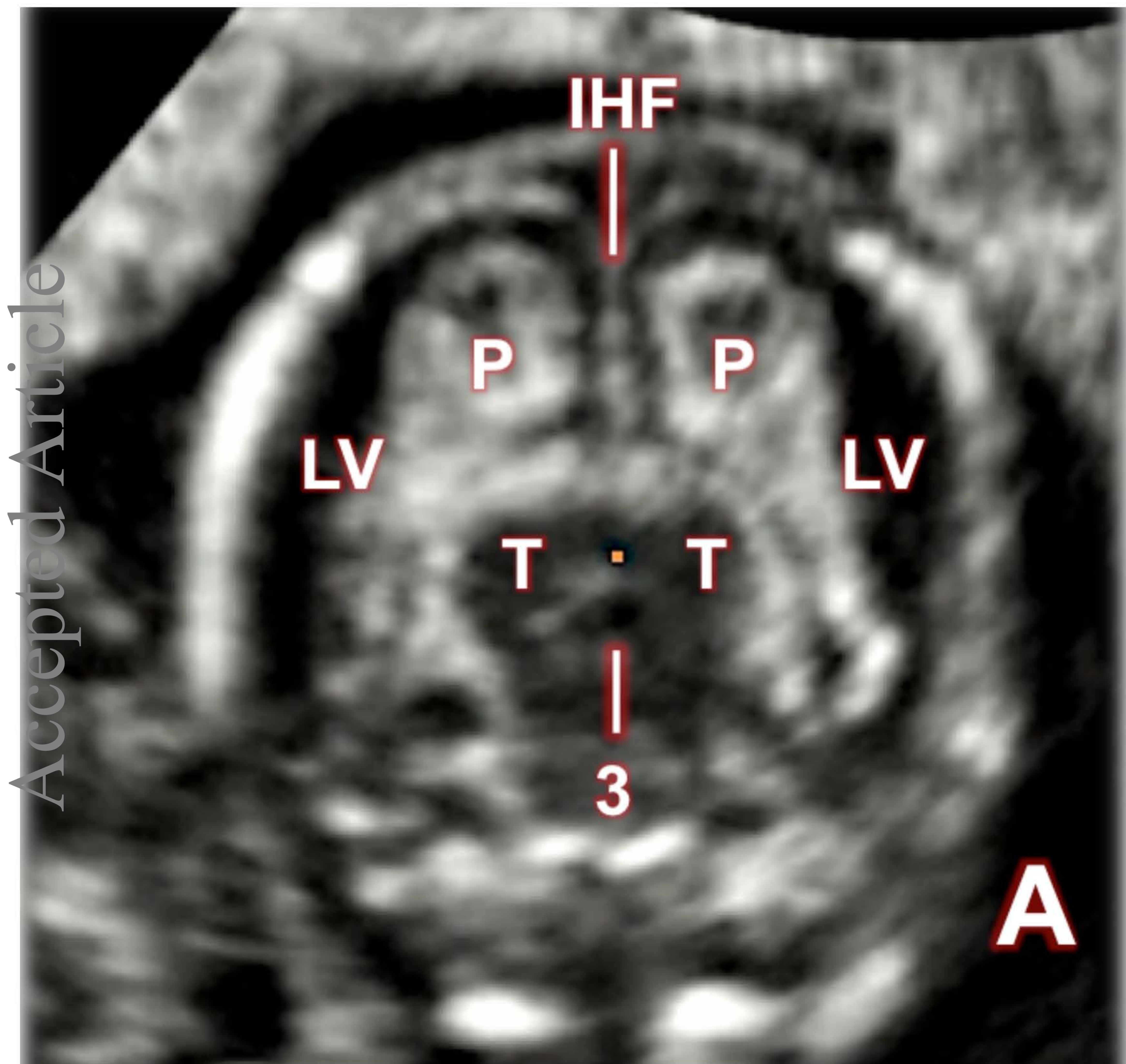


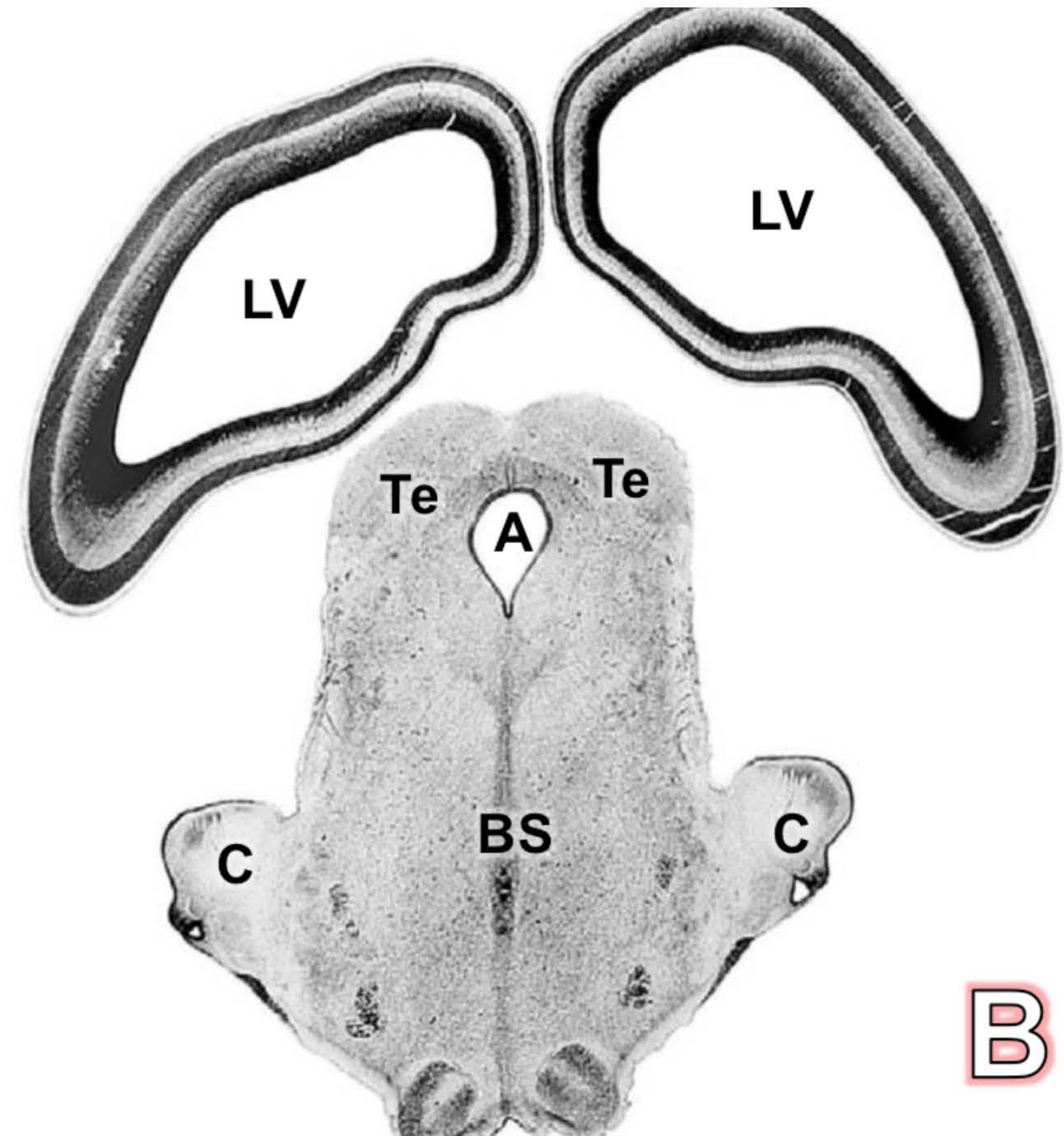
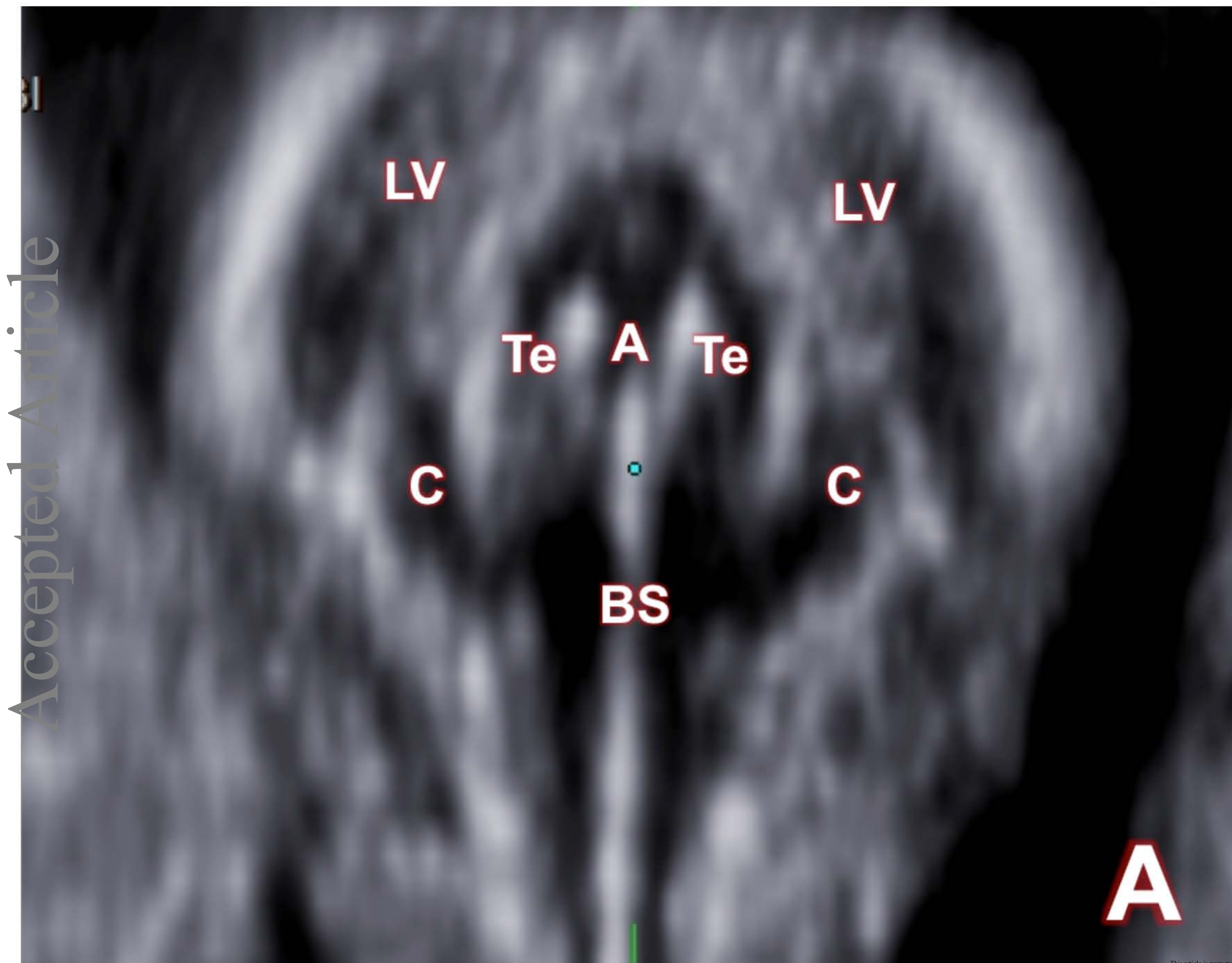
2 1
O
tT
tC
F

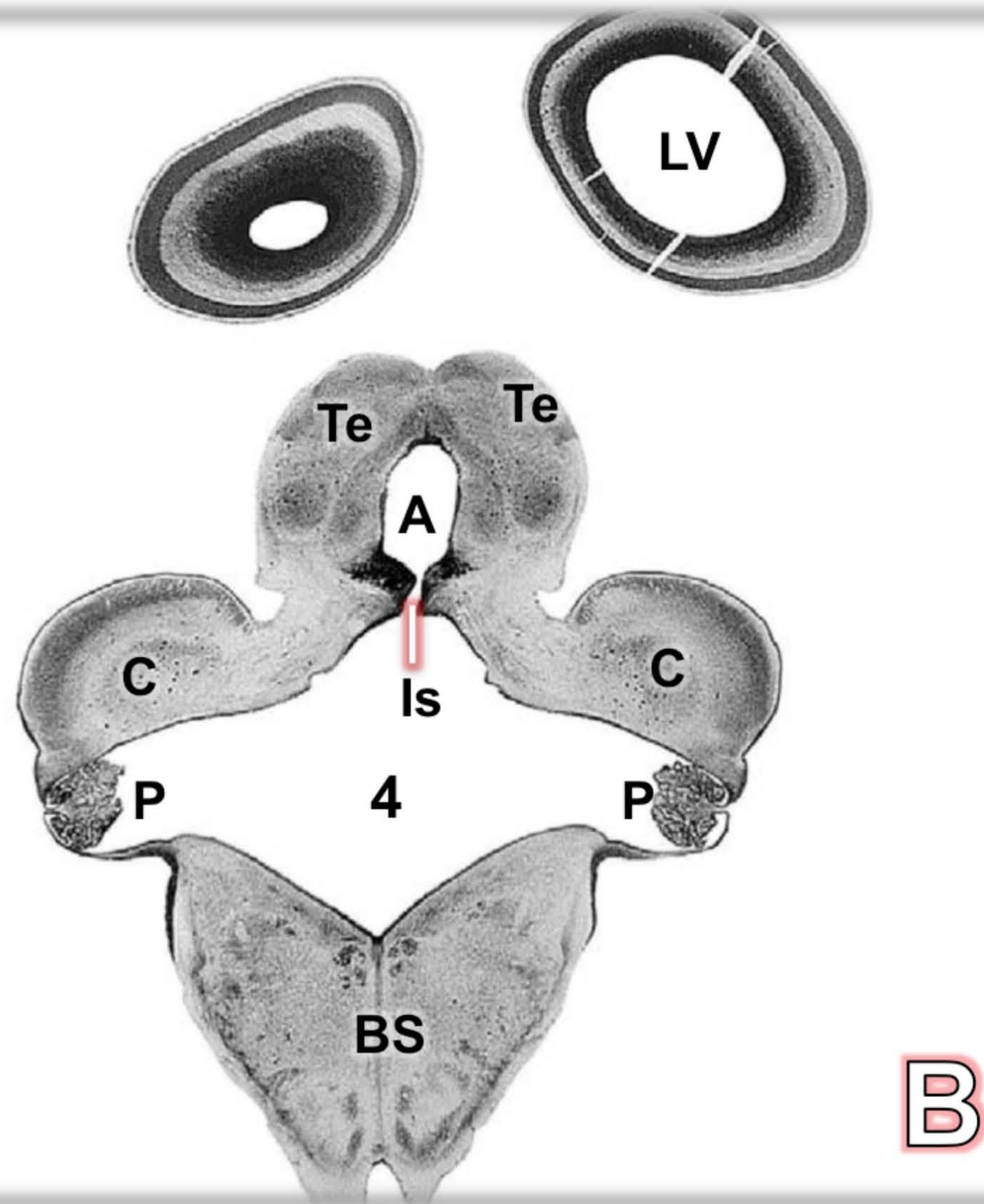
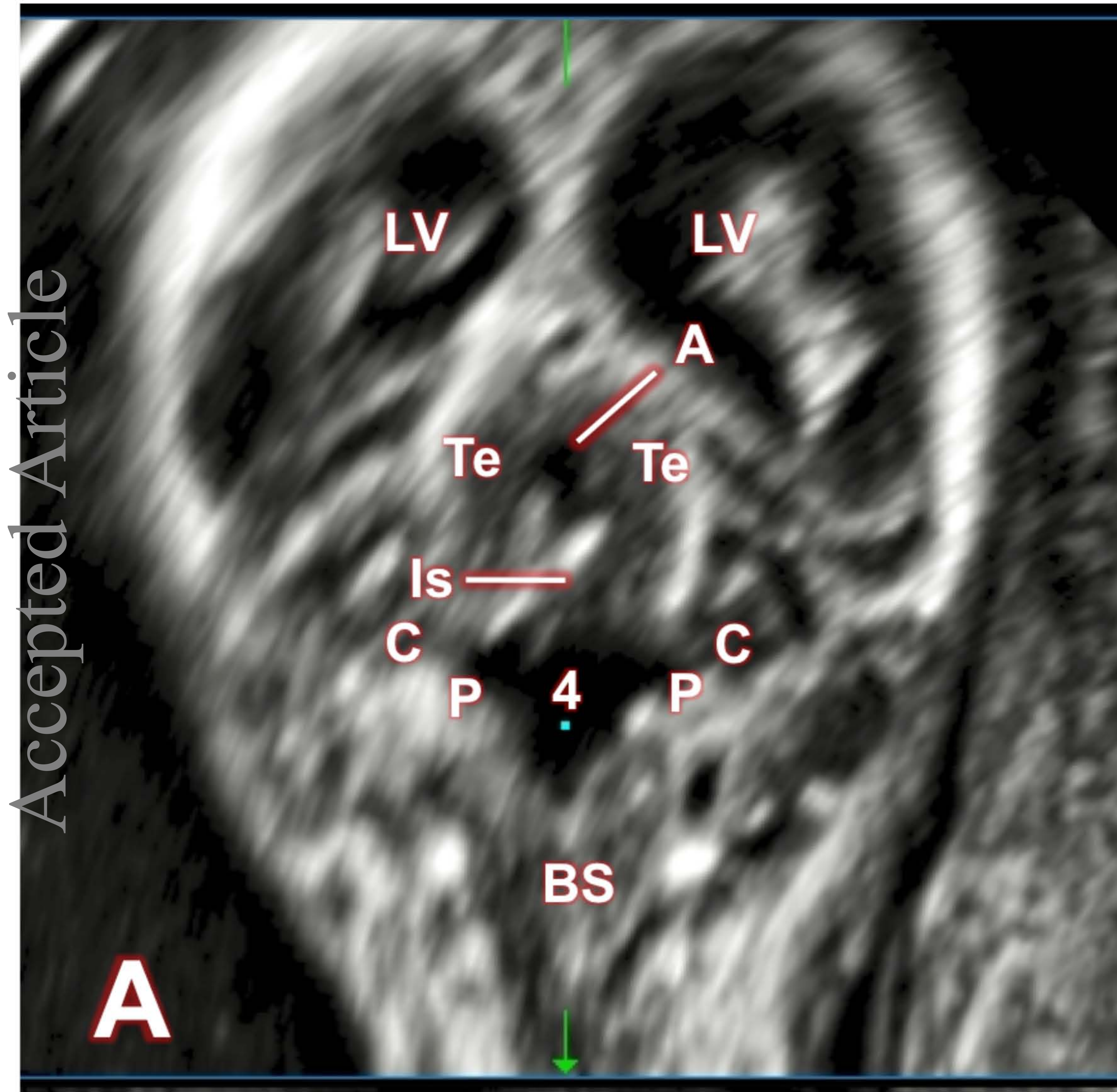


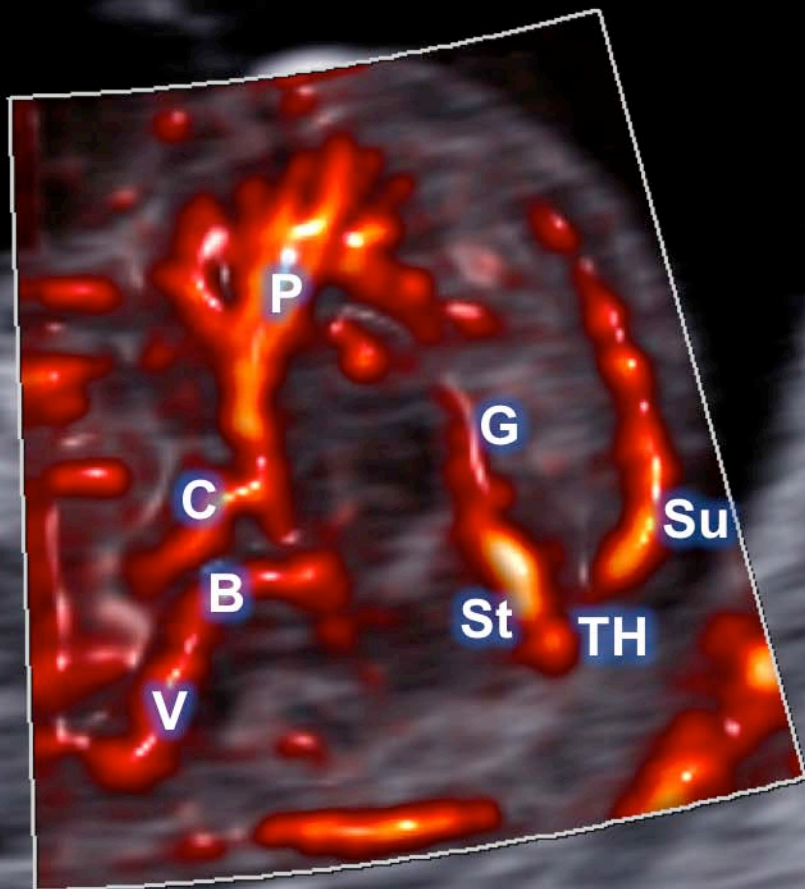


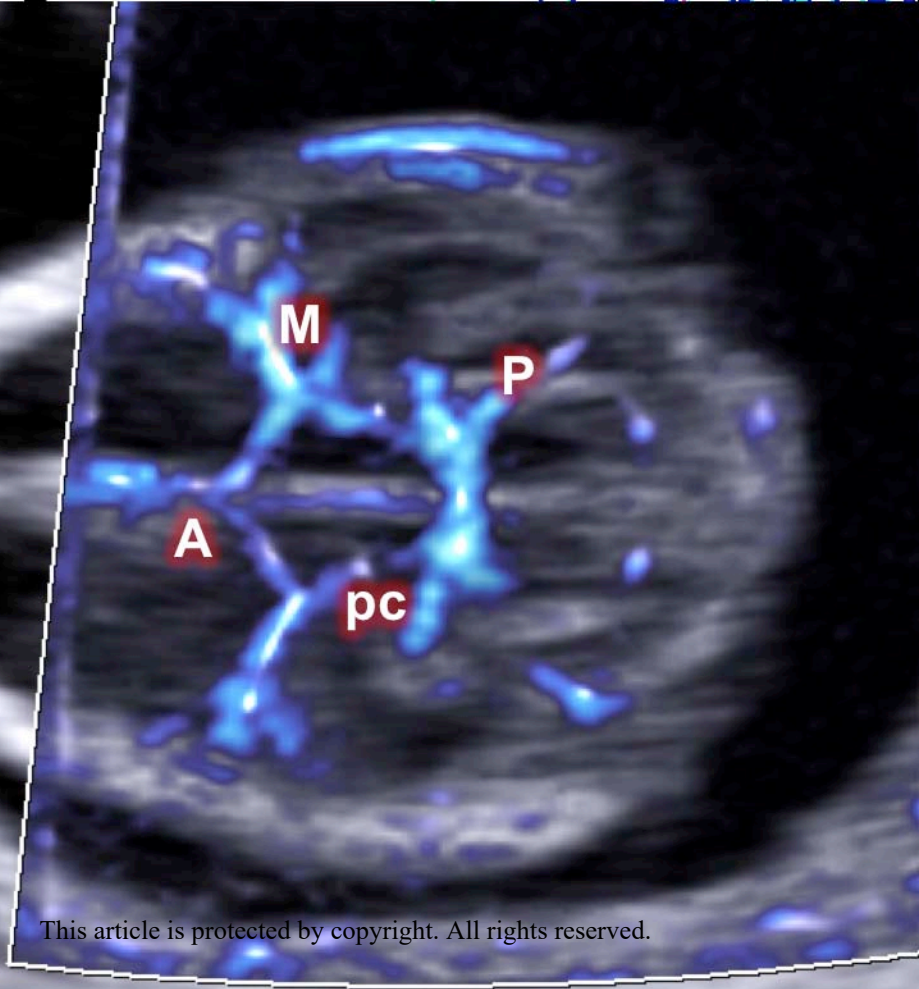




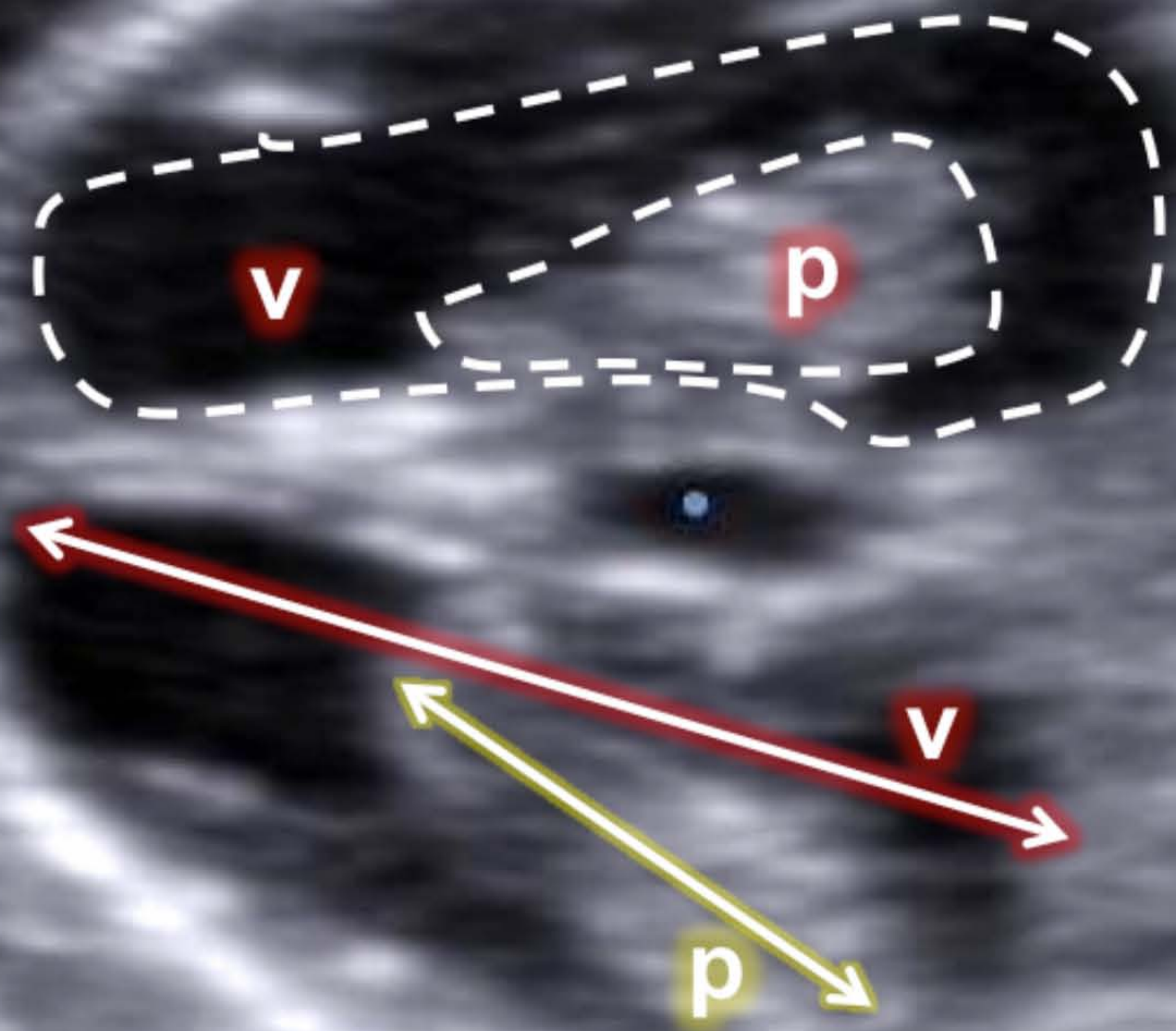




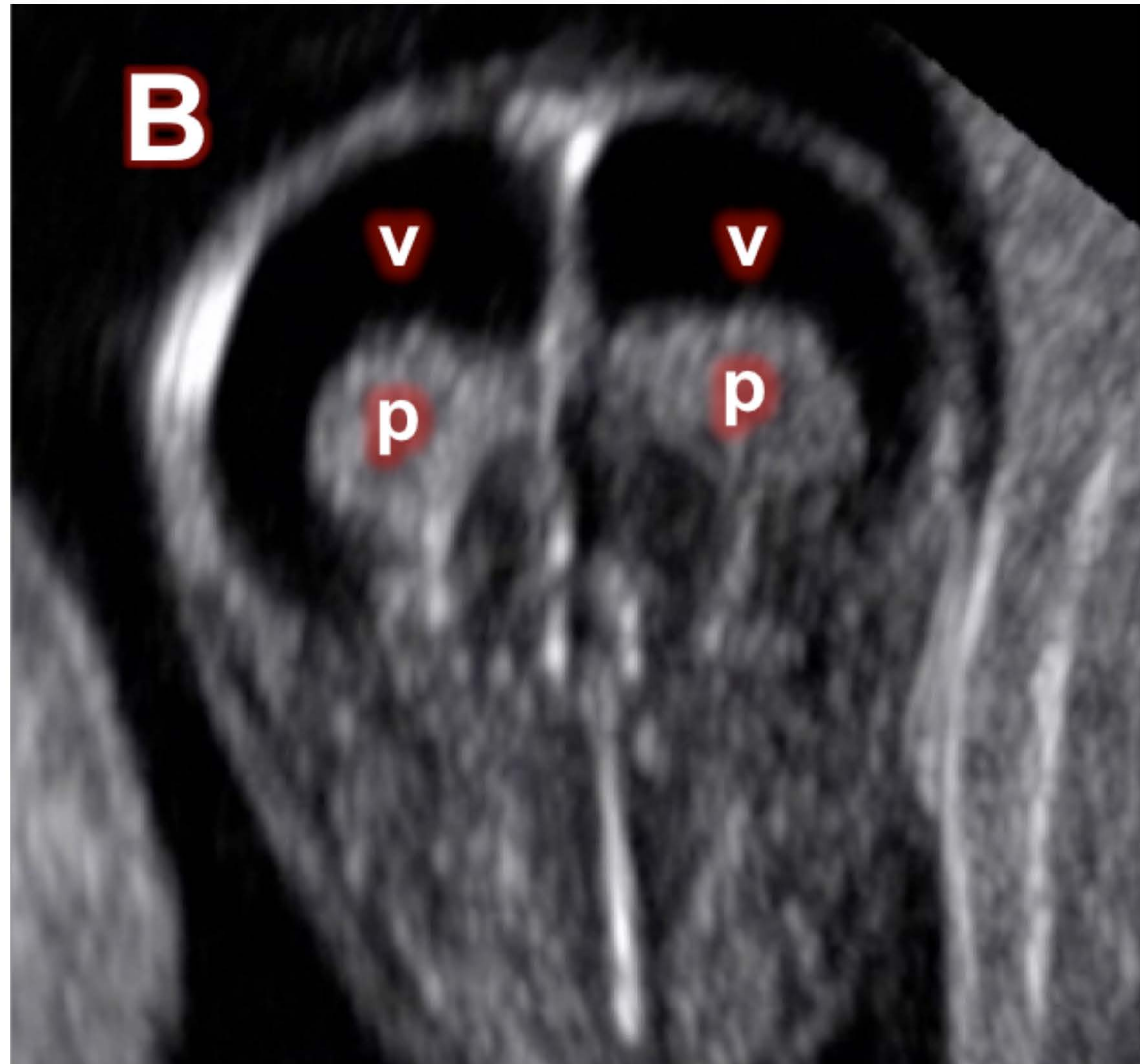




A



B





BS

4



