

Safer Treatment of Novel Imeglimin (Twymeeg) For Elderly Female with Type 2 Diabetes (T2D)

Hatakeyama S^a, Okada M^b, Bando H^{ab*}, Iwatsuki N^a, Sakamoto K^a, Ogawa T^a

^aSakamoto Hospital, Higashi Kagawa city, Kagawa, Japan

^bTokushima University / Medical Research, Tokushima, Japan

Article Info

Article History:

Received: 21 May, 2022

Accepted: 26 May, 2022

Published: 28 May, 2022

^{*}Corresponding author: Bando H, Tokushima University /Medical Research, Nakashowa 1-61, Tokushima 770-0943 Japan; Tel: +81-90-3187-2485; DOI: <https://doi.org/10.36266/IJED/137>

Abstract

Background: A novel oral hypoglycemic agent (OHA) would be imeglimin (Twymeeg) as tetrahydrotriazine-containing drug.

Case presentation: The patient is 93-year-old female and developed appetite loss and slower vocal response in March, 2022.

Result: She was transferred to our hospital, and diagnosed as T2DM with HbA1c 8.4% and small lacunar infarction in bilateral white matter by MRI. Then, imeglimin 2000mg/day was started and HbA1c was decreased to 6.2% in April, 2020.

Discussion: Imeglimin has dual function for increasing insulin secretion and decreasing insulin resistance. It seems to be effective for elderly case, and will be used widely in the future.

Keywords: Oral hypoglycemic agent (OHA); Imeglimin; Twymeeg; Tetrahydrotriazine; Trials of IMeglimin for Efficacy and Safety (TIMES)

Copyright: © 2022 Bando H, et al. This is an open-access article distributed under the terms of the Creative Commons Attribution License, which permits unrestricted use, distribution, and reproduction in any medium, provided the original author and source are credited.

Introduction

Type 2 Diabetes (T2D) has been crucial medical and health crisis for our society, which will increase by more than 50% by 2045 worldwide [1]. Using modern T2D therapeutics, lots of cardiovascular outcome trials were observed, in which risk reduction of congestive heart failure (CHF), atherosclerotic cardiovascular disease (CVD) and chronic kidney disease (CKD) has been found. Consequently, several guidelines showed more evidence-based perspectives, which focus on glycemic goal of each patient associated with benefits, complication reduction and safety [1]. In the light of evidence-based medicine, American Diabetes Association (ADA) has announced latest adequate therapeutic strategy for T2D in the guideline on Jan 2022 [2]. Diabetic patients have been rapidly increased and then applicable treatment has been in progress associated with patient-centered therapy [3]. For oral hypoglycemic agents (OHAs), metformin has been first-line agent for T2D for long years.

Recently, imeglimin was introduced to clinical practice as chemical moiety with metformin and it can modulate mitochondrial complex I activity [4]. The possible development of lactic acidosis by imeglimin was compared with that of metformin. As a result, the incidence of lactic acidosis was lower in imeglimin, in which underlying action mechanism would be beneficial for cases with predisposing conditions. As a

similar molecule to metformin, a novel OHA was introduced to medical practice [4]. It was newly developed for tetrahydrotriazine-containing drug [5]. Its characteristic aspect includes a triazine ring with cyclic small molecule [6]. This novel OHA has been Imeglimin as the brand name Twymeeg [7]. It seems to have dual mechanism of insulin for increasing secretion and decreasing resistance of beta cell [8]. Some clinical studies were conducted, resulting in clinical efficacy for improving glucose variability [9]. Authors and coresearchers have continued clinical research for diabetes, chronic kidney disease (CKD), atherosclerotic cardiovascular disease (ASCVD) and non-communicable disease (NCD) [10, 11]. We have shown some reports of general perspectives and case reports concerning Twymeeg [12,13]. Among our actual diabetic practice, one elderly patient with T2D showed clinical efficacy of Twymeeg. General progress of the case with some perspectives would be described in current report.

Case Presentation

Past History

The case is 93-year-old female, who had not shown remarkable health problems in her eighties. She had a compression fracture of the spine in Jan 2019. Since then, she was pointed out to have gastro esophageal reflux disease (GERD) and mild cognitive impairment (MCI) starting the prescription of Lansoprazole 15 mg and Mosapride citric acid 5 mg/day. In addition, she has mild

constipation and has been taking Magnesium Oxide 330-660 mg/day. She was hospitalized with a femoral neck fracture in Mar 2020 and subsequently suffered from pneumonia and was treated. Otherwise, hypertension and dyslipidemia were not pointed out so far.

History and Physicals

When her blood test was conducted in Nov 2021, her HbA1c was 6.6%. After that, HbA1c increased to 7.0% in Jan 2022. Consequently, Linagliptin 5mg /day was started (Figure 1). She showed gradual appetite loss from March 3, 2022. Her verbal response was not satisfactory, when she was called out on March 8. Blood pressure was rather high as 168/96 mmHg, and then she was transferred to our hospital.

pg (27-33), MCHC 31.9 g/dL (31-36), Plt $17.4 \times 10^4 /\mu\text{L}$. Chest X-ray revealed negative acute abnormality, and electrocardiogram (ECG) showed ordinary sinus rhythm (OSR) without remarkable ST-T changes.

Clinical Course

Magnetic Resonance Imaging (MRI) and magnetic resonance angiography (MRA) for the brain was performed on the same day of admission. As a result, MRI Diffusion-weighted imaging (DWI) showed rather small lacunar infarction in the white matter areas of bilateral frontal lobes. In MRA, bilateral MCA and PCA ends were poorly visualized. From these findings, bilateral subacute lesions may be present which are possible related with current symptoms.

As a treatment, Ozagrel Sodium (Xanbon) 80 mg was administered twice by drip infusion. This actual therapy relieved the symptoms to some degree. Regarding diabetes, Twymeeg 2000 mg/day was started, and blood C-peptide value for fasting was 1.4 ng/mL (0.8-2.5). As a factor related to cardiovascular disease (CVD), NT-proBNP 155 pg/mL (0-125) was almost normal range. After administration of Twymeeg, diabetic markers were HbA1c 6.2% and blood glucose 149 mg/dL, which were decreased from March (Figure 1). Consequently, diabetic situation of this case seemed to be improved in rather short period.

Ethical Standards

This investigation is complied with the standard ethics of the Helsinki Declaration. The comment is also complied with personal information protection act in Japan. Current principle has been performed accompanied with ethical principles for medical practice and research including human subjects. The guidelines have been from public announcement of two Ministries of Japan. They are the Ministry of Health, Labour and Welfare [MHLW] and the Ministry of Education, Culture, Sports, Science Technology [MEXT]. The authors and et al. have established our ethical committee for this investigation. It exists in Sakamoto hospital, including several professionals. They are the director of the hospital, surgeon, physicians, nurse, pharmacist, dietician and also legal professional. All of the members discussed fully the issue and agreed for current protocol. The informed consent was obtained from current case as the written style of the document.

Discussion

Imeglimin has been a topic for novel OHA that is currently developed in clinical practice [14]. Its mode of action would be from improved mitochondrial function for beta cells. The mechanism includes increasing insulin secretion, decreasing insulin resistance and lowering blood glucose values. When taking imeglimin for 2000-3000 mg/day for 24 weeks, reduction of HbA1c would be 0.5-1.0% (6-11 mmol/mol) as monotherapy, and

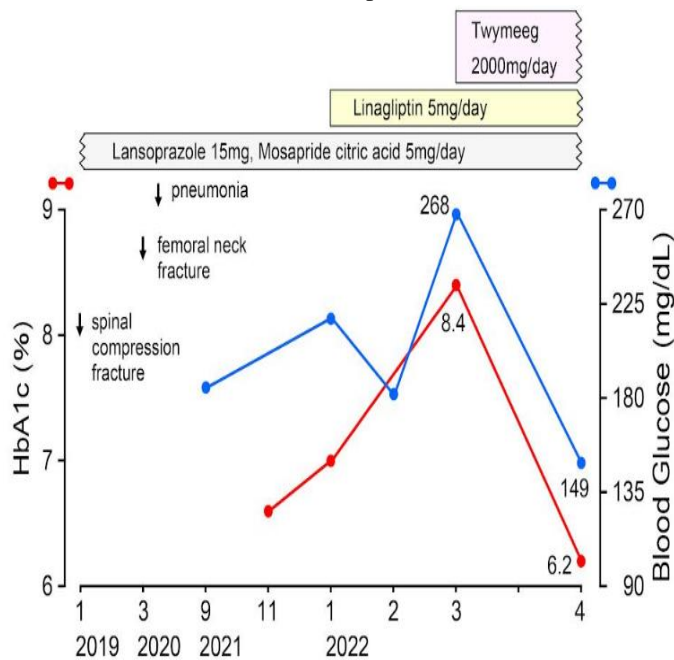


Figure 1: Clinical progress of the case.

Regarding her physical examination on admission, the consciousness is slightly vague with slower vocal response. Vital signs showed BP 183/105 mmHg, pulse 102 /min, and SpO2 98%. There were no significant changes in the heart, lungs, or abdomen, and neurological examination was unremarkable. She did not have the symptom of apparent hemiparesis.

Laboratory Examinations

The results of biochemical tests on Mar 8 were in the following. They are HbA1c 8.4%, blood glucose 268 mg/dL, AST 14 U/L, ALT 11 U/L, ALP 116 U/L (38-113), r-GT 10 U/L, TP 7.4 g/dL, Alb 3.2 g/dL, Uric Acid 6.3 mg/dL, BUN 21.1 mg/dL, Cre 0.42 mg/dL, HDL 45 mg/dL, LDL 67 mg/dL, TG 88 mg/dL, T-Cho 130 mg/dL, WBC 4800 μL , RBC $4.20 \times 10^6 /\mu\text{L}$, Hb 13.0 g/dL, Ht 40.8 %, MCV 97 fL (80-98), MCH 31.0

about 0.6% (7 mmol/mol) for add-on therapy by metformin or sitagliptin against T2D patients [15]. The adverse effect was mainly gastrointestinal discomfort. The evaluation for the position of imeglimin will be conducted among various pharmacological T2D therapy, associated with long-term cardiovascular effects and safety.

In this case, administration of imeglimin showed a marked improvement in HbA1c in 1 month. The medications taken by the case were linagliptin (Tragenta) as Dipeptidyl Peptidase-4 inhibitor (DPP-4i) and imeglimin (Twymeeg). Several trials for OHA of Imeglimin have been conducted so far. They are Trials of IMeglimin for Efficacy and Safety (TIMES) 1, 2, 3. Among them, TIMES 2 reported clinical efficacy for Imeglimin monotherapy or combination therapy [16]. These results were reported in the following. Monotherapy of imeglimin was 0.46%, and combination therapy as OHA and injection showed that sulfonyl urea (SU) 0.56%, glinide agents 0.70%, α -glucosidase inhibitors 0.85%, biguanide agents 0.67% and Sodium-glucose co-transporter 2 inhibitors (SGLT2i) 0.57%.

As the related data with this case, DPP-4i showed remarkable level as 0.92% and glucagon-like peptide-1 receptor agonist (GLP-1RA) showed slight level as 0.12% [16]. The pharmacological mechanism of DPP-4i vs GLP-1RA has common pathway, but both clinical effects were different as 0.92% vs 0.12%. For reference, combined therapy with insulin showed 0.63% that was in the middle degree of GLP-1RA and DPP-4i [17]. From these data of TIMES 2 and 3, pharmacological action difference may be from specific imeglimin function mechanism via mitochondria pathway metabolism.

For basic research for rodent models, some significant efficacies on mitochondria have been investigated [18]. Imeglimin was pointed out to have some mechanism via mitochondria. It shows the function of increasing muscle glucose uptake and decreasing hepatic glucose production, which are both in vivo and in vitro. Imeglimin would decrease beta cell death, increase insulin secretion, but these mechanism remains unclear whether insulin dependent or not.

For radiological findings of this case, MRI showed high signal under the cortex of bilateral brain by DWI [19]. Furthermore, related decrease situation in apparent diffusion coefficient (ADC) was found [20]. Right and left lesions are suggested to be at different period. MRA shows mild stenosis of the internal carotid arteries on both sides, uneven signal of the middle cerebral artery, and poor peripheral visualization. From the above, lacunar infarction has been suspected in both hemispheres of the cerebrum [21].

Current case has received the treatment of Ozagrel sodium. Ozagrel has been introduced to clinical practice as a thromboxane A2 synthesis inhibitor [22]. It is used for an anti-platelet agent, and effective for improving cerebral ischemic

symptoms [23]. For lacunar cerebral infarction, the efficacy of Ozagrel Sodium (Xanbon) was studied [24]. The protocol included 82 cases with lacunar cerebral infarction and T2D, and comparison of clinical effect was conducted between Ozagrel+atorvastatin group and atorvastatin single group. Several biomarkers were investigated such as activities of daily living (ADL) score, National Institutes of Health stroke scale (NIHSS) score, inflammatory factors, macrophage migration inhibitory factor (MIF) levels and others. The result showed the effective ratio as 94% vs 80%, in the former and latter group, respectively.

Some limitations are present in this report. It shows only one case with efficacy of imeglimin. The case is very elderly female, which possibly has non-apparent medical problems before. For remarkable effects, some other factors may be involved in clinical progress. The future course of the case will be followed up. In summary, a diabetic elder case was presented with satisfactory effect of imeglimin. This report would be expected to contribute diabetic research and practice.

Conflict Of Interest

The authors declare no conflict of interest.

Funding

There was no funding received for this paper.

References

1. Perreault L, Skyler JS, Rosenstock J. Novel therapies with precision mechanisms for type 2 diabetes mellitus. *Nat Rev Endocrinol*. 2021; 17: 364-377.
2. American Diabetes Association; Standards of Medical Care in Diabetes—2022 Abridged for Primary Care Providers. *Clin Diabetes*. 2022; 40: 10-38.
3. ADA Professional Practice Committee. 9. Pharmacologic Approaches to Glycemic Treatment: Standards of Medical Care in Diabetes, 2022 *Diabetes Care* 2022; 45: S125-S143.
4. Theurey P, Vial G, Fontaine E, Monternier PA, Fouqueray P, Bolze S, Moller DE, Hallakou-Bozec S. et.al. Reduced lactic acidosis risk with Imeglimin: Comparison with Metformin. *Physiol Rep*. 2022; 10: e15151.
5. Giruzzi M. Imeglimin. *Clin Diabete*. 2021; 39: 439-440.
6. Yendapally R, Sikazwe D, Kim SS, Ramsinghani S, Fraser-Spears R, Witte AP, La-Viola B, et.al. A review of phenformin, metformin, and imeglimin. *Drug Dev Res*. 2020; 81: 390-401.
7. Mima A. Mitochondria-targeted drugs for diabetic kidney disease. *Heliyon*. 2022; 8: e08878
8. Shah N, Abdalla MA, Deshmukh H, Sathyapalan T. Therapeutics for type-2 diabetes mellitus: a glance at the recent inclusions and novel agents under development for use in clinical practice. *Ther Adv Endocrinol Metab*. 2021; 12: 20420188211042145.
9. Dubourg J, Ueki K, Grouin JM, Fouqueray P. Efficacy and safety of imeglimin in Japanese patients with type 2 diabetes: a 24-week, randomized, double-blind, placebo-controlled, dose-ranging phase 2b trial. *Diabetes Obes Metab* 2021; 23: 800-810

10. Miyashiro H, Bando H, Kato Y, Yamashita H And Kato Y. Improved Glucose Variability of Continuous Glucose Monitoring (CGM) By Intake of Japanese Healthy Tofu as Low Carbohydrate Diet (LCD). *Int J Endocrinol Diabetes* 2022; 5: 136
11. Kondo N, Bando H, Hatakeyama S. Generalized edema and heart failure caused from hypothyroidism and ferrous agent for hypochromic anemia. *Endocrinol Metab Int J.* 2021; 9: 38-42.
12. Okada M, Bando H, Iwatsuki N, Ogawa T, Sakamoto K. Clinical Efficacy of Imeglimin (Twymeeg) for Elderly Patient with Type 2 Diabetes Mellitus (T2DM). *Asp Biomed Clin Case Rep.* 2022 Feb 21; 5: 33-37.
13. Bando H, Okada M, Iwatsuki N, Sakamoto K and Ogawa T. Improved HbA1c value by combined treatment of Dulaglutide and Imeglimin for patient with type 2 diabetes mellitus (T2DM). *Int J Endocrinol Diabetes* 2022; 5: 132
14. Hallakou-Bozec S, Vial G, Kergoat M, Fouqueray P, Bolze S, Borel AL, Fontaine E, Moller DE. et.al. Mechanism of action of Imeglimin: A novel therapeutic agent for type 2 diabetes. *Diabetes Obes Metab.* 2021; 23: 664-673.
15. Johansson KS, Brønden A, Knop FK, Christensen MB. Clinical pharmacology of imeglimin for the treatment of type 2 diabetes. *Expert Opin Pharmacother.* 2020; 21: 871-882.
16. Dubourg J, Fouqueray P, Quinslot D, Grouin JM, Kaku K. Long-term safety and efficacy of imeglimin as monotherapy or in combination with existing antidiabetic agents in Japanese patients with type 2 diabetes (TIMES 2): A 52-week, open-label, multicentre phase 3 trial. *Diabetes Obes Metab.* 2021.
17. Reilhac C, Dubourg J, Thang C, Grouin JM, Fouqueray P, Watada H. Efficacy and safety of imeglimin add-on to insulin monotherapy in Japanese patients with type 2 diabetes (TIMES 3): A randomized, double-blind, placebo-controlled phase 3 trial with a 36-week open-label extension period. *Diabetes Obes Metab.* 2022; 24: 838-848
18. Konkwo C, Perry RJ. Imeglimin: Current Development and Future Potential in Type 2 Diabetes. *Drugs.* 2021; 81: 185-190.
19. Taouli B, Beer AJ, Chenevert T, Collins D, Lehman C, Matos C, Padhani AR, Rosenkrantz AB, Shukla-Dave A, Sigmund E, Tanenbaum L, Thoeny H, Thomassin-Naggara I, Barbieri S, Corcuera-Solano I, Orton M, Partridge SC, Koh DM. et.al. Diffusion-weighted imaging outside the brain: Consensus statement from an ISMRM-sponsored workshop. *J Magn Reson Imaging.* 2016; 44: 521-540.
20. Shen JM, Xia XW, Kang WG, Yuan JJ, Sheng L. The use of MRI apparent diffusion coefficient (ADC) in monitoring the development of brain infarction. *BMC Med Imaging.* 2011; 11: 2.
21. Fujita S, Hagiwara A, Otsuka Y, Hori M, Takei N, Hwang KP, Irie R, Andica C, Kamagata K, Akashi T, Kunishima Kumamaru K, Suzuki M, Wada A, Abe O, Aoki S. et.al. Deep Learning Approach for Generating MRA Images From 3D Quantitative Synthetic MRI Without Additional Scans. *Invest Radiol.* 2020; 55: 249-256.
22. Loo MH, Egan D, Vaughan ED Jr, Marion D, Felsen D, Weisman S. et.al. The effect of the thromboxane A2 synthesis inhibitor OKY-046 on renal function in rabbits following release of unilateral ureteral obstruction. *J Urol.* 1987; 137: 571-576.
23. Mesitskaya DF, Syrkin AL, Aksenova MG, Zhang Y, Zamyatnin AA Jr, Kopylov PY. et.al. Thromboxane a Synthase: A New Target for the Treatment of Cardiovascular Diseases. *Cardiovasc Hematol Agents Med Chem.* 2018; 16: 81-87.
24. Yu Y, Wang L, Zhu X, Liu YF, Ma HY. Sodium ozagrel and atorvastatin for type 2 diabetes patients with lacunar cerebral infarction. *World J Diabetes.* 2021; 12: 2096-2106.