

## CASE REPORT

# A Case of Well Leg Compartment Syndrome After Robot-assisted Laparoscopic Prostatectomy : With Review

Yuki Endo<sup>a</sup>, Jun Akatsuka<sup>a</sup>, Kosuke Kuwahara<sup>b</sup>, Suisen Takasaki<sup>a</sup>, Hayato Takeda<sup>a</sup>, Masato Yanagi<sup>a</sup>, Yuka Toyama<sup>a</sup>, Hikaru Mikami<sup>a</sup>, Tsutomu Hamasaki<sup>a</sup>, and Yukihiko Kondo<sup>a</sup>

<sup>a</sup>Department of Urology, Nippon Medical School, Tokyo, Japan, <sup>b</sup>Department of Plastic, Reconstructive and Aesthetic Surgery, Nippon Medical School, Tokyo, Japan

**Abstract :** Robot-assisted laparoscopic prostatectomy (RALP) for prostate cancer was introduced in 2000 and rapidly gained popularity. The Da Vinci Surgical System<sup>®</sup> can ensure improved local control of cancer and fewer perioperative complications. However, RALP is performed in the steep-Trendelenburg position (a combination of lithotomy and head-down tilt position/Lloyd-Davies position) to obtain a good surgical view, and as a result, well leg compartment syndrome (WLCS) can become a serious complication of RALP. Here, we report a case of WLCS after RALP. A 75-year-old man underwent surgery for prostate cancer and immediately complained of pain and numbness after surgery. The pressure of the four leg compartments increased. Ultimately, we diagnosed the patient with WLCS in his right leg, and an emergency fasciotomy was performed. He completely recovered with no permanent disability and was discharged one month after rehabilitation. Although WLCS after RALP is a rare and severe complication, the patient recovered completely with early diagnosis and intervention. Measuring the compartment pressure is useful when the patient is drowsy immediately after recovery from anesthesia. Preventing WLCS requires identifying this condition as a potential complication of RALP and all urologic surgeries performed in the lithotomy position. *J. Med. Invest.* 69:145-147, February, 2022

**Keywords :** Robot-assisted Laparoscopic radical prostatectomy, well leg compartment syndrome, adverse event

## INTRODUCTION

Robot-assisted laparoscopic prostatectomy (RALP) for prostate cancer has rapidly gained popularity over recent years (1). The Da Vinci Surgical System<sup>®</sup> can ensure improved local control of cancer and fewer perioperative complications, such as bleeding and urinary incontinence. However, it can cause complications such as well leg compartment syndrome (WLCS), which is rarely observed with other surgical procedures.

WLCS is a compartment syndrome without trauma or preoperative blood circulation disorder that causes tissue ischemia or necrosis following increased pressure in the lower leg compartment. The resulting injury often leads to disfigurement, amputation, and permanent disability and is fatal in approximately 6% of the cases (2). One of the causes of WLCS is a steep-Trendelenburg position (STP), a position peculiar in RALP surgery, and STP is a combination of lithotomy and head-down tilt position (approximately 30°). In this study, we report a case of WLCS in a 75-year-old patient who underwent RALP to treat prostate cancer and discuss the diagnostic, therapeutic, and preventative approaches for WLCS.

## PATIENT AND METHODS

A 75-year-old man was screened for prostate cancer. Prostate biopsy revealed adenocarcinoma of the prostate (clinical TNM, cT1cN0M0 Jewett B0). The patient was referred to our

department for surgical resection. Elective RALP was planned at the Nippon Medical School Hospital, Tokyo, Japan. He underwent transurethral resection for benign prostatic hyperplasia (TURP) 10 years ago and was on medication for hypertension. His height, body weight, and body mass index were 166 cm, 65.0 kg, and 23.5 kg/m<sup>2</sup>, respectively. The patient was a non-smoker. The surgery was performed under a combination of general and epidural anesthesia. His legs were protected with elastic stockings and intermittent pneumatic compression to prevent deep vein thrombosis during surgery.

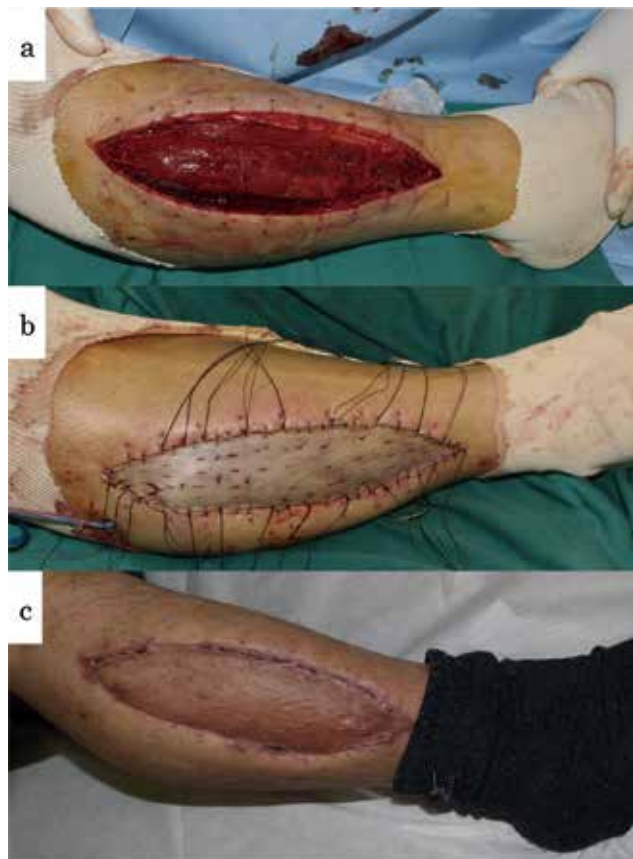
The surgery was technically challenging because the prostate volume was large (64 mL), and severe adhesion around the prostate and urethra was observed due to the previous TURP. He was placed in a combined steep-Trendelenburg/Lloyd-Davies position (head-down tilt by 28°), along with a lithotomy position for 340 min, and the surgery lasted for 280 min. Vital signs remained stable throughout the surgery. Systolic blood pressure was maintained at 80 mmHg. During the surgery, we did not check the appearance or compression of the lower legs. Postoperative anticoagulation therapy was not administered. After the surgery, the patient remained in the intensive care unit. He immediately complained of pain in both legs. The creatinine phosphokinase level immediately after surgery was 741 IU/L (reference range : 40–250). We monitored the patient and administered analgesics because the dorsal foot artery was palpable bilaterally.

The following day, the pain worsened, and the patient experienced numbness, motor and sensory disorders, and right leg swelling. The creatinine phosphokinase level increased to 38,650 IU/L. We consulted the Department of Emergency and Critical Care Medicine for further management. The pressure in the four compartments of the right leg was increased (anterior, 56 mmHg ; lateral, 70 mmHg ; superficial posterior, 50 mmHg ; and deep posterior, 56 mmHg). WLCS of the right leg was diagnosed, and emergency fasciotomy was performed (Figure 1a). The

Received for publication October 14, 2021 ; accepted December 28, 2021.

Address correspondence and reprint requests to Yuki Endo, MD, PhD, Department of Urology, Nippon Medical School, 1-1-5 Sendagi, Bunkyo-ku, Tokyo 113-8603, Japan and Fax : +81-3-3822-2131.

symptoms of the right leg started to improve the next day. Five days after fasciotomy, split-thickness skin grafting from the right groin was performed for wound closure (Figure 1b). Subsequently, rehabilitation continued for one month, and the patient was discharged after complete recovery (Figure 1c).



**Figure 1.** Photograph of the right leg of the patient at different stages of treatment.

a : Right leg after fasciotomy.

b : Right leg after split-thickness skin grafting.

c : Right leg one month after skin grafting during discharge.

## DISCUSSION

WLCS is a rare but serious complication of surgery performed in the lithotomy position (2), with an estimated incidence of one in 3500 cases (0.029%) (3). To the best of our knowledge, WLCS in RALP has only been reported in 15 cases worldwide, and this is the 16<sup>th</sup> case (Table 1). The incidence rate of WLCS in RALP from the UK was 0.29% (9 of 3,110) (4), which is approximately 10 times higher than that in other urology surgeries. In our hospital, RALP was introduced in 2014, and we have experienced only one case of WLCS (this case) out of 437 cases of RALP (0.23%) in the STP in six years. This rate was almost similar to that mentioned in previous reports.

STP is a position in which the upper body is further lowered from the lithotomy position. Most of the body weight is supported by the lower leg muscles. As a result, the pressure on the lower leg muscles increases; thus, the steeper the angle of STP, the greater the pressure on the lower limb muscles. STP has a great influence on the increased occurrence of WLCS; however, the true association between RALP and WLCS is unknown.

The initial diagnosis of WLCS is entirely clinical. Patients with WLCS typically experience severe unremitting lower leg pain within 24 h of recovery from anesthesia (5). Passive dorsiflexion of the toes and ankles exacerbates the pain, and active dorsiflexion of the ankles and toes may be impossible due to pain and subsequent impairment of peroneal nerve function. Signs of neurologic injury (paresthesia, numbness, and foot drop) and vascular insufficiency are the late and ominous indicators of permanent injury. Measuring the compartment pressure is not recommended for routine diagnosis because it is likely to delay limb-saving treatment, and immediate (within one h) four-compartment fasciotomy in the symptomatic limb should be undertaken (6). If the intervention is delayed, the incidence of permanent disability after developing WLCS ranges from 30%–100% (7), and approximately 6% of the cases are fatal (2). Our patient experienced severe pain with numbness in both legs. As he recovered from general anesthesia with unclear consciousness, compartment pressure was measured, and intervention was performed on the right leg, and conservative treatment was performed on the left leg. Due to the diagnosis of WLCS in its early phase by measuring the compartment pressure, the patient recovered completely with no permanent disability.

However, several reports insisted on compartment pressure measurement for diagnosis and indicated that immediate fasciotomy should be performed if the compartment pressure is

**Table 1.** Past case report of WLCS with RALP

author	year	journal	cases	fasciotomy	permanent disability	dorsal artery	max CPK(IU)	max compartment pressure (mmHg)
Raman S.R.	2009	Journal of Robotic surgery	1	performed	none	N/A	N/A	N/A
Rosevere H.M.	2010	Journal of EndoUrology	1	performed	dorsiflex to ~ 90°	N/A	N/A	114
Keene R.	2010	Orthopedic	1	N/A	N/A	N/A	N/A	N/A
Araki M.	2013	Jap. Journal of Urol. Surg.	1	performed	none	palpable	N/A	90
Pridgeon S.[4]	2013	BJU. Int.	9	7/9 ※ 1	N/A	N/A	N/A	not performed
R.H. Yahn	2013	Clinical Nuclear Medicine	1	N/A	N/A	N/A	N/A	N/A
Takechi K.	2017	Jap. Journal of anesthesiology	1	not performed	none	palpable	10560	not performed
Our case	2022	Journal of Medical Investigation	1	performed	none	palpable	38650	70

※ 1 : fasciotomy was performed in 7 out of 9 cases.

>30–55 mmHg (8, 9). In our case, the compartment pressure was measured (50–70 mmHg), and each compartment pressure was >30 mmHg. Hence, we decided to perform a four-compartment fasciotomy within the next 30 min. This urgent intervention may have resulted in a full recovery. Therefore, measuring the compartment pressure is required when diagnosing WCLS in patients with unclear consciousness.

WLCS is related to ischemia-reperfusion injury of the lower limbs after placing the patients in a prolonged lithotomy position. Hemodynamic changes are compounded by an increased compartment pressure associated with the lower limb elevation, increasing steadily over time (10). The risk factors mentioned in the literature are shown in Table 2 (2, 4, 10, 11). Our patient had several risk factors, such as male sex, pelvic surgery, operation time >4 h, placement in STP, muscular physique (muscle training every day), and calf compression.

As prolonged surgery (>4 h) is a risk factor for WLCS, it is recommended to place the legs at a level lower than the heart for a minimum of 15 min after each 4-h interval, when leg elevation is required for >4 h (6). In this case, we did not reposition the patient's legs every four h. It is essential for doctors, nurses, and medical technicians to jointly develop a protocol to check the lower limb pressure at regular intervals. Although the use of thromboprophylaxis, such as stockings or intermittent air pressure on the calf muscle, is a risk factor for WLCS, these should be continued because the risk of venous thromboembolism is likely to be greater than that of WLCS (6).

WLCS in the legs after RALP is a rare but severe complication that requires early diagnosis and intervention. Measuring compartment pressure is useful when the patient is drowsy immediately after recovery from anesthesia. Prevention of WLCS requires identifying this condition as a potential complication of RALP and all urologic surgeries performed in the lithotomy position.

CONFLICT OF INTEREST

The authors declare no conflicts of interest

ACKNOWLEDGEMENT

none

REFERENCES

1. Cao L, Yang Z, Qi L, Chen M : Robot-assisted and laparoscopic vs open radical prostatectomy in clinically localized prostate cancer : perioperative, functional, and oncological outcomes. *Medicine (Baltimore)* 98 : e15770, 2019
2. Simms MS, Terry TR : Well leg compartment syndrome after pelvic and perineal surgery in the lithotomy position. *Postgrad Med J* 81 : 534-536, 2005
3. Mumtaz FH, Chew H, Gelister JS : Lower limb compartment syndrome associated with the lithotomy position : concepts and perspectives for the urologist. *BJU Int* 90 : 792-799, 2002
4. Pridgeon S, Bishop CV, Adshead J : Lower limb compartment syndrome as a complication of robot-assisted radical prostatectomy : the UK experience. *BJU Int* 112 : 485-488, 2013
5. Beraldo S, Dodds SR : Lower limb acute compartment syndrome after colorectal surgery in prolonged lithotomy position. *Dis Colon Rectum* 49 : 1772-1780, 2006
6. Stoop M, Carlson GL : Well Leg Compartment Syndrome after prolonged pelvic surgery : launch of United Kingdom and Ireland Multidisciplinary Clinical Guidelines. *Dis Colon Rectum* 62 : 1150-1152, 2019
7. Christoffersen JK, Hove LD, Mikkelsen KL, Krogsgaard MR : Well leg compartment syndrome after abdominal surgery. *World J Surg* 41 : 433-438, 2017
8. Masten FA 3rd : Compartmental syndrome. An unified concept. *Clin Orthop Relat Res* 8 : 14, 1975
9. Mubarak SJ, Owen CA, Hargens AR, Garetto LP, Akeson WH : Acute compartment syndromes, diagnosis and treatment with the aid of the wickcatheter. *J Bone Joint Surg Am* 60 : 1091-1095, 1978
10. Chase J, Harford F, Pinzur MS, Zussman M : Intraoperative lower extremity compartment pressures in lithotomy-positioned patients. *Dis Colon Rectum* 43 : 678-680, 2000
11. Gill M, Fligelstone L, Keating J, Jayne DG, Renton S, Shearman CP, Carlson GL : Avoiding, diagnosing and treating well leg compartment syndrome after pelvic surgery. *Br J Surg* 106 : 1156-1166, 2019

Table 2. The risk factors for perioperative compartment syndrome as enumerated in each article.

** Authors Factors **	Simms M.S. <i>et. al.</i> [2]	Pridgeon S. <i>et. al.</i> [4]	Stoop M. <i>et. al.</i> [6]	Gill M. <i>et. al.</i> [11]	Our case
pelvic surgery			○	○	○
young			○	○	
men			○		○
vascular disease	○	○	○	○	
operation time>4 h	○	○	○	○	○
steep-Trendelenburg		○	○	○	○
obesity	○	○	○	○	
masculine	○		○		○
early learning curve		○			
perioperative hypotension	○			○	
blood loss	○			○	
calf compression				○	○