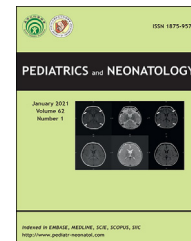


Available online at www.sciencedirect.com

ScienceDirect

journal homepage: <http://www.pediatr-neonatol.com>

Short Communication

Severe COVID-19 during pregnancy and the subsequent premature delivery



Cristina Fernandez-Garcia ^{a,*}, Alicia Montaner-Ramon ^a,
 Susana Hernandez-Perez ^a, Fatima Camba-Longueira ^a,
 Carmen Ribes-Bautista ^a, Marie Antoinette Frick ^b,
 Felix Castillo-Salinas ^a

^a Newborn Department, Vall d'Hebron University Hospital, Spain

^b Pediatric Infectious Diseases Unit, Vall d'Hebron University Hospital, Spain

Received Jun 11, 2020; received in revised form Jul 8, 2020; accepted Sep 16, 2020
 Available online 19 September 2020

1. Introduction

Coronavirus disease 2019 (COVID-19), which is caused by a novel severe acute respiratory syndrome coronavirus 2 (SARS-CoV-2), was declared a pandemic in January 2020. Although most of the cases in pregnant women are mild, there are reports of increasing severe infection in pregnancy. Only a few case of SARS-CoV-2 infection in preterm neonates delivered by mothers with COVID-19 have been reported till date.

The possibility of *in utero* transmission of SARS-CoV-2 is highly controversial.^{1,2} While SARS-CoV-2 has been detected in several neonates by reverse transcription-polymerase chain reaction (RT-PCR) of nasopharyngeal swabs collected in the early hours or days of life,^{3,4} the reliability of these swabs is under scrutiny, as there is a chance of contamination by coronavirus-infected maternal body fluids.

2. Methods

We report the cases of three premature babies delivered by two mothers with severe COVID-19 pneumonia, whose condition deteriorated to the point that necessitated the use of mechanical ventilation on the mothers as well as accelerated child delivery of the mothers. All the babies were admitted to level III neonatal intensive care unit at Vall d'Hebron University Hospital in Barcelona, Spain in March 2020. Clinical management was based on national guidelines and hospital protocols. The babies were separated from their mother and placed on strict isolation as soon as they were born. They had no contact with their close family members unless they were asymptomatic and tested negative to SARS-CoV-2.

3. Results

Patient 1 was born to a 34-year-old woman with severe respiratory failure and HELLP syndrome, who required admission to the intensive care unit and mechanical ventilation. Her condition deteriorated gradually and she was delivered of her baby, a girl weighing 1465 g, by cesarean section at the gestational age of 30 weeks and 5 days. The clinical features were consistent with those of an

* Corresponding author. Vall d'Hebron University Hospital, Universidad Autónoma de Barcelona (UAB), Passeig de la Vall d'Hebron, 119-129 08035, Barcelona, Spain.

E-mail address: c.fernandez@vhebron.net (C. Fernandez-Garcia).

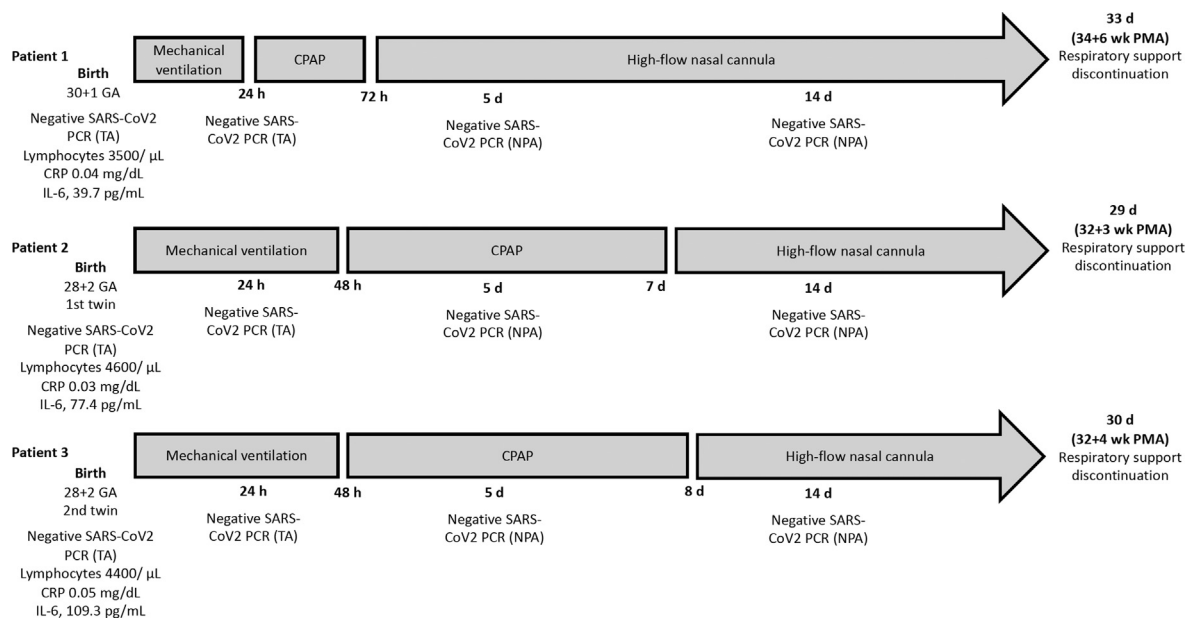


Figure 1 Respiratory support and test results. GA-gestational age in weeks; SARS-CoV-2-severe acute respiratory syndrome coronavirus 2; PCR-polymerase chain reaction; CRP-C-reactive protein; IL-6-interleukin 6; TA-tracheal aspirate; NPA-nasopharyngeal aspirate; CPAP-continuous positive airway pressure; PMA-postmenstrual age.

uncomplicated preterm delivery, although the baby required mechanical ventilation for the first 24 h of life due to maternal sedation.

Patients two and three were twins (both girls) born by cesarean to a 40-year-old woman with severe hypoxia. The babies had a gestational age of 28 weeks and 2 days and weighed 990 g and 1000 g, respectively. They required intubation because of maternal sedation. They received surfactant treatment and were extubated at 48 h of life.

All the babies (3) had an uneventful course and showed no signs or symptoms of COVID-19. RT-PCR of tracheal aspirates at birth and 24 h of life and nasopharyngeal swabs at 5 and 14 days of life were negative for SARS-CoV-2 (Fig. 1).

4. Discussion

There have been very few reports of preterm delivery in mothers with COVID-19 and most babies have tested negative to SARS-CoV-2.^{3,4} In the few reported neonates who tested positive to SARS-CoV-2 via PCR, there is no evidence of *in utero* transmission, since infection in the immediate neonatal period could not be completely excluded.^{5,6}

Preterm delivery was required in the three cases described in this report, since the mothers developed severe COVID-19 pneumonia. There was no evidence of *in utero* transmission, such that all the babies (3) tested negative to SARS-CoV-2 immediately after birth and at 24 h, 5, and 14 days of life. Apart from requiring mechanical ventilation due to maternal sedation, the babies had an uneventful course and showed no signs or symptoms of COVID-19.

Knowledge of how COVID-19 affects newborns and pregnant women is limited. Until multicenter studies are conducted, it is essential to share experiences of case reports and series in order to improve our understanding of the effects of this emerging disease on newborns and their mothers, in the interim.

Declaration of competing interest

None.

References

- Mimouni F, Lakshminrusimha S, Pearlman SA, Raju T, Gallagher PG, Mendlovic J. Perinatal aspects on the covid-19 pandemic: a practical resource for perinatal-neonatal specialists. *J Perinatol* 2020;40:820–6.
- Perlman J, Oxford C, Chang C, Salvatore C, Di Pace J. Delivery room preparedness and early neonatal outcomes during COVID-19 pandemic in New York city. *Pediatrics* 2020;146:e20201567.
- Zeng L, Xia S, Yuan W, Yan K, Xiao F, Shao J, et al. Neonatal early-onset infection with SARS-CoV-2 in 33 neonates born to mothers with COVID-19 in Wuhan, China. *JAMA Pediatr* 2020;174:722–5.
- Khan S, Jun L, Nawsherwan, Siddique R, Li Y, Han G, et al. Association of COVID-19 with pregnancy outcomes in health-care workers and general women. *Clin Microbiol Infect* 2020;26:788–90.
- Alzamora MC, Paredes T, Caceres D, Webb CM, Valdez LM, La Rosa M. Severe COVID-19 during pregnancy and possible in vertical transmission. *Am J Perinatol* 2020;37:861–5.
- Piersigilli F, Carkeek K, Hocq C, van Grambezen B, Hubinont C, Chatzis O, et al. COVID-19 in a 26-week preterm neonate. *Lancet Child Adolesc Health* 2020;4:476–8.