

Oropharyngeal dysphagia in dermatomyositis: Associations with clinical and laboratory features including autoantibodies

著者	Mugii Naoki, Hasegawa Minoru, Matsushita Takashi, Hamaguchi Yasuhito, Oohata Sacihe, Okita Hirokazu, Yahata Tetsutaro, Someya Fujiko, Inoue Katsumi, Murono Shigeyuki, Fujimoto Manabu, Takehara Kazuhiko
著者別名	麦井 直樹, 長谷川 稔, 松下 貴史, 濱口 儒人, 八幡 徹太郎, 染矢 富士子, 室野 重之, 藤本 学, 竹原 和彦
journal or publication title	PLoS ONE
volume	11
number	5
page range	e0154746
year	2016-05
URL	http://doi.org/10.24517/00064883

doi: 10.1371/journal.pone.0154746



RESEARCH ARTICLE

Oropharyngeal Dysphagia in Dermatomyositis: Associations with Clinical and Laboratory Features Including Autoantibodies

Naoki Mugii¹, Minoru Hasegawa^{2*}, Takashi Matsushita³, Yasuhito Hamaguchi³, Sachi Oohata¹, Hirokazu Okita¹, Tetsutarou Yahata¹, Fujiko Someya⁴, Katsumi Inoue⁴, Shigeyuki Muro⁵, Manabu Fujimoto⁶, Kazuhiko Takehara³

1 Department of Rehabilitation, Kanazawa University Hospital, Kanazawa, Ishikawa, Japan, **2** Department of Dermatology, Division of Medicine, Faculty of Medical Sciences, University of Fukui, Yoshida-gun, Fukui, Japan, **3** Department of Dermatology, Faculty of Medicine, Institute of Medical, Pharmaceutical and Health Sciences, Kanazawa University, Kanazawa, Ishikawa, Japan, **4** Division of Rehabilitation Science, Faculty of Medicine, Institute of Medical, Pharmaceutical and Health Sciences, Kanazawa University, Kanazawa, Ishikawa, Japan, **5** Department of Otorhinolaryngology/Head and Neck Surgery, Faculty of Medicine, Institute of Medical, Pharmaceutical and Health Sciences, Kanazawa University, Kanazawa, Ishikawa, Japan, **6** Department of Dermatology, Faculty of Medicine, University of Tsukuba, Tsukuba, Ibaraki, Japan

* minoruha@u-fukui.ac.jp



OPEN ACCESS

Citation: Mugii N, Hasegawa M, Matsushita T, Hamaguchi Y, Oohata S, Okita H, et al. (2016) Oropharyngeal Dysphagia in Dermatomyositis: Associations with Clinical and Laboratory Features Including Autoantibodies. PLoS ONE 11(5): e0154746. doi:10.1371/journal.pone.0154746

Editor: Masataka Kuwana, Nippon Medical School Graduate School of Medicine, JAPAN

Received: March 8, 2016

Accepted: April 18, 2016

Published: May 11, 2016

Copyright: © 2016 Mugii et al. This is an open access article distributed under the terms of the [Creative Commons Attribution License](https://creativecommons.org/licenses/by/4.0/), which permits unrestricted use, distribution, and reproduction in any medium, provided the original author and source are credited.

Data Availability Statement: Files containing voice samples may compromise the privacy of study participants and may not be shared publicly. These files are available upon request to the authors. All other relevant data are within the paper and its Supporting Information files.

Funding: This work was supported by funds for research on intractable diseases from the Ministry of Health, Labor, and Welfare of Japan (NM, MH, MF, KT). The funders had no role in study design, data collection and analysis, decision to publish, or preparation of the manuscript.

Abstract

Objective

Dysphagia develops with low frequency in patients with dermatomyositis. Our objective was to determine the clinical and laboratory features that can estimate the development of dysphagia in dermatomyositis.

Methods

This study included 92 Japanese patients with adult-onset dermatomyositis. The associations between dysphagia and clinical and laboratory features including disease-specific autoantibodies determined by immunoprecipitation assays were analyzed.

Results

Videofluoroscopy swallow study (VFSS) was performed for all patients with clinical dysphagia (n = 13, 14.1%) but not for patients without clinical dysphagia. Typical findings of dysphagia (pharyngeal pooling, n = 11 and/or nasal regurgitation, n = 4) was detected by VFSS in all patients with clinical dysphagia. Eleven patients with dysphagia (84.6%) had anti-transcription intermediary factor 1γ (TIF-1γ) antibody. By univariate analysis, the average age and the male to female ratio, internal malignancy, and anti-TIF-1γ antibody were significantly higher and the frequency of interstitial lung diseases and manual muscle testing (MMT) scores of sternomastoid and deltoid muscles were significantly lower in patients with dysphagia than in patients without dysphagia. Among patients with anti-TIF-1γ antibody,

Competing Interests: The authors have declared that no competing interests exist.

the mean age, the ratios of male to female and internal malignancy were significantly higher and mean MMT scores of sternomastoid muscle were significantly lower in patients with dysphagia compared with patients without dysphagia. By multivariable analysis, the risk of dysphagia was strongly associated with the existence of internal malignancy and anti-TIF-1 γ antibody and was also associated with reduced scores of manual muscle test of sternomastoid muscle. Dysphagia was markedly improved after the treatment against myositis in all 13 patients.

Conclusion

These findings indicate that dysphagia can develop frequently in patients with internal malignancy, anti-TIF-1 γ antibody, or severe muscle weakness of sternomastoid muscle.

Introduction

Polymyositis (PM) and dermatomyositis (DM) are autoimmune connective tissue diseases characterized by symmetric proximal myositis. PM and DM are similar diseases, but DM can be distinguished from PM via the presence of specific skin lesion such as heliotrope rash or Gottron's papule/sign. Clinical manifestations of DM are heterogeneous and interstitial pneumonia and internal malignancy affect the prognosis.

Dysphagia has been reported to develop in 10 to 73% of patients with inflammatory myopathy during the clinical course, especially in inclusion body myositis [1–3]. The dysphagia in this disease primarily affects the skeletal muscle-activated oropharyngeal phase of swallowing. This may occur due to weakness of oropharyngeal, laryngeal, and esophageal musculature. Recognition of dysphagia is important, since dysphagia is associated with various clinical features such as nasal speech, hoarseness, regurgitation, nutritious deficits, aspiration pneumonia, impaired quality of life, and poor prognosis. It has been reported that dysphagia involvement is more frequent in patients with internal malignancy among patients with DM [4, 5].

Recent studies demonstrated that myositis-specific autoantibodies are associated with specific clinical phenotype [6]. Among them, antibodies against a 155-kd protein (anti-p155 Ab) and a 155/140-kd doublet (anti-155/140 Ab) have shown a significant association with malignancy in adult patients with DM [7–9]. Transcription intermediary factor 1 γ (TIF-1 γ) and TIF-1 α/γ have been considered to be the autoantigen target of these Abs, respectively [10]. A patient with DM who was positive for anti-TIF-1 γ Ab had 27-fold higher odds of having malignancy compared with a patient who was negative for the Abs [11]. On the other hand, pulmonary involvement is frequently seen in patients with anti-aminoacyl transfer RNA synthetase (ARS) Abs [12] or anti-melanoma differentiation-associated protein 5 (MDA-5) Ab [13, 14]. DM patients with anti-Mi-2 Abs typically do not have interstitial lung disease (ILD) or internal malignancy and have a good prognosis [15]. However, the association between autoantibodies and the involvement of dysphagia remains unclear. Furthermore, to our best knowledge, almost no studies have analyzed the associated clinical or laboratory features focused on dysphagia in DM.

In this study, we assessed the association between the oropharyngeal involvement and clinical or laboratory features including recently identified autoantibodies.

Materials and Methods

Patients

Ninety-two Japanese patients with DM (72 females and 20 males; age (mean \pm SD), 54.9 \pm 16.2 years) who visited Kanazawa University Hospital between January, 2004 and December, 2015 were included in this study. Eighty patients fulfilled the criteria of Bohan and Peter [16, 17], while the remaining 12 did not fulfil the criteria, but fulfilled Sontheimer's criteria [18], due to the absence of clinical muscle symptoms and presence of subsistent clinical skin eruptions. Mean disease duration was 9.7 \pm 14.9 months. At the time of evaluation, no patients were receiving oral prednisolone therapy and other immunosuppressive drugs.

Clinical assessment

Complete medical histories, physical examinations, and laboratory tests were conducted for all patients during the first visit, with limited evaluations during follow-up visits. The objective symptoms of pharyngeal pooling, nasal regurgitation, and nasal speech were evaluated by otorhinolaryngologists and speech therapists. The patients were diagnosed as having ILD according to the results of chest radiography, chest computed tomography, and pulmonary function testing. Serum Krebs von den Lungen-6 (KL-6) levels as a serum marker of ILD were determined by ELISA as described previously [19]. Presence of internal malignancy was carefully examined using computed tomography, gastrointestinal fiberscope, gallium scintigraphy and other procedures according to need. The medical ethics committee of Kanazawa University approved this study protocol (No. 961, An investigation of rehabilitation for dermatomyositis/polymyositis). An informed written consent was obtained from each patient.

Videofluoroscopy swallow study (VFSS)

The existence of dysphagia was confirmed by VFSS in patients with clinical dysphagia. A fluoroscopy unit (Siemens Polystar digital unit- Siemens AG, Erlangen, Germany) connected to a medical high definition medical quality videorecorder was used. Videofluoroscopy studies were performed in a lateral position with the patient in a seated position. The patient was asked to swallow a food and/or liquid bolus of high density (EZPaque 100% wpv) barium sulphate suspension. Images were acquired at 15 pulses/s.

Myositis disease activity assessment

To assess disease activity based on individual organ systems, the Myositis Disease Activity Assessment Visual Analogue Scales (MYOACT VAS) portion of the Myositis Disease Activity Tool [20] was used. The MYOACT assessment utilizes separate 100-mm VAS to gauge the physician's evaluation of disease activity in several discrete domains. Involvement of all non-muscle organ systems (constitutional, cardiac, pulmonary, gastrointestinal, skeletal, and cutaneous) was also evaluated using the composite extra-skeletal muscle VAS score. An additional VAS measure, the global VAS score, was used to rate overall disease activity.

Immunoprecipitation assays

Immunoprecipitation assays were performed to identify autoantibodies using extracts of the leukemia cell line, K562, as previously described [13]. Using this method, 23 of 92 patients were positive for anti-ARS Ab, 26 patients were positive for anti-TIF-1 γ Ab, 3 patients were positive for anti-Mi-2 Ab, 15 patients were positive for anti-MDA-5 Ab, 5 patients were positive for anti-SS-A (Ro60) Ab, 5 patients were positive for anti-U1 ribonucleoprotein (U1 RNP) Ab, and a patient was positive for anti-signal recognition particle (SRP) Ab. Four patients were

positive both for anti-ARS Ab and anti-SS-A Ab. One patient was positive both for anti-MDA-5 Ab and anti-U1 RNP Ab.

Statistical analysis

Statistical analysis was performed using Student's t test or Fisher's exact probability test. The relationship between the involvement of dysphagia and explanatory variables was analysed using multivariable analysis (logistic regression). Significant variables after univariate regression ($p < 0.15$) were entered into a stepwise multivariate model. Results are expressed as the OR with 95% CI. A p-value < 0.05 was considered indicative of statistical significance.

Results

Videofluoroscopy swallow study (VFSS)

We considered that 13 patients had clinical dysphagia by history taking and examination of otolaryngologists and speech therapists. To confirm the existence of dysphagia, VFSS was performed in these 13 patients and all patients showed the typical findings of dysphagia (pharyngeal pooling; $n = 11$ and/or nasal regurgitation; $n = 4$). Dysphagia was found at the pharyngeal phases, but not at oral stage or esophageal stage in all of these patients. A representative case of pharyngeal pooling is shown as [Fig 1A](#) and [S1 Fig](#). VFSS of a representative case of nasal pooling was also shown before and after treatment of DM ([Fig 1B](#) and [S2 Fig](#)). Before treatment, she showed nasal regurgitation at pharyngeal phases. This patient also developed nasal speech, probably due to the loss of pharyngo-oesophageal muscle tone. However, nasal regurgitation detected by VFSS and nasal speech were diminished after oral treatment of 40 mg/d prednisolone ([S2 Fig](#)). VFSS could not perform in any patients without clinical dysphagia.

Association between dysphagia involvement and clinical/laboratory features

Firstly, we examined the association between the frequency of dysphagia involvement and clinical or laboratory features by univariate analysis ([Table 1](#)). Most remarkable association was detected between dysphagia and the existence of anti-TIF-1 γ Ab or internal malignancy. Most patients with dysphagia had internal malignancy (84.6%) or anti-TIF-1 γ Ab (84.6%). And this frequency was significantly higher than that of patients without them (10.1% and 19.0%, respectively, $p < 0.0001$). Age and the frequency of male/female ratio were significantly higher in patients with dysphagia compared with patients without dysphagia ($p < 0.01$). The manual muscle testing (MMT) of neck (sternomastoid muscle) and shoulder (deltoid muscle) but not hip (iliopsoas muscle) was significantly lower in patients with dysphagia compared with patients without dysphagia ($p < 0.05$). The frequency of ILD was significantly lower in patients with dysphagia compared with patients without it ($p < 0.01$). Otherwise, there were no significant differences between the frequencies of any clinical/laboratory features. Thus, dysphagia was significantly more detected in aged or male patients, patients with internal malignancy, anti-TIF-1 γ Ab, and reduced MMT scores of sternomastoid and deltoid muscles or patients without ILD.

Association between dysphagia involvement and clinical/laboratory features in patients with anti-TIF-1 γ Ab

We also evaluated the difference of clinical/laboratory features between patients with or without dysphagia in DM patients with anti-TIF-1 γ Ab ([Table 2](#)). The mean age and the ratios of male to female and internal malignancy were significantly higher in patients with dysphagia

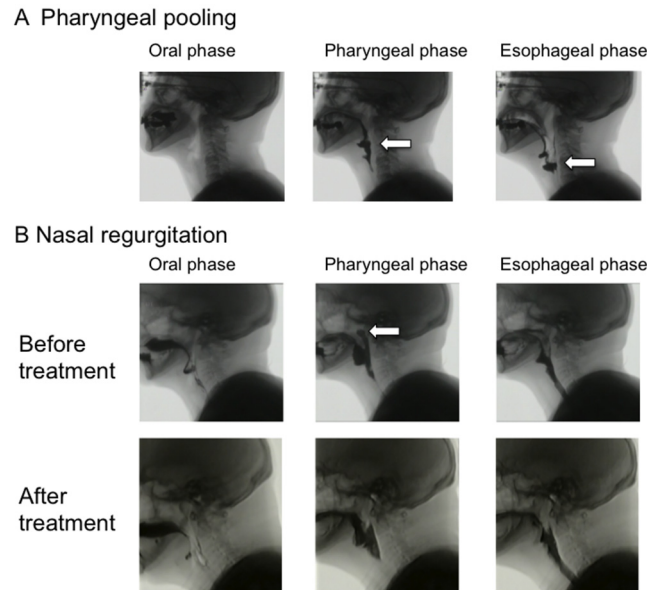


Fig 1. Videofluoroscopy swallow study (VFSS). Videoradiographic sequence in a patient with dermatomyositis (DM). A) Pharyngeal pooling is detected at both pharyngeal and esophageal phases. An arrow indicates abnormal pooling of imaging agent. B) Nasal regurgitation is detected at pharyngeal phases before treatment of DM. However, the observation was disappeared after treatment with corticosteroid. An arrow indicates nasal regurgitation of imaging agent.

doi:10.1371/journal.pone.0154746.g001

compared with patients without dysphagia ($p < 0.05$, $p < 0.05$, and $p < 0.001$, respectively). On the other hand, the mean MMT scores of sternomastoid muscle were significantly lower in patients with dysphagia compared with patients without dysphagia ($p < 0.05$). Other clinical/laboratory features were not significantly different between 2 groups.

Independent factors that were associated with the development of dysphagia

Next, we evaluated clinical or laboratory factors that could closely associated with the development of dysphagia in patients with DM by multivariate analysis. Investigated factors were as follows; age, gender, interstitial lung diseases, internal malignancy, elevated CK, MMT scores (sternomastoid, deltoid, and iliopsoas muscle), anti-ARS Ab, and anti-TIF-1 γ Ab. We performed logistic regression analysis and the final model confirmed the significant risk factors for the development of dysphagia in DM; internal malignancy (odds ratio 22.2), anti-TIF-1 γ Ab (odds ratio 11.8), and MMT score of sternomastoid muscle (odds ratio 0.46 for each score, [Table 3](#)).

The profile of patients with dysphagia

Based on these findings, the profile of 13 patients with dysphagia was evaluated ([Table 4](#)). Ten patients had both anti-TIF-1 γ Ab and internal malignancy. Case 2 (56 year-old, female) was positive for anti-TIF-1 γ Ab but did not have internal malignancy. Case 4 (64 year-old, male) with lung cancer was negative for anti-TIF-1 γ Ab and positive for one kind of anti-ARS Ab (anti-OJ Ab). Another case with dysphagia (case 11; 83 year-old, female) was negative for known autoantibodies by immunoprecipitation assay and did not have malignancy. All patients with dysphagia had muscle weakness and/or elevated serum CK levels. The sequence

Table 1. Associations between dysphagia and clinical or laboratory features in patients with dermatomyositis.

	Dysphagia + (n = 13)	Dysphagia - (n = 79)
Age	67.8±10.2**	52.8±16.1
Sex (male:female)	7: 6**	13: 66
Disease duration (month)	3.9±4.8	10.6±15.8
Symptom		
Muscle weakness	92.3%	68.4%
MMT (sternomastoid)	2.8±1.1*	4.0±1.2
MMT (deltoid)	3.5±1.2*	4.3±0.9
MMT (iliopsous)	3.7±0.9	4.1±0.9
Gottron's sign	92.3%	67.9%
Heliotrope rash	53.8%	43.6%
Interstitial lung diseases	7.7%**	52.6%
Internal malignancy	84.6%***	10.1%
Laboratory finding		
Elevated CK	92.3%	54.4%
Elevated KL-6	23.1%	47.4%
Autoantibodies		
Anti-ARS antibody	7.7%	27.8%
Anti-TIF-1γ antibody	84.6%***	19.0%
Anti-Mi-2 antibody	0%	3.8%
Anti-MDA-5 antibody	0%	19.0%
Anti-SS-A (Ro60) antibody	0%	6.3%
Anti-U1 RNP antibody	0%	6.3%
Anti-SRP antibody	0%	1.3%

MMT, manual muscle testing; CK, creatine kinase; KL-6, Krebs von den Lungen-6; ARS, aminoacyl-tRNA synthetase; TIF-1γ, transcription intermediary factor 1γ; MDA-5, melanoma differentiation-associated protein 5; RNP, ribonucleoprotein; SRP, signal recognition particle.

*p<0.05

**p<0.01

***p<0.0001 vs. patients without dysphagia

doi:10.1371/journal.pone.0154746.t001

of symptoms such as skin, muscle, and dysphagia was not fixed in each patient. All 13 patients showed clinical improvement of dysphagia after treatment of malignancy (n = 10) and DM (corticosteroid therapy; n = 13 and intravenous immunoglobulin therapy; n = 2) during 7.3 ±5.5 months period. Swallowing rehabilitation and balloon dilation were concurrently used in 11 cases and 1 case, respectively.

Among 10 patients with both anti-TIF-1γ Ab and internal malignancy, internal malignancy was treated by both surgical operation and chemotherapy in 6 cases. The malignancy was treated with surgical operation, chemotherapy, and radiation in each one case and another one case could not receive any therapy for the malignancy. Only three cases achieved complete remission of the malignancy.

Association between dysphagia and disease activity

To assess disease activity based on individual organ systems, MYOACT portion of the Myositis Disease Activity Assessment Tool was used. The VAS scales of muscle disease activity, global disease activity score, but not global extra-skeletal muscle disease activity score were significantly

Table 2. Associations between dysphagia and clinical or laboratory features in dermatomyositis patients with anti-TIF-1γ antibody.

	Dysphagia + (n = 11)	Dysphagia - (n = 15)
Age	66.8±9.9*	54.7±19.0
Sex (male:female)	6: 5*	1: 14
Disease duration (month)	4.4±5.1	5.0±6.1
Symptom		
Muscle weakness	90.9%	53.3%
MMT (sternomastoid)	2.9±1.2*	4.0±1.2
MMT (deltoid)	3.6±1.0	4.3±1.5
MMT (illiopsous)	3.7±1.0	4.2±1.0
Gottron's sign	81.8%	73.3%
Heliotrope rash	72.7%	80.0%
Interstitial lung diseases	0%	6.7%
Internal malignancy	90.9%**	20.0%
Laboratory finding		
Elevated CK	90.9%	60.0%
Elevated KL-6	20.0%	20.0%

TIF-1, transcription intermediary factor 1; MMT, manual muscle testing; CK, creatine kinase; KL-6, Krebs von den Lungen-6.

*p<0.05

**p<0.001 vs. patients without dysphagia

doi:10.1371/journal.pone.0154746.t002

higher in patients with dysphagia compared with patients without it (p<0.01, Table 5). Among global extra-skeletal muscle disease activity, the VAS scales of cutaneous disease activity score in addition to gastrointestinal disease activity score were significantly elevated in patients with dysphagia compared with patients without it (p<0.05 and p<0.001, respectively). Thus, patients with dysphagia showed higher muscle, cutaneous and global disease activity of DM.

Discussion

In this study, we detected a most significant association between the involvement of dysphagia and the existence of internal malignancy or anti-TIF-1γ Ab. In addition, reduced MMT of sternomastoid muscles was independent risk factor for the involvement of dysphagia.

There are literatures that have demonstrated the increased frequency of dysphagia in DM patients with internal malignancy compared with patients without malignancy [4]. A recent Japanese study demonstrated that proximal dysphagia, older age, and absence of interstitial lung disease were independent risk factors for malignancy in Japanese patients with DM or PM

Table 3. Multivariate analysis assessing the existence of dysphagia.

	OR (95% CI)	p value
Internal malignancy	22.2 (3.84 to 200.4)	0.0014
Anti-TIF-1γ Ab	11.8 (1.87 to 113.3)	0.0142
MMT (sternomastoid)	0.46 (0.20 to 0.95) for each score	0.0487

TIF-1, transcription intermediary factor 1; MMT, manual muscle testing

doi:10.1371/journal.pone.0154746.t003

Table 4. The profile of dermatomyositis patients with dysphagia.

Case	Age	Sex	Duration (months)	Dysphagia	Autoantibody	Internal malignancy	MMT					Elevated CK (IU/l)	Heliotrope rash	Gotttron's sign	ILD	Treatment (maximum dose)	Sequence of symptoms
							Sternomastoid	Deltaoid	Iliopsoas	Internal	External						
1	48	Female	3	Nasal regurgitation	Anti-TIF-1γ	Ovary	3	4	4	4	+	+	+	—	PSL 30mg, DR	Skin→ Muscle, dysphagia	
2	56	Female	3	Pharyngeal pooling	Anti-TIF-1γ	none	2	3+	2-	2	+	+	+	—	PSL 60mg, mPSL pulse, DR	Skin→ Muscle, dysphagia	
3	56	Male	18	Pharyngeal pooling	Anti-TIF-1γ	Upper pharynx	ND	ND	ND	ND	+	+	+	—	PSL 30mg	Skin→ Muscle, dysphagia	
4	64	Male	2	Pharyngeal Pooling, Cricopharyngeal dysfunction, Nasal regurgitation	Anti-OJ	Lung	2-	2-	2	2	+	+	—	PSL 20mg, mPSL pulse, IVIG, DR, B	Muscle→ dysphagia→ Skin		
5	70	Male	8	Pharyngeal pooling, (Laryngeal elevation)	Anti-TIF-1γ	Stomach	2	2	3	3	+	+	+	—	PSL 50mg, mPSL pulse, DR	Skin→ Muscle, dysphagia	
6	72	Male	2	Pharyngeal pooling	Anti-TIF-1γ	Sigmoid colon	3	4	4	4	+	+	+	—	PSL 50mg, mPSL pulse, DR	Skin→ Muscle	
7	74	Female	2	Pharyngeal pooling, Nasal regurgitation	Anti-TIF-1γ	Gallbladder	2	3-	2	2	+	+	+	—	PSL 50mg, DR	Skin, Muscle, dysphagia	
8	75	Male	7	Pharyngeal pooling	Anti-TIF-1γ	Lung	3-	4+	4	4	+	+	+	—	PSL 50mg	Skin→ Muscle, dysphagia	
9	76	Female	1	Nasal regurgitation	Anti-TIF-1γ	Ovary	2-	2	2	2	+	+	+	—	PSL 40mg, IVIG, DR	Skin→ Muscle, dysphagia	
10	79	Male	1	Pharyngeal pooling	Anti-TIF-1γ	Lung	4	5	4	4	+	+	+	—	PSL 30mg, DR	Skin, Muscle, dysphagia	
11	83	Female	1	Pharyngeal pooling	None	none	4	5	5	5	+	+	+	+	PSL 30mg, DR	Skin→ dysphagia→ Muscle	
12	64	Male	2	Pharyngeal pooling	Anti-TIF-1γ	Lung	5	4	4	4	+	+	+	—	PSL 30mg, DR	Skin→ Muscle→ dysphagia	
13	65	Female	1	Pharyngeal pooling	Anti-TIF-1γ	Breast	2	2	5	5	+	+	+	—	PSL 50mg, DR	Skin, Muscle, dysphagia	

ILD, interstitial lung diseases; TIF-1, transcription intermediary factor 1; ND, not determined; MMT, manual muscle testing; CK, creatine kinase; PSL, prednisolone; mPSL, methyl PSL; CyA, cyclosporin A; IVIG, intravenous immunoglobulin; DR, dysphagia rehabilitation; B, balloning

doi:10.1371/journal.pone.0154746.t004

Table 5. Associations between dysphagia and myositis disease activity scale.

	Dysphagia (n = 13)	No dysphagia (n = 79)	p value
Muscle disease activity	35.4 ± 23.8	14.4 ± 17.5	<0.01
Global extra-skeletal muscle disease activity	17.8 ± 9.9	12.2 ± 6.8	ns
Constitutional disease activity	24.2 ± 23.1	12.3 ± 13.7	ns
Cutaneous disease activity	50.5 ± 19.9	30.5 ± 21.2	<0.05
Skeletal disease activity	1.0 ± 2.8	3.7 ± 7.7	ns
Gastrointestinal disease activity	11.9 ± 22.1	1.1 ± 3.7	<0.001
Pulmonary disease activity	8.1 ± 13.5	18.3 ± 20.9	ns
Cardiac disease activity	0.8 ± 2.8	1.5 ± 4.5	ns
Global disease activity	32.9 ± 17.5	18.4 ± 12.3	<0.01

doi:10.1371/journal.pone.0154746.t005

[5]. In consistent with these previous studies, the involvement of dysphagia was positively associated with the involvement of internal malignancy by multiple regression in our population.

A recent systematic review and metaanalysis demonstrated that adult DM patients who were positive for anti-TIF-1 γ Ab had 27-fold higher odds ratio of having malignancy [11]. Therefore, the increased frequency of internal malignancy may be due to the secondary tendency due to the existence of anti-TIF-1 γ Ab in our study. Alternatively, the association between anti-TIF-1 γ Ab and dysphagia may be due to the correlation between internal malignancy and dysphagia. In either case, our findings suggest that the existence of anti-TIF-1 γ Ab is one of the best indicators to estimate the development of dysphagia in adult patients with DM, although previous studies did not evaluate this Ab. However, there is a phenotypic difference dependent on the age at onset among patients with this Ab. For example, juvenile patients with this Ab do not develop malignancy [7, 21]. In fact, the mean age and ratios of male to female were significantly higher in patients with dysphagia compared with patients without dysphagia among patients with anti-TIF-1 γ Ab (Table 2). Although multivariate analysis did not define the aging or sex as an explanatory variable for the existence of dysphagia, further large studies may be needed to clarify the significance of age or sex for the development of dysphagia. Thus, patients with either internal malignancy or anti-TIF-1 γ Ab may develop dysphagia more frequently compared with other patients.

A previous study demonstrated that the majority of DM patients with autoantibody against small ubiquitin-like modifier activating enzyme develop cutaneous disease and progressed to myositis with systemic features including dysphagia [22]. The frequency has been reported as 8% (9/131 cases) in United Kingdom Caucasian adult-onset DM patients and the frequency of dysphagia has been detected in 7 of 9 patients. This Ab was also detected in 1.5% (7/456 cases) of Japanese DM patients and two of seven with this Ab had dysphagia [23].

Most patients with anti-TIF-1 γ Ab exhibit DM with typical skin lesion and myositis, without ILD [7, 8]. Our findings including MYOACT assessment also indicate that dysphagia involvement tended to be associated with disease activity including global, muscle and skin in addition to gastrointestinal tract in patients with DM. All 11 patients with dysphagia had elevated CK levels and/or muscle weakness. However, a previous study demonstrated that clinical assessment of muscle strength or disease activity can not be used to predict the risk of swallow dysphagia in DM [24]. Our findings suggest that dysphagia develops in associated with multiple factors. Therefore, it is possible that dysphagia may be found during the active phase of DM if the patients had risk factors such as internal malignancy and/or anti-TIF-1 γ Ab. Interestingly, reduced muscle strength of sternomastoid muscles but not other muscles was independent risk factor for the involvement of dysphagia, although sternomastoid muscles are close to

the muscle of swallowing. Furthermore, the clinical symptoms of dysphagia disappeared after the therapy against DM in all 13 patients. In a representative patient, VFSS was very useful to observe the symptoms of dysphagia and to evaluate the effect of treatment.

The frequency of dysphagia was low in our cohort when compared with previous reports. We assessed the existence at the presentation, although previous reports may include the development of dysphagia during long clinical course. The definition of dysphagia may also different, because we evaluated it by otorhinolaryngologists and speech therapists and confirmed using VFSS. The mechanism of dysphagia of DM remains unclear. A recent study using VFSS and manometry indicated that dysphagia in inflammatory muscle diseases may be due to impaired muscle contraction and reduced hyolaryngeal excursion than the often held belief of failed upper esophageal sphincter relaxation [25].

In our study, the number of patients, especially patients with dysphagia is small. Further longitudinal studies in a larger population will be needed to clarify the associated factors for the development of dysphagia in patients with DM.

Supporting Information

S1 Fig. Moving image of Fig 1 (case 1 of Table 4). Pharyngeal pooling is detected at both pharyngeal and esophageal phases.
(MP4)

S2 Fig. Moving image of case 6 of Table 4. Anterior half; nasal regurgitation is detected at pharyngeal phases before treatment of DM. Last half; the observation was disappeared after treatment with corticosteroid.
(MP4)

Acknowledgments

We thank Kaho Yoshifuji and Tomoko Hayashi for her technical assistance of immunoprecipitation.

Author Contributions

Conceived and designed the experiments: NM MH. Performed the experiments: NM MH TM YH SO HO TY FS SM MF KT. Analyzed the data: NM MH KI. Contributed reagents/materials/analysis tools: NM MH TM YH SO HO TY FS SM MF KT. Wrote the paper: NM MH.

References

1. Oh TH, Brumfield KA, Hoskin TL, Stolp KA, Murray JA, Bassford JR. Dysphagia in inflammatory myopathy: clinical characteristics, treatment strategies, and outcome in 62 patients. *Mayo Clin Proc.* 2007; 82:441–7. PMID: [17418072](#)
2. Williams RB, Grehan MJ, Hersch M, Andre J, Cook IJ. Biomechanics, diagnosis, and treatment outcome in inflammatory myopathy presenting as oropharyngeal dysphagia. *Gut.* 2003; 52:471–8. PMID: [12631653](#)
3. Ebert EC. Review article: the gastrointestinal complications of myositis. *Aliment Pharmacol Ther.* 2010; 31:359–65. doi: [10.1111/j.1365-2036.2009.04190.x](#) PMID: [19886949](#)
4. Ponyi A, Constantin T, Garami M, Andras C, Tallai B, Vancsa A, et al. Cancer-associated myositis: clinical features and prognostic signs. *Ann N Y Acad Sci.* 2005; 1051:64–71. PMID: [16126945](#)
5. Azuma K, Yamada H, Ohkubo M, Yamasaki Y, Yamasaki M, Mizushima M, et al. Incidence and predictive factors for malignancies in 136 Japanese patients with dermatomyositis, polymyositis and clinically amyopathic dermatomyositis. *Mod Rheumatol.* 2011; 21:178–83. doi: [10.1007/s10165-010-0362-y](#) PMID: [20922453](#)

6. Mimori T, Imura Y, Nakashima R, Yoshifuji H. Autoantibodies in idiopathic inflammatory myopathy: an update on clinical and pathophysiological significance. *Curr Opin Rheumatol*. 2007; 19:523–9. PMID: [17917530](#)
7. Targoff IN, Mamyrova G, Trieu EP, Perurena O, Koneru B, O'Hanlon TP, et al. A novel autoAb to a 155-kd protein is associated with dermatomyositis. *Arthritis Rheum*. 2006; 54:3682–9. PMID: [17075819](#)
8. Kaji K, Fujimoto M, Hasegawa M, Kondo M, Saito Y, Komura K, et al. Identification of a novel autoantibody reactive with 155 and 140 kDa nuclear proteins in patients with dermatomyositis: an association with malignancy. *Rheumatology (Oxford)*. 2007; 46:25–8.
9. Chinoy H, Fertig N, Oddis CV, Ollier WE, Cooper RG. The diagnostic utility of myositis autoantibody testing for predicting the risk of cancer-associated myositis. *Ann Rheum Dis*. 2007; 66:1345–9. PMID: [17392346](#)
10. Fujimoto M, Hamaguchi Y, Kaji K, Matsushita T, Ichimura Y, Kodera M, et al. Myositis-specific anti-155/140 autoantibodies target transcription intermediary factor 1 family proteins. *Arthritis Rheum*. 2012; 64:513–22. doi: [10.1002/art.33403](#) PMID: [21987216](#)
11. Trallero-Araguas E, Rodrigo-Pendas JA, Selva-O'Callaghan A, Martinez-Gomez X, Bosch X, Labrador-Horrillo M, et al. Usefulness of anti-p155 autoantibody for diagnosing cancer-associated dermatomyositis: a systematic review and meta-analysis. *Arthritis Rheum*. 2012; 64:523–32. doi: [10.1002/art.33379](#) PMID: [21953614](#)
12. Targoff IN. Laboratory testing in the diagnosis and management of idiopathic inflammatory myopathies. *Rheum Dis Clin North Am*. 2002; 28:859–90. PMID: [12506776](#)
13. Sato S, Hirakata M, Kuwana M, Suwa A, Inada S, Mimori T, et al. Autoantibodies to a 140-kd polypeptide, CADM-140, in Japanese patients with clinically amyopathic dermatomyositis. *Arthritis Rheum*. 2005; 52:1571–6. PMID: [15880816](#)
14. Sato S, Hoshino K, Satoh T, Fujita T, Kawakami Y, Fujita T, et al. RNA helicase encoded by melanoma differentiation-associated gene 5 is a major autoantigen in patients with clinically amyopathic dermatomyositis: Association with rapidly progressive interstitial lung disease. *Arthritis Rheum*. 2009; 60:2193–200. doi: [10.1002/art.24621](#) PMID: [19565506](#)
15. Ghirardello A, Zampieri S, Iaccarino L, Tarricone E, Bendo R, Gambari PF, et al. Anti-Mi-2 antibodies. *Autoimmunity*. 2005 Feb; 38:79–83. PMID: [15966133](#)
16. Bohan A, Peter JB. Polymyositis and dermatomyositis (first of two parts). *N Eng J Med*. 1975; 292:344–8.
17. Bohan A, Peter JB. Polymyositis and dermatomyositis (second of two parts). *N Eng J Med*. 1975; 292:403–7.
18. Sontheimer RD. Cutaneous features of classic dermatomyositis and amyopathic dermatomyositis. *Curr Opin Rheumatol*. 1999; 11:475–82. PMID: [10551671](#)
19. Kobayashi J, Kitamura S. KL-6: a serum marker for interstitial pneumonia. *Chest*. 1995; 108:311–5. PMID: [7634858](#)
20. Sultan SM, Allen E, Oddis CV, Kiely P, Cooper RG, Lundberg IE, et al. Reliability and validity of the myositis disease activity assessment tool. *Arthritis Rheum*. 2008; 58:3593–9. doi: [10.1002/art.23963](#) PMID: [18975333](#)
21. Gunawardena H, Wedderburn LR, North J, Betteridge Z, Dunphy J, Chinoy H, et al. Clinical associations of autoantibodies to a p155/140 kDa doublet protein in juvenile dermatomyositis. *Rheumatology (Oxford)*. 2008; 47:324–8.
22. Betteridge ZE, Gunawardena H, Chinoy H, North J, Ollier WE, Cooper RG, et al. Clinical and human leucocyte antigen class II haplotype associations of autoantibodies to small ubiquitin-like modifier enzyme, a dermatomyositis-specific autoantigen target, in UK Caucasian adult-onset myositis. *Ann Rheum Dis*. 2009; 68:1621–5. doi: [10.1136/ard.2008.097162](#) PMID: [18930994](#)
23. Fujimoto M, Matsushita T, Hamaguchi Y, Kaji K, Asano Y, Ogawa F, et al. Autoantibodies to small ubiquitin-like modifier activating enzymes in Japanese patients with dermatomyositis: comparison with a UK Caucasian cohort. *Ann Rheum Dis*. 2013; 72:151–3. doi: [10.1136/annrheumdis-2012-201736](#) PMID: [22843487](#)
24. McCann LJ, Garay SM, Ryan MM, Harris R, Riley P, Pilkington CA. Oropharyngeal dysphagia in juvenile dermatomyositis (JDM): an evaluation of videofluoroscopy swallow study (VFSS) changes in relation to clinical symptoms and objective muscle scores. *Rheumatology (Oxford)*. 2007; 46:1363–6.
25. Langdon CP, Mulcahy K, Shepherd KL, Low VH, Mastaglia FL. Pharyngeal Dysphagia in Inflammatory Muscle Diseases Resulting from Impaired Suprahyoid Musculature. *Dysphagia*. 2012; 27:408–17. doi: [10.1007/s00455-011-9384-7](#) PMID: [22207246](#)