



THE AGA KHAN UNIVERSITY

eCommons@AKU

---

Faculty of Health Sciences, East Africa

Faculty of Health Sciences, East Africa

---

3-31-2022

## Tuberculous Meningitis Presenting with Stroke in an Immunocompetent Adolescent: A Case Report

Rukhsar S. Osman

*Aga Khan University, Tanzania*

Rahim Damji

*Regency Medical Centre, Tanzania*

Zainab Y. Fidaali

*Aga Khan University, Tanzania*

Nahida Walli

*Aga Khan University, Tanzania*

Mariam Noorani

*Aga Khan University, mariam.noorani@aku.edu*

Follow this and additional works at: [https://ecommons.aku.edu/eastafrica\\_fhs\\_fhs](https://ecommons.aku.edu/eastafrica_fhs_fhs)



Part of the [Medical Education Commons](#)

---

### Recommended Citation

Osman, R. S., Damji, R., Fidaali, Z. Y., Walli, N., & Noorani, M. (2022). Tuberculous Meningitis Presenting with Stroke in an Immunocompetent Adolescent: A Case Report. *East Africa Science*, 4(1), 14-18.

# Tuberculous Meningitis Presenting with Stroke in an Immunocompetent Adolescent: A Case Report

Rukhsar S Osman<sup>\*a</sup>, Rahim Damji<sup>b</sup>, Zainab Y Fidaali<sup>c</sup>, Nahida Walli<sup>a</sup>, Mariam Noorani<sup>a</sup>

<sup>a</sup>Department of Paediatrics, Aga Khan University, Dar es Salaam, Tanzania, <sup>b</sup>Department of Paediatrics, Regency Medical Centre, Dar es Salaam, Tanzania, <sup>c</sup>Department of Radiology, Aga Khan University, Dar es Salaam, Tanzania

Correspondence to Rukhsar S Osman ([rukhsaarosman@gmail.com](mailto:rukhsaarosman@gmail.com))

## ABSTRACT

**Background:** Tuberculous meningitis (TBM) is a severe infection of the central nervous system that has high mortality. The disease predominantly affects young children and those who are immunocompromised. Strokes have been reported in about one-third of children with tuberculous meningitis and are associated with poor clinical outcomes.

**Case report:** A previously healthy 14-year-old girl living in Dar es Salaam, Tanzania presented with one month history of weight loss associated with weakness, loss of appetite, apathy; without respiratory symptoms. Anti-TB therapy was started, based on radiological findings of the chest which showed multiple patchy centrilobular nodules with linear branching pattern bilaterally, mediastinum lymph node enlargement with punctate calcification. She then became aphasic and developed right-sided hemiparesis. Brain imaging showed infarction, hydrocephalus and meningeal enhancement. Diagnosis of tuberculous meningitis (TBM) with left sided ischaemic stroke was made and dexamethasone was added to her regimen. Treatment and rehabilitation was continued for 12 months with minimal improvement.

**Conclusion:** Tuberculous meningitis can present with non-specific features and has grave outcomes. Stroke is an uncommon complication in older immunocompetent children and results in severe morbidity. A high index of suspicion is required in adolescents with neurological symptoms that can be confused with behavioural symptoms.

## INTRODUCTION

Tuberculous meningitis (TBM) in children is a deadly disease with a mortality rate of up to 30% in severe cases and about 50% of surviving patients have some form of neurological sequelae despite adequate anti-tuberculous treatment.<sup>1</sup> Because of their relative inability to contain primary tuberculosis infection in the lungs, children younger than 5 years are more frequently affected by tuberculous meningitis. Risk factors including poverty, malnutrition, overcrowding, a compromised immune system and living in an endemic area are similar to those of pulmonary TB. It is very rare in immunocompetent patients.

Lymphohematogenous spread of the mycobacteria to the brain from the primary focus in the lungs results in the development of a Rich focus. This caseous granuloma ruptures into subarachnoid space leading to basal inflammatory exudates that cause cranial nerve palsies and obstruct cerebrospinal fluid pathways resulting in hydrocephalus and obliterative vasculitis which triggers infarctions.<sup>1</sup>

Signs and symptoms of TBM vary from non-specific symptoms such as headache, fever, vomiting and neck stiffness to more progressive meningitic symptoms

such as focal neurologic deficits, with cranial nerve palsies (50%) and limb weakness (10%).<sup>2</sup>

Stroke is a common complication of TBM and has been reported in 13-57% of patients.<sup>3</sup> It is a poor prognostic predictor and about 1 in 5 patients with stroke die within 6 months of diagnosis.<sup>4</sup>

The diagnosis and management of TBM is challenging, particularly in low resource settings because the pathogenesis of the disease is still poorly understood. In addition, there are no rapid, sensitive and affordable tests to diagnose TBM.<sup>5</sup> Neuroimaging findings are non-specific and include: basal meningeal enhancement, hydrocephalus, tuberculomas and infarcts.<sup>5</sup>

Unlike pulmonary TB, the optimal therapy of TBM has not been established in clinical trials yet.<sup>6</sup> A study analysis done from nine trials showed that use of corticosteroids in patients with TBM reduced the risk of death by a quarter at two months to two years after the treatment was initiated.<sup>7</sup>

We report a case of TBM with stroke in an immunocompetent adolescent female. A summary of the timeline of events is provided in [Table 1](#).

## CASE REPORT

A 14-year-old girl of South Asian origin living in Tanzania for the past 8 years; who had been vaccinated with bacille Calmette-Guérin (BCG) vaccine in infancy presented with a one month history of subjective gradual weight loss associated with loss of appetite, weakness, decreased activity and subjective fever. She also reported severe pain in her limbs. However, she had no history of cough, difficulty breathing, headache or night sweats. She had been to several outpatient clinics and was being treated for helicobacter pylori-associated gastritis with no relief. As the illness progressed, she developed extreme weakness and was not able to ambulate. She also had changes in her speech and personality where she would respond only with words and would respond selectively to the mother only.

Her past medical history was unremarkable with no previous hospital admissions or surgical procedures. She had normal growth and developmental milestones. On examination, she was found to be weak, severely cachexic and pale with no palpable lymph nodes. She had no signs of respiratory distress. Her central nervous system findings were unremarkable except for the poor verbal response. The rest of her examination was normal.

A diagnosis of probable tuberculosis was made with a differential diagnosis of autoimmune disease and hematologic malignancy.

A complete blood count showed anaemia with haemoglobin of 6.5g/dl (range: 10.5-14.5g/dl) with microcytic hypochromic red cell indices. White blood cell count was normal at  $5.63 \times 10^9/l$  (range:  $4.5-13.0 \times 10^9/l$ ), absolute neutrophils count -  $4.93 \times 10^9/l$  (range:  $1.78-5.38 \times 10^9/l$ ) and lymphocytes -  $0.37 \times 10^9/l$  (range:  $0.4 - 4.0 \times 10^9/l$ ). Peripheral smear revealed anisopoikilocytosis with target cells, there were no abnormal or immature cells seen.

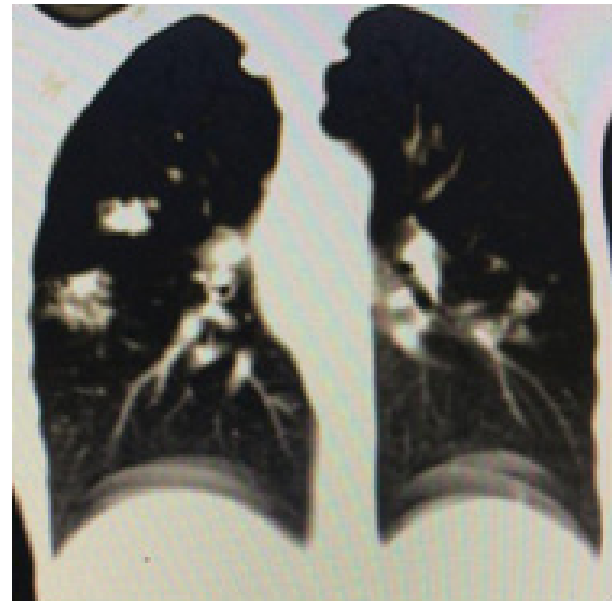
C reactive protein (CRP) was elevated at 91.5mg/l (normal: 0.5 – 5.0mg/l). Electrolytes and renal function were normal except for hyponatremia with sodium of 123mmol/l (range: 135-145mmol/l).

Liver functions showed severe hypoalbuminaemia - 18g/l (range: 35 – 48g/l) with normal liver enzymes. Autoimmune disease workup was done and both anti double-stranded DNA (anti dsDNA) and antinuclear factor (ANA) were negative.

A chest x-ray showed multiple patchy micro lobular consolidations bilaterally and a subsequent Chest Computerised Tomography (CT) scan showed multiple patchy centrilobular nodules with linear branching pattern bilaterally, mediastinum lymph node enlargement with punctate calcification, highly suggestive of pulmonary tuberculosis. (Figure 1). Further history revealed open TB contact with an aunt, 2 years before moving to Tanzania and was not put on post-exposure prophylaxis.

A diagnosis of Pulmonary TB was made with severe acute malnutrition and anti TB drugs (rifampicin, isoniazid, pyrazinamide and ethambutol) were initiated as per the national guideline together with nutritional rehabilitation provided by parenteral nutrition. No active management with iron supplement or blood transfusion was done for anaemia, as it was attributed to chronic inflammation.

**FIGURE 1.** A chest CT showed multiple patchy micro lobular consolidations bilaterally



Over the course of 3 days, she showed clinical improvement; she started feeding orally, started ambulating and gained 1.5 kg. Her repeat CRP was 11.1mg/l and Hb: 7.2g/l. However, despite her clinical improvement, her regular speech did not return and she remained disinterested and was thought to have depression.

On the 4<sup>th</sup> day, she suddenly became more lethargic, completely aphasic, had reduced oral intake and began drooling saliva. She was then referred to a higher level of care for further workup and possible intensive care unit (ICU) admission.

Upon review after referral, she was lethargic with a Glasgow coma score of 8/15, appeared cachexic, and moderately pale with a normal pulse (103 beats per minute), respiration (18 breaths per minute) and blood pressure (110/83). Her weight was 21kg which was less than the 3<sup>rd</sup> centile for age. On neurologic examination, she had a stiff neck with bilaterally equal and reactive pupils and hemiparesis of the right upper and lower limb. She had an impaired gag reflex. Respiratory, cardiovascular and abdominal exam findings were unremarkable.

Magnetic resonant imaging (MRI) and magnetic resonant angiography (MRA) of the brain with contrast was performed which revealed subacute ischemic infarct affecting the left basal ganglia as well as the insular cortex with left frontoparietal leptomenigeal enhancement (figure 2). Hence a diagnosis of tuberculous meningitis with left-sided subacute ischemic infarct was reached. The MRA showed complete occlusion of the M2 segment of the left middle cerebral artery and its branches (figure 3). The gastric aspirate was taken for gene Xpert which detected Mycobacterium tuberculosis sensitive to rifampicin; however, gram stain for acid-fast bacilli (AFB) was negative. Her HIV test was also negative.

**TABLE 1: Timeline of Key Events, Diagnostic Tests and Interventions**

	Summary from initial and follow up visit	Diagnostic testing	Intervention
<b>Day 1</b>	1 month history of gradual weight loss, increasing weakness, loss of appetite, limb pain and selective mutism. On examination: pale, cachexic, poor verbal response and unremarkable systemic exam. <b>Diagnosis:</b> severe acute malnutrition and pulmonary TB	Haemoglobin 6.5g/dl, White blood cell count 5.63 x10 <sup>9</sup> /l, C reactive protein 91.5mg/l sodium 123mmol/l Peripheral smear: anisopoikilocytosis with target cells, albumin 18g/l chest x-ray and CT suggestive of pulmonary TB	Initiation of anti TB drugs (rifampicin, isoniazid, pyrazinamide & ethambutol)
<b>Day 4</b>	Became lethargic, aphasic and drooling saliva. On exam: Glasgow score 8/12, lethargic, cachexic, stiff neck, impaired gag reflex, hemiparesis of the limbs on the right. Diagnosis: tuberculous meningitis with subacute ischaemic infarct.	MRI and MRA of the brain: subacute ischaemic infarct of the left basal ganglia. Gastric aspirate: mycobact- erium tuberculosis sensitive to rifampicin. HIV test: negative	Referral to high- er centre & ad- mission in ICU. Continue with anti TB and pyridoxine. Initiation of dexamethasone and lamotrigine. Speech & physi- otherapy with nutritional rehabilitation.
<b>Day 9</b>	Significant improvement with some weight gain	Albumin: normal Haemoglobin: 6.4g/dl	Discharged home on 1 year dose of anti TB, tapering dose of oral prednisolone & rehabilitati- on.
<b>Follow up after 1 year</b>	Still aphasic with right-sided weakness and stiffness on physiotherapy and baclofen. Dependent on caregivers for daily activities.		

She was admitted to ICU, started on lamotrigine 12.5mg (0.6mg/kg/day) for seizure prophylaxis and dexamethasone 4mg 8 hourly (0.5mg/kg/day) was initiated to reduce cerebral oedema. A neurosurgical consult was sought and non-surgical conservative treatment was advised. Her anti TB drugs were continued and 20mg daily of pyridoxine was added. Occupational, speech and physiotherapy was initiated on the following day of admission. Nutritional rehabilitation was continued with high-calorie nasogastric tube feeds.

She showed gradual improvement and on the 9<sup>th</sup> day was discharged with the weight of 22.1kg, her electrolytes had normalized, albumin was normal though she still had anaemia (Hb: 6.4g/dl). She was on oral prednisolone

2mg/kg per day to be tapered for over a month, anti-TB drugs for 1 year and to continue with rehabilitation.

On follow up after completing her anti-TB treatment, she remains aphasic; she still has stiffness and weakness on the right side of her body and is on physiotherapy and using baclofen. She has not been able to return to school and is still dependent on caregivers for daily activities.

## DISCUSSION

Tuberculous meningitis has been commonly reported in children in countries with a high burden of TB. However, the peak age of occurrence is common in children under the age of 5 years.<sup>1</sup> It is rare in older children with no underlying immunosuppression. Our patient was a 14 y-

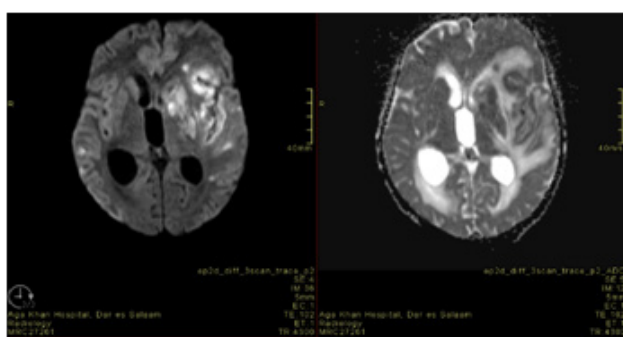
ear-old female with no underlying medical history and hence TBM with a stroke was an unexpected occurrence.

The initial presentation of TBM is usually with non-specific symptoms like fever and headaches. As the disease progresses, they may present with signs of raised intracranial pressure, cranial nerve palsies and neurologic deficits.<sup>1</sup> Our patient presented initially with non-specific symptoms of weight loss, poor appetite and limb pain without any pulmonary symptoms for more than a month. This led to a delay in diagnosis of TB and subsequently, consideration of other diagnoses such as autoimmune disease and hematologic malignancy in addition to tuberculosis.

She subsequently showed speech disturbance with poor verbal response and changes in her personality. This was initially presumed to be a behavioural or emotional problem. Behavioural problems are common in adolescents with chronic illness and girls with chronic illness have been found to be more at risk of emotional disturbances.<sup>8</sup> Her symptoms were only attributed to being neurological when she developed further neurological signs like reduced level of consciousness and drooling. The delay in recognition of the neurological signs and symptoms also led to further diagnostic delay of TBM.

The common triad of neuroradiological findings in TBM are: Basal meningeal enhancement, hydrocephalus and infarctions in the supratentorial brain parenchyma and brain stem.<sup>5</sup> Tuberculosis related infarcts commonly occur in the "TB zone" supplied by the medial lenticulostriate and thalamoperforating arteries. However, other studies have also described infarcts in multiple areas and involving perforators as well as cortical branches.<sup>3</sup> Our patient had an infarct involving the basal ganglia which is the commonest site of infarction in TB.

**FIGURE 2. Magnetic Resonant Imaging (MRI) of the Brain**

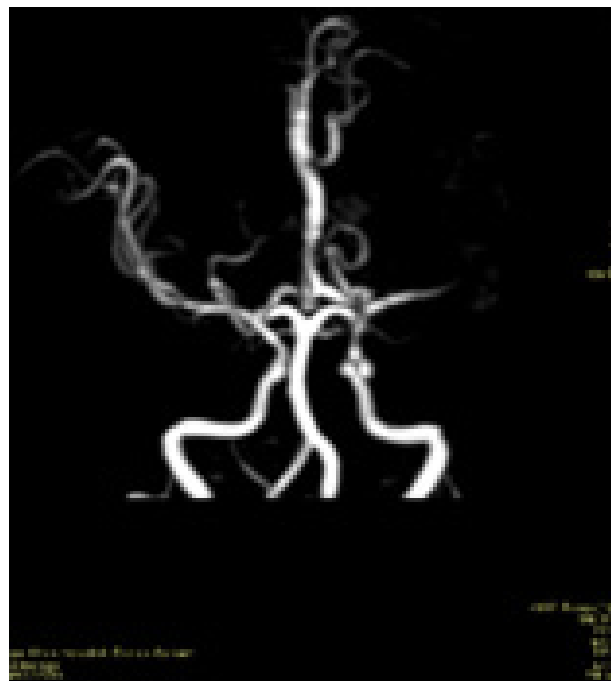

Arterial occlusion in TB usually involves the terminal branches and the complete occlusion of the M2 segment of the middle cerebral artery that was seen in our patient is a rare finding. Our patients' neuroimaging also did not demonstrate the vasospasm and vasculitis that occurs frequently in TB associated strokes.

Despite adequate anti TB treatment and supportive care, our patient did not make a complete recovery and had si-

gnificant residual neurological symptoms. This is similar to what is described in the literature with only about 35 % of patients making a complete recovery. Poorer outcomes are described in those diagnosed with late stages of disease.<sup>1</sup>

**FIGURE 3. magnetic Resonant Angiography (MRA) of the Brain**



## CONCLUSION

TBM in children remains a devastating disease, associated with substantial morbidity and mortality. The diagnosis of TBM remains challenging for clinicians especially in a resource-limited setting, mainly due to difficulties in the direct detection of *M. tuberculosis* bacilli in CSF and other specimens. The non specific nature of initial symptoms also contributes to diagnostic delay. A high index of suspicion is required for early diagnosis and treatment in countries with high burden of TB irrespective of age and immune status; more so in adolescents where neurologic symptoms can be confused with behavioural problems.

## REFERENCES

1. Daniel B, Grace G, Natrajan M. Tuberculous meningitis in children: Clinical management & outcome. *Indian J Med Res.* 2019;150(2):117-130. doi:10.4103/ijmr.IJMR\_786\_17
2. Wilkinson, R. J., Rohlwinck, U., Kant Misra, U., van Crevel, R., Thi Hoang Mai, N., Dooley, K. E., Caws, M., Figaji, A., Savic, R., Solomons, R., & Thwaites, G. E. (2017). Tuberculous meningitis. *Nature Reviews.* 2017.120 doi: 10.1038/nrneurol.2017.120
3. Misra UK, Kalita J, Maurya PK. Stroke in tuberculous

- meningitis. *J Neurol Sci.* 2011;303(1-2):22-30. doi:10.1016/j.jns.2010.12.015
4. Leiguarda R, Berthier M, Starkstein S, Nogués M, Lylyk P. Ischemic infarction in 25 children with tuberculous meningitis. *Stroke.* 1988;19(2):200-204. doi:10.1161/01.STR.19.2.200
  5. Murthy JMK. Tuberculous meningitis: The challenges. *Neurol India.* 2010;58(5):716. doi:10.4103/0028-3886.72178
  6. Török, M. E. (2015). Tuberculous meningitis: advances in diagnosis and treatment. *British Medical Bulletin*, 113(1), 117–131. doi: 10.1093/BMB/LDV003
  7. PrasadK, R. H. (2016). Cochrane Library Cochrane Database of Systematic Reviews Corticosteroids for managing tuberculous meningitis (Review). doi: 10.1002/14651858.CD002244.pub4
  8. Delamater AM, Guzman A, Aparicio K. Mental health issues in children and adolescents with chronic illness. *Int J Hum Rights Healthc.* 2017;10(3):163-173. doi:10.1108/IJHRH-05-2017-0020

---

**Peer Reviewed****Competing Interests:** None declared.**Funding:** This study was not funded**Received:** 23 June 2021; **Accepted:** 26 October 2021**Cite this article as** Osman SR, Damji R, Fidaali YZ, Walli N, Noorani M. Tuberculous Meningitis Presenting with Stroke in an Immunocompetent Adolescent: A Case Report. *E Afr Sci.* 2022; 4(1):6-10. <https://doi.org/10.24248/easci.v4i1.54>

© Osman et al. This is an open-access article distributed under the terms of the Creative Commons Attribution License, which permits unrestricted use, distribution, and reproduction in any medium, provided the original author and source are properly cited. To view a copy of the license, visit <http://creativecommons.org/licenses/by/4.0/>. When linking to this article, please use the following permanent link: <https://doi.org/10.24248/easci.v4i1.54>

---