

**O.V. Kutovyi,  
E.V. Zhmurenko**

## DIFFERENTIATED APPROACH TO SURGICAL TREATMENT OF ADRENAL GLANDS TUMORS

Dnipro State Medical University  
V. Vernadsky str., 9, Dnipro, 49044, Ukraine  
Дніпровський державний медичний університет  
вул. В. Вернадського, 9, Дніпро, 49044, Україна  
e-mail: elya.zhmurenko@gmail.com

**Цитування:** Медичні перспективи. 2021. Т. 26, № 4. С. 124-131

**Cited:** Medicni perspektivi. 2021;26(4):124-131

**Key words:** benign adrenal tumor, adrenalectomy, adrenal resection

**Ключові слова:** доброякісна пухлина надниркової залози, адреналектомія, резекція надниркової залози

**Ключевые слова:** доброкачественная опухоль надпочечника, адреналэктомия, резекция надпочечника

**Abstract.** Differentiated approach to surgical treatment of adrenal glands tumors. Kutovyi O.V., Zhmurenko E.V. Objective – to improve the results of treatment of adrenal tumors by optimizing a differentiated approach based on the analysis of the results of various surgical invasions. The paper analyzed the results of treatment of 145 patients with various adrenal tumors, which were divided into 2 groups: I (n=71) - patients after adrenalectomies, II (n=74) – after adrenal resections. Organ-preserving invasions showed better results during the early and long-term postoperative period in patients with corticosteromas, pheochromocytomas and incidentalomas by reducing the severity of fluctuations in hemodynamic parameters and the frequency of adrenal insufficiency. Due to the introduction of the treatment algorithm, the number of adrenal resections increased by 26.6% in patients with neoplasms more than 4,0 cm in diameter ( $p=0.0001$ ). The choice of surgical invasion should be individualized, taking into account the clinical features of the disease, hormone indicator parameters, the size of tumors, the comprehensiveness of the adrenal gland lesion and the ratio of the latter to nearby organs and structures. Adrenal insufficiency was detected 14.2% more often after adrenalectomies ( $p=0.044$ ) compared to adrenal resections. Treatment according to the developed algorithm reduced the incidence of adrenal insufficiency by 5.8% ( $p=0.028$ ). In the long-term postoperative period, contralateral gland tumors occurred with the same frequency (4.8%) among patients after adrenalectomies and resections. Relapse of the neoplasm after resections was detected in 3 (7.1%), as a result of which 2.4% underwent repeated operations with the final removal of the gland. An increase in the size of a single adrenal gland was more common by 21.4% after adrenalectomies.

**Реферат.** Диференційований підхід до хірургічного лікування новоутворень надниркових залоз. Кутовий О.В., Жмуренко Е.В. Метою роботи було покращити результати лікування пухлин надниркових залоз за рахунок оптимізації диференційованого підходу на основі аналізу результатів різних варіантів хірургічних втручань. У роботі проаналізовано результати лікування 145 пацієнтів з різними пухлинами надниркових залоз, які були розподілені на 2 групи: I (n=71) – хворі після адреналектомії, II (n=74) – після резекції надниркових залоз. Органозберігаючі втручання показали кращі результати протягом раннього та віддаленого післяопераційного періоду у хворих з кортикостеромами, феохромоцитомами та інсиденталомами за рахунок зменшення ступеня вираженості коливань показників гемодинаміки та частоти надниркової недостатності. Завдяки впровадженню алгоритму лікування на 26,6% збільшилась кількість резекцій наднирників у хворих з новоутвореннями більше ніж 4,0 см у діаметрі ( $p=0,0001$ ). Через це вибір хірургічного втручання має бути індивідуалізованим з урахуванням клінічної картини захворювання, даних показників гормонів, розмірів пухлин, повноти ураження надниркової залози та відношення останньої до прилеглих органів, структур. Надниркова недостатність визначалась на 14,2% частіше після адреналектомії ( $p=0,044$ ) порівняно з резекціями наднирників. Лікування згідно з розробленим алгоритмом дозволило зменшити частоту надниркової недостатності на 5,8% ( $p=0,028$ ). У віддаленому післяопераційному періоді пухлини контралатеральних залоз виникали з однаковою частотою (4,8%) серед пацієнтів після адреналектомії та резекцій. Рецидив новоутворення після резекцій виявили в 3 (7,1%) пацієнтів, внаслідок чого у 2,4% виконали повторні операції з остаточною видаленням залози. Збільшення розмірів одного наднирника зустрічалось на 21,4% частіше після адреналектомії.

Minimally invasive interventions are widely used in the practice of surgeons of various profiles. Their advantages are well known. Currently, the use of endovideosurgery is a priority in the removal of benign neoplasms of the adrenal glands. However, clear guidelines for treatment tactics and the extent of interventions according to the nature and size of these tumors have not yet been developed. In particular,

according to R.Ya. Heydarov in the case of adrenal neoplasms up to 3.0 cm in diameter it is necessary to follow an organ-preserving approach [6]. According to the results of M.E. Beloshchytsky in patients with bilateral adrenal lesions after unilateral adrenalectomy in 9 (41.0%) patients there was a tendency to increase in the size of the contralateral tumor by no more than 1.0 cm in 3 years, in 10 (59%) – the size and structure

of tumors were preserved without dynamics [1]. According to N.A. Maistrenko, A.R. Vavilov, H. Erdem et al. surgical tactics should be active, as when conducting additional tests, patients show subclinical hormonal activity [5, 7]. According to P.S. Vetshev, L.I. Ippolitov et al. adrenal neoplasms less than 3.0 cm in diameter without signs of malignant growth and hormonal activity do not require invasive interventions and can be left under dynamic observation [2]. According to M. Pwdziwiatr indications for removal of adrenal tumors was the size of the latter from 3.0 to 5.0 cm, because with their increase the risk of potentially malignant tumors increases as well [12].

However, the removal of benign tumors with a size of 1.0-3.0 cm in the absence of hormonal activity and a tendency to increase exposes the patient to the risk of complications in 3.6% of cases with a probability of malignancy in 1.8% [1, 12].

The question of treatment tactics depending on the characteristics of adrenal tumors remains relevant and requires detailed research and resolution.

Aim of this work was to improve the results of treatment of adrenal tumors by optimizing a differentiated approach based on the analysis of the results of different options for surgery.

#### MATERIALS AND METHODS OF RESEARCH

The paper analyses the results of treatment of 145 patients with various tumors of adrenal glands for the period from 2011 to 2019 in the clinic of surgery No. 2 on the basis of the department of endocrine surgery of the Communal Enterprise "Ilya Mechnikov Dnipropetrovsk Regional Clinical Hospital" of Dnipropetrovsk Regional Council".

The research was conducted in accordance with the principles of bioethics set out in the WMA Declaration of Helsinki – "Ethical principles for medical research involving human subjects" and "Universal Declaration on Bioethics and Human Rights" (UNESCO).

Patients in 123 (84.8 %) cases were operated by video-assisted intervention, in 13 (9.0%) – laparoscopy and in 9 (6.2%) – laparotomy. Access conversion was performed in 4 (2.8%) cases.

All patients were divided into 2 groups: I (n=71) – included patients, after adrenalectomies, II (n=74) – after resection of the adrenal glands. In each of the group there were subgroups: IA (n=49) and II A (n=42) included patients who underwent interventions for the period up to 2016 and including, IB and II B – patients, in whom diagnosis and treatment of neoplasms was carried out according to the developed algorithm. The mean age of patients was 56.9 (1.6) (M (SD)) years. Of these, 39 were men (26.9%) and 106 were women (73.1%). The majority of examined patients (73.1%) were women, this trend was observed in the comparison groups,  $p=0.620$ .

At the preoperative stage of the examination for tumor imaging patients underwent ultrasound (US) examination of the abdominal cavity organs (ACO) and retroperitoneal space, computed tomography abdominal cavity organs (CT ACO) with intravenous contrast, determination of hormonal activity of adrenal tumors and general clinical methods of research (general blood test, general urine test, coagulation analysis, biochemical blood analysis [10, 11, 14].

Adrenocorticotrophic hormone (ACTH) concentration was measured by chemiluminescent immunoassay (CLIA) on an Immulite analyzer (Siemens AG), Germany. Urine cortisol levels were determined by enzyme-linked immunosorbent assay (ELISA) on an analyzer with a test system IBL International GmbH, Germany. Blood aldosterone and active renin levels were calculated by ELISA on a DRG analyzer (Germany) for aldosterone and Demeditec (Germany) for active renin. The aldosterone-renin ratio (ARR) was calculated additionally by the formula for the ratio of aldosterone to active renin. Free metanephrines of blood (adrenaline and noradrenaline) were determined by liquid chromatography and tandem mass spectrometry (LC/MS) using an analyzer and test system API 5500 LC-MS-MS. Daily urinary excretion of catecholamines was calculated by ELISA.

Electrolyte parameters were determined by potentiometric ISE for potassium, sodium, chlorine and colorimetric analysis for calcium on a Cobas 6000 analyzer using a test system Roche Diagnostics (Switzerland).

In addition, an analysis of the results of ultrasound and CT was performed. The malignant potential of the tumor was preliminarily assessed on the basis of the size, shape, location and density of the tumor on the Hounsfield scale in the native, arterial and delayed phase (10 minutes after the start of the study) contrast [1, 5, 10, 11, 14].

The indication for organ-preserving operations was the peripheral location of the pathological focus. Among the contraindications to resection of the adrenal gland were: 1) malignant nature of the formation according to histopathological examination intraoperatively; 2) multicentric lesions of one gland [8, 13, 14, 15].

Statistical analysis of the results of the study was performed using the software product STATISTICA 6.1 (StatSoftInc., Serial No. AGAR909E415822FA) and Excel – 2010 using the methods of parametric (Student's t test for related and unrelated samples) and nonparametric statistics (Mann-Whitney test for unrelated samples and Wilcoxon test for repeated measurements, Pearson's  $\chi^2$  test for nominal data, including the Yates correction for continuity). The results of the treatment were presented using the arithmetic mean

(M), standard deviation (SD) in the presence of a normal distribution; median and interquartile range of Me (25%, 75%). For all types of analysis, the critical level of statistical significance is  $p < 0.05$  [4].

### RESULTS AND DISCUSSION

Performing organ-preserving operations by laparoscopy was accompanied by difficulties in determining the boundaries of tumors on palpation with an instrument, especially at the size of the latter less than 2.0 cm.

When comparing the results in groups I and II, no difference was found in the duration of interventions, but there was a tendency to their lengthening with the left location of tumors, regardless of the volume of operations. The volume of blood loss in group I was higher in right-sided interventions (322.1 (183.8) ml and 108.0 (12.3) ml,  $p = 0.007$ ), in group II – in left-sided interventions (156.4 (36, 7) ml and 89.1 (9.1) ml,  $p = 0.006$ ).

During adrenalectomies and resections, bleeding from the main vessels and reactive pleurisy occurred in approximately equal amounts ( $p > 0.05$ ). In organ-preserving operations, the cause of bleeding was incomplete hemostasis of the remained adrenal parenchyma. In adrenalectomies, the causes of bleeding were damage to the main vessels in 3 (4.2%) patients, in 2 (2.8%) – accompanied by damage to the spleen.

After laparotomies, the average duration of anesthesia was 7.0 (6.0; 7.0) days, after hand-assisted laparoscopic surgery (HALS) – 5.24 (0.1) days, after laparoscopy – 3.0 (3.0; 4.0) days. According to the obtained data, laparoscopy had a less traumatic effect on the abdomen and required a shorter duration of analgesia in patients after surgery ( $p = 0.0001$ ).

The length of hospital stay after adrenalectomies and resections did not differ significantly (11.6±0.4 days – for adrenalectomies, 11.6±0.32 days for organ-sparing operations,  $p > 0.05$ ), as in addition to the severity of the patient's condition was taken into account the presence of complications from the abdominal cavity and changes in hemodynamic parameters depending on the hormonal activity of tumors.

Intraoperatively and during the first day, 81.5% of patients needed glucocorticosteroids to stabilize blood pressure. The amount of drug administered depended on the histological structure of the tumor and the volume of intervention. After total corticosteroid removal, patients required 650.0 (300.0; 700.0) mg, after resection – 400.0 (200.0; 600.0) mg,  $p = 0.048$ . After adrenalectomies in patients with pheochromocytomas, the volume of hydrocortisone was 700.0 (525.0; 800.0) mg, after resection – 350.0 (300.0; 475.0) mg,  $p = 0.016$ . In patients with aldosterone, there was no difference between the amount of drug administered in I (300.0 (200.0; 575.0) mg)

and II (475.0 (300.0; 600.0) mg) groups ( $p = 0.515$ ). Persistent hypotension occurred in 3 (18.8%) patients after pheochromocytomas removal and required correction of BP figures with glucocorticoids, infusion of crystalloids, colloids and sympathomimetics.

After removal of the adrenal pheochromocytomas in group I, there was a significantly higher level of cortisol ( $p = 0.011$ ) and metanephrine of urine ( $p_{2m} = 0.002$ ,  $p_{6m} = 0.007$ ,  $p_{12m} = 0.001$ ) during the 12 months of the postoperative period. In 2 and 6 months after total removal of corticosteromas, patients had significantly higher levels of urinary cortisol ( $p_{2m} = 0.011$ ,  $p_{6m} = 0.027$ ) in group I, after 12 months there was a tendency to decrease in ACTH and cortisol. After removal of aldosteromas in group I there was a tendency to decrease in the level of aldosterone and renin ( $p = 0.013$ ) in the blood in 2 months. After total removal of the insidentalomas in 2 months there was an increase in urinary cortisol ( $p = 0.039$ ) in group I, but after 12 months there was a significant decrease in blood ACTH ( $p = 0.006$ ).

Given the changes in hormone levels after total removal of tumors, within 6 months patients were 14.2% ( $p = 0.044$ ) more likely to have palpitations, 16.6% ( $p = 0.024$ ) – anxiety and poor sleep, 14.2% ( $p = 0.044$ ) – increase in body temperature.

After 12 months, signs of hypertension after adrenalectomy disappeared in 58.3% of patients with hormonally active tumors, after resection – in 52.0% ( $p = 0.440$ ).

Adrenal insufficiency (AI) was stable 12 months after adrenalectomy in 8 (19.0%) patients and after organ-preserving operations in 2 (4.8%), ( $p = 0.044$ ). Transient nature of AI was diagnosed in 4 (9.5%) patients after adrenalectomy and 2 (4.8%) – after organ-preserving operations.

According to the results of CT tumors of the contralateral adrenal glands were detected in 4 patients: in 2 (4.8%) after adrenalectomies, in 2 (4.8%) – after resections. Recurrence of neoplasms on the side of operations was in 3 (7.1 %) patients after organ-preserving operations. Hypertrophy of the contralateral adrenal gland after unilateral adrenalectomy was observed in 19 (45.2%) patients, after resection – in 10 (23.8%),  $p = 0.040$ .

Treatment of patients with adrenal pathology was carried out according to the developed algorithm, depending on the side of the lesion, the size of tumors, the native density of the latter and the ability to produce autonomic hormones. Differential diagnosis of neoplasms was performed using CT of the abdominal cavity organs and intraoperative histological examination, due to which the final decision on the choice of the volume of surgery was made (Fig. 1, 2).

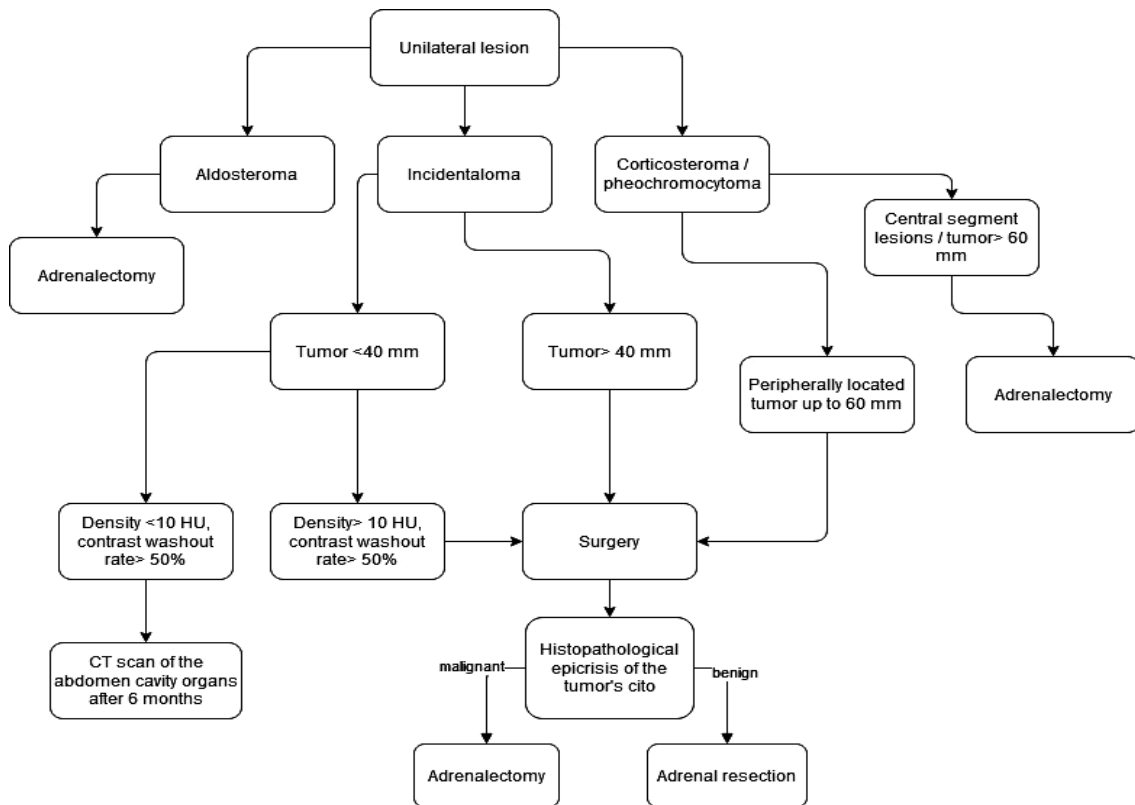


Fig. 1. Algorithm for surgical treatment of patients with benign tumors of the adrenal glands with unilateral gland lesion

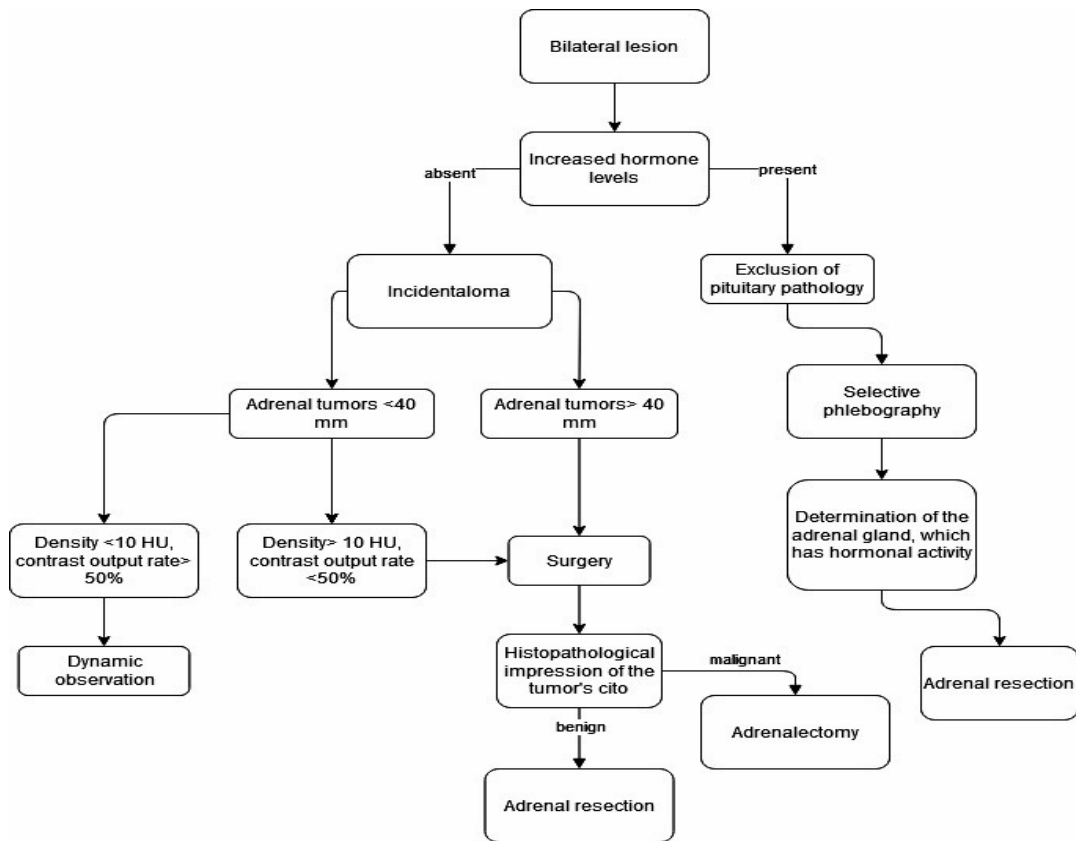


Fig. 2. Algorithm for surgical treatment of patients with benign tumors of the adrenal glands with bilateral gland lesion

Patients with tumors smaller than 4.0 cm, who had a native density <10.0 HU and a rate of contrast medium excretion >50.0%, were subjected to repeated CT of the adrenal cavity organs and examination of hormone levels after 6 months.

The use of the algorithm for the treatment of adrenal tumors led to an improvement in the results of surgical interventions in comparison with and after its introduction (Fig. 3).

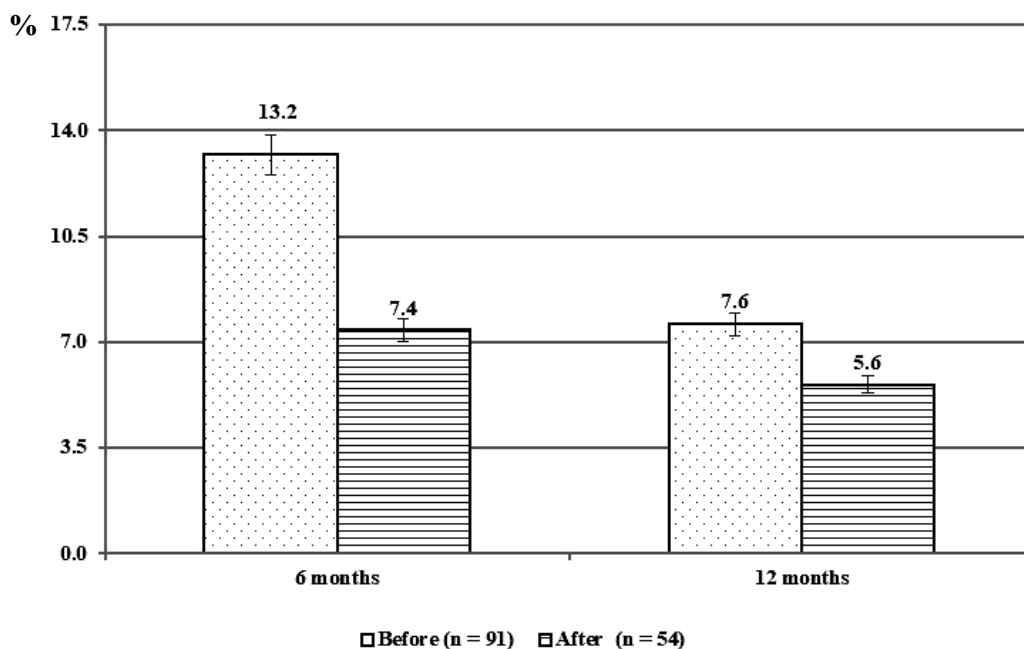


Fig. 3. Frequency of adrenal insufficiency in patients before and after the introduction of the algorithm.

When comparing the results of surgical treatment after 6 months, a decrease in the incidence of hypocorticism in patients treated according to the developed algorithm by 5.8% was observed ( $p=0.028$ ). After 12 months, there was no significant difference in results ( $p=0.326$ ).

In addition, when planning stage of surgical interventions, we were able to increase the number of organ-preserving interventions by expanding the indications to the latter (Fig. 4).

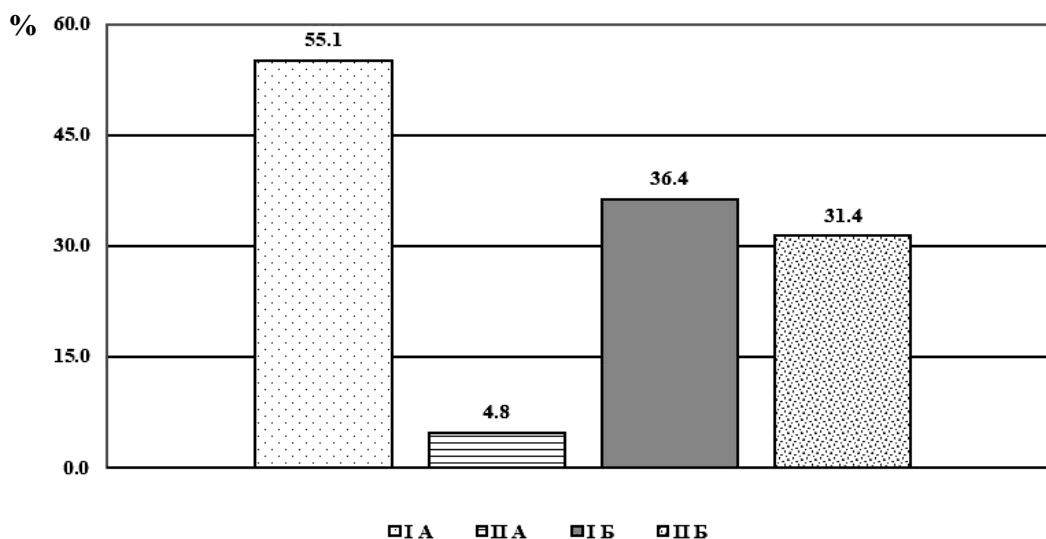


Fig. 4. Frequency of organ-preserving interventions in subgroups among patients with tumors greater than 4.0 cm

As a result of the study among the "large" tumors of the adrenal glands (more than 4.0 cm), the number of organ-preserving interventions increased from 4.8% to 31.4%,  $p=0.0001$ . As a result, there was a tendency to reduce the number of adrenalectomies by 18.7% ( $p=0.150$ ) in this category of patients.

The effectiveness of treatment of benign tumors was evaluated in terms of normalization of the hormonal status of patients and the frequency of recurrence of tumors. According to the results of our study, the performance of organ-preserving operations provided a more physiological postoperative period for the patient due to the functionality of the parenchyma of the preserved healthy part of the gland. In addition, resection of the adrenal glands led to a reduction in the number of complications and improvement of treatment outcomes in patients with pheochromocytomas and corticosteromas after 12 months.

The advantages of organ-preserving interventions were also noted by V.N. Chernyshov et al., M.E. Nichitaylo et al., K. Yuge et al. and others in their works. They report the possibility of adrenal resection with no recurrence in patients with aldosteromas. In cases of bilateral location of pheochromocytomas, the use of adrenal resections allowed to avoid the use of replacement therapy and the possibility of repeated surgery in patients with genetic hereditary diseases (multiple endocrine neoplasia type 2 and von Hippel-Lindau syndromes) [5, 7, 12, 14].

According to international standards of treatment for unilateral adrenal tumor, adrenalectomy is recommended [14]. According to the results of histopathological examination of the aldosteromas in 27.0% of cases after total adrenalectomies, examination in the non-neoplastic tissue of the gland revealed microadenomas, which justified the chosen volume of intervention. According to O.N. Sadriev, recurrence of adrenal tumors was observed in 11.2% of patients 5 years after unilateral removal of the gland [7, 9].

According to the results of our study, patients after adrenalectomy had more frequent episodes of tachycardia, elevated blood pressure, increased levels of cortisol and ACTH, which worsened the well-being of patients in 16.6% of cases. This may be due to the fact that the remaining adrenal gland was subjected to greater stimulation by the pituitary

gland to compensate for the hormonal function of the body, which caused hyperplasia of the glandular tissue [8, 83].

Researchers have not reached consensus on the tactics of management of patients with adrenal tumors up to 3.0 cm. According to R.Ya. Heydarov, N.A. Maistrenko, A.R. Vavilov, M.E. Beloshchytsky surgical tactics should be active, because when conducting additional tests, patients show subclinical hormonal activity, and surgical treatment leads to normalization of blood pressure [1, 5, 6]. In our opinion, after excluding the hormonal activity of tumors, signs of malignancy with the help of hormonal tests, additional functional tests and computed tomography / magnetic resonance imaging allow the surgeon to refuse from active tactics in favor of conservative observation. Therefore, a differentiated approach to the choice of tactics and method of treatment taking into account the quantitative and qualitative characteristics of the tumor allows you to choose the optimal scope of surgery to minimize possible complications for patients.

#### CONCLUSIONS

1. The choice of surgery should be individualized taking into account the clinical picture of the disease, the data of hormones, tumor size, the completeness of the adrenal gland and the relationship of the latter to the surrounding organs, structures.

2. Adrenal insufficiency 12 months after the intervention was determined to be by 14.2% more frequent after adrenalectomies ( $p=0.044$ ) compared with adrenal resection. Treatment according to the developed algorithm allowed to reduce the frequency of adrenal insufficiency by 5.8% ( $p=0.028$ ).

3. In the remote postoperative period, tumors of the contralateral glands occurred with the same frequency (4.8%) among patients after adrenalectomies and resections. Recurrence of the tumor after resection was detected in 3 cases (7.1%), resulting in 2.4% performed repeated operations with the final removal of the gland. The increase in the size of a single adrenal gland was 21.4% more common after adrenalectomy.

Conflict of interests. The authors declare no conflict of interest.

#### REFERENCES

1. Beloshitskii ME, Britvin TA. [Features of diagnostics and choice of surgical tactics for bilateral adrenal tumors]. Tavrish. mediko-biolog. vestnik. 2017;20(3-2). Russian.
2. Vetshev PS, Jankin PL, Zhivotov VA, Poddubnyj EI, Bejdullaeva TM, et al. [The choice of the method

of surgical treatment for benign adrenal tumors]. Vestn. nats. mediko-hirurg. centra im. N.I. Pirogova. 2017;12(2-4). Russian.

3. Beltsevich DG, Melnichenko GA, Kuznecov NS, Troshina EA, Platonova NM, Vanushko VJe, et al. [Clinical guidelines of the Russian Association of Endocrinologists

for the differential diagnosis of an adrenal incidentalomas]. *Endokr. hir.* 2016;10(4):31-42. Russian. doi: <https://doi.org/10.14341/serg2016431-42>

4. Klyushin DA, Petunin YU. [Evidence-based medicine. Application of statistical methods]. Moskva: Dialektika; 2007. p. 320. Russian.

5. Maistrenko NA, Zhelezniak IS, Romashhenko PN, Blumina SG. [Computed tomography technologies in adrenal surgery]. *Vestn. hir. imeni I.I. Grekova.* 2016;175(1). Russian. doi: <https://doi.org/10.24884/0042-4625-2016-175-1-30-36>

6. Geidarov RYa, Popov OS, Latypov VR, Dambaev GC, Gunter VJe, et al. [Organ-preserving approach in surgery of "small tumors" of the adrenal glands]. *Journ. of Siber. Med. Sc.* 2014;4. Russian.

7. Rybakov SI. [Tumors of the adrenal cortex: monograph]. ООО "АСМИ". 2018. p. 507. Russian.

8. Chaurova VG. [Possibilities of performing organ-saving surgeries in adrenal formations]. [dissertation]. Sankt-Peterburg; 2017. p. 136. Russian.

9. Shydlovskiy VO, Shydlovskiy OV, Rybakov SJ. [Primary hyperaldosteronism (broadening, pathogenesis, diagnosis, exhilaration)]. Ternopil: TNMU; 2019. p. 156. Ukrainian.

10. Shyngareeva LA, Baikov DE. [Possibilities of magnetic resonance imaging and computed tomography in the diagnosis of adrenal masses]. *Medicina.* 2017;5(1):36-43. Russian.

11. Shyngareeva LA, Baikov DE. [X-ray computed tomography in differential diagnosis of adrenal glands incidentalomas]. *Vestn. nac. med.-hirurgicheskogo centra im. N.Y. Pyrogova.* 2018;13(1):121-3. Russian.

12. Pwdziwiatr M, Natkaniec M, Kisialewski M, Major P, Matlok M, Kołodziej D, et al. Adrenal Incidentalomas Clinical Study: Should We Operate on Small Tumors in the Era of Laparoscopy. *Intern. Jour. of Endocr.* 2014;1:5. doi: <http://dx.doi.org/10.1155/2014/658483>

13. Lee JM, Kim MK, Ko SH, Koh JM, Kim BY, Kim SW, et al. Clinical guidelines for the management of adrenal incidentaloma. *Endocrinology and Metabolism.* 2017;32(2):200-18. doi: <https://doi.org/10.3803/EnM.2017.32.2.200>

14. Fassnacht M, Fassnacht M, Dekkers OM, Else T, Baudin E, Berruti A, et al. European Society of Endocrinology Clinical Practice Guidelines on the management of adrenocortical carcinoma in adults, in collaboration with the European Network for the Study of Adrenal Tumors. *European J of endocrinology.* 2018;179(4):G1-46. doi: <https://doi.org/10.1530/EJE-18-0608>

15. Erdem H, Çetinkınar S, Kuyucu F, Erçil H, Görür M, Sözen S. Surgical approach in adrenal incidentalomas: Report of thirteen cases and review of the literature. *Turk. Jour. of Surg./Ulusal cerrahi dergisi.* 2016;32(2):103. doi: <https://doi.org/10.5152/UCD.2015.3004>

## СПИСОК ЛІТЕРАТУРИ

1. Белошицкий М. Е., Бритвин Т. А. Особенности диагностики и выбора хирургической тактики при двухсторонних опухолях надпочечников. *Таврич. медико-биолог. вестн.* 2017. Т. 20. № 3-2.

2. Выбор метода хирургического лечения при доброкачественных опухолях надпочечников / П. С. Ветшев и др. *Вестн. Нац. медико – хирург. Центра им. Н. И. Пирогова.* 2017. Т. 12. С. 2-4.

3. Клинические рекомендации Российской ассоциации эндокринологов по дифференциальной диагностике инциденталом надпочечников / Д. Г. Бельцевич и др. *Эндокр. хир.* 2016. Т. 10, № 4. С. 31-42. DOI: <https://doi.org/10.14341/serg2016431-42>

4. Ключин Д. А., Петунин Ю. Доказательная медицина. Применение статистических методов. Москва: Дialektika. 2007. 320 с.

5. Майстренко Н. А., Железняк И. С., Ромащенко П. Н., Блюмина С. Г. Компьютерно-томографические технологии в хирургии надпочечников. *Вестн. Хир. имени И. И. Грекова.* 2016. Т. 175, № 1. С. 30-36. DOI: <https://doi.org/10.24884/0042-4625-2016-175-1-30-36>

6. Органосохранный подход в хирургии «малых опухолей» надпочечников / Р. Я. Гейдаров и др. *Journ. of Siber. Med. Sc.* 2014. No. 4.

7. Рыбаков С. И. Опухоли коры надпочечников: монография. ООО «АСМИ, 2018. 507 с.

8. Чаурова В. Г. Возможности выполнения органосберегающих операций при образованиях надпо-

чечников: дис... канд. мед. наук: 14.01.03 / Санкт-Петербург, 2017. 136 с.

9. Шидловський В. О., Шидловський О. В., Рыбаков С. Й. Первинний гіперальдостеронізм (поширеність, патогенез, діагностика, лікування). Тернопіль: ТНМУ, 2019. 156 с.

10. Шингареева Л. А., Байков Д. Э. Возможности магнитно - резонансной и компьютерной томографии в диагностике объемных образований надпочечников. *Медицина.* 2017. Т. 5, № 1. С. 36-43.

11. Шингареева Л. А., Байков Д. Э. Рентгеновская компьютерная томография в дифференциальной диагностике инциденталом надпочечников. *Вестн. Нац. мед.-хирургического Центра им. Н.И. Пирогова.* 2018. Т. 13, № 1. С. 121-123.

12. Adrenal Incidentalomas Clinical Study: Should We Operate on Small Tumors in the Era of Laparoscopy / M. Pwdziwiatr et al. *Intern. Jour. of Endocr.* 2014. Vol. 1. P. 5. DOI: <http://dx.doi.org/10.1155/2014/658483>

13. Clinical guidelines for the management of adrenal incidentaloma / J. M. Lee et al. *Endocrinology and Metabolism.* 2017. Vol. 32, No. 2. P. 200-218. DOI: <https://doi.org/10.3803/EnM.2017.32.2.200>

14. European Society of Endocrinology Clinical Practice Guidelines on the management of adrenocortical carcinoma in adults, in collaboration with the European Network for the Study of Adrenal Tumors / M. Fassnacht

et al. *European J of endocrinology*. 2018. Vol. 179, No. 4. P. G1-46. DOI: <https://doi.org/10.1530/EJE-18-0608>

H. Erdem et al. *Turk. Jour. of Surg.* 2016. Vol. 32, No. 2. P. 103. DOI: <https://doi.org/10.5152/UCD.2015.3004>

15. Surgical approach in adrenal incidentalomas: Report of thirteen cases and review of the literature /

Стаття надійшла до редакції  
11.01.2021

