

Rowan University

Rowan Digital Works

Stratford Campus Research Day

25th Annual Research Day

May 6th, 12:00 AM

Retinal Vasculitis: A Case Study

Peter Maduka
Rowan University

Sarah G. Bonaffini
Philadelphia College of Osteopathic Medicine

Naman Shah
Lake Erie College of Osteopathic Medicine

Deepika Malik
Moore Eye Institute

Follow this and additional works at: https://rdw.rowan.edu/stratford_research_day



Part of the [Eye Diseases Commons](#), [Ophthalmology Commons](#), [Pathological Conditions, Signs and Symptoms Commons](#), and the [Sense Organs Commons](#)

Let us know how access to this document benefits you - share your thoughts on our [feedback form](#).

Maduka, Peter; Bonaffini, Sarah G.; Shah, Naman; and Malik, Deepika, "Retinal Vasculitis: A Case Study" (2021). *Stratford Campus Research Day*. 98.

https://rdw.rowan.edu/stratford_research_day/2021/may6/98

This Poster is brought to you for free and open access by the Conferences, Events, and Symposia at Rowan Digital Works. It has been accepted for inclusion in Stratford Campus Research Day by an authorized administrator of Rowan Digital Works.

Retinal Vasculitis: A case study.

Peter Maduka 1, Sarah G. Bonaffini, D.O.2, Naman Shah3, Deepika Malik, M.D.4

1. Rowan University School of Osteopathic Medicine, Medical Student, Stratford, NJ.
2. Philadelphia College of Osteopathic Medicine, Medical Student, Philadelphia, PA.
3. Lake Erie College of Osteopathic Medicine, Bradenton, FL .
4. Moore Eye Institute, Springfield, PA

Abstract

Purpose: To describe a case of idiopathic retinal vasculitis.

Methods: Case report and literature review.

Case: A healthy 25-year-old female presented with a one-week history of a large floater in her right eye.

Patient's subjective complaint of floaters, including the scotoma on VF and the FA findings were most consistent with retinal vasculitis displaying predominant venous involvement. However, findings for acute macular neuroretinopathy and multiple evanescent white dot syndrome (MEWDS) were present as well. Autoimmune and infectious disease panels were negative. Neuro consult and brain MRI showed nonspecific, non-contributory findings. Several weeks later, following Medrol dose pack, patient reported significantly improved visual field and this was consistent with improved clinical and diagnostic findings.

Conclusion: Although cases of retina vasculitis have been linked to infectious, neoplastic, systemic and autoimmune diseases, idiopathic cases can present concurrently with other retinopathies.

Introduction

Retinal vasculitis as the name implies describes a sight-threatening condition characterized by inflammation of the retinal vessels. As an umbrella term, it describes various manifestations of retinal vasculature inflammation including perivascular sheathing, cuffing, intraretinal infiltrates, necrosis, and vascular leakage or occlusion (1, 2, 3). Although the manifestation of retinal vasculitis is clinical apparent on eye examination, the pathophysiology is yet to be clearly delineated (1).

Due to lymphocytic cellular findings in the perivascular region in certain non-infectious cases, some studies have hypothesized an immunological basis to the inflammation seen in retinal vasculitis (4). Other studies have implicated certain genes in some rare forms of retinal vasculitis (5).

Furthermore, retinal vasculitis have been linked to infectious etiologies including toxoplasmosis, HIV, tuberculosis and even following streptococcal infection (3, 6, 7, 8). In addition, various systemic diseases including but not limited to Behçet's disease, sarcoidosis, systemic lupus erythematosus and multiple sclerosis have been shown to be implicated in cases of retinal vasculitis (9)

The diversity of findings in infectious, malignancy, autoimmune and idiopathic settings furthermore complicates the precise etiology of retinal vasculitis; hence, a multifactorial approach is important if diagnosis and treatment is to be effective. Based on etiology, diagnostic and laboratory tests will vary and treatment may include steroids, antimicrobial and immunomodulatory agents (4).

Here, we discuss a case of retinal vasculitis which also presented with findings of Acute Macular Neuroretinopathy (AMN) and Multiple Evanescent White Dot Syndrome (MEWDS) in a young, healthy female.

Methods and Materials

Case report and literature review

Results

A healthy 25-year-old female with no known ophthalmic history presented with a week-long complaint of a sudden, constant, and unchanging large floater in her right eye. Best-corrected visual acuity (BCVA) was 20/30 in both eyes without improvement. Extraocular movements (EOM) and pupillary exam were normal. Intraocular pressure was within normal limits and anterior segment exam was unremarkable

Optical coherence tomography (OCT) in the right eye showed disruption of the inner segment/outer segment (ISOS) inferotemporal to the foveal avascular zone (FAZ) (Fig A). Visual field (Fig B) was performed demonstrating a superior nasal scotoma in the right eye consistent with ISOS disruption as seen on OCT. Wide field fundus and Autofluorescence were within normal limits, however, Fluorescein angiography (FA) imaging of the right eye displayed peripheral and mid-peripheral venous staining (Fig C). The left eye displayed nasal peripheral venous staining (Fig C). Both eyes demonstrated significant granular appearance of the posterior pole.

The patient's medical and surgical history were unremarkable except for a history of migraines with associated transient floaters since the age of 15. Family history was unremarkable except for a maternal cousin with undiagnosed alopecia since youth. There was also no history of rashes, fevers, seizures, joint pains, or diarrhea. The patient is sexually active and denied the use of recreational drugs.

Laboratory testing for CBC, ESR, C-reactive protein, cyclic citrullinated peptide and ACE were all within normal limits. Also, ANCA panel, Protein C and A were all negative. Additional testing including HLAB5/A29, SSA/SSB, Toxoplasmosis, HIV, Syphilis IgG/IgM, Lyme, Bartonella, CMV, VZV (IgG positivity), and RF were all negative. The patient however displayed positivity for HSV, and urinalysis revealed a mixed flora.

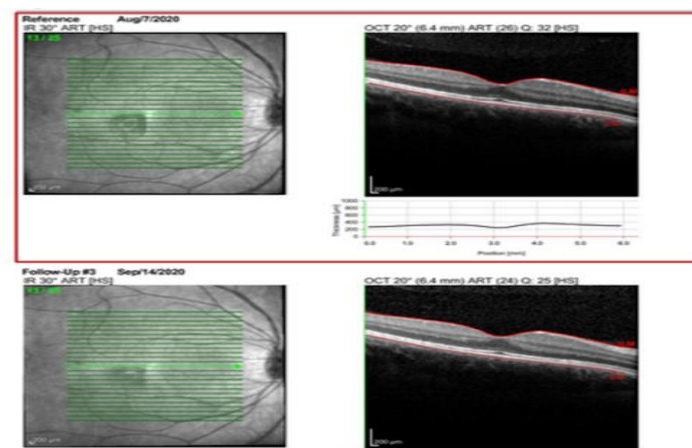


Figure A: Optical Coherence Tomography demonstrating disruption of the inner segment/outer segment (ISOS) inferotemporal to the foveal avascular zone (FAZ).

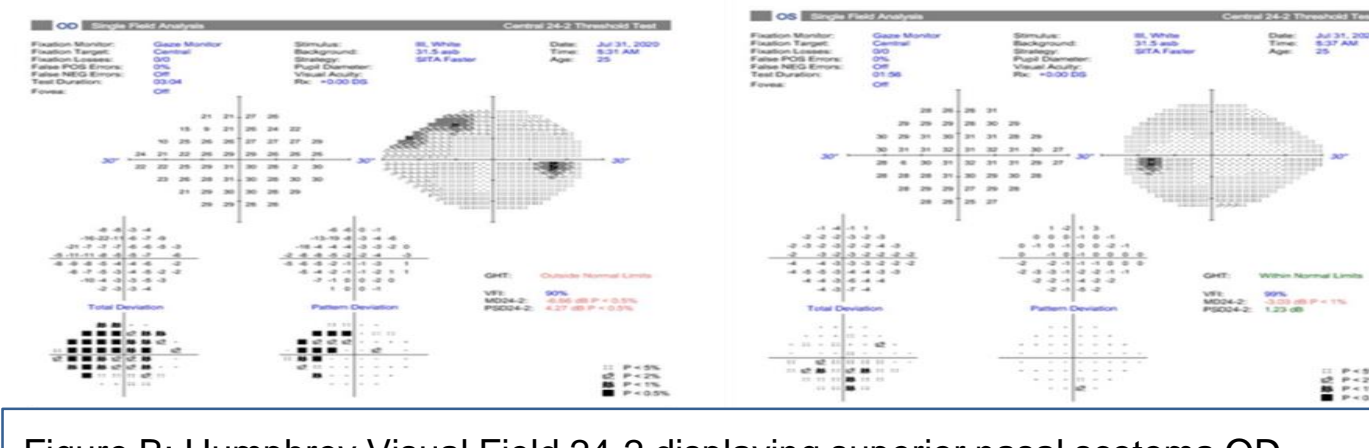


Figure B: Humphrey Visual Field 24-2 displaying superior nasal scotoma OD, normal field OS.

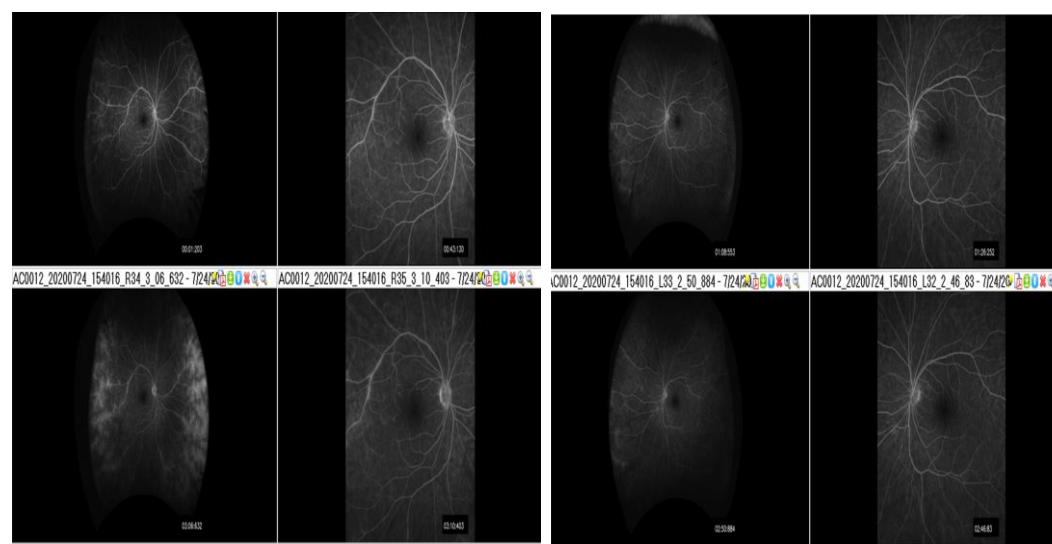


Figure C: Fluorescein Angiogram: OD: vascular staining, nasal and temporal periphery. OS: small focal vascular staining, nasal periphery.

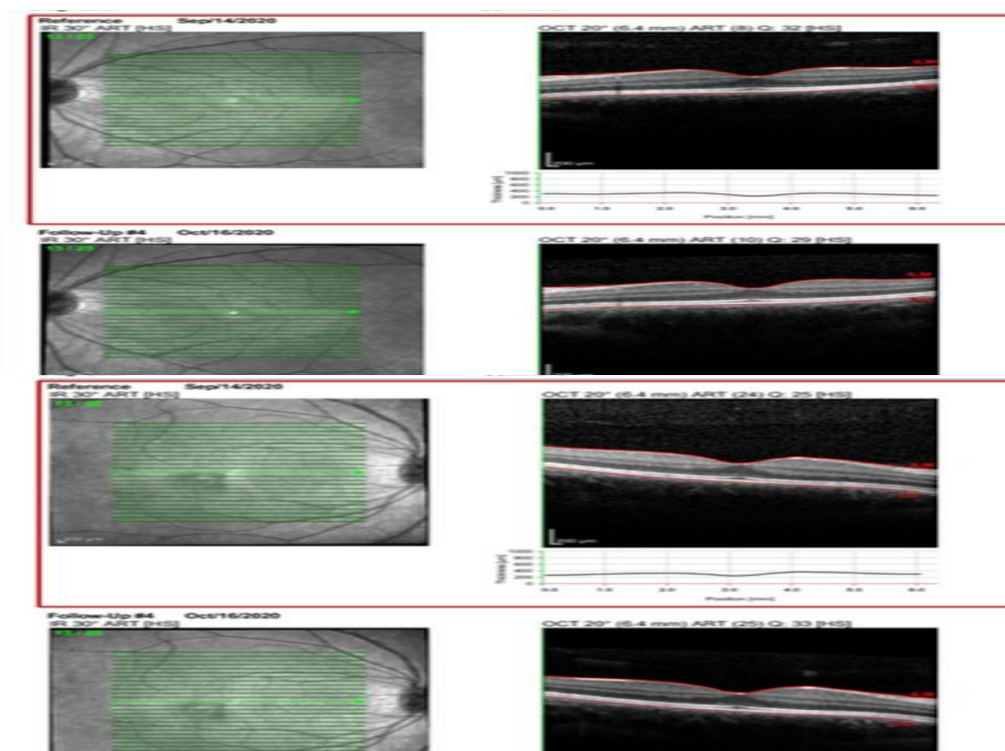


Figure D: Optical Coherence Tomography demonstrating no edema and fading disruption of the ISOS junction inferotemporal to the FAZ.

Discussion

Based on clinical appearance, OCT and FA, the patient's findings showed evidence of the following;

- Acute macular neuroretinopathy (OCT changes in macula)
 - Multiple Evanescent White Dot Syndrome (MEWDS) (granular appearance of posterior pole on FA)
 - Retinal vasculitis, predominant venous involvement (as on FA).
- Differential diagnosis also included disseminated choroiditis and chorioretinitis.

The patient's subjective complaint of floaters, including the scotoma on VF and the FA examination were however most consistent with retinal vasculitis displaying predominant venous involvement (10). Based on the working diagnosis, the patient was prescribed a Medrol dose pack that she started taking after she was cleared for UTI by her OB/GYN. She did not require antibiotics at this time.

A neuro consult was requested to rule out multiple sclerosis. MRI Brain showed nonspecific findings likely associated with her migraine headaches. Demyelinating disorder was considered unlikely and there was no evidence of intracranial hemorrhage, territorial infarct, or mass.

On follow up visit several weeks later, there were no signs of active inflammation on ocular examination. OCT revealed fading of the disruption of the ISOS junction inferotemporal to the FAZ (Fig D). The FA showed decreased peripheral and mid-peripheral venous staining consistent with a resolving vasculitis. She reported significantly improved visual field and this was consistent with improved scotoma on formal VF testing.

Clinical findings in retinal vasculitis are prominent on fundus examination; however, understanding the etiology can be complex and requires a multisystem approach. Although infectious and systemic etiologies can be apparent on laboratory testing, some cases of retinal vasculitis have been linked to idiopathic causes (11). Although visual prognosis is good with appropriate and prompt treatment, certain complications including macular ischemia, retinal vein or arterial occlusions, recurrent neovascularization, vitreous hemorrhage, and retinal detachment are associated with disease progression and can lead to poor visual outcomes (1,2).

A detailed patient history and ocular exam are essential in identifying the characteristic findings in retinal vasculitis. Our patient's subjective complaint of floaters, including the scotoma on VF and the FA examination were very consistent with retinal vasculitis. However, the patient's OCT findings showed evidence of Acute macular neuroretinopathy and the granular appearance on FA of posterior pole were consistent with Multiple Evanescent White Dot Syndrome (MEWDS).

Upon diagnosis, to ensure adequate treatment, additional laboratory testing including autoimmune and infectious disease panels are required to discriminate between infectious and noninfectious etiologies. However, even in the absence of a clear etiology, prompt treatment must be initiated to preserve visual prognosis and prevent complications.

Conclusions

The manifestation of retinal vasculitis in most cases is clinical apparent on objective eye examination, however, the etiology may not be apparent (1). Although cases of retina vasculitis have been linked to infectious, neoplastic, systemic and autoimmune diseases, idiopathic cases can present and are common (4), hence a negative work-up should not delay diagnosis and treatment. In addition, prominent findings of retinal vasculitis may occur in conjunction with other retinal pathology as demonstrated in this case. With adequate and prompt treatment however, clinical resolution and a good visual prognosis is possible (1) (2).

Contact

Peter Maduka

Rowan University School of Osteopathic Medicine

Email: maduka65@rowan.edu

References

1. Abu El-Asrar AM, Herbort CP, Tabbara KF. Retinal vasculitis. *Ocul Immunol Inflamm*. 2005;13(6):415-433. doi:10.1080/09273940591003828
2. Walton RC, Ashmore ED. Retinal vasculitis. *Curr Opin Ophthalmol*. 2003;14(6):413-419. doi:10.1097/0005735-200312000-00015
3. Butler NJ, Furtado JM, Winthrop KL, Smith JR. Ocular toxoplasmosis II: clinical features, pathology and management. *Clin Exp Ophthalmol*. 2013;41(1):95-108. doi:10.1111/j.1442-9071.2012.02838.x
4. Hughes EH, Dick AD. The pathology and pathogenesis of retinal vasculitis. *Neuropathol Appl Neurobiol*. 2003;29(4):325-340. doi:10.1046/j.1365-2990.2003.00499.x
5. Rosenbaum JT, Sibley CH, Lin P. Retinal vasculitis. *Curr Opin Rheumatol*. 2016;28(3):228-235. doi:10.1097/BOR.0000000000000271
6. Drake-Casanova P, Moreno-Arrones JP, Gorroño Echebarría M, Dapena-Sevilla I, Pareja-Esteban J, Vleming-Pinilla E. Vasculitis retiniana por VIH [HIV retinal vasculitis]. *Arch Soc Esp Oftalmol*. 2010;85(1):32-34.
7. Chen L. Tubercular Retinal Vasculitis. *JAMA Ophthalmol*. 2019;137(4):e184499. doi:10.1001/jamaophthalmol.2018.4499
8. Ali NQ, Niederer RL. Severe retinal vasculitis as a manifestation of poststreptococcal syndrome in a child. *Clin Exp Ophthalmol*. 2019;47(9):1198-1199. doi:10.1111/ceo.13635
9. Gascon P, Jarrot PA, Matonti F, Kaplanski G. Vasculites rétinienne et maladies systémiques [Retinal vasculitis and systemic diseases]. *Rev Med Interne*. 2018;39(9):721-727. doi:10.1016/j.revmed.2018.04.013
10. Ku JH, Ali A, Suhler EB, Choi D, Rosenbaum JT. Characteristics and visual outcome of patients with retinal vasculitis. *Arch Ophthalmol*. 2012;130(10):1261-1266. doi:10.1001/archophthalmol.2012.1596
11. Menia NK, Kiran S, Bansal R. Idiopathic retinal vasculitis, aneurysms, and neuroretinitis. *Indian J Ophthalmol*. 2018;66(8):1195. doi:10.4103/ijo.IJO_49_18